

Out-of-body experience and autoscopia of neurological origin

Olaf Blanke,^{1,2,3} Theodor Landis,³ Laurent Spinelli^{1,2} and Margitta Seeck¹

¹Laboratory of Presurgical Epilepsy Evaluation, Programme of Functional Neurology and Neurosurgery, University Hospitals, Geneva-Lausanne, and ²Functional Brain Mapping Laboratory and ³Neurology Clinic, Department of Neurology, University Hospital, Geneva, Switzerland

Correspondence to: Dr Olaf Blanke, Department of Neurology, University Hospital of Geneva, 24 rue Micheli-du-Crest, 1211 Geneva, Switzerland
E-mail: olaf.blanke@hcuge.ch

Summary

During an out-of-body experience (OBE), the experient seems to be awake and to see his body and the world from a location outside the physical body. A closely related experience is autoscopia (AS), which is characterized by the experience of seeing one's body in extrapersonal space. Yet, despite great public interest and many case studies, systematic neurological studies of OBE and AS are extremely rare and, to date, no testable neuroscientific theory exists. The present study describes phenomenological, neuropsychological and neuroimaging correlates of OBE and AS in six neurological patients. We provide neurological evidence that both experiences share important central mechanisms. We show that OBE and AS are frequently associated with pathological sensations of position, movement and perceived completeness of one's own body. These include vestibular sensations (such as floating, flying, elevation and rotation), visual body-part illusions (such as the illusory shortening, transformation or movement of an extremity) and the experience of seeing one's body only partially during an OBE or AS. We also find that the patient's body position prior to the experience influences OBE and AS. Finally, in five patients, brain damage or brain dysfunction is localized to the temporo-parietal junction (TPJ). These results suggest that

the complex experiences of OBE and AS represent paroxysmal disorders of body perception and cognition (or body schema). The processes of body perception and cognition, and the unconscious creation of central representation(s) of one's own body based on proprioceptive, tactile, visual and vestibular information—as well as their integration with sensory information of extrapersonal space—is a prerequisite for rapid and effective action with our surroundings. Based on our findings, we speculate that ambiguous input from these different sensory systems is an important mechanism of OBE and AS, and thus the intriguing experience of seeing one's body in a position that does not coincide with its felt position. We suggest that OBE and AS are related to a failure to integrate proprioceptive, tactile and visual information with respect to one's own body (disintegration in personal space) and by a vestibular dysfunction leading to an additional disintegration between personal (vestibular) space and extrapersonal (visual) space. We argue that both disintegrations (personal; personal–extrapersonal) are necessary for the occurrence of OBE and AS, and that they are due to a paroxysmal cerebral dysfunction of the TPJ in a state of partially and briefly impaired consciousness.

Keywords: out-of-body experience; autoscopia; neurology; body schema; multisensory processing

Abbreviations: AP = autoscopic phenomenon; AS = autoscopia; FLAIR = fluid attenuated inversion recovery; OBE = out-of-body experience; SPECT = single photon emission computer tomography; TPJ = temporo-parietal junction.

Received June 30, 2003. Revised August 22, 2003. Accepted September 22, 2003. Advanced Access publication December 12, 2003

Introduction

An out-of-body experience (OBE) may be defined as the experience in which a person seems to be awake and to see his body and the world from a location outside the physical body. A closely related experience is autoscopia (AS), which is

characterized by the experience of seeing one's body in extrapersonal space. Both experiences are classified as autoscopic phenomena (AP) (Devinsky *et al.*, 1989; Brugger *et al.*, 1997) as, during an OBE and an AS, the

experient sees himself as a part of the extrapersonal world. Yet, during the OBE, the experient appears to 'see' himself and the world from a location other than his physical body (parasomatic visuo-spatial perspective), whereas the experient during AS remains within the boundaries of his physical body (physical visuo-spatial perspective) (Green, 1968; Blackmore, 1982; Irwin, 1985; Devinsky *et al.*, 1989; Brugger, 2002).

OBE and AS (OBE/AS) have fascinated mankind from time immemorial and are abundant in folklore, mythology and spiritual experiences (Rank, 1925; Menninger-Lerchenthal, 1946; Todd and Dewhurst, 1955; Sheils, 1978). In more recent times, both experiences became a frequent and popular topic in the romantic literary movement of the 19th Century (Rank, 1925; Todd and Dewhurst, 1955; Böschstein, 1987; McCulloch, 1992). Reflecting these popular trends, detailed case descriptions (Muldoon and Carrington, 1929; Yram, 1972; Alvarado, 1992) and medical reports (Du Prel, 1886; Féré, 1891; Sollier, 1903) began to appear. Since then, both experiences have been described repeatedly in patients suffering from neurological or psychiatric disease (Menninger-Lerchenthal, 1935, 1946, 1961; Lhermitte, 1939; Hécaen and Ajuriaguerra, 1952; Todd and Dewhurst, 1955; Lukianowicz, 1959; Leischner, 1961; Frederiks, 1969; Critchley, 1969; Devinsky *et al.*, 1989; Grüsser and Landis, 1991; Dening and Berrios, 1994; Brugger *et al.*, 1997). Both AP have been related to various neurological diseases such as epilepsy, migraine, neoplasia, infarction and infection (Menninger-Lerchenthal, 1935, 1946; Lippman, 1953; Devinsky *et al.*, 1989; Grüsser and Landis, 1991; Dening and Berrios, 1994; Brugger *et al.*, 1997; Podoll and Robinson, 1999) and psychiatric diseases such as schizophrenia, depression, anxiety, and dissociative disorders (Menninger-Lerchenthal, 1935; Lhermitte, 1939; Bychovski, 1943; Hécaen and Ajuriaguerra, 1952; Todd and Dewhurst, 1955; Lukianowicz, 1958; Dening and Berrios, 1994).

Most neurological authors agree that OBE/AS relate to a paroxysmal pathology of body perception and cognition (or body schema). Yet, it is not known which of the many senses involved in body perception and cognition are primarily involved in the generation of OBE/AS. Thus, some authors postulated a dysfunction of proprioception and kinesthesia, others a dysfunction of visual or vestibular processing, as well as combinatory dysfunctions between these different sensory systems (Menninger-Lerchenthal, 1935; Hécaen and Ajuriaguerra, 1952; Leischner, 1961; Frederiks, 1969; Devinsky *et al.*, 1989; Brugger *et al.*, 1997; Grüsser and Landis, 1991). OBE/AS are also known in the healthy population, where they happen generally once or twice in a lifetime and have a prevalence of ~10% (Menninger-Lerchenthal, 1935; Lhermitte, 1951; Hécaen and Ajuriaguerra, 1952; Green, 1968; Palmer, 1979; Blackmore, 1982; Irwin, 1985). Parapsychological and psychological authors have intensively investigated OBE/AS in healthy subjects based on case collections, surveys and experimental investigations. Whereas, some parapsychological authors sug-

gest that OBE might reflect the projection of a subtle, non-physical aspect of one's personality in extrapersonal space and thus an actual separation of the mind from the body (Muldoon and Carrington, 1929; Crookall, 1964; Rogo, 1982; but see Irwin, 1985; Blackmore, 1982; Alvarado, 1992), most psychological theories assume OBE to reflect an imaginal experience (Schilder, 1914, 1935; Palmer, 1978; Irwin, 1985; Blackmore, 1982). Thus, later authors were able to link OBEs to processes of mental imagery and visuo-spatial perspective-taking (Irwin, 1981, 1986; Cook and Irwin, 1983; Blackmore, 1987); Brugger (2002) has recently included this in his classification of OBE/AS in neurological and psychiatric patients.

With respect to the neuroanatomical underpinnings of OBE/AS, most studies found the parietal, temporal and occipital lobe to be involved (Hécaen and Ajuriaguerra, 1952; Todd and Dewhurst, 1955; Lunn, 1970; Devinsky *et al.*, 1989; Brugger *et al.*, 1997). Some of these authors have suggested either a predominance of temporal lobe involvement (Devinsky *et al.*, 1989; Grüsser and Landis, 1991; Dening and Berrios, 1994) or parietal lobe (Menninger-Lerchenthal, 1935, 1946; Hécaen and Ajuriaguerra, 1952). Others suggested that both experiences have no precise brain localization (Lhermitte, 1951). With regard to hemispheric asymmetries, some authors found no hemispheric predominance (Hécaen and Ajuriaguerra, 1952; Frederiks, 1978; Devinsky *et al.*, 1989; Dening and Berrios, 1994), while others have suggested a right hemispheric predominance (Menninger-Lerchenthal, 1935, 1946; Grüsser and Landis, 1991; Brugger *et al.*, 1997).

Despite these numerous investigations, systematic neurological studies of OBE and AS are rare. To date, there is no widely accepted and testable neuroscientific theory about the central mechanisms of OBE/AS (Dening and Berrios, 1994). This is surprising as other body illusions, such as supernumerary phantom limbs or the transformation of an extremity (visual illusions of body parts), have been systematically investigated by many neuroscientists (Hécaen and Ajuriaguerra, 1952; Ramachandran and Hirstein, 1998; Brugger *et al.*, 2000; Halligan, 2003). Importantly, these studies have led to the description of some of the central mechanisms of visual illusions of body parts and to the development of more efficient treatments (Sathian *et al.*, 2000). However, this is not the case for visual illusions of the entire body such as OBE/AS, which continue to occupy a neglected position between neurobiology and mysticism.

The present study describes phenomenological, neurological, neuropsychological and neuroimaging correlates of OBE/AS in six neurological patients. This was performed in order to develop testable hypotheses about their underlying neural mechanisms.

Methods

Phenomenology

Each case was analysed by means of a semi-structured interview, which recorded detailed phenomenological information about the

OBE/AS (visual, vestibular, auditory, tactile, proprioceptive and motor characteristics). We also inquired about the visuo-spatial perspective from which the experience was 'seen' (physical or parasomatic visual perspective) and the visual characteristics of one's own 'seen' body (completeness: whether all body parts were seen; body position: standing, sitting, supine; eventual actions). We asked explicitly for simple and complex visual, auditory and tactile hallucinations, the presence of visual field loss, and visual and non-visual body-part illusions (Hécaen and Ajuriaguerra, 1952). With respect to vestibular manifestations, we inquired about the sensation of rotation, vertigo, falling, elevation, flying, floating, lightness and heaviness (Smith, 1960). For all manifestations, we asked whether they appeared before, during, or after OBE/AS or at different instances. We also inquired about emotional feelings during OBE/AS. Patients were recruited from the Neurology Clinic, Geneva (Patients 4, 5) and from the Presurgical Epilepsy Unit (Patients 1, 2, 3, 6). Informed consent was obtained and the study was conducted in conformity with The Declaration of Helsinki.

Surface and intracranial EEG, electrical cortical stimulation

Continuous long-term video-EEG recordings with 29 scalp and two sphenoidal electrodes were carried out in Patients 1, 2 and 6 (Blanke *et al.*, 2000a). Repetitive EEGs in Patients 4 and 5 were performed by 19 scalp electrodes. Patients 2 and 3 were further investigated using subdural grid recordings (Ad-Tech, USA), since non-invasive investigations did not allow us to define the epileptic focus and its anatomical dissociation from vital cortex (Lesser *et al.*, 1987). Eighty-eight electrodes were implanted in Patient 2 and 102 electrodes in Patient 3. Subdural electrodes and electrical stimulation were used as described by Blanke *et al.* (2000b).

Clinical examination

A complete neurological examination including quantitative visual field testing and an extensive neuropsychological examination (oral and written language, visual gnosias, spatial functions, executive functions, memory; Pegna *et al.*, 1998) was carried out for each patient.

Neuroimaging

In all patients, 3D MRI was carried out. MRI sequences included T1, T2 weighted imaging as well as a fluid attenuated inversion recovery (FLAIR) sequence (additional diffusion and perfusion imaging were performed for Patient 4). For each patient, the anatomical region implicated in OBE/AS generation was estimated based on neuroimaging examinations that were available in each patient [in addition to 3D MRI: intracranial EEG, intracranial stimulation, EEG spike mapping, PET and single photon emission computer tomography (SPECT)]. EEG spike mapping was performed by applying a distributed linear inverse solution [LAURA (based on Local AutoRegressive Averages); Grave *et al.*, 2001] within the 3D MRI of the patient (Michel *et al.*, 1999; Lantz *et al.*, 2001).

Individual lesion analysis

For each patient, the results of neuroimaging examinations were transformed to the individual patient's 3D MRI (Spinelli *et al.*, 2001; Blanke *et al.*, 2003). Three-dimensional rendering and superimpos-

ing of the individual lesions and localized dysfunctions were carried out using AVS software (Advanced Visual Systems, USA). In Patient 1, ictal SPECT and three-dimensional EEG spike mapping were matched to MRI (PET could not be recovered in digital format). In Patient 2, the gyral location of the intracranial electrodes where her seizures (those related to OBEs) started was matched to MRI. In Patient 3, the gyral location of the intracranial electrodes whose stimulation resulted in an OBE was matched to MRI. In Patient 4, no lesion could be determined (MRI and EEG recordings were normal). In Patient 5, diffusion MRI and EEG spike mapping were matched to MRI (neither SPECT nor PET were carried out). In Patient 6, interictal PET and EEG spike mapping were matched to MRI (ictal SPECT was unrevealing).

Group lesion analysis

The regions as suggested by the individual overlap analysis for the five patients (all patients except Patient 4) were used to determine the region of overlap overall patients (mean overlap analysis). This was performed by transposing the MRI (including the location of individual lesion overlap) of each patient onto Patient 5's MRI (left hemisphere).

Case reports

A short summary of the clinical findings is given in Table 1 for each patient. Special emphasis is given to the phenomenological description of OBE/AS. More clinical and phenomenological details are given as supplementary material available at Brain Online.

Patient 1

Patient 1 suffered from complex partial seizures that were characterized initially by an OBE or visual manifestations of varying degree (supplementary material). Pharmacoresistant epilepsy was diagnosed. Presurgical epilepsy evaluation suggested right occipito-parietal seizure onset partly overlapping and anterior to a right occipito-parietal dysembryoblastic neuroepithelial tumor (Fig. 2A, pink).

OBE. Patient 1 felt as if she would be elevated vertically and effortlessly from her actual position associated with vertigo and fear. She saw herself (entire body as lying on the ground, facing up) and some unknown people (some were standing around her body, others were moving around) below. Initially, she felt as being 'above her real body', but that she was rapidly rising higher. She felt as if her elevated body was in the horizontal position, but did not see any part of it. The visual scene always took place outdoors and was described as 'a green meadow or hill'. The sensation of elevation continued and, quickly, she saw everything from so far away that she could not distinguish details anymore stating that she saw "something like a map of some country as you find in geography books". Here, the elevation stopped and she fell back "to earth". The patient indicated that OBEs occurred independent of her body position.

Patient 2

Patient 2 suffered from complex partial seizures that were characterized initially by the hearing of a humming sound in her right backspace. On other occasions, she had the visual impression (while lying down) that her legs were elevated and bent (at the knees) followed by stretching, in rhythmic alternation. If she asked

Table 1 Clinical data: results of neurological examination, visual field testing, ictal and interictal surface EEG recordings (sEEG), intracranial EEG (iEEG), 3D MRI, PET, SPECT, neuropsychological examination and individual lesion overlap analysis

Patient (origin)	Neurology	VF	sEEG Ictal/ seizures	sEEG Interictal	iEEG Ictal/ stimulation	MRI	PET Interictal	SPECT Ictal	Neuro-psychology Interictal/post-ictal	OBE/AS Site gyrus
1 (epileptic seizure)	Normal	Normal	R (post T)	-	-	R (O, P, T)	R (O, P)	R (T, O, P)	Topographical agnosia, mental rotation deficit, visuo-spatial memory deficit	AG, LOG, STG, MTG
2 (epileptic seizure)	Normal	Normal	L (post T)	L (T, post T)	L (AG, STG, PCG)	L (post T)	L (T,P)	L (T,P)	Anomic aphasia, verbal fluency deficit, oral and written comprehension deficit	AG, STG, PCC
3 (electrical cortical stimulation)	Normal	Normal	R (T, ant T)	R (T)	R (AG,STG)	Normal	Normal	R (T)	Visuo-spatial and verbal memory deficit, visual agnosia, visuo-spatial fluency	AG, STG
4 (not known)	Left motor loss	-	Normal	Normal	-	Normal	-	-	Normal	-
5 (epileptic seizure)	Spatiotemporal disorientation, right sensori-motor loss	Right lateral homonymous hemianopia	-	L (T, F)	-	L (insula, P, O)	-	-	Global aphasia, apraxia	LOG, AG, insula
6 (epileptic seizure)	Normal*	Normal	L (T)	L (ant T, post T)	-	Bilateral postsurgical subcortical lesions	L (T)	Normal	Naming deficit, ideomotor apraxia, verbal fluency deficit, verbal and visuo-spatial memory deficit	STG, MTG, AG

Anatomical location indicated by: AG = angular gyrus; F = frontal; L = left hemisphere; LOG = lateral occipital gyrus; MTG = middle temporal gyrus; O = occipital; P = parietal; PCC = precentral gyrus; R = right hemisphere; STG = superior temporal gyrus; T = temporal.

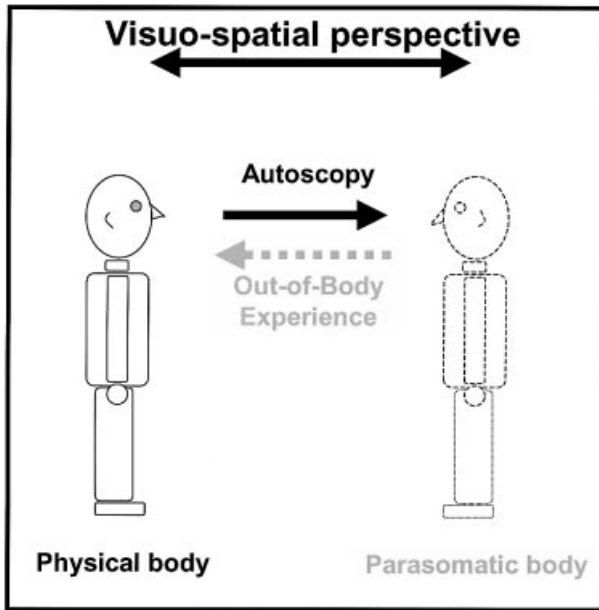


Fig. 1 Phenomenology of OBE and AS. An OBE is defined as the experience in which a person seems to see his/her body and the world from a location outside the physical body. During an OBE, the experient appears to 'see' himself (physical body, depicted on the left) and the world from a location other than his physical body (parasomatic body and visuo-spatial perspective, depicted on the right). AS is defined as the experience of seeing one's body (depicted on the right) in extrapersonal space, but from the habitual physical visuo-spatial perspective. During AS, the observer thus remains within the boundaries of his physical body (depicted on the left). Both experiences are classified as autoscopic phenomena since, during OBE and AS, the observer sees himself as a part of the extrapersonal world. The direction of the visuo-spatial perspective is indicated by an arrow for both experiences.

another person whether they saw her legs moving, they always responded negatively. Pharmacoresistant epilepsy was diagnosed. During non-invasive presurgical epilepsy evaluation, Patient 2 presented an OBE during a complex partial seizure due to a focal dysplasia in the left parieto-temporal cortex. Subdural electrodes allowed us to localize the seizure onset zone to the angular gyrus, the posterior superior temporal gyrus and the postcentral gyrus in the left hemisphere (Fig. 2B, red electrodes), overlapping partly with the lesion as defined by MRI (extending posteriorly, where language function was found). Focal resection of the middle part of the left superior and middle temporal gyrus, leaving language cortex intact, was carried out. Following the operation, the frequency and length of complex partial seizures were diminished. Yet, partial seizures with different semiology characterized by AS and vestibular manifestations without auditory manifestations were noted. Further work is pending.

OBE (prior to operation). The patient was lying in bed and awakened from sleep, and the first thing she remembered was "the feeling of being at the ceiling of the room". She "[...] had the impression that I was dreaming that I would float above [under the ceiling] of the room [...]". The patient also saw herself in bed (in front view) and gave the description that "the bed was seen from above" and that "there was a man and that she was very frightened". The scene was in colour, and was visually clear and very realistic.

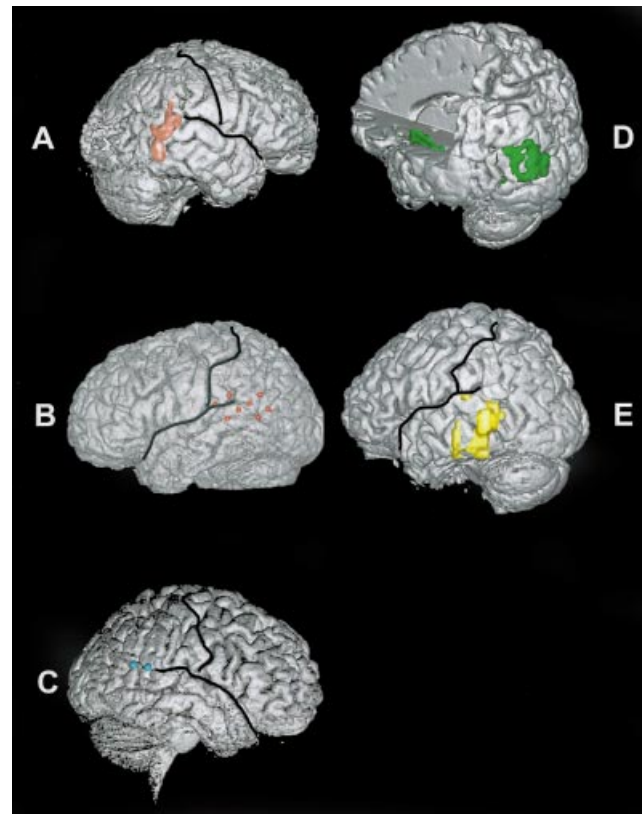


Fig. 2 Individual lesion analysis. In the five patients in whom a lesion could be defined, the results of lesion overlap analysis are shown on the individual 3D MRIs. (A–C) Lesion overlap for patients with OBE (note that Patient 2 initially experienced OBE, but after partial resection of her epileptic focus, she experienced AS). (D–E) Lesion overlap for patients with AS. In Patient 1 (A), lesion overlap (pink) is centred on the posterior part of the superior and middle temporal gyri and the angular gyrus in the right hemisphere. In Patient 2 (B), seizure onset (red) was localized to the posterior part of the superior temporal gyrus, the angular gyrus and the inferior postcentral gyrus in the left hemisphere. In Patient 3 (C, blue), electrical cortical stimulation of the junction of the posterior part of the superior temporal gyrus and the angular gyrus in the right hemisphere induced an OBE. In Patient 4 (D), lesion overlap (green) is centred in two regions in the left hemisphere. One region included the angular gyrus and the lateral occipital gyrus; the other region was localized to the insula. Lesion overlap in Patient 5 (E, yellow) included the posterior parts of the superior and middle temporal gyrus, and the adjacent angular gyrus in the left hemisphere.

Video analysis revealed facial automatisms and a patient who looked to the left and immediately afterwards sat up. She did not answer questions asked 30 s after seizure onset. During the post-ictal phase, she presented habitual word finding difficulties.

AS (after the operation). Post-operatively, Patient 2 described the appearance of AS characterized by the impression as if she were seeing herself from behind herself (seeing the back of her head and upper torso without arms). She felt as if she were "standing at the foot of my bed and looking down at myself" and as if "looking through a telescope". During the same experience, Patient 2 also has the impression of 'seeing' from her physical visuo-spatial perspective, which looked at the wall immediately in front of her. Asked at

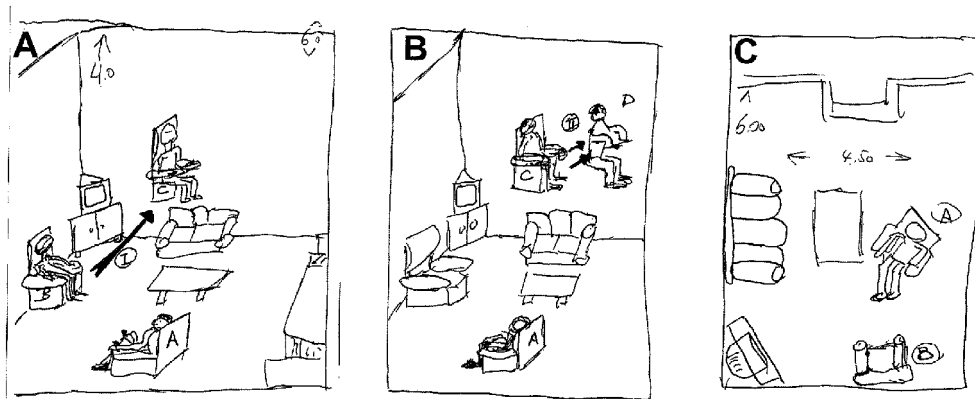


Fig. 3 Graphical depiction of experienced AS (as drawn by Patient 4). The patient divided his experience in two periods (A,B). In the initial period, he experienced being elevated in his living room chair into the air by ~3 m in the direction of the arrow (A). In the second period, he experienced a 'second' body, which continued to be elevated, but left the patient's body from the elevated position in the chair (see text). (C) depicts the visual scene as Patient 4 experienced seeing it from his elevated position in the chair. Numbers indicate the dimensions of the patient's living room in metres. The position of the patient's wife is indicated by (A) and the successive locations of Patient 3 during the he-autoscopic period by (B), (C) and (D).

which of these two positions she thinks herself to be, she answered that "I am at both positions at the same time", without having the feeling of being out of her body.

Patient 3

Patient 3 suffered from complex partial seizures that started with an epigastric aura followed by the sensation of globally diminished hearing. Patient 3 never experienced OBE/AS during or outside her seizures. Rarely she had the dreamlike impression of flying and lightness and the distinct feeling that somebody was behind her back (more frequently on the right side) although, upon turning round, there was nobody there. Pharmacoresistant epilepsy was diagnosed and she was addressed for presurgical epilepsy evaluation. Based on these examinations, right temporal lobe epilepsy was diagnosed. However, as MRI did not reveal any lesion, invasive monitoring was indicated and confined the seizure focus to the right amygdala and the immediately surrounding cortex (Fig. 2C).

OBE. The phenomenology and clinical findings related to OBEs of Patient 3 have been briefly described previously (Blanke *et al.*, 2002). OBEs were induced repeatedly by electrical stimulation during invasive presurgical epilepsy evaluation. At the same electrode site, vestibular sensations and visual body part illusions were induced (supplementary material). Figure 2C depicts the electrode sites (turquoise dots) at the parieto-temporal junction where OBEs and other responses were obtained.

An OBE was induced three times at 3.5 mA. Immediately after the first stimulation, Patient 3 reported: "I see myself lying in bed, from above, but I only see my legs". She said that she 'saw' only her legs and lower trunk. The remaining parts of the room including the table next to the bed and the window, as well as three other people present were also seen from the above visual perspective. An essential part of the experience was the feeling of being separated from her seen body. She said: "I am at the ceiling" and "I am looking down at my legs". Two further stimulations induced an identical experience. She felt an instantaneous sensation of 'floating' near the ceiling and localized herself ~2 m above the bed. During these trials, Patient 3 was very intrigued and surprised by the induced responses.

Patient 4

Patient 4 was known for arterial hypertension, smoking and moderate recurrent migraine headaches. He had been hospitalized for venous thrombosis (left central retinal vein leading to severely diminished visual acuity that partially recovered) and acutely diminished visual acuity of the right eye (complete recovery). Despite numerous clinical investigations, the aetiology of the venous thrombosis of the left eye and the diminished visual acuity of the right eye could not be determined. During the hospitalization, Patient 4 was referred to the neurology clinic for loss of consciousness, severe headache and left-sided weakness associated with AS. The neurological examination revealed a left-sided arm and leg weakness that recovered within 48 h. Further examinations were normal. No precise diagnosis could be given (migraine, transitory ischaemic attack, epilepsy).

AS. Patient 4 was sitting when he suddenly heard his wife saying quite loudly: "Are you alright?". He had difficulty answering and felt slowly elevated with the chair into the air (to ~3 m high; Fig. 3A). He then experienced being "doubled" and saw "a second own body" that came "out of the elevated body" sitting in the chair (Fig. 3B). This 'second body' was seen from behind with all body parts in the sitting position (from his elevated physical visuo-spatial perspective). It continued to float and ascend without any body movements. This experience was associated with feelings of lightness and floating. In rapid alternation, he heard and saw his wife from above (Fig 3C) and from immediately in front of him (as if still sitting in his chair on the ground). The experience was described as a moment of elation and great happiness.

Patient 5

Patient 5 was known for familial hemiplegic migraine. Migraine headaches were present since puberty. Associated neurological symptoms (recurrent right-sided digital paresthesias, followed by propagation to the entire arm, the right half of the face, and finally the patient's back) were noticed since he was 19 years old. These symptoms were followed by speech difficulties and simple visual hallucinations, and diminished within 2–3 h, followed by severe

Table 2 General and visual phenomenology of OBE and AS

Patient	Visuo-spatial perspective		Colour	Visual clarity	Veridicality	Integration of actual facts	Presence of other seen objects/subjects
	Number	Position					
1 (OBE)	1	Para	+	High	+	–	+
2a (OBE)	1	Para	+	High	+	+	+
2b (AS)	2	Para/Phy	–	Medium	+	+	+
3 (OBE)	1	Para	+	High	+	+	+
4 (AS)	2	Para/Phy	+	High	+	+	+
5 (AS)	2	Para/Phy	+	High	+	+	+
6 (AS)	1	Phy	–	High	–	(+)	(+)

The number and position of the visuo-spatial perspective (para = parasomatic; phy = physical), the presence of coloured vision (+ = yes; – = no), the visual clarity (high, medium, low) and veridicality of the experience are given (+ = yes; – = no). In addition, the integration of actual facts into the experience (+ = yes; – = no) and the presence of other seen objects/persons than the patient's own body (+ = yes; – = no) are given.

left-sided headaches. Several neurological examinations during the period of migraine headache found right-sided sensori-motor loss, right-sided homonymous hemianopia, as well as aphasia and apraxia. During the present hospitalization, Patient 5 was referred to us for severe spatial-temporal disorientation, speech difficulties and right-sided weakness with fever (38.5°C). The neurological examination showed moderate right-sided sensori-motor loss, right-sided homonymous hemianopia, and severe global aphasia and apraxia. For further clinical details, see the supplementary material. On the 10th day, Patient 5 presented a complex partial seizure that was characterized by AS, secondary tonico-clonic generalization and urinal loss. EEG and MRI investigations suggested two independent seizure foci: the left fronto-temporal-insular cortex and the left temporo-parieto-occipital cortex (Fig. 3D). During the next 3 months, Patient 5 almost completely recovered from his severe neuropsychological deficits. He did not re-experience OBE/AS, but the frequent paroxysmal experience of feeling a 'shadow' of a person on the right. Under anti-epileptic medication, no further complex partial seizures were noted.

AS. Patient 5 was sitting at a table in a room of the hospital while a nurse was re-adjusting a venous catheter on his right arm. Suddenly, he felt intense fear and was convinced that the "nurse wants to intoxicate me". This was associated with the experience of slow backward rotation into a horizontal position. There, he suddenly saw himself standing behind the nurse. He stated that: "He looked like myself, but ten years younger and was dressed differently than I was at that moment". Patient 5 saw only the upper part of himself, including the trunk, head, shoulders, arms and hands. Then he had the impression of being examined by a physician. This was interrupted by the intervention of his second body, who was seen to start a fight with the physician and nurses. Patient 5 had the impression of seeing the scene either from his rotated position ("look[ing] at the ceiling") or from his initial sitting position in the chair prior to the seizure. These different perspectives changed a few times during the episode. During this episode, Patient 5 felt extremely tense; he was shaking and making fists so strongly that his fingers were perforating his palms.

Patient 6

Patient 6 suffered from complex partial seizures that were characterized initially by AS or by simple visual hallucinations. Pharmacoresistant epilepsy was diagnosed. Presurgical epilepsy

evaluation suggested seizure onset in the left posterior and anterior temporal region (Fig. 2E).

AS. In isolation or in association with her habitual complex partial seizures, Patient 6 would suddenly have the impression of seeing an "image of herself in front of her eyes". She saw only the upper part of the figure including the face and upper torso. She had the feeling that she was "looking into a mirror or at a picture of myself". She described the image of herself as flat and two-dimensional. Her face was motionless and expressionless with eyes open and mouth closed. The image was localized centrally and ~1 m from the patient's physical body. She could not detail much of the remaining visual scene, as the area surrounding her seen upper body was dark. AS was mainly experienced when she was sitting, but also occurred rarely in lying and standing positions.

Results

Visual phenomenology

Visual characteristics will be described separately for OBE and AS, and are summarized for all patients in Tables 2 and 3. Since the seizure semiology in Patient 2 changed following partial resection of her epileptic focus, pre-operative manifestations (OBE) are described as Patient 2a and post-operative manifestations (AS) as Patient 2b (Tables 2 and 3).

All OBEs were described from one visuo-spatial perspective, which was localized by all patients (1, 2a and 3) in a second (parasomatic) body outside the physical body. This parasomatic visuo-spatial perspective was experienced as immediately elevated in all patients and described as inverted by 180° with respect to the extrapersonal visual space and their habitual physical body position. In two OBE-patients, the parasomatic visuo-spatial perspective and body were ~2–3 m above their actual physical position (Patients 2a and 3), whereas it was variable and also included greater distances in Patient 1. No OBE-patient described more than one simultaneous visuo-spatial perspective. During AS, the patients described either one (Patient 6) or two visuo-spatial perspectives. Whereas, Patient 6 experienced AS from her habitual physical visuo-spatial perspective, Patients 2b, 4 and 5 experienced 'seeing' from two different visuo-spatial

Table 3 Own body phenomenology of OBE and AS

Patient	Entire/ partial body	Extremities	Trunk	Seen position	Initial position	Front view/back view	Vestibular
1 (OBE)	E	+	+	L	L/ST/SI	F	Elevation, flying, lightness, vertigo
2a (OBE)	E	+	+	L	L	F	Flying, lightness
2b (AS)*	p	-	+	SI	L/SI	B	Falling to the right
3 (OBE)	p	-	+	L	L	F	Elevation, flying, lightness, heaviness, sinking, falling
4 (AS)	E	+	+	SI	SI	B	Elevation, flying, lightness
5 (AS)	p	-	+	ST	SI	F	Rotation from sitting to lying position
6 (AS)	p	-	+	ST/SI	L/ST/SI	F	-

Whether the patients had the impression that they saw their body entirely or incompletely (E = entire body; p = partial body) and their extremities and their trunk (+ = yes; - = no) is indicated. The position in which the patients saw their body (ST = standing; SI = sitting; L = lying down) and the position they were in prior to the autoscopic phenomenon (ST = standing; SI = sitting; L = lying down) is marked. Patient 1 could not indicate in which body position she was in prior to her seizures (with OBE). Patient 6 had seizures with AS only when she was sitting or standing. Patient 2b saw herself during her seizure with AS initially as lying on her stomach and then as getting up into a kneeling position (*; see text for further detail). Whether the patients saw themselves front-view (F) or back-view (B), and which vestibular sensations were associated with the autoscopic phenomenon, is also indicated. Because the phenomenology of the autoscopic phenomenon changed in Patient 2 from an OBE prior to the operation (Patient 2a) to AS postoperatively (Patient 2b), her phenomenology was analysed separately for both periods.

perspectives. They described one physical visuo-spatial perspective (as is classically reported in AS and Patient 6) and experienced a second visuo-spatial perspective that was also experienced as being from the physical body. Yet, the latter perspective did not coincide with the patient's position prior to AS and had characteristics of a parasomatic and physical visuo-spatial perspective. The latter visuo-spatial perspective was experienced either as elevated (Patient 4), as rotated (Patient 5), or as displaced as well as rotated (Patient 2b). Whereas Patient 2b experienced both visuo-spatial perspectives simultaneously, Patients 4 and 5 experienced an alternation between both visuo-spatial perspectives.

OBEs were described as vivid and veridical (Patients 1, 2a and 3), although Patient 2a also experienced her OBE as dreamlike. AS were also experienced as vivid and veridical (Patients 4, 5 and 2b; again described as dreamlike by Patient 2b). Only Patient 6 experienced AS as a non-realistic visual pseudo-hallucination. The visual clarity of the experience was judged by all patients as high, as in everyday life and both AP were mostly experienced in colour (Patients 1, 2a, 3, 4 and 5; Table 2). In all OBE- and AS-patients, the patient's own body was seen among other objects or subjects. In all patients (except Patient 1), details from the actual visual scene were integrated into OBE/AS. These details included the general location (hospital or at home), objects in physical contact with the experient's body (clothes, bed, chair), objects and people within the room (nurse, doctor, table).

In all patients, self-recognition was immediate even if their face was not seen (Patient 3) or their body was seen from behind (Patients 2a and 4). Two OBE-patients saw their entire body [Patient 3 saw only the lower part of her body (legs, feet and lower trunk)]. Among the AS-patients, only one patient saw his body completely, yet perceived it as thinner, glowing

and without much detail (Patient 4). The three remaining AS-patients, only saw their upper body parts (always including head, upper trunk and shoulders; Table 3).

All OBE-patients saw their own body as lying on the ground or in bed, whereas all AS-patients saw their body in an upright position (standing or sitting). These 'seen' own body positions agree with the patient's physical body position prior to the AP. Thus, all three OBE-patients were in supine position prior to their OBE (Table 3). In Patients 2a and 3, this was observed by the authors directly. Patient 1 did not remember her body position prior to the OBEs and stated that seizures could occur in any body position. With respect to body position prior to AS, an initial sitting body position was found for most AS-patients (Table 3). In Patients 4 and 5, this was observed by the authors directly (Patient 5) or the wife of Patient 4. In Patient 6, AS was recalled by the patient as being preceded by a either a sitting or standing position. She stated that AS never occurred while she was in a supine position and that a sitting position was more frequent than a standing position. Patient 2b described that, prior and during AS, she was in a supine position from which she was getting up on her knees. To summarize, all OBE-patients were in supine position and most AS-patients in an upright position (sitting or standing) prior to the AP.

Simple visual manifestations occurred in OBE- and AS-patients. They were characterized by a contralesional flash of light (Patient 5), black dots in the superior visual fields (Patient 6), bilateral blurred vision and object transformations (Patient 1).

Non-visual phenomenology

Although all patients described OBE/AS in visual terms, associated sensations were most often vestibular. Two

patients reported auditory manifestations and three patients reported visual body part illusions.

All OBE-patients experienced vestibular sensations characterized by feelings of flying or floating (Table 3). Vertigo was rare and reported only by Patient 1. Patient 3 also experienced sensations of heaviness and falling. Patients 2a and 3 felt immediately elevated and floating in the parasomatic position, whereas Patient 1 experienced different levels of elevation. There were no reports of actually experienced rotations into the 180° inverted OBE position (along the vertical axis) or rotational sensations along the other bodily axes (binaural axis or axis of sight; Brandt, 1999). Thus, the 180° inversion of the elevated parasomatic body and the elevated visuo-spatial perspective with respect to the extrapersonal space and the physical body was always experienced as immediate.

Concerning AS, three of four patients experienced vestibular sensations. Yet, these sensations were more variable. Patient 4 reported a feeling of slow progressive elevation, as well as floating and lightness without the sensation of rotation or 180° inversion with respect to extrapersonal space (as reported by patients with OBE). Patient 5 experienced a slow progressive backward rotation from a vertical position (sitting in a chair) to a horizontal position (lying). Patient 2b reported the immediate feeling of being in the upright standing position (from a horizontal kneeling position on her bed). On other occasions, she experienced the sensation of loss of balance and falling to the right. Whereas in OBE-patients the vestibular sensations were always experienced during the OBE, they were reported prior to (Patient 5), during (Patients 2b and 4), or independently of AS (Patient 2b; sensation of falling), or not reported at all (Patient 6).

Visual body part illusions occurred in OBE and AS patients, and were characterized by illusory flexion of the contralateral upper extremity (Patient 3) or both lower extremities (Patients 2a and 3) or by the illusory transformation of one or two extremities (limb shortening in Patient 3; perforation of his hands by his fingers in Patient 5). These visual body part illusions were perceived as highly veridical although some of these illusions included impossible body part transformations such as in Patients 3 and 5.

OBE/AS were associated with various emotions. Whereas fear was reported most often (Patients 1, 2a, 2b and 5), feelings of joy and elation were reported by Patient 4. For Patients 3 and 6 the experience was neutral, yet intriguing and surprising.

Aetiology

OBE/AS were found to be related to focal epilepsy in Patients 1, 2 and 6. In these cases of epilepsy, the patients suffered from very frequent complex partial seizures (20–70 per week) with rare secondary generalizations (0–1 per year). In two of these patients, epilepsy was due to a dysembryoblastic neuroepithelial tumor. Although Patient 5 suffered

from severe familial hemiplegic migraine, the clinical symptomatology and the clinical evolution under antiepileptic treatment—as well as EEG and MRI data during his hospitalization—are all evidence in favour of an epileptic origin of his AS. The complex partial seizure might thus be considered a complication of the patient's familial hemiplegic migraine due to circumscribed cortical changes as shown by MRI. Patient 4's history of acute repetitive visual loss and frequent migraine headaches suggests that his AS was probably related to a transitory ischaemic attack related to migraine. In Patient 3, the OBE was induced artificially by electrical stimulation of cortex distant from the primary epileptic focus. To summarize, OBE/AS were due to complex partial seizures in four patients, to electrical cortical stimulation in one patient, and to a probable transitory ischaemic attack due to migraine in one patient.

Impairment of consciousness

In five patients, OBE/AS occurred during a mental state that was characterized by a partial impairment of consciousness. This impairment was related to complex partial seizures in four patients (1, 2, 5 and 6) and of unknown origin in Patient 4. Interestingly, the impairment of consciousness was only partial and very short as determined by the ictal and post-ictal clinical examination. The clinical evolution in these patients was characterized by the quick recovery of full consciousness and the absence of secondary generalizations. Patient 3 (OBE by electrical stimulation) showed no impairment of consciousness during or after stimulation.

Neuropsychology

In three patients (2, 5 and 6), the neuropsychological examination detected moderate to severe specific signs of aphasia, agraphia, alexia and apraxia. Moderate to severe spatial or visual agnosia was found in two patients (1 and 3). Thus, five of the six patients suffered from signs of lateral posterior cortex involvement (Jones-Gotman *et al.*, 1993). In Patient 4, the neuropsychological examination was normal, but no post-ictal examination could be carried out. Executive functions were normal in all patients (except Patient 1 who had a mild deficit). Verbal and visuo-spatial memory impairments, which are the classical neuropsychological finding in temporal lobe epilepsy (Jones-Gotman *et al.*, 1993; Pegna *et al.*, 1998), were mostly mild deficits and observed in three patients (1, 3 and 6). In conclusion, these findings show a predominance of specific language and visuo-spatial deficits (83%) compared with memory deficits (50%) and executive deficits (17%), and suggest involvement of the lateral posterior cortex of either hemisphere.

Anatomy

Lesion analysis shows that both hemispheres are involved in OBE (two right hemisphere, one left hemisphere) and AS

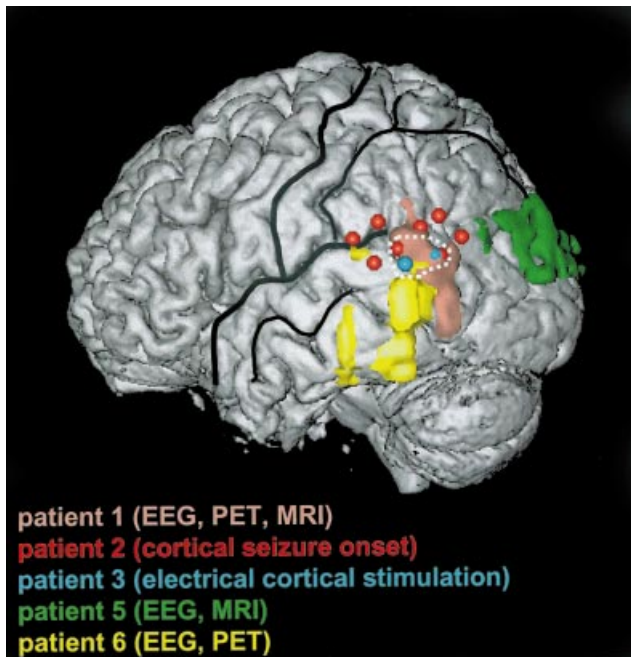


Fig. 4 Mean lesion overlap analysis of the five patients in whom a lesion could be defined (Patients 1, 2, 3, 5 and 6). Each patient is indicated in the same colour as in Fig. 2. The results of the individual lesion analysis of each patient were transposed onto the left hemisphere of Patient 5 (see Methods). Mean overlap analysis centred on the TPJ (area indicated by dashed white line). Thick black lines indicate Sylvian fissure and central sulcus; thin lines indicate superior temporal sulcus, postcentral sulcus and intraparietal sulcus.

(one right hemisphere, three left hemisphere; Table 1). With respect to gyral anatomy, individual overlap analysis found the angular gyrus to be involved in all five patients in whom lesion analysis could be performed (Fig. 2A–E). Involvement of the middle and superior temporal gyri, as well as the lateral occipital gyrus, was found in two patients. For mean lesion overlap analysis, we plotted the lesion of each patient onto the left hemisphere of Patient 5 (Fig. 4). Mean lesion overlap (four of the five patients) centred on the temporo-parietal junction (TPJ), including the anterior part of the angular gyrus and the posterior part of the superior temporal gyrus (Fig. 4).

Discussion

Phenomenology

Like most previous authors, we defined and distinguished OBE from AS by the spatial location of the visuo-spatial perspective of the experient (Menninger-Lerchenthal, 1935; Lhermitte, 1939; Green, 1968; Blackmore, 1982; Rogo, 1982; Irwin, 1985; Devinsky *et al.*, 1989; Denning and Berios, 1994); during an OBE, the experient appears to ‘see’ the world and his body from one parasomatic visuo-spatial

perspective, whereas the experient during an AS remains within the boundaries of his physical body and appears to have one physical visuo-spatial perspective. Whereas all present OBE-patients conform to that definition, three of the present AS-patients indicated that they experienced to ‘see’ from two visuo-spatial perspectives—the habitual physical visuo-spatial perspective and an additional parasomatic visuo-spatial perspective (Patients 2a, 4 and 5). None of these patients felt ‘out of their body’, but also experienced ‘seeing’ the world from a parasomatic visuo-spatial perspective. It might be relevant that this parasomatic visuo-spatial perspective was experienced in rapid alternation with the habitual physical visuo-spatial perspective. A similar case has been described by Brugger *et al.* (1994) and called he-autoscopy. This extended the work of earlier authors (Menninger-Lerchenthal, 1935; Hécaen and Ajuriaguerra, 1952), who distinguished he-autoscopy from the simpler, more visual, and less realistic, AS which is characterized by one stable physical visuo-spatial perspective (see Patient 6). Brugger (2002) included this distinction between AS and he-autoscopy in a recent classification system of AP and proposed that he-autoscopy represents phenomenologically and functionally an intermediate state between AS and OBE. Accordingly, we will consider separately the three AP: (i) AS; (ii) he-autoscopy; and (iii) OBE.

Some authors have argued that only OBEs are judged as veridical, whereas AS and he-autoscopy are experienced as mere visual pseudo-hallucinations (Rogo, 1982; Blackmore, 1984; Irwin, 1985). Our data show that he-autoscopy is also experienced as veridical. Indeed, the seen parasomatic body may be so realistic that patients with he-autoscopy (and rarely also AS) may jostle their parasomatic body while walking together (Sivadon, 1937), draw a chair for the parasomatic body to sit down on (Dewhurst and Pearson, 1955) and ask their parasomatic body for help (Patient 5). In addition, OBE and he-autoscopy are both experienced as taking place in real and familiar surroundings [Menninger-Lerchenthal, 1935; Lhermitte, 1939; Hécaen and Ajuriaguerra, 1952; Lukianowicz, 1959 (cases A and F)]. These data suggest that OBE and he-autoscopy are mostly experienced as veridical, whereas AS is mostly experienced as unreal (Patient 6; Brugger, 2002).

The present patients show that the impression of reality and self-recognition is preserved even if visual details of the seen body differ from the patient’s actual appearance such as clothes and age in Patient 5, hair cut in Patient 2b or the size and colouring of his body in Patient 4. Similar observations have been reported previously for AP in patients [Sollier, 1903; Lhermitte, 1939; Lukianowicz, 1957 (case B); McConnel, 1965; Kölmel, 1985 (case 6); Devinsky *et al.*, 1989 (case 4)] and healthy subjects (Larsen, 1927; Crookall, 1964; Green, 1968; Irwin, 1985). In some of our patients, self recognition was immediate even if the patient saw his back during the autoscopic phenomenon (Patients 2b and 4). These findings suggest that self-recognition in AP may be relatively independent of the visual features of one’s body (Sollier,

1903; Menninger-Lerchenthal, 1935; Lhermitte, 1939; Brugger *et al.*, 1997) and points to the importance of non-visual, body-related, perceptual mechanisms. The importance of these non-visual, body-related, perceptual mechanisms is further suggested by the association of vestibular sensations, visual body-part illusions, the partialness of the seen body and the differential effects of the initial body position on AP.

The association of vestibular sensations with OBE/AS has been described previously in case collections and surveys in healthy subjects (Muldoon and Carrington, 1929; Crookall, 1964; Green, 1968; Yram, 1972; Blackmore, 1982; Irwin, 1985) as well as in neurological patients (Bonnier, 1893; Skworzoff, 1931; Menninger-Lerchenthal, 1935, 1946; Hécaen and Ajuriaguerra, 1952; Devinsky *et al.*, 1989; Grüsser and Landis, 1991). Whereas most latter authors observed the frequent association of vestibular sensations and OBE or AS, others proposed that a paroxysmal vestibular dysfunction might be an important mechanism for the generation of AP (Bonnier, 1893; Skworzoff, 1931; Menninger-Lerchenthal, 1935, 1946; Grüsser and Landis, 1991). Menninger-Lerchenthal (1935) extended this view and pointed to the important role of vestibular disorders in the generation of visual illusions and dysfunctions. In the present study, the importance of vestibular mechanisms in AP is underlined by their presence in five of the six patients and by the fact that vestibular sensations were evoked in Patient 3 at the same site where higher currents induced an OBE associated with sensations of floating and elevation (see also Penfield, 1955). If we assume that both electrically induced responses in Patient 3 (vestibular sensations, OBE) result from interference with neurons under the stimulating electrode, this finding suggests that OBE and vestibular sensations are caused by functionally and anatomically related neuronal populations (Nathan *et al.*, 1993; Blanke *et al.*, 2000c). Importantly, the core region of the vestibular cortex (monkey: Guldin and Grüsser, 1998; human: Lobel *et al.*, 1998; Brandt and Dieterich, 1999; Fasold *et al.*, 2002) is situated at the TPJ and/or the posterior insula. As the TPJ was found in all present patients (in whom brain damage could be detected) to be implicated in AP, this localization improves previous results that have suggested the temporal, parietal and occipital cortex (Todd and Dewhurst, 1955; Lunn, 1970; Devinsky *et al.*, 1989; Grüsser and Landis, 1991; Brugger *et al.*, 1997) and agrees with earlier anatomical suggestions (Menninger-Lerchenthal, 1935; Hécaen and Ajuriaguerra, 1952). The TPJ is also implicated in visuo-spatial neglect (Halligan *et al.*, 2003)—a clinical condition which has been shown to disturb the patient's egocentric spatial relationship with extrapersonal space or visuo-spatial perspective (Karnath, 1994; Farrell and Robertson, 2000; Vogeley and Fink, 2003). In addition, the TPJ is activated during egocentric perspective changes in healthy subjects (Maguire *et al.*, 1998; Vallar *et al.*, 1999). These previous findings underline the importance of the TPJ in normal and pathological visuo-spatial perspective taking and concur with the present anatomical results in OBE/AS. The present study

shows that different pathological vestibular sensations are associated with OBE and AS/he-autoscopia, respectively. Our data suggest that OBEs are associated with graviceptive, otholithic, vestibular sensations: feelings of elevation and floating, 180° inversion of parasomatic body and visuo-spatial perspective with respect to extrapersonal space. This favours a graviceptive vestibular dysfunction in OBEs that has been described as a consequence of brain lesions or epileptic discharge in neurological patients (Smith, 1960; Brandt *et al.*, 1994; Brandt, 1999) and as a physiological response to microgravity conditions (inversion illusion during space missions or the low gravity phase of parabolic flights; Lackner, 1992; Mittelstaedt and Glasauer, 1993). The 180° inversion of the parasomatic body with respect to the extrapersonal space in OBEs is reminiscent of otholithic vestibular sensations of cortical or subcortical origin: the room tilt illusion (Solms *et al.*, 1988; Tiliket *et al.*, 1996; Malis and Guyot, 2003). Whereas, during the room tilt illusion, it is not the body and visuo-spatial perspective of the observer which seems inverted by 180° within a stable extrapersonal visual space (as in OBEs or inversion illusions), it is the extrapersonal visual space which seems inverted by 180° with respect to a stable observer during the room tilt illusion. Interestingly, responses to microgravity may be experienced as room tilt or inversion illusion (Lackner, 1992; Mittelstaedt and Glasauer, 1993). Finally, room tilt illusion, inversion illusion and OBE share characteristics that suggest their related origin: they are paroxysmal, can be aborted by bodily action and eye closure, and are mostly characterized by exact 180° inversion between the extrapersonal space and the observer. Vestibular sensations in patients with he-autoscopia were less prominent and more variable, but present in all three patients. They were characterized by sensations of progressive elevation, rotation or falling. In addition, they were associated loosely with he-autoscopia occurring prior, during, or independently of the autoscopic period, thus differing from vestibular sensations in patients with OBEs. Our patient with AS did not report any pathological vestibular sensations. In conclusion, these data provide evidence for an important role of vestibular cortex in the induction of OBE and he-autoscopia. Whereas, our data suggest that OBEs are related to a cortical otholithic dysfunction, they do not provide further details about the vestibular dysfunction in he-autoscopia, and suggest that a vestibular dysfunction may even be absent in AS. Since vestibular dysfunctions and illusions due to acquired cortical brain damage are generally present without AP (Smith, 1960; Solms *et al.*, 1988; Brandt *et al.*, 1994), a vestibular dysfunction might be a necessary, but not a sufficient condition to induce AP.

In addition to a vestibular dysfunction, the present data suggest that AP might also relate to a failure to integrate proprioceptive, tactile and visual body-related information (disintegration in multisensory personal space) in a coherent central representation of one's body (body schema). This is suggested by the following five findings. First, many of the present patients experienced paroxysmal visual body-part

illusions. The association of visual body-part illusions with AP has been described previously [Ehrenwald, 1931; Menninger-Lerchenthal, 1935, 1946; Lhermitte, 1939; Hécaen and Ajuriaguerra, 1952; Lunn, 1970 (cases 1 and 2); Ioanasescu, 1969 (case 8); Devinsky *et al.*, 1989 (case 10)] and has led several authors to argue for a similar or closely related functional and anatomical origin (Menninger-Lerchenthal, 1935; Hécaen and Ajuriaguerra, 1952; Ioanasescu, 1960; Brugger *et al.*, 1997). Our data show that three of the six patients experienced illusory body-part sensations. As for vestibular sensations, the presence of body part illusions is not a necessary condition for OBE and AS since they most frequently occur without AP (Hécaen and Ajuriaguerra, 1952; Hécaen, 1973). The second phenomenological link between AP and a body schema dysfunction is suggested by the fact that the patients' own body, which is seen during the autoscopic phenomenon, was often restricted either to the patients' upper or lower body. Although most healthy and neurological AP-experiencers describe their seen body as complete, a review of the literature reveals that partialness of the seen own body during the AP is not uncommon [neurology/psychiatry: Menninger-Lerchenthal, 1935; Genner, 1947; Hécaen and Ajuriaguerra, 1952 (case 84); Conrad, 1953; Lukianowicz, 1957 (case A); Devinsky *et al.*, 1989 (case 7); Bhaskaran *et al.*, 1990; Grüsser and Landis, 1991; Denning and Berrios, 1994; healthy subjects: Crookall, 1964 (case 183); Yram, 1972; Irwin, 1985 (case 13)]. Thirdly, the present data show that AP differ depending on the patient's position prior to the experience, suggesting an influence of proprioceptive and tactile mechanisms. Thus, during an OBE our patients were in a supine position as was found by Green (1968) in 75% of OBEs. Interestingly, most techniques that are used to induce OBE voluntarily propose that the subjects use a supine and relaxed position (Blackmore, 1982; Irwin, 1985). However, the patient's position prior to AS and he-autoscopy was either sitting or standing in our experience, confirming results by Denning and Berrios (1994), who reviewed a large number of patients with AS and he-autoscopy. Fourthly, the importance of body-related processing on AP is further underlined by our observation that the experient during an OBE 'sees' himself in supine position, whereas the experient during an AS 'sees' himself in a sitting or standing position, thus reflecting different body positions prior to or during the respective autoscopic phenomenon. Finally, visual body-part illusions generally occur in posterior parietal lobe dysfunction or in posterior temporal lobe dysfunction concordant with the proposed lesion location in the present patients with AP (Menninger-Lerchenthal, 1935; Hécaen and Ajuriaguerra, 1952; Ramachandran and Hirstein, 1998). In addition, several neuropsychological and neuroimaging studies suggest the implication of the TPJ and/or cortical areas along the intraparietal sulcus in combining tactile, proprioceptive and visual information in a coordinated reference frame (Calvert *et al.*, 2000; Bremner *et al.*, 2001; Ladavas, 2002).

Aetiology, impairment of consciousness and neuropsychology

Our findings suggest that AP are related to partially or minimally altered states of consciousness of short duration during partial seizures, focal electrical stimulation and a probable transitory ischaemic attack. Seizure history and prolonged video-EEG recordings in the epileptic Patients 1, 2 and 6 further revealed that all patients suffered from very frequent complex partial seizures. The ictal and post-ictal neurological and neuropsychological examination showed that loss of consciousness was brief, with partly preserved oral comprehension and task execution. In addition, seizures were almost never followed by secondary generalization. Based on the results from Patient 3, in whom an OBE of 2 s duration was induced by electrical stimulation, it might be suggested that AP may even occur without any impairment of consciousness. Even in Patients 4 and 5, for whom fewer neuropsychological data were available, partial persistence of consciousness (or cognitive abilities) is suggested by the fact that they included accurate facts in their accounts or were talking and responding to questions during the period of partially impaired consciousness. Finally, the interictal and post-ictal neuropsychological examinations revealed moderate to severe selective impairments concordant with a lateralized neocortical seizure focus (as shown by lesion analysis). Thus, specific signs of agraphia, alexia, paraphasia, as well as apraxia and visual agnosia, were observed while functions subserved by other cortical areas such as memory were preserved or only mildly impaired. The above mentioned ictal and post-ictal findings are distinct from patients with medial temporal lobe epilepsy in whom complex partial seizures are generally less frequent, of longer duration, more frequently associated with complete loss of consciousness and secondary generalizations, and with more severe memory impairments (Jones-Gotman *et al.*, 1993; Foldvary *et al.*, 1997; Kotogal, 1992; Wieser, 2000). The present neurological and neuropsychological data thus lend support to models that have linked AP to partially impaired or altered states of consciousness (Tart, 1974, 1975; Blackmore, 1982).

Theoretical considerations

The integration of proprioceptive, tactile and visual information with respect to one's body with vestibular information is important for the constant updating of the movement and position of single body parts and the entire body, as well as the body's position in extrapersonal space. Largely unconscious, these mechanisms ascertain that seen and felt body positions are synchronized and that inconsistent information is discarded. In order to create a central representation of one's own body (Melzack, 1990), the brain must integrate and weigh the evidence from these different sensory sources. This involves mechanisms for imposing coherence on information from different sensory sources and mechanisms for diminishing incoherences in order to avoid uncertainty. Thus, the

brain must create sensory central representations of the movement and position of the body and its position in extrapersonal space, even if this requires the temporary inhibition of discrepant inputs. Discrepant proprioceptive input might be discarded (and regarded as noise) if visual, tactile and vestibular input about the position and movement of one's own body concur. Yet, in some cases, discrepant input can be strong and persistent leading to two discrepant central representations of one's own body or body parts as induced experimentally (Goodwin *et al.*, 1972; Craske, 1977; Lackner, 1988).

We speculate that, during AP, the integration of proprioceptive, tactile, and visual information of one's body has failed due to discrepant central representations by the different sensory systems. This might then lead to the experience of seeing one's body or body parts in a position that does not coincide with the felt position of one's body, as proposed for the affected body part in supernumerary phantom limbs (Ramachandran and Hirstein, 1998; Brugger *et al.*, 2000). The fact that patients with supernumerary phantom limbs only experience their illusory limb on one side of their body, whereas the AP in our patients always concerned the trunk or the entire body suggests that a different dysfunction is present in our patients. This is also suggested by the fact that artificially induced disintegration in personal space (Goodwin *et al.*, 1972; Craske, 1977; Lackner, 1988) as well as visual body part illusions (Hécaen and Ajuriaguerra, 1952) are not always associated with AP. We thus speculate that an additional vestibular dysfunction is necessarily present in AP. As shown in Fig. 5, we speculate that the different forms of AP are related to different degrees of vestibular dysfunction.

The latter dysfunction is especially apparent for OBEs that were always associated with vestibular sensations. This suggests that disembodiment and elevated visuo-spatial perspective during OBEs might be related to disintegration between vestibular and extrapersonal sensory information as suggested for the inversion illusion and the room tilt illusion (Brandt, 1999). Yet, whereas inversion illusion and room tilt illusion are not associated with an additional disintegration in personal space (failure to integrate proprioceptive, tactile and visual information with respect to one's own body), OBEs are. We thus speculate that the disintegration in personal space in patients with an OBE leads to the illusory reduplication of one's own body and that the co-occurring disintegration between personal and extrapersonal space (vestibular dysfunction) leads to the intriguing experience of seeing one's own double from an elevated parasomatic position (Fig. 5, *right*). Whereas disintegration in personal space is also present in patients with AS, the vestibular dysfunction is much weaker or might even be absent (Fig. 5, *left*). He-autoscopy represents an intermediate state between AS and OBE, and is characterized by disintegration in personal space and varying or instable degrees of vestibular dysfunction leading to partially elevated and parasomatic

Phenomenology and pathophysiology of autoscopic phenomena

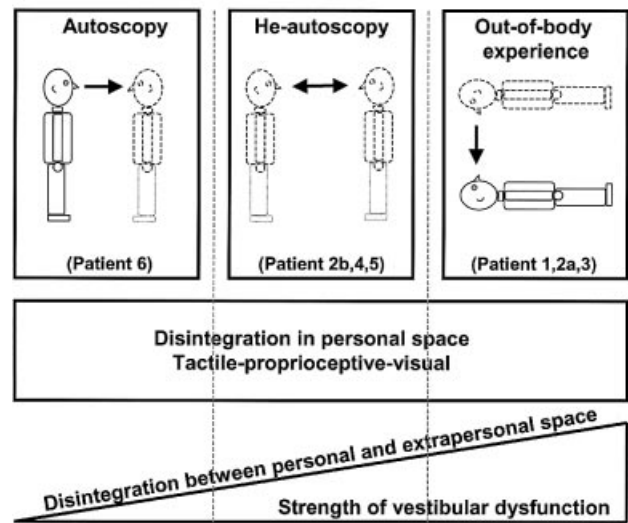


Fig. 5 The phenomenology of AS (*left*), he-autoscopy (*middle*) and OBE (*right*) are represented schematically in the upper part of the figure. The position and posture of the physical body for each autoscopic phenomenon is indicated by black lines and that of the parasomatic body in dashed lines. We found that AS and he-autoscopy occurred primarily in a sitting/standing position and OBE in a supine position. The fact that patients with AS and he-autoscopy frequently only see their upper bodies is also included (the absence of the lower body is indicated by a pointed lower contour of the body). The visuo-spatial perspective is indicated by the arrow pointing away from the location in space from which the patient had the impression he/she saw from AS: from the physical body; OBE: from the parasomatic body; He-autoscopy: alternating between physical and parasomatic body. The pathophysiology of AS, he-autoscopy and OBE are represented schematically in the middle and lower parts of the figure. The square in the middle of the figure indicates that all three autoscopic phenomena are characterized by a disintegration of tactile-proprioceptive-visual information in personal space. In the lower part of the figure, we indicate that the different forms of autoscopic phenomena are associated to different degrees with a vestibular dysfunction leading to disintegration between personal (vestibular) and extrapersonal (visual) space. Whereas, an OBE is characterized by a strong vestibular dysfunction, a vestibular dysfunction is weak or may be absent in AS. He-autoscopy represents, pathophysiologically, an intermediate state between OBE and AS.

visuo-spatial perspectives that alternate with the physical visuo-spatial perspective (Fig. 5, *middle*).

In conclusion, we propose a neuroscientific theory that accounts for the three main forms of AP: AS, he-autoscopy and OBE. We argue that these complex illusory reduplications of one's own body result from a double disintegration in: (i) personal space; and (ii) between personal and extrapersonal space at the TPJ. The unconscious creation of central representation(s) of one's own body based on

proprioceptive, tactile, visual and vestibular information, and their integration with central representations of extrapersonal space is a prerequisite for rapid and effective action in our surroundings. We speculate that significant ambiguous input from these different sensory systems and, especially the vestibular system, are important mechanisms in the intriguing experience of seeing one's body in a position that does not coincide with the felt position of one's body.

Acknowledgements

We wish to thank J.-G. Villemure for the implantation of the subdural grid electrodes and neurosurgical operations. We also wish to thank G. Lantz for his help with the analysis of the multichannel EEG recordings, C. Mohr for valuable discussions about the manuscript and J.-M. Annoni, F. Bernasconi, A. Coeytaux, S. Perrig, S. Ortigue, and C. Ribi for assistance with the patients. This work was supported by grants from the Leenaards Foundation and the Swiss National Science Foundation (3100-068105.02; 3100-067874.02; 3100-67105.01; 3100-65323.01; 3200-68105.02).

References

- Alvarado CS. The psychological approach to out-of-body experiences: a review of early and modern developments. *J Psychol* 1992; 126: 237–50.
- Bhaskaran R, Kumar A, Nayar PC. Autoscopia in hemianopic field. *J Neurol Neurosurg Psychiatry* 1990; 53: 1016–7.
- Blackmore SJ. Beyond the body. An investigation of out-of-body experiences. London: Heinemann; 1982.
- Blackmore SJ. Where am I? Perspectives in imagery and the out-of-body experience. *J Ment Imagery* 1987; 11: 53–66.
- Blanke O, Lantz G, Seeck M, Spinelli L, Grave de Peralta R, Thut G, et al. Determination of seizure onset in the frequency-domain. *Clin Neurophysiol* 2000a; 111: 763–72.
- Blanke O, Spinelli L, Thut G, Michel CM, Perrig S, Landis T, et al. Location of the human frontal eye field as defined by electrical cortical stimulation: anatomical, functional and electrophysiological characteristics. *Neuroreport* 2000b; 11: 1907–13.
- Blanke O, Perrig S, Thut G, Landis T, Seeck M. Simple and complex vestibular responses induced by electrical cortical stimulation of the parietal cortex in humans. *J Neurol Neurosurg Psychiatry* 2000c; 69: 553–6.
- Blanke O, Ortigue S, Landis T, Seeck M. Stimulating illusory own-body perceptions. *Nature* 2002; 419: 269–70.
- Blanke O, Landis T, Mermoud C, Spinelli L, Safran AB. Direction-selective motion blindness after unilateral posterior brain damage. *Eur J Neurosci* 2003; 18: 709–22.
- Bonnier P. Vertige. Paris: Masson; 1893.
- Böschenstein R. Doppelgänger. Phantastische Geschichten. München: Winkler Verlag; 1987.
- Brandt T. Central vestibular disorders. In: Brand T. Vertigo. Its multisensory syndromes. 2nd ed. London: Springer; 1999. p. 167–246.
- Brandt T, Dieterich M. The vestibular cortex. Its location, functions and disorders. *Ann NY Acad Sci* 1999; 871: 293–312.
- Brandt T, Dieterich M, Danek A. Vestibular cortex lesions affect the perception of verticality. *Ann Neurol* 1994; 35: 403–12.
- Bremner F, Schlack A, Duhamel JR, Graf W, Fink GR. Space coding in primate posterior parietal cortex. *Neuroimage* 2001; 14: S46–51.
- Brugger P. Reflective mirrors: perspective taking in autoscopic phenomena. *Cogn Neuropsychiatry* 2002; 7: 179–94.
- Brugger P, Agosti R, Regard M, Wieser HG, Landis T. Heautoscopy, epilepsy, and suicide. *J Neurol Neurosurg Psychiatry* 1994; 57: 838–9.
- Brugger P, Regard M, Landis T. Illusory reduplication of one's own body: phenomenology and classification of autoscopic phenomena. *Cogn Neuropsychiatry* 1997; 2: 19–38.
- Brugger P, Kollias SS, Muri RM, Crelier G, Hepp-Reymond MC, Regard M. Beyond re-membering: phantom sensations of congenitally absent limbs. *Proc Natl Acad Sci USA* 2000; 97: 6167–72.
- Bychowski G. Disorders of the body-image in the clinical pictures of psychoses. *J Nerv Ment Dis* 1943; 97: 310–35.
- Calvert GA, Campbell R, Brammer MJ. Evidence from functional magnetic resonance imaging of crossmodal binding in the human heteromodal cortex. *Curr Biol* 2000; 10: 649–57.
- Conrad K. über ein eigenartiges Spiegelphänom. Heautoskopisches Phänomen als Dauerzustand bei Hypophysentumor. *Nervenarzt* 1953; 24: 265–70.
- Cook AM, Irwin HJ. Visuo-spatial skills and the out-of-body experience. *J Parapsychol* 1983; 47: 23–35.
- Craske B. Perception of impossible limb positions induced by tendon vibration. *Science* 1977; 196: 71–3.
- Critchley M. The body image. In: Critchley M. The parietal lobes. New York: Hafner; 1969. p. 225–55.
- Crookall R. More astral projections. Analyses of case histories. London: Aquarian Press; 1964.
- Dening TR, Berrios GE. Autoscopic phenomena. *Br J Psychiatry* 1994; 165: 808–17.
- Devinsky O, Feldmann E, Burrowes K, Bromfield E. Autoscopic phenomena with seizures. *Arch Neurol* 1989; 46: 1080–8.
- Dewhurst K, Pearson J. Visual hallucinations of the self in organic disease. *J Neurol Neurosurg Psychiatry* 1955; 18: 53–7.
- Du Prel C. Der Doppelgänger. Sphinx (Monatsschrift der übersinnlichen Weltanschauung) 1886; 2: 86–96.
- Ehrenwald H. Anosognosie und Depersonalization. *Nervenarzt* 1931; 4: 681–8.
- Farrell MJ, Robertson IH. The automatic updating of egocentric spatial relationships and its impairment due to right posterior cortical lesions. *Neuropsychologia* 2000; 38: 585–95.
- Fasold O, von Brevern M, Kuhberg M, Ploner CJ, Villringer A, Lempert T, et al. Human vestibular cortex as identified with caloric stimulation in functional magnetic resonance imaging. *Neuroimage* 2002; 17: 1384–93.
- Féré C. Note sur les hallucinations autoscopiques ou spéculaires et sur les hallucinations altruistes. *C R Séanc Soc Biol* 1891; 3: 451–53.
- Foldvary N, Lee N, Thwaites G, Mascha E, Hammel J, Kim H, et al. Clinical and electrographic manifestations of lesional neocortical temporal lobe epilepsy. *Neurology* 1997; 49: 757–63.
- Frederiks JAM. Disorders of the body schema. In: Vinken PJ, Bruyn GW, editors. Handbook of neurology, Vol. 4. Amsterdam: North-Holland; 1969. p. 207–40.
- Genner T. Das Sehen des eigenen Spiegelbildes als epileptisches Äquivalent. *Wien klin Wschr* 1947; 59: 656–8.
- Goodwin GM, McCloskey DI, Matthews PBC. Proprioceptive illusions induced by muscle vibration: contribution by muscle spindles to perception? *Science* 1972; 175: 1382–4.
- Grave de Peralta Menendez R, Gonzalez Andino S, Lantz G, Michel CM, Landis T. Non-invasive localization of electromagnetic epileptic activity. I. Method descriptions and simulations. *Brain Topogr* 2001; 14: 131–7.
- Green CE. Out-of-body experiences. Oxford: Institute of Psychophysical Research; 1968.
- Grüsser O-J, Landis T. The splitting of 'I' and 'me': heautoscopy and related phenomena. In: Grüsser OJ, Landis T. Visual agnosias and other disturbances of visual perception and cognition. Amsterdam: MacMillan; 1991. p. 297–303.
- Guldin WO, Grüsser O-J. Is there a vestibular cortex? *Trends Neurosci* 1998; 21: 254–9.
- Halligan PW, Marshall JC, Wade DT. Three arms: a case study of supernumerary phantom limb after right hemisphere stroke. *J Neurol Neurosurg Psychiatry* 1993; 56: 159–66.

- Halligan PW, Fink GR, Marshall JC, Vallar G. Spatial cognition: evidence from visual neglect. *Trends Cogn Sci* 2003; 7: 125–33.
- Hécaen H. Les asomatognosies. In: Hécaen H. Introduction à la neuropsychologie. Paris: Librairie Larousse; 1973. p. 273–96.
- Hécaen H, Ajuriaguerra J. L'héautoscopie. In: Hécaen H, Ajuriaguerra J. Méconnaissances et hallucinations corporelles. Paris: Masson; 1952. p. 310–43.
- Ionasescu V. Paroxysmal disorders of the body image in temporal lobe epilepsy. *Acta Psychiatr Scand* 1960; 35: 171–81.
- Irwin HJ. Correspondence. *J Soc Psychol Res* 1981; 51: 118–20.
- Irwin HJ. Flight of mind: a psychological study of the out-of-body experience. Metuchen (NJ): Scarecrow Press; 1985.
- Irwin HJ. Perceptual perspective of visual imagery in OBEs, dreams and reminiscence. *J Soc Psych Res* 1986; 53: 210–17.
- Jones-Gotman M, Smith ML, Zatorre RJ. Neuropsychological testing for localizing and lateralizing the epileptogenic region. In: Engel J Jr, editor. Surgical treatment of the epilepsies. 2nd ed. New York: Raven Press; 1993. p. 245–61.
- Karnath HO. Subjective body orientation in neglect and the interactive contribution of neck muscle proprioception and vestibular stimulation. *Brain* 1994; 117: 1001–12.
- Kölmel HW. Complex visual hallucinations in the hemianopic field. *J Neurol Neurosurg Psychiatry* 1985; 48: 29–38.
- Kotogal P. Seizure symptomatology in temporal lobe epilepsy. In: Lüders HO, editor. Epilepsy surgery. New York: Raven Press; 1993. p. 143–56.
- Lackner JR. Some proprioceptive influences on the perceptual representation of body shape and orientation. *Brain* 1988; 111: 281–97.
- Lackner JR. Sense of body position in parabolic flight. *Ann NY Acad Sci* 1992; 656: 329–39.
- Ladavas E. Functional and dynamic properties of visual peripersonal space. *Trends Cogn Sci* 2002; 6: 17–22.
- Lantz G, Grave de Peralta Menendez R, Gonzalez Andino S, Michel CM. Noninvasive localization of electromagnetic epileptic activity. II. Demonstration of sublobar accuracy in patients with simultaneous surface and depth recordings. *Brain Topogr* 2001; 14: 139–47.
- Larsen CD. My travels in the spirit world. Rutland: Tuttle; 1927.
- Leischner A. Die autoskopischen Halluzinationen (Héautoscopie). *Fortschr Neurol Psychiatr* 1961; 29: 550–85.
- Lesser RP, Lüders H, Klem G, Dinner DS, Morris HH, Hahn JF, et al. Extraoperative cortical functional localization in patients with epilepsy. *J Clin Neurophysiol* 1987; 4: 27–53.
- Lhermitte J. Les phénomènes héautoscopiques, les hallucinations spéculaires et autoscopiques. In: Lhermitte J. L'image de notre corps. Paris: L'Harmattan; 1939. p. 170–227.
- Lhermitte J. Les phénomènes héautoscopiques, les hallucinations spéculaires. In: Lhermitte J. Les hallucinations. Clinique et physiopathologie. Paris: G. Doin; 1951. p. 124–68.
- Lippman CW. Hallucinations of physical duality in migraine. *J Nerv Ment Dis* 1953; 117: 345–50.
- Lobel E, Kleine JF, Bihan DL, Leroy-Willig A, Berthoz A. Functional MRI of galvanic vestibular stimulation. *J Neurophysiol* 1998; 80: 2699–709.
- Lunn V. Autoscopic phenomena. *Acta Psychiatr Scand* 1970; 46 Suppl 219: 118–25.
- Lukianowicz N. Autoscopic phenomena. *Arch Neurol Psychiatr* 1958; 80: 199–220.
- Maguire EA, Burgess N, Donnett JG, Frackowiak RS, Frith CD, O'Keefe J. Knowing where and getting there: a human navigation network. *Science* 1998; 280: 921–4.
- Malis DD, Guyot J-P. Room tilt illusion as a manifestation of peripheral vestibular disorders. *Ann Otol Rhinol Laryngol* 2003; 112: 600–5.
- McConnel WB. The phantom double in pregnancy. *Br J Psychiatry* 1965; 111: 67–9.
- McCulloch WH. A certain archway: autoscopia and its companions seen in Western writing. *Hist Psychiatry* 1992; 3: 59–78.
- Melzack R. Phantom limbs and the concept of a neuromatrix. *Trends Neurosci* 1990; 13: 88–92.
- Menninger-Lerchenthal E. Das Truggebilde der eigenen Gestalt. Berlin: Karger; 1935.
- Menninger-Lerchenthal E. Der eigene Doppelgänger. Bern: Huber; 1946.
- Menninger-Lerchenthal E. Heautoskopie. *Wien Med Wochenschr* 1961; 111: 745–56.
- Michel CM, Grave de Peralta R, Lantz G, Gonzalez Andino S, Spinelli L, Blanke O, et al. Spatiotemporal EEG analysis and distributed source estimation in presurgical epilepsy evaluation. *J Clin Neurophysiol* 1999; 16: 239–66.
- Mittelstaedt H, Glasauer S. Illusions of verticality in weightlessness. *Clin Investig* 1993; 71: 732–9.
- Muldoon SJ, Carrington H. The projection of the astral body. London: Rider; 1929.
- Nathan SS, Sinha SR, Gordon B, Lesser RP, Thakor NV. Determination of current density distributions generated by electrical stimulation of the human cerebral cortex. *Electroencephalogr Clin Neurophysiol* 1993; 86: 183–92.
- Naudascher MG. Trois cas d'hallucinations spéculaires. *Ann Médico-Psychol* 1910; 68: 284–96.
- Palmer J. The out-of-body experience: A psychological theory. *Parapsychol Rev* 1978; 9: 19–22.
- Palmer J. A community mail survey of psychic experiences. *J Am Soc Psychol Res* 1979; 73: 221–51.
- Pegna AJ, Qayoom Z, Gericke CA, Landis T, Seeck M. Comprehensive post-ictal neuropsychology improves focus localization in epilepsy. *Eur Neurol* 1998; 40: 207–11.
- Penfield W. The role of the temporal cortex in certain psychical phenomena. *J Ment Sci* 1955; 101: 451–65.
- Podoll K, Robinson D. Out-of-body experiences and related phenomena in migraine art. *Cephalalgia* 1999; 19: 886–96.
- Ramachandran VS, Hirstein W. The perception of phantom limbs. *Brain* 1998; 121: 1603–1630.
- Rank O. Der Doppelgänger. Eine psychoanalytische Studie. Leipzig: Internationaler Psychoanalytischer Verlag; 1925.
- Rogo DS. Leaving the body. A complete guide to astral projection. New York: Simon and Schuster; 1982.
- Sathian K, Greenspan AI, Wolf SL. Doing it with mirrors: a case study of a novel approach to neurorehabilitation. *Neurorehabil Neural Repair* 2000; 14: 73–6.
- Schilder P. Über Autoskopie, über die Lokalisation des Denkens und über die 'Ichverdoppelungen' der Hysterie. In: Schilder P. Selbstbewusstsein und Persönlichkeitsbewusstsein. Eine psychopathologische Studie. Berlin: Springer; 1914. p. 229–46.
- Schilder P. The image and appearance of the human body. London: Kegan Paul, Trench, Trubner; 1935.
- Sheils D. A cross-cultural study of beliefs in out-of-the-body experiences, waking and sleeping. *J Soc Psychol Res* 1978; 49: 697–741.
- Sivadon P. Phénomènes autoscopiques au cours de la grippe. *Ann Med Psychol* 1937; 95: 215–20.
- Skworzoff K. Doppelgänger-Halluzinationen bei Kranken mit Funktionsstörungen des Labyrinths. *Z ges Neurol Psychiatr* 1931; 133: 762–66.
- Smith BH. Vestibular disturbances in epilepsy. *Neurology* 1960; 10: 465–9.
- Sollier PA. Les phénomènes d'autoscopie. Paris: Félix Alcan; 1903.
- Solms M, Kaplan-Solms K, Saling M, Miller P. Inverted vision after frontal lobe disease. *Cortex* 1988; 24: 499–509.
- Spinelli L, Blanke O, Perrig S, Lantz G, Thut G, Ducommun C, et al. Comprehensive pre-surgical exploration for epilepsy using multimodal imagery and invasive recordings: a case report. *Neuroimage* 2001; 13: S841.
- Tart CT. Out-of-body experiences. In: White J, editor. Psychic exploration: a challenge for science. New York: Putnam; 1974. p. 349–73.
- Tart CT. States of consciousness. New York: Dutton; 1975.
- Tiliket C, Ventre-Dominey J, Vighetto A, Grochowicki M. Room tilt illusion. A central otolith dysfunction. *Arch Neurol* 1996; 53: 1259–64.
- Todd J, Dewhurst K. The double: its psycho-pathology and psychophysiology. *J Nerv Ment Dis* 1955; 122: 47–55.

- Tong F. Out-of-body experiences: from Penfield to present. *Trends Cogn Sci* 2003; 7: 104–6.
- Vallar G, Lobel E, Galati G, Berthoz A, Pizzamiglio L, Le Bihan D. A fronto-parietal system for computing the egocentric spatial frame of reference in humans. *Exp Brain Res* 1999; 124: 281–6.
- Vogeley K, Fink GR. Neural correlates of the first-person-perspective. *Trends Cogn Sci* 2003; 7: 38–42.
- Wieser HG. Semiology of neocortical temporal lobe epilepsy. *Adv Neurol* 2000; 84: 201–214.
- Yram P. *Practical astral projection*. New York: Samuel Weiser; 1972.