

Successful bcr-abl targeting with imatinib in uterine sarcoma

Uterine sarcomas are a heterogeneous group of neoplasms with a propensity for metastasis and resistance to conventional therapy and represent 8% of all uterine malignancies. They consist of pure stromal tumors, the endometrial stromal sarcomas (ESSs) and leiomyosarcomas, mixed epithelial and mesenchymal tumors and carcinosarcomas [1]. The poor prognosis of uterine sarcomas is due, in part, to the limited success of treatments meant to enhance local and distant disease control after surgical resection. Response to chemotherapy in these cases is limited, and while radiotherapy may decrease local disease recurrence, its use has not affected overall survival [2]. The aggressive nature of uterine sarcomas and the failure of conventional therapy highlight the need for new treatment strategies, which in turn result in selective inhibition of tumor cell growth and the initiation of apoptosis [3]. Here, we describe a patient with relapsed ESS who, in the lack of other applicable therapies, was explored for KIT and platelet-derived growth factor receptor (PDGFR)- α/β expression and who responded significantly to treatment with imatinib mesylate.

This 75-year-old woman was admitted in October 2008 to our hospital for vaginal bleeding and discharge as well as discomfort in the lower pelvis. Eight years earlier, the patient had undergone vaginal hysterectomy because of low-grade ESS. In 2004, a tumor mass in the right ovary was resected and a singular metastasis of the previously diagnosed ESS found. This time postoperative local transcutaneous radiotherapy was carried out (32 Gy).

At admission in 2008, a moderate microcytic anemia (hemoglobin level 11.4 g/dl) with low ferritin level 11 $\mu\text{g/l}$ (10–200 $\mu\text{g/l}$) was noted. Leukocyte and thrombocyte counts as well as liver tests and renal function were within normal range. A computed tomography (CT) scan revealed recurrence of a mass measuring $14 \times 9 \text{ cm}^2$ in the lower pelvis with suspected infiltration of the urinary bladder (Figure 1). A biopsy was taken. Histological work-up confirmed relapse of the low-grade ESS according to the World Health Organization criteria.

searched for treatment options and carried out immunohistologic staining for tyrosine kinase receptors KIT, PDGFR- α and - β as described before [4].

Both PDGFR- β and PDGFR- α were strongly expressed in the tissue specimen, whereas KIT stained negative (figure not shown). We have determined these receptors as a number of tyrosine kinase inhibitors, such as imatinib, are in widespread clinical use. Imatinib is an inhibitor of bcr-abl, KIT and PDGFR and has revolutionized the treatment of chronic myelogenous leukemia and gastrointestinal stromal cancer (GIST) [4, 5].

Thus, the patient commenced Glivec® (Novartis, Switzerland) 400 mg/day in October 2008. Clinical symptoms declined within 10 days after initiation of imatinib, and except for slight stool disorders, no adverse effects were noted during treatment. Repeated CT scan in January and March 2009 (Figure 1) revealed a progressive and substantial regression of the tumor mass and durable remission. To date, 8 months after initiation of imatinib, remission persists and no progression of disease is noted.

Previous studies have shown that uterine sarcomas rarely express KIT or PDGFR- β to any determinant degree but express PDGFR- α protein at high intensity [6, 7]. The case described herein might therefore be exceptional, but, analogous to GIST, KIT and PDGFR are homologous and it is tempting to speculate that downstream signaling molecules might be targeted.

In GIST, treatment with imatinib is active independent of the immunohistochemical (IHC) presence or expression level of KIT [8] as, counterintuitively, IHC KIT-negative or -positive GIST share similar morphologic, cytogenetic and molecular features. Wild-type GIST and KIT, but predominantly PDGFR- α mutations, have been found in IHC KIT-negative GIST activating the same downstream oncogenic molecules [9]. However, analysis of exons 12 and 18 of the kinase receptor in our patient (methodology as was described previously [6]), did not reveal mutational status and thus does not entirely explain for the responsiveness toward tyrosine kinase inhibition.

Given the paucity of effective chemotherapeutic regimens but in turn novel molecular targets in uterine sarcomas, here we demonstrate for the first time that rational, i.e. based on IHC detection, PDGFR- β and - α inhibition with imatinib in this relapsed uterine ESS resulted in a durable remission.

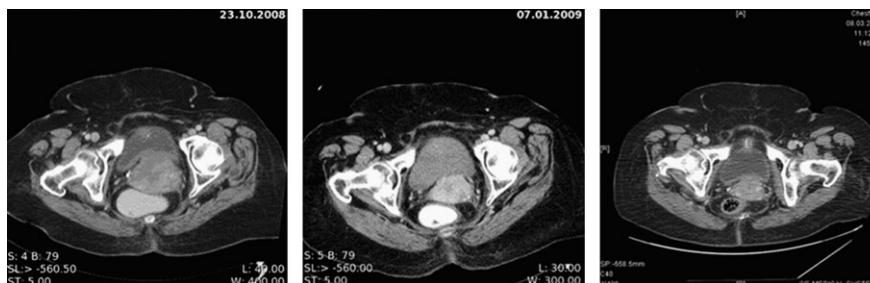


Figure 1. Repeated computed tomography scan conducted at the initiation of imatinib therapy ($14 \times 9 \text{ cm}^2$), 4 and 6 months thereafter, respectively, demonstrating the substantial regression of the endometroid uterine sarcoma ($4 \times 3 \text{ cm}^2$).

Our findings indicate a role for PDGFR signaling in ESS development, with PDGFR and its downstream signaling molecules representing a novel therapeutic target in ESS.

A. Trojan^{1*}, M. Montemurro², M. Kamel³ & G. Kristiansen⁴

¹OnkoZentrum Zürich, Klinik im Park, Zürich, ²Centre Pluridisciplinaire d'Oncologie, ³Department of Radiology, Lausanne, ⁴Department of Pathology, University Hospital, Zürich, Switzerland
(*E-mail: trojan@1st.ch)

references

1. Brooks SE, Zhan M, Cote T, Baquet CR. Surveillance, epidemiology, and end results analysis of 2677 cases of uterine sarcoma 1989–1999. *Gynecol Oncol* 2004; 93: 204–208.
2. Giuntoli RL II, Metzinger DS, DiMarco CS et al. Retrospective review of 208 patients with leiomyosarcoma of the uterus: prognostic indicators, surgical management, and adjuvant therapy. *Gynecol Oncol* 2003; 89: 460–469.
3. Tuveson DA, Fletcher JA. Signal transduction pathways in sarcoma as targets for therapeutic intervention. *Curr Opin Oncol* 2001; 13: 249–255.
4. Heinrich MC, Corless CL, Demetri GD et al. Kinase mutations and imatinib response in patients with metastatic gastrointestinal stromal tumor. *J Clin Oncol* 2003; 21: 4342–4349.
5. Demetri GD, von Mehren M, Blanke CD et al. Efficacy and safety of imatinib mesylate in advanced gastrointestinal stromal tumors. *N Engl J Med* 2002; 347: 472–480.
6. Adams SF, Hickson JA, Hutto JY et al. PDGFR-alpha as a potential therapeutic target in uterine sarcomas. *Gynecol Oncol* 2007; 104: 524–528.
7. Zafrakas M, Theodoridis TD, Zepiridis L et al. KIT protein expression in uterine sarcomas: an immunohistochemical study and review of the literature. *Eur J Gynaecol Oncol* 2008; 29: 264–266.
8. Chirieac LR, Trent JC, Steinert DM et al. Correlation of immunophenotype with progression-free survival in patients with gastrointestinal stromal tumors treated with imatinib mesylate. *Cancer* 2006; 107: 2237–2244.
9. Duensing A, Joseph NE, Medeiros F et al. Protein Kinase C theta (PKCtheta) expression and constitutive activation in gastrointestinal stromal tumors (GISTs). *Cancer Res* 2004; 64: 5127–5131.

doi:10.1093/annonc/mdp431

Published online 11 September 2009