



ELSEVIER

European Journal of Cardio-thoracic Surgery 25 (2004) 865–871

 EUROPEAN JOURNAL OF
 CARDIO-THORACIC
 SURGERY

www.elsevier.com/locate/ejcts

Non-steroidal anti-inflammatory drugs decrease the quality of pleurodesis after mechanical pleural abrasion[☆]

D. Lardinois^{a,*}, P. Vogt^b, L. Yang^a, I. Hegyi^b, M. Baslam^a, W. Weder^a

^a*Division of Thoracic Surgery, University Hospital, Zurich, Switzerland*

^b*Department of Pathology, University Hospital, Zurich, Switzerland*

Received 10 October 2003; received in revised form 7 January 2004; accepted 12 January 2004

Abstract

Objective: Non-steroidal anti-inflammatory drugs (NSAIDs) are often applied for pain management after thoracic surgery. Since these drugs diminish collagen deposition through inhibition of the prostaglandin synthesis, we investigated their effects on adhesion formation after endoscopic mechanical pleural abrasion, which is often applied in the therapy of pneumothorax. **Methods:** Mechanical pleural abrasion was performed unilaterally by the use of video-assisted thoracoscopic surgery technique in an established pig model. Ten animals (41.3 ± 3.4 kg) were divided into a treatment group and a control group. In the treatment group, animals received 100 mg diclofenac (2 mg/kg body weight) orally daily for 3 weeks after surgery. At 3 weeks, all animals were sacrificed and efficacy of pleurodesis was macroscopically assessed by three independent reviewers blinded to the treatment of animals using a five-point severity pleurodesis score (from 0, no adhesions to 4, complete symphysis) and obliteration grade rating the distribution of adhesions (from 0, no adhesions to 4, adhesions in the whole chest). Microscopic evaluation was performed by two pathologists blinded to the study groups as well. A four-point score assessed the amount of collagen deposition (from 1, a few collagen fibers to 4, scar). **Results:** Gross observation showed more dense adhesions in control animals with a median pleurodesis score of 3.67 ± 1.0 in comparison to 2 ± 2.2 in the treatment group ($P = 0.01^*$, Mann–Whitney non-parametric test). Distribution of adhesions was comparable in both groups with a median obliteration score of 3.67 ± 1.3 . Histopathologic examination showed a higher amount of collagen deposition in the control group, suggesting more dense adhesions, whereas in the treatment group there was loose granulation tissue (score of 4.0 ± 0.8 vs. 2.3 ± 1.0 in the treatment group, $P = 0.06$). The degree of inflammatory reaction was comparable in the two groups. **Conclusions:** Our results demonstrate that perioperative use of NSAIDs highly affects the quality of pleural adhesions obtained after mechanical abrasion in this pig model, which further suggests that these drugs should be avoided for pain management when a pleurodesis is performed.

© 2004 Elsevier B.V. All rights reserved.

Keywords: Non-steroidal anti-inflammatory drug; Mechanical pleural abrasion; Pleurodesis; Collagen deposition; Pig model

1. Introduction

Non-steroidal anti-inflammatory drugs (NSAIDs) are being used with increasing frequency, due to their potent analgesic effects without having side-effects on the central neural system and additionally due to the large number and varieties of these agents. The analgesic, anti-inflammatory properties, and efficacy of NSAIDs in a wide variety of diseases have been already established [1,2].

Wound healing and formation of adhesions involve inflammation, cell proliferation, matrix deposition, and neovascularization. The exact mechanism by which NSAIDs affect collagen deposition and the time course of the events leading to the formation of fibrin and of adhesions after pleurodesis have not been completely elucidated until now. NSAIDs can inhibit the inflammatory process and the formation of fibrosis, due to their ability to suppress prostaglandin synthesis [2,3]. It was demonstrated in a rat model that breaking strength and collagen concentration at the wound site were less after use of NSAIDs than in the untreated wounds [4,5]. Despite this, NSAIDs are widely used as perioperative analgesics.

Video-assisted thoracoscopic surgery (VATS) has been demonstrated to be a safe and reliable method in

[☆] Presented at the joint 17th Annual Meeting of the European Association for Cardio-thoracic Surgery and the 11th Annual Meeting of the European Society of Thoracic Surgeons, Vienna, Austria, October 12–15, 2003.

* Corresponding author. Tel.: +41-12-55-8802; fax: +41-12-55-8805.
 E-mail address: didier.lardinois@usz.ch (D. Lardinois).

the management of recurrent spontaneous pneumothorax [6–9]. Thoracoscopic wedge-resection of an identified bleb combined with mechanical pleurodesis or apical pleurectomy is mostly considered as the standard therapy of recurrent pneumothorax. However, in patients who underwent mechanical pleural abrasion, a recurrence rate between 3 and 10% has been reported in different series, often within 1 year postoperatively [10,11]. Reduction of the recurrence rate could be obtained by training surgeons not to overlook blebs during the procedure, consider widening the area of pleurodesis, and/or perform apical pleurectomy [12,13]. The objective of the present study was to assess if NSAIDs affect the quality of pleurodesis resulting from mechanical abrasion in pigs. We hypothesized that the current use of NSAIDs perioperatively in patients with spontaneous pneumothorax could influence the rate of recurrence of the disease after thoracoscopic therapy, due to a decrease in the quality of adhesions obtained after mechanical pleural abrasion.

2. Materials and methods

2.1. Animal subjects

The study protocol was approved by our Institution's Committee on Investigations involving animal subjects. All animals were housed and procedures were performed in the facilities of the University Hospital Zurich. Animal care was provided in accordance with the Guide for the Care and Use of Laboratory Animals (National Institutes of Health NIH No. 86-23, revised, 1985).

2.2. General design

Ten VLS (Schweizerisches Veredeltes Landschwein) pigs with a mean weight of 41.3 kg (range 37.9–44.7 kg) were randomly divided into one treatment group and one control group of five animals each. A unilateral left thoracoscopy and an apical pleural abrasion by use of a commercially available abrader (electro-surgical tip cleaner, Surgisite[®], Johnson & Johnson) were performed in all animals. A chest tube was placed until the animals were extubated. The animals were then extubated. In the treatment group, an NSAID (diclofenac-Voltaren[®]) was orally given to the animals at a dosage of 100 mg daily for 3 weeks after surgery. The animals were then sacrificed. At autopsy, the efficacy of pleurodesis was graded by evaluating the gross appearance of each pleural cavity and lung (pleurodesis score), by determining the extent of adhesion formation (obliteration grade), and by histologic examination. Macroscopic and microscopic evaluations were performed by three reviewers, respectively, two pathologists, blinded to the treatment.

2.3. Operative technique

Premedication was performed by use of ketamin 10–20 mg/kg + azaperon 2 mg/kg + atropine 0.02–0.05 mg/kg intramuscularly. The animals underwent standard endotracheal intubation (endotracheal tubes AIRE-CUF, with connector, Provet AG). Inhalation anesthesia consisted of O₂ and Isofluran. Perioperative monitoring consisted of measurements of arterial blood pressure by use of a cuff and online registration of ECG, temperature, and pulsoxymeter. A venous catheter for infusions was introduced through a vein on the ear. All animals received amoxicillin as an antibiotic therapy (10–20 mg/kg intramuscular) before the operation.

An anti-microbial skin preparation (povidone–iodine) was employed prior to all invasive procedures, each of which was performed by aseptic surgical technique. For thoracoscopic pleurodesis, three 10 mm-trocars were introduced (the optic trocar in the ninth intercostal space, the two others in the eighth intercostal space, anteriorly and posteriorly). Surgery was performed on the left side. Visual examination of the left hemithorax was performed using a rigid telescope and video camera (Richard Wolf Co). Thoracoscopic mechanical abrasion was then performed by rubbing the parietal pleura with an abrader (electro-surgical tip cleaner, Surgisite[®], Johnson & Johnson) until punctate hemorrhages were observed and localized areas of the pleura were abraded (Fig. 1a and b). At the conclusion of each thoracoscopic procedure, a chest tube was inserted through one of the trocar insertion sites. The pleural drain was connected to a reservoir and negative suction (–20 cmH₂O) was applied. The cutaneous trocar incisions were closed with running silk. The chest tube was removed as soon as the animals were awake and began moving, and radiographic verification of complete lung re-expansion was then performed. Directly postoperatively, 1 ml buprenorphine (Temgesic[®]) at a dosage of 0.3 mg/ml was administered subcutaneously to all animals to suppress immediate postoperative pain. A patch of fentanyl (Durogesic TTS 75 µg/h[®]) was also applied on the skin of all animals during the first 3 days postoperatively. No animal of the control group required additional pain therapy from the 4th day until sacrifice. The other animals received diclofenac (Voltaren[®]) orally at a dosage of 100 mg daily for 3 weeks.

2.4. Macroscopic evaluation

In the two groups, the effects of pleurodesis were assessed 3 weeks after thoracoscopic pleural abrasion. The animals underwent standard intubation and were sacrificed by administration of KCl intracardial under deep anesthesia. A median sternotomy was performed and both pleural cavities were inspected and graded by three investigators blinded to the administration or not of the NSAID. Observation of the second thoracic cavity (without pleural

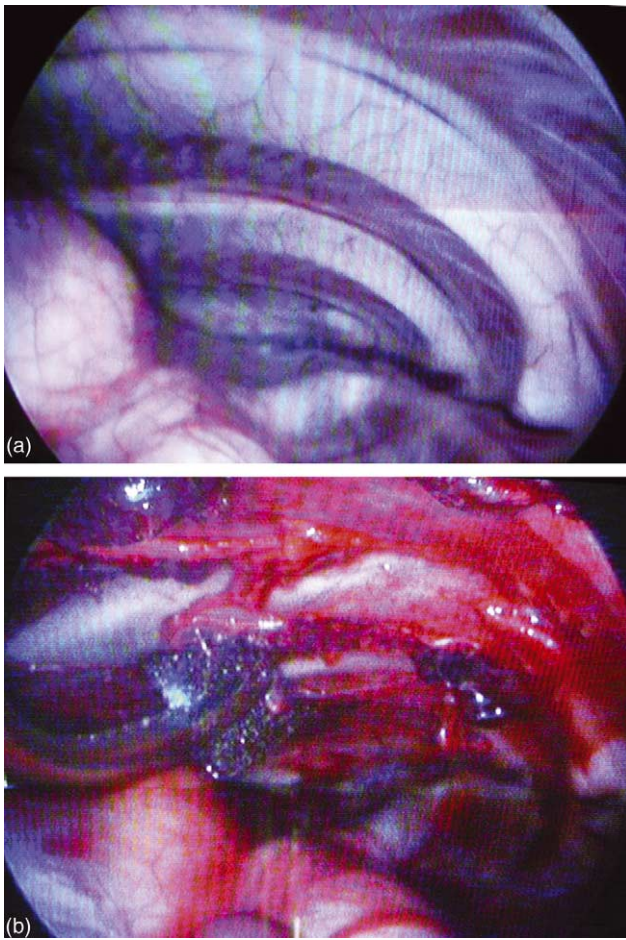


Fig. 1. Left hemithorax before (a) and after (b) thoracoscopic mechanical pleural abrasion.

abrasion) was performed to exclude preexisting pathological findings in the animal.

A five-point *pleurodesis-score* was employed to characterize the response to pleurodesis:

- 0 normal pleural space without any adhesions
- 1 no adhesions but pleural space inflamed as evidenced by redness and fibrin deposition
- 2 few scattered adhesions; light resolution by simple pressure, able to dissect bluntly without tearing the lung
- 3 generalized scattered adhesions; manual resolution, blunt dissection possible
- 4 severe, dense adhesions; sharp dissection with injury to the lung parenchyma required to take down adhesions.

The extent of pleurodesis within the pleural cavity was assessed by use of an *obliteration grade*, measuring the distribution of adhesions between lung and chest wall in the four locations, apical, mediastinal, lateral, and dorsal

- 0 absence of adhesions
- 1 adhesions in one location

- 2 adhesions in two locations
- 3 adhesions in three locations
- 4 adhesions everywhere.

2.5. Microscopic evaluation

In the areas of greatest adhesion formation, a 2–3 cm wedge of lung parenchyma was removed en bloc with a corresponding portion of the chest wall. A specimen was placed in 10% neutral buffered formaldehyde solution and labeled for subsequent identification. Paraffin sections were stained with hematoxylin–eosin and elastin–van Gieson stains. The review of the specimens was made by two pathologists who were blinded to the treatment of the animals. The extent of fibrosis, production of collagen, granulation tissue formation, and foreign body granulomas were assessed. A four-point *fibrosis-score* was used to evaluate the collagen deposition between the lung and the chest wall

- 1 a few fibers of collagen
- 2 more fibers of collagen but not well-organized

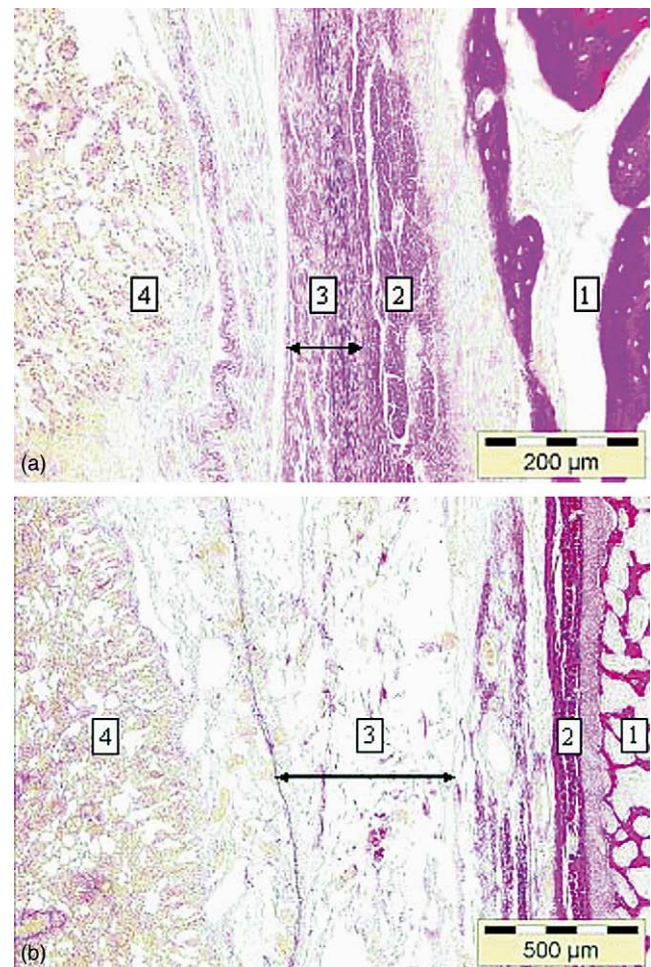


Fig. 2. Microscopic findings 3 weeks after mechanical pleural abrasion. (a) Control group. 1, Bone; 2, muscle; 3, thick layers of collagen fibers; 4, lung. (b) Treated group. 1, Bone; 2, muscle; 3, loose connective tissue with a few fibers of collagen; 4, lung.

Table 1
Pleurodesis score in the two groups of animals

	Treated group					Control group				
	1	2	3	4	5	6	7	8	9	10
Reviewer 1	2	2	2	2	3	3	4	3	4	4
Reviewer 2	2	2	1	1	4	4	4	3	4	4
Reviewer 3	2	2	2	2	3	4	3	4	4	3

- 3 high density of collagen fibers, partially organized in thick layers
4 scar.

2.6. Statistical analysis

The data were expressed as median \pm SD. A non-parametric analysis of variance (Mann–Whitney test, SPSS for Windows, Version 11.0) was performed. A *P*-value < 0.05 was considered statistically significant.

3. Results

All animals except two had an uneventful postoperative recovery. One animal of the treatment group died from gastric ulceration with perforation 1 week following surgery and was replaced. The dosage of diclofenac was maintained at 100 mg/day but a protector of the gastric mucosa was administrated (Omeprazolium, Antra[®], 40 mg/day). Another animal of the NSAID group suffered from diarrhea without evidence of bleeding from the upper gastro-intestinal tract.

In all animals, chest X-ray showed a fully re-expanded left lung after removal of the chest tube.

Observation of the right, non-treated thoracic cavity showed no preexisting adhesions in all animals at autopsy.

Gross macroscopic evaluation showed a more effective pleurodesis, with more dense adhesions requiring sharp dissection for lysis in the control animals with a median pleurodesis score of 3.67 ± 1.0 in comparison to 2 ± 2.2 in the treatment group (*P* = 0.01*, Mann–Whitney non-parametric test). The distribution of the scores given by the three independent reviewers was homogeneous in all control animals (Table 1). In one treatment animal, the scores were comparable in all but one animal in which scattered adhesions were observed. This animal presented

with postoperative diarrhea. Adhesion distribution was uniform and comparable with a median obliteration score of 3.67 ± 1.3 in the two groups of animals.

Histopathologic analysis showed no statistically significant difference between the two groups but did show a clear trend. A higher amount of organized collagen fibers suggesting more dense adhesions was observed in the control group, whereas loose granulation tissue was seen in the treatment group (Fig. 2a and b). The fibrosis score defining the collagen deposition was 4.0 ± 0.8 in the control animals vs. 2.3 ± 1.0 in the treated one (*P* = 0.06, Mann–Whitney non-parametric test). Again the distribution of the scores was homogeneous in the control group, whereas in one animal of the treated group organized collagen fibers were observed. This animal corresponded to the animal with scattered adhesions on gross observation (Table 2). The distance between the chest wall (pleura parietalis) and the lung was shorter in the control group than in the treated animals, in which a very loose connective tissue was observed. In this connective tissue, the proliferation of capillaries and fibroblasts was very limited. In the control animals, granulation tissue was not observed any more because a scar had already developed. The degree of inflammatory reaction was not marked and comparable in the two groups.

4. Discussion

Pleurodesis is a common procedure in thoracic surgery, being performed to prevent recurrence of a pneumothorax or a malignant effusion. After re-expansion of the lung, postoperative adhesions between lung and chest wall are expected to avoid recurrence. The exact mechanisms responsible for the formation of adhesions after pleurodesis remain incompletely understood. Besides an early inflammatory process, mesothelial cell injury results in fibronectin

Table 2
Collagen deposition score in the two groups of animals

	Treated group					Control group				
	1	2	3	4	5	6	7	8	9	10
Pathologist 1	2	1	2	1	4	3	4	3	4	4
Pathologist 2	2–3	2	2	2	4	2–3	4	3–4	4	4

production, which also plays a role in the pathogenesis of fibrin formation and eventual pleural fibrosis [14,15]. Perez showed that plasma proteins including fibrinogen were found at the site of tissue injury, due to increased vascular permeability. Fibrinogen is converted into a fibrin matrix by activated procoagulants. This fibrin matrix is thought to participate early in the inflammatory response by providing a temporary support for inflammatory cell adhesion and migration, and subsequent remodeling of the tissue with permanent extracellular matrix proteins such as collagen [4,14]. In patients, pneumothorax can occur with additional formation of pleural effusion, which can be rich in plasma proteins and fibrinogen. However, it seems unlikely that the pleural fluid per se is responsible for the formation of adhesions, since doxycycline induces a more effective pleurodesis in a rabbit model when the pleural fluid is drained [16]. As the formation of adhesions requires an inflammatory process and as classical NSAIDs inhibit inflammation through inhibition of the prostaglandin synthesis, the perioperative use of NSAIDs as analgesics might negatively influence the pleurodesis obtained after mechanical pleural abrasion. A previous report showed that systemic corticosteroids decrease the effectiveness of talc pleurodesis in a rabbit model, due to an inhibition of the inflammation [14]. The degree of mechanical or chemical pleurodesis has already been evaluated and compared in different trials in animals by use of several scores, but the influence of NSAIDs on pleural adhesions following pleurodesis has not been investigated until now, although these analgesics are very often used in patients nowadays [17–20]. Pigs represent an ideal animal model for this experimental project because this model has already been established in the evaluation of different surgical techniques of the spontaneous pneumothorax and in the comparison of different modalities of pleurodesis [21–24]. This model is suitable for the thoracoscopic approach and is anatomically comparable with patients. The volume of the hemithorax in pigs allows a good evaluation of the macroscopical changes after pleurodesis and a suitable assessment of tissue for histopathologic examination. In the previous reports, macroscopic observation and assessment of samples for histologic analysis were usually performed 3–4 weeks after pleurodesis, because at this time, the histopathologic changes were already present [17–20]. Furthermore, we wanted to put the animals in an analogous situation to patients with pneumothorax, who often take analgesics for a few weeks after surgery. This is the reason why an observation at 3 weeks postoperatively has been proposed in our study. To facilitate comparisons with other experimental studies, we intentionally used both the previously described pleurodesis score and obliteration grade to assess macroscopic outcome.

Gross macroscopic analysis showed significantly more dense adhesions in the non-treated group. This observation was confirmed by the microscopic evaluation. The difference in the analysis of the fibrosis score was not statistically

significant, although a clear trend was shown. This could be due to the small number of animals in each group and to the fact that an animal, which received diclofenac, showed adhesions and collagen deposition. This animal presented with diarrhea postoperatively, which could have impaired the resorption of the substance. In all the other animals, both pleurodesis and fibrosis scores were uniformly distributed.

The obliteration grade is a measure of the extent of adhesions between the lungs, mediastinum and chest wall. The fact that there was no score difference between the two groups as well as the homogeneous repartition of the obliteration grade within each group confirm the reproducibility of our thoracoscopic approach and of the technique of mechanical abrasion used and suggest that abrasion was similar in depth and surface area in all animals. In the microscopic evaluation, the degree of inflammation was comparable in both groups and not very marked. This was not surprising in the animals of the treatment group, since NSAIDs can markedly blunt the early inflammatory process consisting of migration of leukocytes, edema formation, production of fibrin and capillary dilation [3,4,25]. It was also demonstrated that besides the inhibition of the cyclooxygenase pathway, NSAIDs also act as immunomodulating agents by blocking the production of endogenous prostaglandin-E. Prostaglandin-E is involved in regulating monocyte production of collagenase as well as mediating inflammation, and collagenase plays an important role in the breakdown and remodeling of collagen.

In the control group, scar tissue had already developed between the visceral and the parietal pleura at the control time 3 weeks after mechanical abrasion. The inflammatory process after pleural abrasion, including an ingrowth of capillaries, an influx of inflammatory cells with activation of fibroblasts, could have been already achieved at this time. Fibrosis without significant inflammatory reaction was already described in a pig model 30 days after chemical or mechanical abrasion [18,21]. Our results and the data of these previous studies support the concept that adhesion strength and numbers is dependent on an initial and transient inflammatory reaction but not on a persistent chronic inflammation.

In our study, 100 mg diclofenac (Voltaren®) was administered daily. This dosage is similar to the usual postoperative dosage in humans. Gastro-enterologic side-effects were not expected in this project, since NSAIDs have already been administered to pigs over a long time without development of ulceration in other trials [3]. After co-administration of a selective blocker of the proton pump, postoperative recovery was uneventful in all animals. All the animals received the same dose of opiates, ruling out an hypothetical influence of these substances in the interpretation of the results.

In conclusion, the present study demonstrates that the use of classical NSAIDs significantly decreases the quality of pleurodesis after mechanical abrasion in this pig model. As a consequence, we have changed our clinical practice in

the postoperative analgesic therapy of the patients receiving a mechanical pleurodesis either for a pneumothorax or for a malignant effusion. Furthermore, since we could demonstrate the negative effects of these drugs on the quality of pleurodesis, a continuation of this trial evaluating other NSAIDs like selective COX-II inhibitors and nitric oxide-releasing NSAIDs is on-going in the same animal model and using different techniques of pleurodesis like pleurectomy.

References

- [1] Dong YL, Fleming RY, Yan TZ, Waymack JP. Effect of ibuprofen on the inflammatory response to surgical wounds. *J Trauma* 1993;35:340–3.
- [2] Reuter BK, Asfaha S, Buret A, Wallace JL. Exacerbation of inflammation-associated colonic injury in rat through inhibition of cyclooxygenase-2. *J Clin Invest* 1996;98:2076–85.
- [3] Jones MK, Wang H, Peskar BM, Sarfeh IJ, Tarnawski AS. Inhibition of angiogenesis by nonsteroidal anti-inflammatory drugs: insight into mechanisms and implications for cancer growth and ulcer healing. *Nat Med* 1999;5:1418–23.
- [4] Haws MJ, Kucan JO, Roth AC, Suchy H, Brown RE. The effects of chronic ketorolac tromethamine (toradol) on wound healing. *Ann Plast Surg* 1996;37:147–51.
- [5] Muscara MN, McKnight W, Asfaha S, Wallace JL. Wound collagen deposition in rats: effects of an NO-NSAID and a selective COX-2 inhibitor. *Br J Pharmacol* 2000;129:681–6.
- [6] Cardillo G, Facciolo F, Giunti R, Gasparri R, Lopergolo M, Orsetti R, Martelli M. Videothoroscopic treatment of primary spontaneous pneumothorax: a 6-year experience. *Ann Thorac Surg* 2000;69:357–61.
- [7] Hatz RA, Kaps MF, Meimarakis G, Loehe F, Muller C, Furst H. Long-term results after video-assisted thoracoscopic surgery for first-time and recurrent spontaneous pneumothorax. *Ann Thorac Surg* 2000;70:253–7.
- [8] Ayed AK, Al-Din HJ. The results of thoracoscopic surgery for primary spontaneous pneumothorax. *Chest* 2000;118:235–8.
- [9] Chan P, Clarke P, Daniel FJ, Knight SR, Seevanayagam S. Efficacy study of video-assisted thoracoscopic surgery pleurodesis for spontaneous pneumothorax. *Ann Thorac Surg* 2001;71:452–4.
- [10] Cardillo G, Facciolo F, Regal M, Carbone L, Corzani F, Ricci A, Martelli M. Recurrences following videothoracoscopic treatment of primary spontaneous pneumothorax: the role of redo-videothoracoscopy. *Eur J Cardiothorac Surg* 2001;19:396–9.
- [11] Ohno K, Miyoshi S, Minami M, Matsuda H, Ohashi S. Ipsilateral recurrence frequency after video-assisted thoracoscopic surgery for primary spontaneous pneumothorax. *J Thorac Cardiovasc Surg* 2000;48:757–60.
- [12] Leo F, Pastorino U, Goldstraw P. Pleurectomy in primary pneumothorax: is extensive pleurectomy necessary? *J Cardiovasc Surg* 2000;41:633–6.
- [13] Smit HJ, Wienk MA, Schreurs AJ, Schramel FM, Postmus PE. Do bullae indicate a predisposition to recurrent pneumothorax? *Br J Radiol* 2000;73:356–9.
- [14] Perez RL, Roman J. Fibrin enhances the expression of IL-1 beta by human peripheral blood mononuclear cells. Implications in pulmonary inflammation. *J Immunol* 1995;154:1879–87.
- [15] Lee YC, Malkernek D, Devin CJ, Thompson PJ, Johnson JE, Lane KB, Light RW. Comparing transforming growth factor beta-2 and fibronectin as pleurodesing agents. *Respirology* 2001;6:281–6.
- [16] Wu W, Teixeira LR, Light RW. Doxycycline pleurodesis in rabbits: advantage of chest tubes. *Chest* 1997;112:136S.
- [17] Mitchem RE, Herndon BL, Moltani A, Battie CN, Reisz GR. Pleurodesis by autologous blood, doxycycline, and talc in a rabbit model. *Ann Thorac Surg* 1999;67:917–21.
- [18] Colt HG, Russack V, Chiu Y, Pedersen CA, Kapelanski D. A comparison of thoracoscopic talc insufflation, slurry, and mechanical abrasion pleurodesis. *Chest* 1997;111:442–8.
- [19] Xie C, Teixeira LR, McGovern JP, Light RW. Systemic corticosteroids decrease the effectiveness of talc pleurodesis. *Am J Respir Crit Care Med* 1998;157:1441–4.
- [20] Lee YC, Teixeira LR, Clinton JD, Lane KB, Light RW. Transforming growth factor-β2 induces pleurodesis significantly faster than talc. *Am J Respir Crit Care Med* 2001;163:640–4.
- [21] Cohen RG, Shely WW, Thompson SE, DeMeester TR, Starnes VA. Talc pleurodesis: talc slurry versus thoracoscopic talc insufflation in a porcine model. *Ann Thorac Surg* 1996;62:1000–2.
- [22] Platt TE, Menegazzi JJ, Check BD. A randomized, crossover comparison of various ventilation devices in a swine pneumothorax model. *Prehosp Emerg Care* 1998;2:167–9.
- [23] Barton ED, Rhee P, Hutton KC, Rosen P. The pathophysiology of tension pneumothorax in ventilated swine. *J Emerg Med* 1997;15:147–53.
- [24] McGahren ED, Teague WG, Flanagan T, White B, Rodgers BM. The effects of talc pleurodesis on growing swine. *J Pediatr Surg* 1990;25:1147–51.
- [25] Ukawa H, Yamakuni H, Kato S, Takeuchi K. Effects of cyclooxygenase-2 selective and nitric oxide-releasing nonsteroidal anti-inflammatory drugs on mucosal ulcerogenic and healing responses of the stomach. *Dig Dis Sci* 1998;43:2003–11.

Appendix A. Conference discussion

Dr T. Treasure (London, UK): This is clinically, potentially, important. In order to translate this into clinical practice, we would need to know that it was true also in humans. And in order to get the numbers, it probably needs a multicenter trial.

Do you think that you could come up with a feasible design to test this in the human situation?

This morning, in another session, there was talk about whether Society and the Association lead multicenter trials. Do you think this could be done in that way?

Dr Lardinois: Although the number of the animals was small in our study, the difference between the two groups was so clear and undoubtful that we have changed our clinical practice in the postoperative analgesic therapy of the patients receiving a mechanical pleurodesis either for a pneumothorax or for a malignant effusion. We do not give classical NSAIDs any more.

Dr J. Wihlm (Strasbourg, France): Actually, it's a concept we have, since years, in our department because we are fighting with the anesthesiologists because when they stopped any means of pain control including peridural analgesia, for example, they gave oral morphinics and these kinds of drugs. And we completely abandoned that especially when operating on emphysema and COPD people.

Dr Lardinois: We can understand the anesthesiologists when giving NSAIDs for postoperative pain management because these substances have potent analgesic effects without having side-effects on the central neural system and additionally due to the large number and varieties of these agents.

Dr G. Egri (Budapest, Hungary): I only wonder if you had any data before concerning this effect of NSAIDs, or how did you have this concept to look if these kinds of drugs have such effects on the pleura?

Dr Lardinois: Several reports already showed that NSAIDs can inhibit the inflammatory process and the formation of fibrosis, due to their ability to suppress prostaglandin synthesis. It was also demonstrated that collagen concentration at the wound site was less after use of NSAIDs than in the untreated wounds. Furthermore, the degree of mechanical or chemical pleurodesis has already been evaluated and compared in different trials in animals by use of several scores. Pigs represent an ideal animal model for this experimental project because this model has already been established in

the evaluation of different surgical techniques of the spontaneous pneumothorax and in the comparison of different modalities of pleurodesis. To facilitate comparisons with other experimental studies, we intentionally used both the previously described pleurodesis score and obliteration grade to assess macroscopic outcome.

Dr S. Eggeling (*Berlin, Germany*): I have two questions. The first is do you think that you can transport this model to pleurectomy, so spontaneous pneumothorax operation with pleurectomy?

And the second one is, there are a lot of non-steroid anti-phlogistic drugs, and do you have an idea if this is true, for example, for Novalgin (Novaminsulfon)?

Let me tell you that for 5 or 6 years we abandoned any NSAIDs from pleurodesis because of this point of view. This is a very nice study, and it's good to know that you found out what we already thought that will be true; but we always used Novalgin, and we think that this doesn't reduce the effect of pleurodesis.

Dr Lardinois: Regarding the first question, I cannot give you a precise answer. In the literature it is not clear what represents the best technique of pleurodesis in patients. There are reports showing a benefit of talc pleurodesis and other demonstrating an advantage of mechanical pleurodesis or of pleurectomy. We choose the VATS approach combined with a mechanical abrasion because thoroscopic wedge-resection of an identified bleb combined to mechanical pleurodesis is mostly considered as the standard therapy of recurrent pneumothorax.

We are evaluating other analgesics like selective COX-2 inhibitors on the same model using mechanical or other modalities of pleurodesis in an ongoing study. Regarding your second question, we do not use Nivaquine in our institution and I have no experience with it.

Dr G. Ladas (*London, UK*): There is evidence we saw that a single dose of non-steroidals produces analgesic effect quite quickly, while the anti-inflammatory effect takes longer, takes a couple of weeks to become pronounced.

So the question is, how did you choose this 3-week period? Because what often happens, the most difficult period for postoperative pain control is when you stop the PCA or epidural. And some people feel that giving a single or a couple doses of non-steroidals may help you in this transition period without necessarily carrying over for 3 weeks. So do you plan to look into the effect in a shorter period of administration?

Dr Lardinois: As already mentioned, the degree of mechanical or chemical pleurodesis has already been evaluated and compared in different trials in animals. In these previous reports, macroscopic observation and assessment of samples for histologic analysis were usually performed 3–4 weeks after pleurodesis because at this time, the histopathologic changes were already present and the inflammatory process has been already achieved. Furthermore, we wanted to put the animals in an analogous situation to patients with pneumothorax, who often take analgesics for a few weeks after surgery. That is the reason why an observation at 3 weeks postoperative has been proposed in our study.