

37. Janson C, Lindberg E, Gislason T, Elmasry A, Boman G. Insomnia in men—a 10-year prospective population based study. *Sleep* 2001;**24**:425–430.
38. Mezick EJ, Hall M, Matthews KA. Are sleep and depression independent or overlapping risk factors for cardiometabolic disease? *Sleep Med Rev* 2011;**15**:51–63.
39. Taylor D, Mallory L, Lichstein K, Durrence H, Riedel B, Bush A. Comorbidity of chronic insomnia with medical problems. *Sleep* 2007;**30**:213–218.
40. Hung J, Whitford EG, Hillman DR, Parsons RV. Association of sleep apnoea with myocardial infarction in men. *Lancet* 1990;**336**:261–264.
41. Benetó A, Gomez-Siurana E, Rubio-Sanchez P. Comorbidity between sleep apnea and insomnia. *Sleep Med Rev* 2009;**13**:287–293.
42. Coleman RM, Roffwarg HP, Kennedy SJ, Guilleminault C, Cinque J, Cohn MA, Karacan I, Kupfer DJ, Lemmi H, Miles LE, Orr WC, Phillips ER, Roth T, Sassin JF, Schmidt HS, Weitzman ED, Dement WC. Sleep-wake disorders based on a polysomnographic diagnosis. *JAMA* 1982;**247**:997–1003.
43. Krell S, Kapur V. Insomnia complaints in patients evaluated for obstructive sleep apnea. *Sleep Breath* 2005;**9**:104–110.

CARDIOVASCULAR FLASHLIGHT

doi:10.1093/eurheartj/ehu036

Online publish-ahead-of-print 16 February 2014

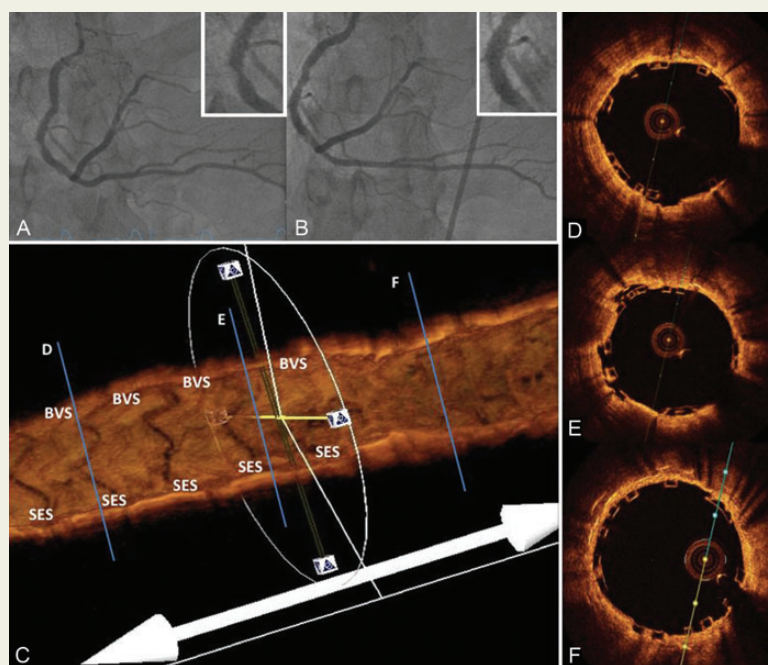
First three-dimensional optical frequency domain imaging evaluation of a bioabsorbable vascular scaffold implantation in an in-stent restenosis 6 years after CYPHER stenting

Milosz Jaguszewski, Slayman Obeid, Thomas F. Lüscher, and Christian Templin*

University Heart Center, University Hospital Zurich, Raemistr. 100, 8091, Zurich, Switzerland

*Corresponding author. Tel: +41 442559585, Fax: +41 442554401, Email: christian.templin@usz.ch

A 60-year-old male patient with a past history of acute ST-segment elevation myocardial infarction in 2007 and primary percutaneous coronary intervention of the right coronary artery (RCA) was referred to the Andreas Gruentzig Catheterization Laboratories for elective evaluation due to angina symptoms and a positive stress perfusion magnetic resonance imaging (MRI) with an inferoseptal ischaemic burden and furthermore a reduced left ventricular ejection fraction of 39% was detected by MRI. An angiogram was performed and as culprit lesion a 70% in-CYPHER-Stent restenosis in the middle portion of the RCA (Panel A) was detected. After passing the lesion with a BMW guide wire and a vascular sealing with a 3.0 × 15 mm Maverick balloon and a 3.0 × 12 mm non-compliant Maverick balloon (25 atmosphere), a bioabsorbable vascular scaffold (BVS) 3.5 × 18 mm was implanted in the middle portion of the RCA. Subsequently, after post-dilatation with a 3.5 × 15 mm non-compliant Maverick balloon (25 atmosphere), the final angiogram (Panel B) and three-dimensional (3D)-optical frequency domain imaging (OFDI) (Panel C) demonstrated an optimal post-procedural result with well-apposed scaffold struts in all cross-sectional images (Panels D–F).



Bioabsorbable vascular scaffold has been utilized to cover simple, *de novo* lesions so far. Scarce data exist on the potential use of BVS in off-label indications, such as acute coronary syndromes, in bifurcation lesions, chronic total occlusions and in-stent restenosis. Interventional studies are now underway to answer the safety issues of these indications.

Three-dimensional optical frequency domain imaging as a high-frame rate and high resolution intravascular imaging shows the strut apposition of implanted scaffolds inapparent in coronary angiography. Furthermore, the rapid spiral pullback enables the 3D reconstruction and visualization of the strut rupture and whole scaffold structure. Herein, we present for the first time a 3D-OFDI to demonstrate the performance and feasibility of BVS in a patient with in-stent restenosis.