

Q J Med 2004; 97:717–727
doi:10.1093/qjmed/hch118

Original papers



Life-threatening envenoming by the Saharan horned viper (*Cerastes cerastes*) causing micro-angiopathic haemolysis, coagulopathy and acute renal failure: clinical cases and review

M. SCHNEEMANN¹, R. CATHOMAS¹, S.T. LAIDLAW², A.M. EL NAHAS²,
R.D.G. THEAKSTON³ and D.A. WARRELL^{3,4}

From the ¹Department of Medicine, University Hospital, Zürich, Switzerland,

²Sheffield Kidney Institute, Northern General Hospital, Sheffield, UK,

³Alistair Reid Venom Unit, Liverpool School of Tropical Medicine, Liverpool, UK, and

⁴Nuffield Department of Clinical Medicine, University of Oxford,
John Radcliffe Hospital, Oxford, UK

Received 4 May 2004 and in revised form 12 August 2004

Summary

Background: The desert horned vipers (*Cerastes cerastes* and *C. gasperettii*) are the most familiar snakes of the great deserts of North Africa and the Middle East, including the plains of Iraq. They are responsible for many human snake bites. In Western countries, they are popular among exotic-snake keepers.

Aim: To investigate mechanisms of life-threatening envenoming and treatment.

Design: Clinical investigation.

Methods: Clinical and laboratory studies with measurement of serum venom antigen concentrations by enzyme immunoassay.

Results: Two men bitten while handling captive Saharan horned vipers (*Cerastes cerastes*) in Europe developed extensive local swelling and life-threatening systemic envenoming, characterized

by coagulopathy, increased fibrinolysis, thrombocytopenia, micro-angiopathic haemolytic anaemia and acute renal failure. The clinical picture is explicable by the presence in *C. cerastes* venom of several thrombin-like, Factor-X-activating, platelet-aggregating, haemorrhagic and nephrotoxic components. In one case, prophylactic use of subcutaneous epinephrine may have contributed to intracranial haemorrhage. The roles in treatment of heparin (rejected) and specific antivenom (recommended) are discussed.

Discussion: *Cerastes cerastes* is capable of life-threatening envenoming in humans. Optimal treatment of envenoming is by early administration of specific antivenom, and avoidance of ineffective and potentially-dangerous ancillary methods.

Introduction

The desert horned vipers (genus *Cerastes*) are the best known, most distinctive and most abundant

venomous snakes of the great deserts of North Africa and the Middle East; from Morocco in the

Address correspondence to Professor D.A. Warrell, Nuffield Department of Clinical Medicine, University of Oxford, John Radcliffe Hospital, Headington, Oxford OX3 9DU, UK. e-mail: david.warrell@ndm.ox.ac.uk

QJM vol. 97 no. 11 © Association of Physicians 2004; all rights reserved.

west, east to Iraq and western Iran, and south to the Sudan. In Arabia, it is one of the most frequently observed snakes despite its nocturnal habit;¹ in Dharan, Saudi Arabia, it was responsible for most of a series of 26 cases of snake bite;² and on the plains of Iraq, it is the commonest snake.³ In Egypt, *C. cerastes* was depicted in pre-dynastic times (>3000 BC),^{4,5} and was represented by the phonetic hieroglyph 'f' or 'fy' in inscriptions and papyri.⁶ Whether Cleopatra used a snake as the instrument of her suicide has been long debated.^{7,8} Some favour the idea that she chose *C. cerastes*, but its venom is insufficiently potent, rapid and reliable. A more plausible candidate is the Egyptian cobra or 'asp' (*Naja haje*). In the 5th century AD, the Greek historian Herodotus found that at Thebes in Upper Egypt, horned vipers were deemed sacred⁹ and their bodies were embalmed.¹⁰ These snakes have captured the attention of desert travellers from the time of James Bruce of Kinnaird in the 18th century^{7,11} to Doughty, Philby and Thesiger in the 20th.¹²

The genus *Cerastes* (Viperinae) comprises three species of desert vipers: *C. cerastes* (Saharan horned viper) (Figure 1) distributed across North Africa as far as south-western Israel and also in south-western Arabia; *C. gasperettii* (Gasperetti's horned viper), from the Arava Valley of south-eastern Israel, east through the Arabian peninsula to western Iran; and *C. vipera* (Saharan sand-viper), a much smaller species which never has supraocular horns.^{13,14} In

the past, *C. cerastes* and *C. gasperettii* were known by many other scientific names, including *C. cornutus*, *C. aegyptiacus*, and *Aspis cerastes*. Until now, no distinction has been made between the venoms of *C. cerastes* and *C. gasperettii* in the medical or toxinological literature but, in the present paper, attribution has been inferred reliably from the known geographical distribution of the two species, accepting their sympatry in south-western Arabia. A hornless subspecies *C. c. mutila*, inhabiting the western Sahara, was proposed by Doumergue.¹⁴ However, this feature is now regarded as merely a polymorphism and the subspecies is no longer recognized.¹⁵

In the 19th century, *C. cerastes* had a bad reputation among French military surgeons in Algeria (see below). Doumergue (1901)¹⁵ considered its bite potentially lethal, Calmette (1908)¹⁶ thought it responsible for frequent fatal accidents and Phisalix (1922)¹⁷ noted that its bite could kill many different species including horses, camels and pigeons. However, Corkill (1935) wrote that 'This species is of wide distribution, frequent occurrence, evil reputation and fierce behaviour, yet not a single thoroughly authenticated fatal case of poisoning resulting from its bite has been published.'¹⁸ This echoed the opinion of the Egyptian physicians who wrote the earliest known account of the treatment of snake bite, the Brooklyn Museum Papyri, dating perhaps from 2200 BC. They regarded bites by horned vipers 'fy' as non-lethal, as the victims could be saved.^{6,19}



Figure 1. Saharan horned viper (*Cerastes cerastes*).



Figure 2. Saharan horned viper (*Cerastes cerastes*) lacking supra-ocular horns and responsible for biting Patient 1.

In the face of such a historical depth of medical opinion, we were surprised to be confronted by two cases of potentially fatal envenoming caused by captive specimens of the Saharan horned viper (*C. cerastes*). We attempt to attribute the underlying pathophysiological mechanisms to known constituents of the venom of this fabulous snake.

Case histories

Patient 1

A 63-year-old retired car salesman, presented to Chur regional hospital, Switzerland, on 19 May 2001 at 1400 h. One and a half hours earlier, he had been bitten on the index finger of his left hand by his pet Saharan horned viper, which he designated '*Cerastes cerastes mutila*' (Figure 2). This snake, captive-bred (F2) from southern Moroccan stock, was 7 years old and 60 cm in total length. The patient had been bitten by a *Vipera raddei* 30 years earlier, but had not been given antivenom. He felt well. There were two visible fang punctures. Results of routine haematological tests, including tests of blood coagulation, were completely normal. However, over the next 6 hours, swelling extended throughout the arm. He became fatigued and nauseated, and he vomited. Five and a half hours after the bite, an area of necrosis 1.5 cm in diameter was discernible at the bite, and there was evidence of coagulopathy: International Normalized Ratio (INR) 2.4, PTT 67 s, fibrinogen 0.3 g/l.

He was referred to the University Hospital of Zürich, arriving 8 h after the bite. The serum *C. cerastes* venom antigen concentration, measured later by enzyme-immuno-assay in Liverpool, was

36.5 ng/ml.²⁰ Ten and a half hours after the bite, he received, over 1 h, 50 ml of Antirept (Pasteur Mérieux Lyon-France sérum antivenimeux, polyvalent, purifié: moyen orient-afrique du nord), an equine antivenom with activity against *C. cerastes* venom. Epinephrine (0.25 mg) was injected subcutaneously as prophylaxis a few minutes beforehand and, 30 min after the antivenom, he was given 100 mg of prednisolone intravenously, because he had developed nausea, suggesting an anaphylactoid reaction. Two hours after starting antivenom, his serum venom antigen concentration had dropped to 2.2 ng/ml.

Initial laboratory findings showed undetectable plasma fibrinogen, prolonged prothrombin time (>200 s, INR 5.1), prolonged APTT (>200 s), prolonged thrombin time (>200 s), low factor II activity (54%; normal range 60–150%), very low factor V activity and thrombocytopenia (Table 1). Factor VII and factor VIII activities were normal and anti-thrombin III activity was slightly diminished (73%; normal range 75–120%). D-dimers were slightly elevated (Table 1). On admission, his urine contained erythrocytes but no leukocytes or casts. The patient received 2 g of fibrinogen, 4 units of fresh frozen plasma and six units of platelets.

Over the next 12 h, prothrombin time, factor V and fibrinogen had returned to normal (Table 1). However, haemolytic anaemia developed (Table 1), LDH peaked at 8136 U/l on day 5 and haptoglobin levels were low from day 1 onwards, with a nadir of <1 mg/dl on day 5). Fragmented erythrocytes were seen on day 1 and persisted until day 11. These findings were compatible with micro-angiopathic haemolysis. Intravenous heparin (10 000 units/24 h) was given for one day starting on

day 2, in an attempt to inhibit thrombin formation (see Discussion).

There was a persistent profound thrombocytopenia and evidence of increased fibrinolysis (Table 1), fibrinogen degradation products 7400 ng/l (normal values <500 ng/l) and rhabdomyolysis (creatin kinase maximum 7873 U/l with a low CK-MB isoenzyme peaking at 109U/l on day 4, myoglobin 2874 µg/l). Myocardial damage was suggested by a troponin T level of 1.6 µg/l, although the electrocardiogram remained normal apart from a sinus tachycardia. A beta-blocker was started for suspected ischaemic heart disease.

He remained haemodynamically stable, but was virtually anuric. Biochemical evidence of acute renal failure developed over the first 48 h requiring haemodialysis. Because of the evidence of persistently increased fibrinolysis and the thrombocytopenia, it was decided to administer a second 100 ml dose of antivenom (Favirept, Pasteur Mérieux Lyon-France, fragments F(ab)₂ d'immunoglobulines équine antivenimeuses de Bitis, Echis, Naja, Cerastes et Macrovipera) on day 4, 80 h after the snakebite. Before antivenom administration, the patient received 100 mg of prednisolone intravenously, 2 mg of clemastine (a histamine anti-H₁ blocker) intravenously and 0.25 mg epinephrine subcutaneously as prophylaxis against anaphylactic reactions. The following morning, the patient noticed difficulty in picking up a cup and reading the newspaper. Ophthalmoscopy excluded a retinal lesion but, 16 days later, after he had been transferred back to Chur, an MRI revealed an intracerebral haemorrhage in the occipital region (Figure 3).

During the next 10 days, the patient's haemoglobin concentration increased steadily, and the thrombocytopenia resolved completely (Table 1). Haemodialysis was maintained until the proteinuria decreased to <1 g/day after 37 days. His renal function continued to improve, returning to normal for him two months after the bite. Twenty months

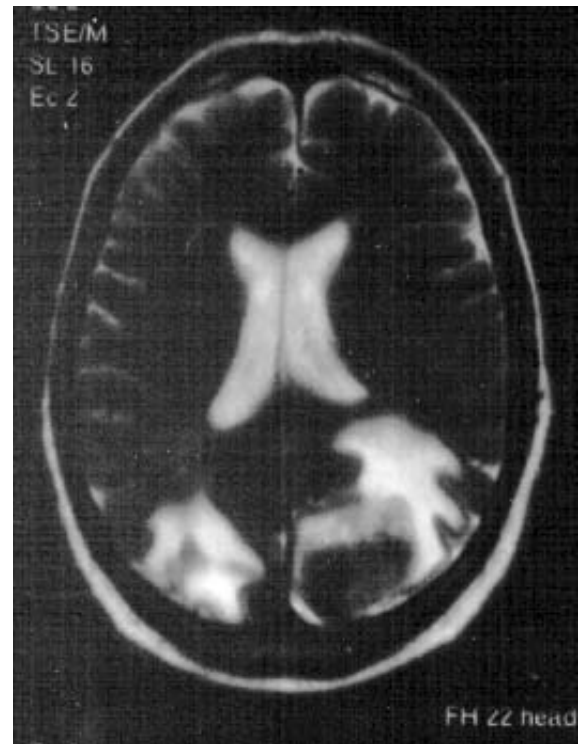


Figure 3. Patient 1: MRI scan taken 16 days after he developed symptoms of a stroke (courtesy of Dr Brunner, Kantonsspital Chur, Switzerland).

after the snakebite, the patient was well with no sequelae.

Patient 2

A 43-year-old unemployed snake enthusiast was admitted to a hospital in Sheffield, UK at 1030 h on 18 September 1998, complaining of increasing pain and swelling of the right arm. About 20 h earlier, he had been bitten on the right index finger by a Saharan horned-viper (*C. cerastes*), said to be from North Africa, while negotiating its purchase in London. Initially, there was some pain and local swelling but after drinking heavily, he slept for most of the train journey back to Sheffield. He was

Table 1 Patient 1: changes in haematological variables after antivenom treatment

| Days after bite | 1 | 2 | 3 | 4 | 5 | 6 | 7 | 8 | 9 | 10 | 11 | NR |
|-------------------------------|------|------|-------|-------|------|------|------|------|-----|------|-----|---------|
| Antivenom | • | | | • | | | | | | | | |
| Haemoglobin (g/l) | 154 | 104 | 90 | 75 | 66 | 75 | 65 | 82 | 78 | 79 | 72 | |
| Platelets ($\times 10^9/l$) | 67 | 24 | 29 | 13 | 32 | 25 | 44 | 68 | 113 | 161 | 173 | |
| Prothrombin time (%) | 10 | 32 | 55 | 95 | 100 | 105 | 108 | 105 | 100 | 100 | | |
| Factor V (%) | 2 | 59 | 70 | 102 | 109 | 116 | | | | | | 50–100% |
| Fibrinogen (g/l) | U | 1.06 | 2.5 | 3.04 | 4.01 | 3.9 | 3.17 | 3.87 | 2.6 | 4.48 | | |
| D-dimer (µg/ml) | 0.25 | 0.45 | 17.58 | 12.11 | 8.05 | 5.62 | 2.92 | 3.85 | | 0.3 | | <0.2 |

U, Undetectable; NR, normal range.

awoken by pain 11 h after the bite. On admission, he was complaining of increasing pain, swelling and bruising in the bitten limb. He had felt short of breath after walking up a slope to the hospital. There were two fang punctures on the knuckle of his right index finger and gross tender swelling of the entire right arm from fingers to the shoulder-tip. There was bruising in the antecubital fossa but no other evidence of bleeding, his blood pressure was normal and he was still passing some urine. There were no other abnormal physical signs. The ECG was normal apart from a sinus tachycardia of 110 bpm. The haemoglobin concentration was normal, there was thrombocytopenia (Table 2), leukocyte count $18.2 \times 10^9/l$ (neutrophils 15.9), prothrombin time 23.9 s (INR 1.92, laboratory normal range 11–15 s), APTT 39 s (28–38 s), thrombin time 14 s (9 s), fibrinogen concentration reduced with elevated D-dimers (Table 2). The serum *C. cerastes* venom antigen concentration was 5.6 ng/ml at 1200 h (21 h after the bite). Urethral catheterization yielded only a few ml of dark urine. There was evidence of free haemoglobin in his blood and urine (Figure 4). The blood film showed red cell fragmentation, crenation and microspherocytes (Figure 5a). Plasma sodium 141 mmol/l, potassium 6.1 mmol/l, urea and creatinine elevated (Table 2), bilirubin 73 mmol/l, creatine kinase 401, myoglobin 700. Twenty-two and a half hours after the bite, *C. cerastes* venom antigen concentration was 28.2 ng/ml. After consultation with DAW, 10 ampoules of Behringwerke Near and Middle East polyspecific antivenom were administered 23–24 h after the bite and, in view of his deteriorating renal function, he was admitted to the Renal Unit. A femoral dialysis line was inserted under the cover of an infusion of platelets and cryoprecipitate. Five hours after starting antivenom, *C. cerastes* venom antigen was undetectable in his serum. Prothrombin time (12 s), APTT (33 s), and fibrinogen had returned to normal, levels of D-dimer had dropped and the platelet count had risen

(Table 2). Over the next three days, his haemoglobin concentration and platelet count fell, and there was continuing deterioration in his renal function (Table 2). A second dose of 10 ampoules of the same antivenom was therefore given 4 days after the bite. After this there was a sustained increase in platelet count. He was given haemodialysis 4, 6 and 11 days after the bite. Morphological evidence of microangiopathic haemolysis persisted, the changes becoming more severe on the day after the first antivenom treatment (Figure 5b). Impressed by further falls in haemoglobin concentration and platelet count 4–8 days after the bite together with the blood film appearances of red cell fragmentation with many burr cells (Figure 5c), the nephrologists postulated haemolytic uraemic syndrome and contemplated renal biopsy and plasma exchange. However, his urine output and renal function improved consistently over the next few days. He was discharged from hospital 20 days after the bite. Thirty-seven days after the bite, the swelling of his arm was resolving, although the digits were still swollen and stiff. Red cell fragmentation was still evident on the blood film, his haemoglobin was 11.0 g/dl, platelets $157 \times 10^9/l$, urea 6.9 mmol/l, creatinine 132 $\mu\text{mol/l}$. Subsequently, all these abnormalities resolved completely.

Discussion

There is a small literature on envenoming by desert horned vipers. Identification is facilitated by the distinctive supraorbital 'horns' (Figure 1), which make this snake virtually unmistakable. Severe and even fatal envenoming by *C. cerastes* was reported in the 19th century. Chavasse (1891) provided what is probably the only account of a fatal bite by this species.²¹ A 28-year-old man was bitten twice on the index finger by a horned viper near Laghouat oasis, 400 km south of Algiers. After four days of traditional treatment, he presented

Table 2 Patient 2: changes in haematological variables and renal function after antivenom treatment

| Days after bite | 0 | 1 | 2 | 3 | 4 | 5 | 6 | 7 | 8 | 9 | 10 | 11 | 12 | NR |
|----------------------------------|------|------|------|------|------|------|------|------|------|------|------|------|------|---------|
| Antivenom | • | | | • | | | | | | | | | | |
| Haemoglobin (g/l) | 155 | 113 | 101 | 84 | 82 | 65 | 72 | 62 | 80 | 72 | 73 | 69 | 79 | |
| Platelets ($\times 10^9/l$) | 65 | 114 | 62 | 42 | 73 | 101 | 200 | 245 | 280 | 342 | 315 | 334 | 246 | |
| Fibrinogen (g/l) | 0.45 | 2.14 | 4.08 | 4.39 | | 4.53 | 5.26 | 4.46 | 3.97 | | 4.7 | 4.7 | 4.83 | 1.8–4.0 |
| D-dimer ($\mu\text{g/ml}$) | 128 | 64 | 8 | 8 | | 6 | 3 | 6 | 6 | | 6 | 6 | 4 | <0.2 |
| Urea (mmol/l) | 13.3 | 28.6 | 33.8 | 32.0 | 41.6 | 47.2 | 37.4 | 41.7 | 25.7 | 33.8 | 25.5 | 29.8 | 25.1 | |
| Creatinine ($\mu\text{mol/l}$) | 355 | 754 | 903 | 923 | 1098 | 1370 | 1123 | 1319 | 878 | 1054 | 899 | 1087 | 879 | |

NR, normal range.




Figure 4. Patient 2: on admission to hospital, spontaneously sedimented blood showing haemoglobinaemia (right), compared to a control.

with vomiting, sweats, severe headache, epistaxis and red urine. He was febrile, jaundiced and collapsed with tachypnoea, tachycardia, swelling of the entire bitten arm and painful, enlargement of lymph nodes. Over the next few days, the bitten finger became gangrenous with a purulent discharge; the patient experienced persistent diarrhoea and died one week after the bite. Corkill

reviewed snakes and snake bites in Iraq (1932)³ and the Sudan (1935).¹⁸ He mentioned two anecdotal fatalities from Dohuk and Baghdad, in one of which the patient died 24 h after the bite with massive swelling of the bitten arm. The usual symptoms were marked swelling and necrosis followed by indolent sepsis in the neighbourhood of the bite, but with a notable absence of the haemorrhagic symptoms typical of viperine envenoming.³ Guyon (1862) described two cases in Laghouat, Algeria treated by local incisions and instillation and ingestion of ammoniacals.²² One man, bitten on the foot, had been subjected to a traditional remedy of having the bitten part placed inside the abdomen of a freshly-killed dog. He developed local swelling up to the knee and, 4 days later, hemiparesis and difficulty speaking, attributable to a stroke. The other, who was bitten on the buttock while sleeping in his tent, coughed up blood a few hours later. Schaumont (1883) treated three cases in Algeria with local instillation of an opiate-ether potion.²³ Only one of them developed signs of local envenoming. Driout (1883) in southern Algeria advocated potassium permanganate treatment after demonstrating its efficacy in dogs, goats and birds bitten by horned-vipers.²⁴ Escard (1889) admitted a patient who had been bitten on the little toe 24 h earlier by a 'léfâ' (*C. cerastes*) in Algeria.²⁵ The bitten limb was red with purplish blotches and was tensely swollen right up to the inguinal ligament. There were blisters containing yellowish fluid and a hydrarthrosis of the knee. Despite repeated injections of potassium permanganate into the limb, all the symptoms had disappeared after 12 days. Calmette (1908) reported a 26-year-old man who was bitten on the finger by a horned-viper 50 cm in length near Laghouat, Algeria.¹⁶ He was treated with Calmette's non-specific antivenomous serum and with injections of potassium permanganate and, over the next few days, developed tense swelling and ecchymoses of the arm and adjacent area of the trunk but survived. A number of cases of *C. cerastes* envenoming have been described in Israel. Efrati (1979) noted that the clinical features in seven cases were similar to mild envenoming by *Vipera palaestinae*. One patient developed necrosis requiring amputation of a finger.²⁶ Systemic symptoms were mild, comprising nausea and vomiting in most patients, with skin haemorrhages and haematuria in four. Evidence of coagulopathy (hypofibrinogenaemia and prolongation of prothrombin time) was less severe than in victims of *Echis coloratus* envenoming. Path and Ravid (1971) reported a 20-year-old man bitten on the finger who showed transient tachycardia, decrease in haemoglobin concentration (9.4 g/dl), thrombocytopenia

($98 \times 10^9/l$) and depletion of clotting factors (prothrombin time 20%, thrombin and APPT mildly prolonged), who was admitted 8 h after the bite.²⁷ There was marked swelling of the bitten hand and

arm, and a local haemorrhagic blister, which turned necrotic. Shargil *et al.* (1973) described six cases of *C. cerastes* bite admitted to hospital in Tel Aviv.²⁸ Most of the patients had applied tourniquets, and

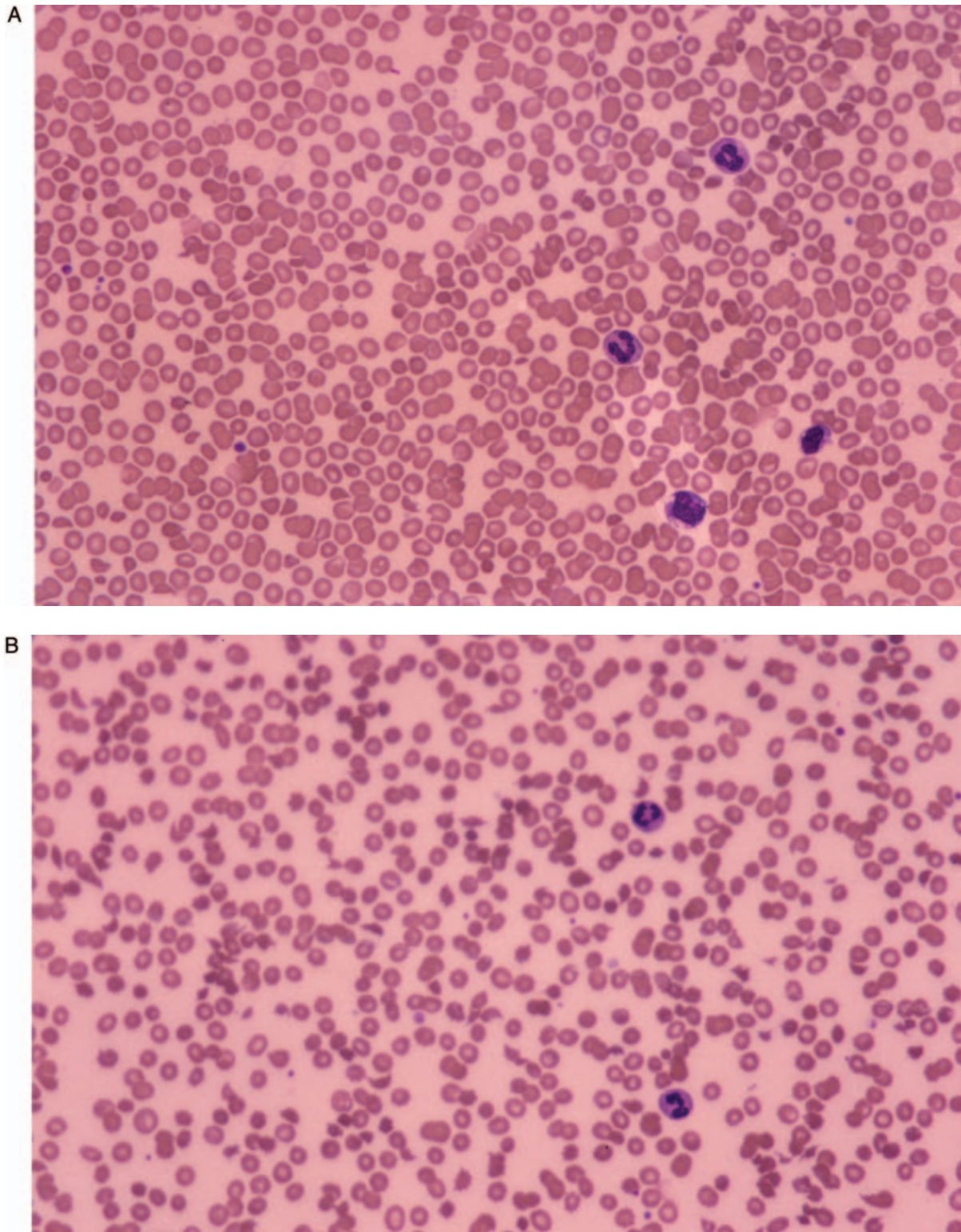


Figure 5. Patient 2: blood smear showing fragmented erythrocytes, evidence of microangiopathic haemolysis: **A** on admission to hospital 20 h after the bite; **B** 44 h after the bite; and **C** 7 days after the bite.

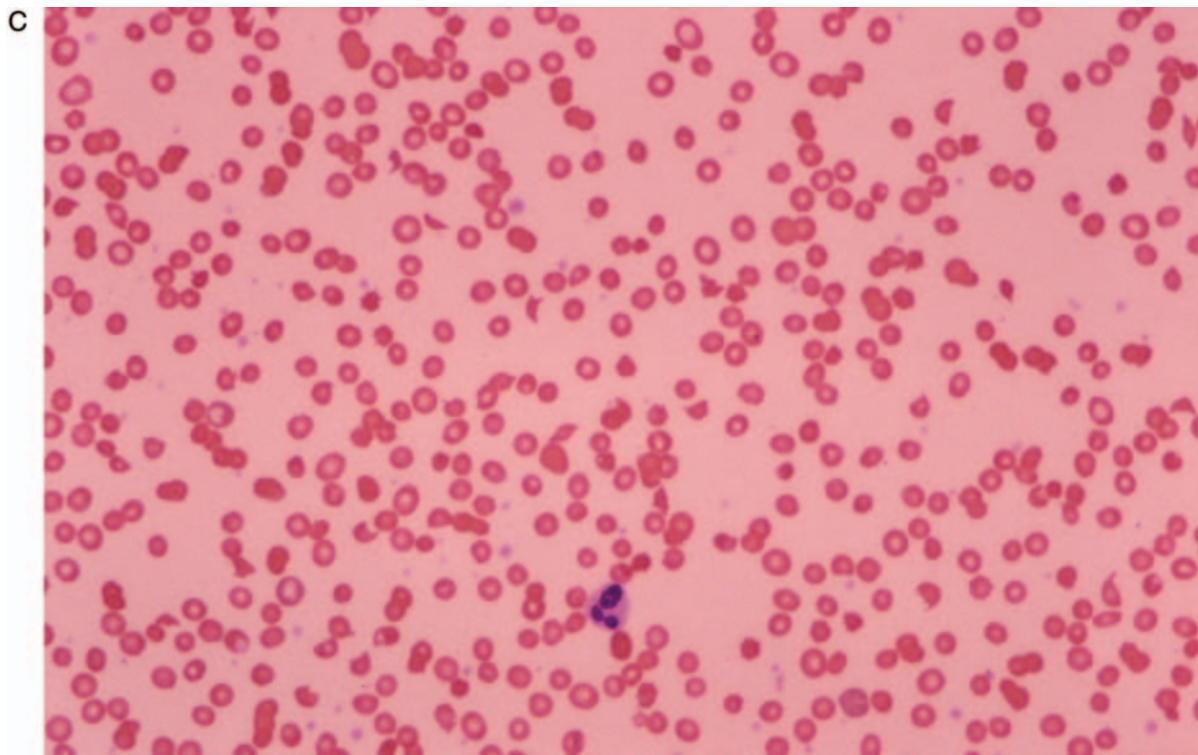


Figure 5. Continued.

three developed necrosis of bitten fingers, requiring amputation in one. Common systemic symptoms were nausea, abdominal pain and sweating. Haematemesis was recorded in one and haematuria in four cases. Four were treated with specific (Pasteur) antivenom, five were mildly anaemic at some stage, three had peripheral leukocytosis, three thrombocytopenia, while three showed a mild coagulopathy. A 17-year-old man bitten on the finger was admitted to hospital in Beer-Sheva, with local swelling, haemorrhagic blister and necrosis which required skin grafting. There was upper abdominal pain and vomiting. He had a leukocytosis of $15.4 \times 10^9/l$ and coagulopathy attributed to disseminated intravascular coagulation.²⁹ An 18-year-old woman also treated at Beer-Sheva had been bitten on the finger while playing with a *C. cerastes*. There was swelling which eventually involved the whole arm, bleeding from the fang marks and from venipuncture wounds, incoagulable blood (indefinitely prolonged prothrombin and partial thromboplastin times), thrombocytopenia and a haemoglobin concentration of only 9.1 g/dl, mild erythrocyte anisocytosis but no visible schistocytes. She was treated only with fresh frozen plasma and eventually made a full recovery. Renal and hepatic functions had remained normal.³⁰ Chippaux (1982) found that bites by these species were characterized by local inflammatory reaction and swelling which, however, showed little tendency to spread, unusually

acute pain and a tendency to develop local necrosis as early as three or four hours after the bite.³¹ About a dozen cases of bites by the Saharan sand viper (*Cerastes vipera*) have been reported.^{32,33} This species, which is much smaller than the desert horned vipers (maximum length ~ 35 cm compared to 90 cm), is capable of causing mild local and systemic envenoming but local necrosis, renal failure and systemic bleeding have not been observed.

Against this background of reported experience of *C. cerastes* bites, both the cases reported here, inflicted in Europe by captive Saharan horned vipers, were surprising for the life-threatening severity of envenoming. Like many other published cases, both patients developed massive swelling of the bitten limb, with bruising and, in Patient 1, a small area of necrosis. However, unlike the reported cases, both our patients showed evidence of profound coagulopathy, fibrinolysis and thrombocytopenia associated with haemolytic anaemia attributable to microangiopathic haemolysis. In both cases, there was acute renal failure requiring prolonged haemodialysis. In Patient 2, the clinical picture raised the possibility of haemolytic-uraemic-syndrome (HUS), but the evidence of marked coagulopathy in both cases strictly excludes this diagnosis.^{34–36}

How can the clinical findings in our cases be explained by what is known of the composition of *C. cerastes* venom? More than 30 studies have been

published on *C. cerastes* venom and, so far, more than 13 different toxins have been identified.³⁷ These include serine proteases and other thrombin-like enzymes (fibrinogenases) (IVa, Cerastocytin,^{38,39} Cerastotin,⁴⁰ RP3 4, Afaâcytin⁴¹ and Cerastase F-4), which are likely to be responsible for causing hypofibrinogenaemia in human victims; activators of platelet aggregation/agglutination (Cerastocytin, Cerastotin), which could cause thrombocytopenia and endothelial activation; inhibitors of platelet aggregation (IVa, Cerastatin,⁴² Cerastin), which could contribute to a bleeding tendency; Factor X activators (calcium-dependent and calcium-independent serine proteases, Afaâcytin), which could result in disseminated intravascular coagulation; a haemorrhagic protease (Cerastase F-4), which could cause spontaneous systemic bleeding; a protein C activator exerting a possible anticoagulant effect; and an α/β fibrinogenase, which releases serotonin from platelets (Afaâcytin); a phosphodiesterase exonuclease and a weakly toxic phospholipase A₂, which could contribute to local tissue damage.

Since some of these toxins exert opposing actions, the net effect, for example on platelets, may depend on the composition of the venom injected by a particular snake on a particular occasion. The large intraspecies variation in venom composition is now well recognized⁴³ and geographical variation in *C. cerastes* venom has been documented.⁴⁴ This has obvious implications for antivenom production and efficacy.

Micro-angiopathic haemolysis was a striking feature of both our cases (Figure 5). It is attributable to vascular endothelial damage and thrombin deposition on the walls of blood vessels, resulting in the distortion, damage and destruction of circulating erythrocytes. A direct action of venom enzymes, such as the phospholipase A₂, may have contributed to erythrocyte damage.

Acute renal failure is an expected consequence of this process, but in rats, the effects of sub-lethal doses of *C. cerastes* venom were interpreted as causing mesangial proliferative glomerulonephritis leading to acute tubular necrosis by direct nephrotoxicity and ischaemia. There was cortical necrosis resulting from thrombosis and bleeding.⁴⁵ However, in neither of our patients was renal biopsy justified, and so we have no information about histopathological changes.

In Patient 1, heparin was given for 24 h in an attempt to inhibit venom thrombin activity. However, the use of heparin as an ancillary treatment for snake-venom-induced coagulopathy is highly controversial. Thrombin-like activities of venoms are not inhibited by heparin,⁴⁶ and it

has never been proved effective in clinical trials,⁴⁷ even in victims of Russell's vipers (*Daboia russelii* and *D. siamensis*) envenoming in whom there is some slight theoretical basis for its use.⁴⁸ Heparin increases the risk of haemorrhage in victims of viper bites and should never be risked in the treatment of these patients.⁴⁹ Our Patient 1, who had pre-existing hypertension and peripheral vascular disease affecting the femoral and cerebral arteries, with a history of a previous stroke, developed neurological symptoms on the fourth day after the bite. Cerebral haemorrhage was later confirmed by MRI (Figure 3). There is a report of a stroke directly attributable to *C. cerastes* envenoming,²² but our patient's symptoms appeared at a time when the anti-haemostatic effects of envenoming and circulating level of venom had been controlled by two substantial doses of antivenom. This was about 48 h after heparin treatment had been stopped, but was temporally related to the administration of 0.25 mg of epinephrine subcutaneously as prophylaxis against an antivenom reaction.⁵⁰ In Australia, there was an inconclusive debate about the role of epinephrine in haemorrhagic strokes complicating bites by tiger and brown snakes.⁵¹ Premawardhena *et al.* (1999)⁵⁰ have qualified their earlier recommendation of routine prophylaxis with subcutaneous epinephrine, based on a controversial study,⁵² after a patient suffered a fatal stroke 10 h following epinephrine treatment.⁵³ His pre-existing pathology would have rendered our patient vulnerable to this rare complication of epinephrine, but causation is unproven.

In both of our patients, use of large doses of polyspecific antivenom with activity against *C. cerastes* venom proved decisive in curtailing the coagulopathy, but did not prevent the evolution of profound renal failure. This was also the case in victims of Russell's viper (*Daboia siamensis*) bite in Myanmar, even when antivenom was administered within 1–2 h of envenoming.⁴⁸

This clinical study has demonstrated the ability of *C. cerastes* to cause complicated and potentially fatal envenoming, a warning to those exotic-snake enthusiasts who keep this species in captivity, and to those who live, work, travel and go to war in its extensive eremic domain.

Acknowledgements

We are grateful to Professor Elazar Kochva for translations from the Hebrew, and to Dr P.L.F. Giangrande of the Oxford Haemophilia Centre and Thrombosis Unit for helpful discussion.

References

- Gasperetti J. Snakes of Arabia. *Fauna of Saudi Arabia* 1988; **9**:169–450.
- Mandaville J. The hooded *Malpolon*, *M. moilensis* (Reuss) and notes on other snakes of North-Eastern Arabia. *J Bombay Nat Hist Soc* 1967; **64**:115–17.
- Corkill NL. *Snakes and snake bite in Iraq. A Handbook for Medical Officers*. London, Bailliere Tindall & Cox, 1932.
- Keimer L. Notes au sujet de l'hiéroglyphe et des vipères dans l'Égypte ancienne. *Études d'Égyptologie* 1945; **7**:1–52.
- Keimer L. Histoires de serpents dans l'Égypte ancienne et moderne. *Mémoires présentés à l'Institut d'Égypte. Cairo, l'Institut Français d'Archéologie Orientale* 1947; **50**: 1–89, i–xxi.
- Nunn JF. *Ancient Egyptian Medicine*. London, British Museum Press, 1996.
- Kirk R. Poisonous snakes of the Sudan. *Sudan Wildlife and Sport* 1951; **2**:17–27.
- Jarcho S. The Correspondence of Morgagni and Lancisi on the Death of Cleopatra. *Bull Hist Med* 1969; **43**:299–325.
- Waterfield R (translator). *Herodotus: The Histories 2:74*. Oxford, Oxford University Press, 1998.
- Howe WW, Wells J. *A commentary on Herodotus*. Oxford, Oxford University Press, 2000.
- Anderson J. *Zoology of Egypt: reptilia and batrachia*. London, Quaritch, 1898.
- Corkill NL, Cochrane JA. The snakes of the Arabian Peninsula and Socotra. *J Bombay Nat Hist Soc* 1966; **62**:475–506.
- Werner YL, Leverdier A, Rosenman D, Sivan N. Systematics and zoo geography of *Cerastes* (Ophidia: Viperidae) in the Levant: 1. Distinguishing Arabian from African '*Cerastes cerastes*'. *The Snake* 1991; **23**:90–100.
- Doumergue F. *Essai sur la faune erpétologique de l'oranie*. Oran, Fouque, 1901.
- Werner YL, Sivan N. Systematics and zoo geography of *Cerastes* (Ophidia: Viperidae) in the Levant: 2. Taxonomy, ecology, and zoo geography. *The Snake* 1992; **24**:34–49.
- Calmette A. *Les venins des animaux venimeux et la sérothérapie antivenimeuse*. Paris, Masson, 1907.
- Phisalix M. *Animaux venimeux et venins*. Paris, Masson, 1922.
- Corkill NL. *Notes on Sudan snakes*. Sudan Government Museum (Natural History) Publication No 3, 1935.
- Sauneron S. *Un traité Égyptien d'ophiologie*. Cairo, Institut Français d'Archéologie Orientale, 1989.
- Myer WP, Habib AG, Onayade AA, Yakub A, Smith DC, Nasidi A, Daudu IJ, Warrell DA, Theakston RDG. First clinical experiences with a new ovine Fab *Echis ocellatus* snake bite antivenom in Nigeria: randomised comparative trial with Pasteur Ipsar Africa antivenom. *Am J Trop Med Hyg* 1997; **56**:291–300.
- Chavasse. Morsure de vipère à cornes suivie de mort. *Arch Méd Pharm Milit* 1891; **18**:494–8.
- Guyon M. Morsure du céraste ou vipère cornue. *Gazette Méd de Paris* 1862; Série XVII: 71–3.
- Schaumont M. Note sur le traitement des morsures de vipères à cornes. *Arch Méd Pharm Milit* 1883; **2**:99–102.
- Driout. Le permanganate de potasse, dans le traitement de la morsure des vipères à cornes par le Dr Driout. *Gazette médicale de l'Algérie* 1883; **28**:50–1.
- Escard L. Accidents consécutifs et la morsure d'une vipère à cornes—traitement par les injections hypodermiques de permanganate de potasse—Guérison. *Arch Méd Pharm Milit* 1889; **13**:203–7.
- Efrati P. Symptomatology, pathology and treatment of the bites of viperid snakes. In: Lee C-Y, ed. *Snake Venoms*. Berlin, Springer-Verlag, 1979:956–77.
- Path J, Ravid M. *Aspis cerastes* bite—case report. *Harefuah* 1971; **81**: 85–6.
- Shargil A, Shabat D, Rosenthal T. Clinical and laboratory findings in *Aspis cerastes* snake bite. *Harefuah* 1973; **85**:504–8.
- Shulzinska H, Keynan A, Dvilansky A. Effects of *Cerastes cerastes* snake bite on coagulation. *Harefuah* 1978; **94**:323–4.
- Lifshitz M, Kastel H, Harman-Boehm I. *Cerastes cerastes* envenomation in an 18 year old female: a case report. *Toxicon* 2002; **40**:1227–9.
- Chippaux J-P. Les complications locales des morsures de serpents. *Médecine Tropicale* 1982; **42**:177–83.
- Ben-Baruch N, Porath A, Kleiner-Baumgarten A, Keynan A. *Cerastes vipera* envenoming—a report of 7 cases. *Trans Roy Soc Trop Med Hyg* 1986; **80**:664.
- Lifshitz M, Kapelushnik J, Ben-Harosh M, Sofer S. Disseminated intravascular coagulation after *Cerastes vipera* envenomation in a three-year-old child: a case report. *Toxicon* 2000; **38**:1593–8.
- Chandler WL, Jelacic S, Boster DR, et al. Prothombotic coagulation abnormalities preceding the hemolytic-uremic syndrome. *New Eng J Med* 2002; **346**:23–32.
- Allford SL, Rose P, Machin SJ. Guidelines on the diagnosis and management of the thrombotic microangiopathic haemolytic anaemias. *Br J Haematol* 2003; **120**:556–73.
- Shah NT, Rand JH. Controversies in differentiating thrombotic thrombocytopenic purpura and hemolytic uremic syndrome. *Mount Sinai J Med* 2003; **70**:344–51.
- Theakston RDG, Kamiguti AS. A list of animal toxins and some other natural products with biological activity. *Toxicon* 2002; **40**:579–651.
- Marrakchi N, Zingali RB, Karoui H, Bon C, el Ayeb M. Cerastocytin, a new thrombin-like platelet activator from the venom of the Tunisian viper *Cerastes cerastes*. *Biochim Biophys Acta* 1995; **1244**:147–56.
- Marrakchi N, Barbouche R, Guermazi S, Bon C, el Ayeb M. Procoagulant and platelet-aggregating properties of cerastocytin from *Cerastes cerastes* venom. *Toxicon* 1997; **35**:261–72.
- Marrakchi N, Barbouche R, Guermazi S, Karoui H, Bon C, El Ayeb M. Cerastotin, a serine protease from *Cerastes cerastes* venom, with platelet-aggregating and agglutinating properties. *Eur J Biochem* 1997; **247**:121–8.
- Laraba-Djebari F, Martin-Eauclaire MF, Mauco G, Marchot P. Afaâcytin, an alpha beta-fibrinogenase from *Cerastes cerastes* (horned viper) venom, activates purified factor X and induces serotonin release from human blood platelets. *Eur J Biochem* 1995; **233**:756–65.
- Marrakchi N, Barbouche R, Bon C, el Ayeb M. Cerastatin, a new potent inhibitor of platelet aggregation from the

- venom of the Tunisian viper, *Cerastes cerastes*. *Toxicon* 1997; **35**:125–35.
43. Warrell DA. Geographical and intraspecies variation in the clinical manifestations of envenoming by snakes. *Symp Zool Soc London* 1997; **70**:189–203.
44. Hassan F, El-Hawary MF, Gazawi A, Anis A, Wanas S. Biochemical properties of Egyptian *Cerastes* venoms in relation to geographic distribution. *Zeitschrift fur Ernahrungswissenschaft* 1980; **19**:259–65.
45. Abd-el-Aal A, Fares NH. Renal alterations induced by *Cerastes cerastes cerastes* venom. *J Nat Toxins* 1998; **7**:45–71.
46. Nahas L, Kamiguti AS, Rzeppa HW, Sano IS, Matsunaga S. Effect of heparin on the coagulant action of snake venoms. *Toxicon* 1975; **13**:457–63.
47. Warrell DA, Pope HM, Prentice CRM. Disseminated intravascular coagulation caused by the carpet viper (*Echis carinatus*): trial of heparin. *Br J Haematol* 1976; **33**:335–42.
48. Myint-Lwin, Warrell DA, Phillips RE, *et al*. Bites by Russell's viper (*Vipera russelli siamensis*) in Burma: haemostatic, vascular, and renal disturbances and response to treatment. *Lancet* 1985; **ii**:1259–64.
49. Mahasandana S, Rungruxsirivorn Y, Chantarangkul V. Clinical manifestations of bleeding following Russell's viper and green pit viper bites in adults. *South East Asian J Trop Med Publ Health* 1980; **11**:285–93.
50. Premawardhena AP, de Silva CE, Fonseka MMD, Gunatilake SB, de Silva HJ. Low dose subcutaneous adrenaline to prevent acute adverse reactions to antivenom serum in people bitten by snakes: randomised, placebo-controlled trial. *Br Med J* 1999; **318**:1041–3.
51. Tibballs J. Pre-medication for snake antivenom. *Med J Austr* 1994; **160**:4–7.
52. Ball DE, Tisocki K. Prophylaxis against early anaphylactic reactions to snake antivenom. Stopping trials early may result in insufficient evidence being accrued. *Br Med J* 1999; **319**:920–1 (Correspondence).
53. Dissanayake AS, Karunanayake P, Kasturiratne KTAA, *et al*. Safety of subcutaneous adrenaline as prophylaxis against acute adverse reactions to anti-venom serum in snake bite. *Ceylon Med J* 2002; **47**:48–9.

