

Tracheal tube-tip displacement in children during head-neck movement—a radiological assessment[†]

M. Weiss^{1*}, W. Knirsch², O. Kretschmar², A. Dullenkopf¹, M. Tomaske², C. Balmer²,
K. Stutz¹, A. C. Gerber¹ and F. Berger^{2,3}

¹Department of Anaesthesia and ²Department of Cardiology, University Children's Hospital, Zurich, Switzerland. ³Department of Congenital Heart Disease, German Heart Centre, Berlin, Germany

*Corresponding author: Department of Anaesthesia, University Children's Hospital, Steinwiesstrasse 75, CH-8032 Zurich, Switzerland. E-mail: markus.weiss@kispi.unizh.ch

Background. Aims of this study were to assess the maximum displacement of tracheal tube tip during head-neck movement in children, and to evaluate the appropriateness of the intubation depth marks on the Microcuff Paediatric Endotracheal Tube regarding the risk of inadvertent extubation and endobronchial intubation.

Methods. We studied children, aged from birth to adolescence, undergoing cardiac catheterization. The patients' tracheas were orally intubated and the tracheal tubes positioned with the intubation depth mark at the level of the vocal cords. The tracheal tube tip-to-carina distances were fluoroscopically assessed with the patient supine and the head-neck in 30° flexion, 0° neutral position and 30° extension.

Results. One hundred children aged between 0.02 and 16.4 yr (median 5.1 yr) were studied. Maximum tracheal tube-tip displacement after head-neck 30° extension and 30° flexion demonstrated a linear relationship to age [maximal upward tube movement (mm)=0.71×age (yr)+9.9 ($R^2=0.893$); maximal downward tube movement (mm)=0.83×age (yr)+9.3 ($R^2=0.949$)]. Maximal tracheal tube-tip downward displacement because of head-neck flexion was more pronounced than upward displacement because of head-neck extension.

Conclusions. The intubation depth marks were appropriate to avoid inadvertent tracheal extubation and endobronchial intubation during head-neck movement in all patients. However, during head-neck extension the tracheal tube cuff may become positioned in the subglottic region and should be re-adjusted when the patient remains in this position for a longer time.

Br J Anaesth 2006; **96**: 486–91

Keywords: children; complications, intubation tracheal; equipment, tubes tracheal

Accepted for publication: January 3, 2006

Because of their short trachea, precise depth of tracheal tube insertion is mandatory in children in order to avoid either inadvertent tracheal extubation or endobronchial intubation during head-neck movement. Intubation depth marks on the majority of paediatric tracheal tubes were therefore introduced to allow tracheal tube positioning with the tracheal tube tip in the mid-tracheal position.¹ However, in the past, several authors reported on the inappropriateness of manufacturers' depth marks.^{2–4}

In the new Microcuff paediatric endotracheal tube (Microcuff PET, Microcuff GmbH, Weinheim, Germany), the intubation depth marks are placed so that the tracheal tube tip of an age-related tracheal tube becomes advanced to about 65% into the shortest trachea in this age group with the patient supine and the head in neutral position.^{5–7}

Systematically assessed data about tracheal tube tip displacement during head-neck manipulation in children are missing.

Thus, the aims of this study were to assess tracheal tube tip displacement during head-neck manipulation and to evaluate appropriateness of the Microcuff PET intubation

[†]*Declaration of interest.* The tracheal tubes studied were ordered from a local distributor. No financial support was obtained from the manufacturer for the presented study. M.W. is involved in designing paediatric tracheal tube cuffs made from polyurethane in co-operation with Microcuff GmbH, Weinheim, Germany and TYCO Health Care, R&D Athlone, Ireland. No agreements or financial benefits arise from these co-operations.

depth marks regarding inadvertent extubation and endobronchial intubation.

Methods

With Ethical Review Board approval and written parental consent, we included 100 consecutive paediatric patients, from birth up to 18 yr of age, undergoing cardiac catheterization under general anaesthesia using oro-tracheal intubation. After inhalation or i.v. induction of anaesthesia and complete neuromuscular block, the patients' tracheas were intubated with an age-related sized Microcuff PET.^{8,9} Tracheal tube sizes were selected according to Motoyama's formula for selection of cuffed tracheal tubes in children aged ≥ 2 yr [internal diameter (ID, in mm)=(age in yr: 4)+3.5].¹⁰ For patients below 2 yr of age tracheal tubes were chosen according to Khine's recommendations.¹¹ The tracheal tube depth mark was placed at the level of the vocal cords using direct laryngoscopy and the tube was taped to the right corner of the mouth. Afterwards, precise intubation depth mark position was re-confirmed with the head in neutral position by the attending consultant anaesthetist.

Fluoroscopic images were taken with the patient supine and the head without a pillow first in 30° flexion, second 0° in neutral and last in 30° extension position using a 30° angled jig. Neutral and 30° positions of the head were defined as vertical and 30° lines respectively from the external ear channel to the superior orbital margin (ear-eye-line). Head manipulations were performed with the tracheal tube disconnected from the anaesthetic circuit and the tracheal tube cuff fully deflated in order to not artificially restrict intra-tracheal tube displacement.

Calibration of the cardiac catheter laboratory X-ray measurement system (Philips Integris Allura 9/9 biplane system, Philips DA Best, Netherlands) was performed by electronically measuring the diameter (A) of a standard cardiac catheter placed in the pulmonary trunk, superior vena cava or ascending aorta on the radiograph. The electronically measured diameter (A) for each patient was compared against the known diameter of the cardiac catheter used and a magnification factor was calculated for each patient.

Measurements and calculations of the distance from the distal endpoint of the radiopaque line near the trachea tube tip (D) (Fig. 1) to the tracheal carina (E) were performed offline after the catheterization procedure for each of the three positions (Fig. 1). To obtain the effective distance from the real tracheal tube tip to the carina the electronically measured distances (C) from the end of radiopaque line of the tracheal tube (D) to the tracheal carina (E) were corrected first by the magnification factor and second for the clear, radiopaque free tracheal tube-tip portion, as provided by the manufacturer. Trachea length (vocal cords-to-carina distance) was calculated by adding the distance from the intubation depth mark to the tracheal tube tip with the

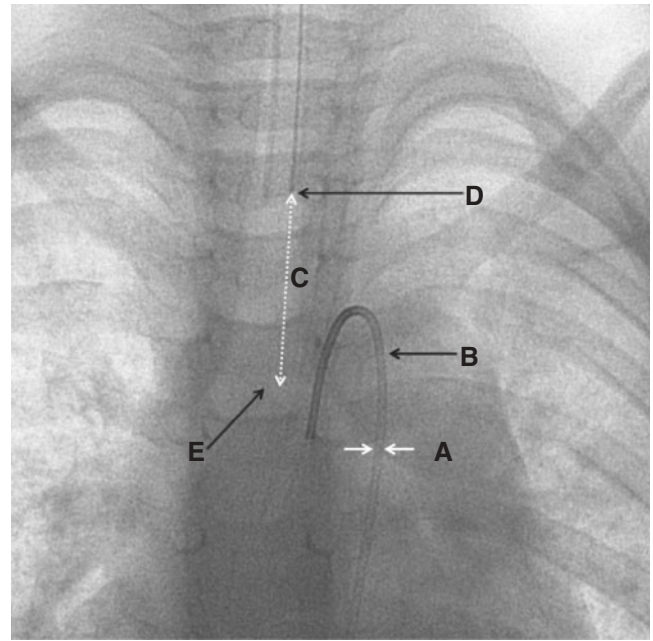


Fig 1 Calibration of the laboratory system was performed by electronically measuring the diameter (A) of a standard cardiac catheter on the radiograph (B) introduced into the pulmonary trunk, superior vena cava or ascending aorta. The distance (C) from the endpoint of the tube's radiopaque line (D) to the tracheal carina (E) was electronically measured and first corrected by the magnification factor and second corrected by subtraction of the clear, radiopaque free tracheal tube-tip portion, as provided by the manufacturer, to obtain the effective distance from the real tracheal tube tip to the carina.

effective distance from tracheal tube tip to carina, the head in 0° position.

Percent tracheal tube advancement into the trachea in relation to tracheal length was calculated with the head-neck in 30° flexion, neutral position and 30° extension. Data are presented as median (range).

A linear regression model using Microsoft Excel Software 2003 was used to relate maximal caudal and cranial tracheal tube tip displacement to age and height, and to calculate maximal downward tube-tip displacement after 30° head-neck flexion and maximal upward tube-tip movement after 30° head-neck extension for each age group.

Results

One hundred children (47 girls; 53 boys) aged between 0.02 and 16.4 (median 5.1) yr, undergoing cardiac catheterization were studied. In spite of large differences for magnitude of tracheal tube displacement between patients, head-neck extension consistently led to an upward movement of the tracheal tube tip whereas head-neck flexion moved the tracheal tube tip towards the carina.

Overall median (range) tracheal tube-tip advancement in the trachea in the neutral position was 53.4% (38.8–74.6%) of the tracheal length, decreasing to 42.5% (27.9–59.8%) in 30° head-neck extension, and increasing to 65.3%

Table 1 Calculated tracheal length and tracheal tube advancement in the trachea. Tracheal tube advancement was calculated for the patient supine and the head-neck in neutral position, in 30° flexion and in 30° extension as percent of tracheal length. Data are summarized as median (range). ID, internal diameter

Tube size ID (mm)	Patients (n)	Age (yr)	Tracheal length (mm)	Distance between depth-mark to tube-tip (mm)	Percent of tracheal length		
					Insertion depth at 30° flexion	Insertion depth at neutral position	Insertion depth at 30° extension
All	100	5.1 (0.02–16.4)	68.2 (36.4–116.4)	–	65.3 (43.9–88.1)	53.4 (38.8–74.6)	42.5 (27.9–59.8)
3.0	10	0.4 (0.02–0.9)	45.6 (36.4–52.2)	24	65.0 (50.1–74.0)	52.6 (46.0–65.9)	41.9 (28.1–56.0)
3.5	11	1.4 (1.1–1.9)	50.5 (41.8–60.5)	27	66.6 (52.9–84.9)	53.4 (44.6–64.6)	40.0 (36.4–55.3)
4.0	19	2.6 (2.0–3.9)	58.0 (49.2–73.9)	30	63.0 (48.4–77.1)	51.7 (40.6–61.0)	41.1 (27.9–48.9)
4.5	18	4.9 (4.0–5.9)	65.2 (49.4–87.6)	34	62.1 (43.9–88.1)	52.2 (38.8–68.8)	39.0 (30.9–52.0)
5.0	8	6.7 (6.2–7.6)	76.0 (52.3–94.7)	39	57.3 (52.2–88.0)	51.3 (41.2–74.6)	37.2 (29.7–53.5)
5.5	13	9.1 (8.0–9.9)	83.6 (67.0–98.1)	45	67.3 (52.3–85.0)	53.8 (45.9–67.2)	44.4 (36.1–52.4)
6.0	9	10.4 (10.0–11.9)	83.4 (72.8–105.4)	50	69.9 (62.4–86.7)	60.0 (47.4–68.7)	42.9 (28.2–59.8)
6.5	6	13.0 (12.1–13.7)	90.8 (82.2–116.4)	54	59.5–77.6 (73.5)	46.4–65.7 (59.4)	47.4 (33.4–54.4)
7.0	6	15.5 (14.4–16.4)	103.4 (82.9–114.6)	58	62.0–79.0 (71.3)	50.6–70.0 (56.1)	45.9 (34.4–56.1)

Table 2 Maximal measured and extrapolated $*[y \text{ (mm)}=0.71 \times \text{yr}+9.9]$ downward tube-tip displacement after 30° head-neck flexion and maximal measured and extrapolated $**[y \text{ (mm)}=0.83 \times \text{yr}+9.3]$ upward tube-tip movement after 30° head-neck extension. Minimal tube tip to carina distance calculated for the construction of the Microcuff PET and distance between depth-mark and upper border of the cuff in Microcuff PET are given.⁵ ID, internal diameter

ID (mm)	Patients (n)	Age median (range) (yr)	Maximal downward tube-tip displacement		Minimal distance between tube-tip to carina (mm)	Maximal upward tube-tip displacement		Distance between depth-mark and upper border of the cuff (mm)
			(mm)	(mm)*		(mm)	(mm)**	
3.0	10	0.4 (0.02–0.9)	9.7	10.6	15.4	9.8	10.1	9
3.5	11	1.4 (1.1–1.9)	10.0	11.3	16.0	8.5	11.0	10
4.0	19	2.6 (2.0–3.9)	10.7	12.8	16.6	12.9	12.6	12
4.5	18	4.9 (4.0–5.9)	14.8	14.2	19.8	14.5	14.3	12
5.0	8	6.7 (6.2–7.6)	14.1	15.6	22.0	14.0	15.9	16
5.5	13	9.1 (8.0–9.9)	17.5	17.0	23.2	18.5	17.6	16
6.0	9	10.4 (10.0–11.9)	21.2	18.5	25.4	20.3	19.2	18
6.5	6	13.0 (12.1–13.7)	16.4	19.9	28.5	19.9	20.9	19
7.0	6	15.5 (14.4–16.4)	20.0	21.3	31.7	22.0	22.6	22

(43.9–88.1%) in 30° head-neck flexion (Table 1). Maximal displacement distances for each age group are given in Table 2.

Maximum tracheal tube-tip displacement after head-neck extension and flexion demonstrated a linear relationship to age and height (Fig. 2). Maximal tracheal tube-tip downward displacement because of head-neck flexion was more pronounced than upward displacement because of head-neck extension. No intra-subject correlation was found between the amount of upward and downward tracheal tube tip displacement ($R^2=0.192$).

Discussion

In this study we assessed tracheal tube-tip displacement during head-neck manipulation in children aged from birth to adolescence and evaluated the appropriateness of the so far unapproved intubation depth marks of the Microcuff paediatric tracheal tube.

The main findings were that tracheal tube-tip displacement because of head-neck movement demonstrated large inter-individual differences with larger values for head-neck extension than for head-neck flexion. However, the

intubation depth marks were correct in preventing both inadvertent endobronchial intubation and inadvertent tracheal extubation, respectively.

Head-neck extension during anaesthesia in tracheally intubated children is common during ENT surgery, dental or cleft surgery as well as during lifting and turning a child. Marked flexion of the head-neck is used during neurosurgery for posterior fossa craniotomies, during lumbar puncture or after tracheo-oesophageal fistula repair. Furthermore, patients requiring mechanical ventilation because of various reasons in the intensive care unit undergo significant head-neck movement during their health care management. Because of their short trachea, the margin of safety for tracheal tube-tip displacement is definitely decreased in children. In case of tracheal tube misplacement, children are easily at risk for inadvertent endobronchial intubation or accidental extubation.¹² As demonstrated by our study, head-neck flexion consistently results in a movement of the tracheal tube tip towards the carina, and head-neck extension moves the tracheal tube tip away from the carina. This observation is similar to the results reported by other authors^{13–16} (Table 3) and is easily explained by the anatomy of airway and cervical vertebral column. With

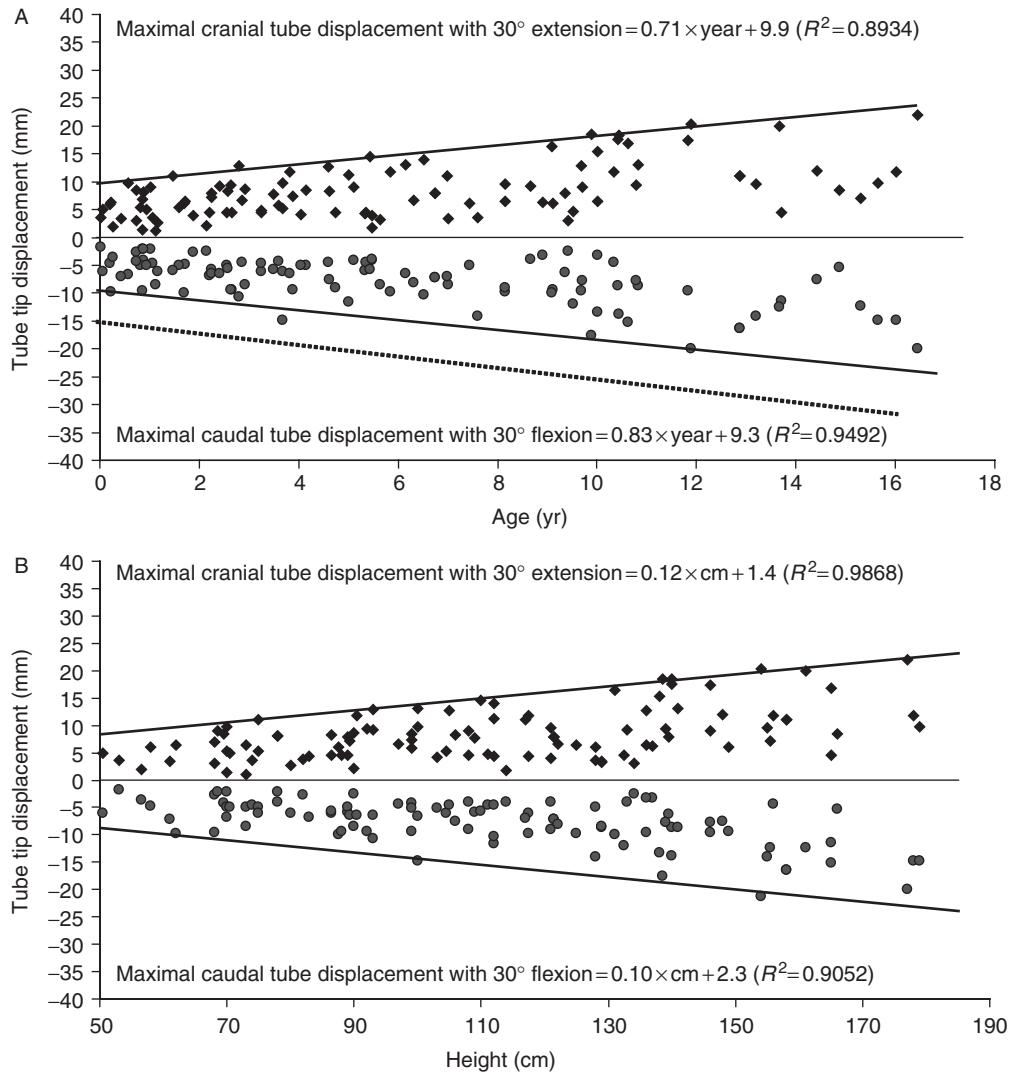


Fig 2 Thick upper and lower line indicates maximal tube tip displacement measured during 30° flexion (squares) and 30° extension (dots) of head and neck. The dotted line in the upper diagram indicates the minimal calculated distance from the tracheal tube-tip to the carina when the intubation depth-mark is placed at the glottic level ($n=100$).

head-neck extension the airway placed in front of the cervical vertebral column represents the outer arc with a greater circumference. The tracheal tube with its defined length and being taped at the mouth will move with its tip within the trachea away from the carina. During flexion the airway is considered as the inner arc and becomes shorter. Consecutively, the tracheal tube with its constant length will move within the airway towards the carina. Various explanations where exactly tracheal tube displacement takes place during head-neck manipulations have been discussed.¹³⁻¹⁵

Based on our measurements the concept of the Microcuff PET intubation depth marks, namely aiming to advance the tracheal tube to about 65% into the shortest trachea in a related age group, avoided both endobronchial intubation during 30° head-neck flexion, and inadvertent tracheal extubation during 30° head-neck extension in all patients studied.^{8,10,11} Maximal caudal tracheal tube-tip displacement during head-neck flexion was less than the calculated

margin of safety regarding endobronchial intubation (Table 2). This is an important advantage of this newly designed tracheal tube compared with conventional paediatric cuffed tracheal tubes, in which a low margin of safety regarding inadvertent endobronchial intubation was reported, even with the cuff placed just below the vocal cords.^{16,17}

Whereas in uncuffed tracheal tubes head-neck extension is only of importance regarding inadvertent tracheal extubation, in cuffed tracheal tubes the position of the cuff is of interest in these situations with regard to possible injury of the vocal cords.¹⁷⁻¹⁹ In the Microcuff PET the cuff could be designed very short, because of its improved sealing capability^{5,9} and is placed very distally on the tracheal tube shaft. However, our data reveal that maximal cranial tracheal tube-tip displacement during head-neck extension was similar to the distance from the intubation depth mark to the upper border to the cuff in some

Table 3 Literature review: head-neck movement and tracheal tube-tip displacement. Data are mean (sd) [range] or maximal values, as available. Rx, radiography; FOB, fibreoptic bronchoscopy; NA, data not available

Authors	n	Patient characteristics	Intubation route	Investigation technique	Flexion		Extension		Flexion-extension	
					mm	Angle	mm	Angle	mm	Angle
Todres and colleagues ²¹	16	Neonates (0.91–3.14 kg)	10× oral 6× nasal	Rx Rx					14.3 (4.83) 16.8 (5.98)	NA
Donn and Blane ²⁷	1	Neonate (1.1 kg)	1× oral 1× nasal	Rx Rx	–8 –8.5	NA NA	4.5 11	NA NA		
Rost and colleagues ²⁸	8	560–2100 g	8× oral	Rx	3.1 (1.7)	55°	7.4 (5.2)	55°		
Rotschild and colleagues ²⁶	9	Neonates (<1000 g)	9× oral 9× nasal	Autopsy Autopsy	–15 –10	Full Full	8 13	Full Full		
	15	Neonates (>1000 g)	15× oral 15× nasal	Autopsy Autopsy	–10 –16	Full Full	15 16	Full Full		
Roopchand and colleagues ²⁵	13	Neonates (660–5200 g)	13× oral	Rx	–6.7 (1.7) [–5, –10]	Full	7.2 (1.9) [5, 10]	Full		
Trout and colleagues ²⁴	1	Child 12 months	1× oral	Rx					2.7	NA
Kim and colleagues ²⁰	25	Children 2–8 yr	25× oral	FOB	–10 (5) [–2, –21]	Full	20 (6) [8, 36]	Full		
Sugiyama and Yokoyama ²²	10	Children 16–19 months 8.2–11.2 kg	10× oral	FOB	9 (2) [–12, –6]	Full	9 (5) [3, 15]	30°	17 (7) [6, 25]	30°
			10× oral	FOB		Full	17 (4) [10, 24]	45°	25 (6) [16, 34]	45°
Olufolabi and colleagues ²³	15	Children <10 kg	15× oral 15× nasal	Rx Rx	–1.9 (9.2) –6.3 (6.0)	NA NA	6.5 (6.0) 3.5 (3.6)	NA NA		
	15	Children 10–20 kg	15× oral 15× nasal	Rx Rx	–10.3 (0.1) –8.6 (4.7)	NA NA	14.2 (4.8) 9.5 (7.0)	NA NA		
	15	Children >20 kg	15× oral 15× nasal	Rx Rx	–10.1 (0.2) –11.5 (3.8)	NA NA	13.8 (7.2) 7.2 (5.1)	NA NA		
Yap and colleagues ³⁰	50	Adults	50× oral	FOB	5.5 (8.7) [–23, 19]	30°	6.3 (12.0) [–21, 33]	30°		
Hartrey and Kestin ²⁹	20	Adults	20× nasal 20× oral	FOB FOB	–14.1 (9.1) [–32, 3] –15.3 (8.1) [–32, 1]	NA NA	8.6 (7.4) [–5, 21] 8.7 (9.3) [–7, 25]	NA NA		NA
Conrady and colleagues ¹⁴	20	Adults	5× oral 15× nasal	Rx Rx	–1.5 [–5, –20] –21 [0, –31]	NA NA	17 [–2, 52] 24 [13, 43]	NA NA	39 [–32, –50] 5 [0, 22]	NA NA

patients (Table 2). This implicates, that the cuff may become placed within the larynx during head-neck extension, representing a major problem of cuffed tracheal tubes in children, because there is only limited space beyond the depth mark to keep a cuff free subglottic portion of the tracheal tube shaft.

Recently, Kim and colleagues²⁰ have reported that the trachea itself shows a significant elongation during head-neck extension which mimics tracheal tube-tip movement away from the carina, so that the tracheal tube cuff does not effectively move to this extent. Nevertheless, intra-laryngeal cuff placement should be avoided as this is known to cause laryngeal damage. Therefore, in case of extension of the head-neck, the tracheal tube should be re-adjusted according to the depth mark after finally positioning the head. Surely, there is further potential to improving most paediatric cuffed tracheal tubes by shorter cuffs and more distal cuff placement.

So far, no systematically obtained data regarding tracheal tube-tip displacement because of head-neck manipulation in children ranging from birth to adolescence are available. In most of the studies only a certain group of patients (low birth weight patients, preterms, neonates, infants, children

and adults) was assessed^{12–15 19 21–30} (Table 3). In most of these studies the angle of the head-neck movement has not been standardized nor defined nor were maximum values indicated. Nevertheless, most of these study results were similar to our findings, except those from Yap and colleagues³⁰ in which the direction of the tracheal tube-tip movement was not consistent for both, head-neck extension and flexion. This may be explained by the fact, that the tracheal tube does not automatically return to the initial position when flexion and extension are started from neutral position. Thus, investigations should be started in flexion followed by the neutral position and then extension or vice versa.

We have only assessed head-neck extension-flexion at 30° which can be stated as a limitation of our study. It is conceivable that further extension of the head, with the occipital lowered below the horizontal line, as it is used for rigid oesophagoscopy, may result in even more pronounced tracheal tube-tip movement. Furthermore, we did not assess possible other results of movements if started with head-neck extension, continue with neutral position and end up with flexion. Otherwise a significant advantage of this study design was that a single operator performed the

defined head-neck extension. Also calibration and measurement of the distances were performed by a single investigator. Whether there may be a potential further movement of the tube tip, if a second measurement time point would have been chosen, cannot be excluded.

In conclusion the insertion depth marks of the newly designed Microcuff paediatric tracheal tube were appropriate in avoiding both inadvertent tracheal extubation and endobronchial intubation during head-neck movement in all patients. However, during head-neck extension the tracheal tube cuff may become positioned in the subglottic region and should therefore be re-adjusted.

References

- 1 Loew A, Thibeault D. A new and safe method to control the depth of endotracheal intubation in neonates. *J Pediatr* 1974; **54**: 506–8
- 2 Wallace CJ, Bell GT. Tracheal tube markings. *Paediatr Anaesth* 2001; **14**: 279–85
- 3 Goel S, Lim SL. The intubation depth marker: the confusion of the black line. *Paediatr Anaesth* 2003; **13**: 579–83
- 4 Weiss M, Dullenkopf A, Gysin C, Dillier C, Gerber AC. Shortcomings of paediatric cuffed endotracheal tubes. *Br J Anaesth* 2003; **92**: 78–88
- 5 Weiss M, Dullenkopf A, Gerber AC. Microcuff pediatric tracheal tube. A new tracheal tube with a high volume-low pressure cuff for children. *Anaesthesist* 2004; **53**: 73–9
- 6 Griscom NT, Wohl MEB. Dimensions of the growing trachea related to age and gender. *Am J Radiol* 1986; **146**: 233–7
- 7 Pettersson H, Ringertz H. *Measurements in Pediatric Radiology*. London: Springer, 1991; 103–5
- 8 Weiss M, Gerber AC, Dullenkopf A. Appropriate placement of intubation depth marks in a new cuffed paediatric tracheal tube. *Br J Anaesth* 2005; **94**: 80–7
- 9 Dullenkopf A, Gerber AC, Weiss M. Tracheal sealing characteristics of a new paediatric tracheal tube with high volume–low pressure polyurethane cuff. *Acta Anaesthesiol Scand* 2005; **49**: 232–7
- 10 Motoyama EK. Endotracheal intubation. In: Motoyama EK, Davis PJ, eds. *Smith's Anesthesia for Infants and Children*. St Louis: CV Mosby Co., 1990; 272–5
- 11 Khine HH, Corrdry DH, Kettrick RG, et al. Comparison of cuffed and uncuffed endotracheal tubes in young children during general anesthesia. *Anesthesiology* 1997; **86**: 627–31
- 12 Kuhn LR, Poznanski AK. Endotracheal tube position in infants. *J Pediatr* 1971; **78**: 991–6
- 13 Donn SM, Kuhns LR. Mechanism of endotracheal tube movement with change of head position in the neonate. *Pediatr Radiol* 1980; **9**: 37–40
- 14 Conrady PA, Goodman LR, Lainge F, Singer MM. Alteration of endotracheal tube position. *Crit Care Med* 1976; **4**: 8–12
- 15 Toung TJ, Grayson R, Saklad J, Wang H. Movement of the distal end of the endotracheal tube during flexion and extension of the neck. *Anesth Analg* 1985; **64**: 1030–2
- 16 Ho AMH, Aun CST, Karmakar MK. The margin of safety associated with the use of cuffed paediatric tracheal tubes. *Anaesthesia* 2002; **57**: 173–5
- 17 Holzki J. Tubes with cuffs in newborn and young children are a risk! *Anaesthesist* 2002; **51**: 321–3
- 18 Dillier CM, Trachsel D, Baulig W, Gysin C, Gerber AC, Weiss M. Laryngeal damage due to an unexpectedly large and inappropriately designed cuffed pediatric tracheal tube in a 13-month-old child. *Can J Anaesth* 2004; **51**: 72–5
- 19 Cavo JW. True vocal cord paralysis following intubation. *Laryngoscope* 1985; **95**: 1352–9
- 20 Kim JH, Do SH, Kim YL, Ham BM, Yum KW. Elongation of the trachea during neck extension in children: implication in the safety of endotracheal tube. *Eur J Anaesthesiol* 2005; **22** Suppl 34: A–568
- 21 Todres ID, deBros F, Kramer SS, Moylan FMB, Shannon DC. Endotracheal tube displacement in the newborn. *J Pediatr* 1976; **89**: 126–7
- 22 Sugiyama K, Yokoyama K. Displacement of the endotracheal tube caused by change of head position in pediatric anesthesia. Evaluation of fiberoptic bronchoscopy. *Anesth Analg* 1996; **82**: 251–3
- 23 Olufolabi AJ, Charlton GA, Spargo PM. Effect of head posture on tracheal tube position in children. *Anaesthesia* 2004; **59**: 1069–72
- 24 Trout S, Aaron J, Zapata-Sirvent RL, Hansborough JF. Influence of head and neck position on endotracheal tube tip position on chest X-ray examination: a potential problem in the infant undergoing intubation. *J Burn Care Rehabil* 1994; **15**: 405–7
- 25 Roopchand R, Roopnarinesingh S, Ramsewak S. Instability of the tracheal tube in neonates. A postmortem study. *Anaesthesia* 1989; **44**: 107–9
- 26 Rotschild A, Chitayat D, Puterman ML, Phang MS, Ling E, Aldwin V. Optimal positioning of endotracheal tubes for ventilation of preterms infants. *Am J Dis Child* 1991; **145**: 1007–12
- 27 Donn SM, Blane CE. Endotracheal tube movement in the preterm neonate: oral versus nasal intubation. *Ann Otol Rhinol Laryngol* 1985; **94**: 18–20
- 28 Rost JR, Frush DP, Auten RL. Effect of neck position on endotracheal tube location in low birth weight infants. *Pediatr Pulmonol* 1999; **27**: 199–202
- 29 Hartrey R, Kestin IG. Movement of oral and nasal tracheal tubes as a result of changes in head and neck position. *Anaesthesia* 1995; **50**: 682–7
- 30 Yap SJ, Morris RW, Pybus DA. Alterations in endotracheal tube position during general anaesthesia. *Anaesth Intensive Care* 1994; **22**: 586–8