

Peripheral Facial Nerve Palsy in Severe Systemic Hypertension: A Systematic Review

Rinaldo Jörg,¹ Gregorio P Milani,² Giacomo D. Simonetti,³ Mario G. Bianchetti,¹ and Barbara Goeggel Simonetti⁴

BACKGROUND

Signs of nervous system dysfunction such as headache or convulsions often occur in severe systemic hypertension. Less recognized is the association between severe hypertension and peripheral facial nerve palsy. The aim of this study was to systematically review the literature on the association of peripheral facial palsy with severe hypertension.

METHODS

Systematic review of Medline, Embase, Web of Science, and Google Scholar from 1960 through December 2011 and report of two cases.

RESULTS

The literature review revealed 24 cases to which we add two cases with severe hypertension and peripheral facial palsy. Twenty-three patients were children. Palsy was unilateral in 25 cases, bilateral in one case, and

recurred in nine. The time between the first facial symptoms and diagnosis of hypertension was a median of 45 days (range, 0 days–2 years). In five case series addressing the complications of severe hypertension in children, 41 further cases of peripheral facial palsy were listed out of 860 patients (4.8%).

CONCLUSIONS

The association between severe hypertension and peripheral facial palsy is mainly described in children. Arterial hypertension is diagnosed with a substantial delay. Outcome is favorable with adequate antihypertensive treatment. The pathophysiology is still debated.

Keywords: arterial hypertension; blood pressure; children; hypertension; hypertensive emergency; peripheral facial paralysis; systematic review.

doi:10.1093/ajh/hps045

Peripheral facial nerve palsy typically presents with weakness of all muscles of the face: The facial creases and nasolabial fold disappear, the forehead unfurrows, and the corner of the mouth droops. In more severe cases, the eyelid does not close and on attempted closure the Bell's phenomenon with the eye rolling upward becomes noticeable. Acute peripheral facial nerve palsy may result from infectious conditions such as Lyme disease, otitis media, chickenpox, herpes zoster oticus, mumps, and mononucleosis; from noninfectious, presumably inflammatory disorders such as the Melkersson-Rosenthal syndrome; and from traumas or neoplasms. However most cases present without an apparent cause and are classified as Bell's palsy.¹ There is also an association between peripheral facial nerve palsy and severe systemic hypertension, as was first described by Moxon more than a century ago.²⁻³ We systematically review the literature on this entity and report on two children in whom facial nerve palsy led to the detection of severe systemic hypertension.

METHODS

The US National Library of Medicine, Embase, Web of Science, and the web-based search engine Google Scholar were searched using the terms *arterial hypertension*, *systemic hypertension*, and *malignant hypertension*, each combined with *peripheral facial nerve paralysis* and *Bell paralysis*, limiting the search to publications in English, German, and Italian dating from January 1960 to December 2011. If the publication was available as a full-length article or a letter, if the patients included were individually described revealing at least age, sex, and blood pressure (BP) measurement in the hypertensive range; if the facial palsy was specified as being of the peripheral type, the publication was included in this study. From each case of severe systemic hypertension complicated by peripheral facial nerve palsy, two authors (R.J. and G.P.M.) independently excerpted the patients' clinical characteristics including information on the underlying cause of systemic hypertension, family and previous

Correspondence: Giacomo D. Simonetti (giacomo.simonetti@insel.ch).

Initially submitted July 23, 2012; date of first revision October 24, 2012; accepted for publication October 29, 2012.

¹Division of Pediatrics, Mendrisio and Bellinzona Hospitals and University of Berne, Switzerland; ²Pediatric Emergency Unit, Clinica Pediatrica De Marchi, Fondazione IRCCS Ca' Granda Ospedale Maggiore Policlinico, Milan, Italy; ³Pediatric Nephrology, University Children's Hospital Berne and University of Berne, Switzerland; ⁴Pediatric Neurology, University Children's Hospital Berne and Department of Neurology, University Hospital Berne and University of Berne, Switzerland.

© American Journal of Hypertension, Ltd 2013. All rights reserved. For Permissions, please email: journals.permissions@oup.com

personal history, further investigations performed, such as neuroimaging, treatment modalities applied, and critically appraised the publications.

The time to diagnosis was defined as the time elapsed between the first facial symptoms and the diagnosis of arterial hypertension. Severe hypertension was defined as a BP exceeding the 99th percentile by >5 mm Hg in children or 180/110 mm Hg in adults.⁴ For each patient the extent of severe hypertension was expressed by means of the modified BP severity index, which is calculated dividing the measured BP (in mm Hg) by either the calculated 99th percentile BP value specific for that patient plus 5 mm Hg in children or by 180/110 mm Hg in adults. The facial nerve dysfunction was graded as mild in subjects with preserved eye closure and severe in those with impaired eye closure.

Written informed consent for publication of information regarding the two described cases was obtained from both patients' parents.

Continuous data are presented as median values with interquartile range (IQR) or minimum and maximum range, and categorical data as frequencies and percentages calculated from the results reported in the original publications. Correlation analyses were performed with the Spearman test. Comparison of prevalence between the groups was performed using the Fisher exact test. All the statistical analyses were performed with GraphPad Prism, version 4.01 for Windows (GraphPad Software, San Diego, CA).

RESULTS

Systematic review of the literature

The systematic review revealed 326 publications, of which 282 remained after excluding duplicates. Fifteen publications met the inclusion criteria. The references of these 15 reports revealed three further publications meeting the inclusion criteria. In total, 18 reports were included in this study (17 in English, one in Italian) describing 24 cases.⁵⁻²² All publications included were reports of single cases or case series.

Finally, we found 41 additional cases of peripheral facial nerve palsy in five publications which specifically addressed the neurological signs of severe systemic hypertension in pediatric patients. These cases were only listed and not described in detail, permitting only analysis of prevalence.^{14, 23-26}

Case reports

Case 1. A previously healthy 5-year-old boy developed left facial muscular weakness, which spontaneously recovered over two months. At this time BP was not measured. Three months later he was referred because of headache, nocturia, and a similar facial weakness on the same side. The physical examination disclosed left-sided peripheral facial nerve palsy with normal facial symmetry and tone at rest, four-limb BP of 220/160 mm Hg, and bilateral retinal hemorrhages and tortuous vessels on fundoscopy. Urinalysis disclosed pathological proteinuria (++) and mild erythrocyturia. Electrocardiography and echocardiography revealed

left ventricular hypertrophy. Blood investigations showed a normal complete blood cell count and renal profile, a normal circulating complement C3 level, and absent antinuclear and antineutrophil autoantibodies. The final diagnosis of segmental renal hypoplasia with systemic hypertension was made by means of renal ultrasound and, subsequently, contrast-enhanced abdominal computed tomography, which revealed a segmental cortical thinning and dilated calices in the upper part of the right kidney. A voiding cystourethrography failed to detect a vesicoureteral reflux. The BP was gradually brought under control, initially with intravenous labetalol, later on medication with ramipril and chlortalidon. After 2 weeks, BP values were slightly below the 95th percentile (108/69 mm Hg). The facial nerve paresis resolved after BP was brought under control and completely within 2 months. One year later, BP remained within normal range and further neurological complications were not observed.

Case 2. In a previously healthy 11-year-old girl with sudden onset of left facial weakness and negative serologic testing for Lyme disease, the suspected diagnosis of idiopathic peripheral facial nerve paresis was made and oral prednisone (1 mg per kg body weight per day for 7 days) prescribed. At this time BP was not measured. Ten days later the girl experienced a generalized tonic-clonic seizure and was admitted to hospital. Physical examination revealed a left-sided peripheral facial nerve paresis (with normal facial symmetry and tone at rest), four-limb BP of 230/170 mm Hg, bilateral retinal hemorrhages and tortuous vessels on fundoscopy, and an epigastric systolic bruit. Urinalysis disclosed pathological proteinuria (+/++) and erythrocyturia. Electrocardiography and echocardiography revealed a left ventricular hypertrophy. Blood investigations showed a normal complete blood cell count and renal profile, and a negative autoimmune profile. The BP was gradually brought under better control (after 1 week BP was 123/84 mm Hg), initially with intravenous labetalol, later on combined medication with amlodipine and chlortalidon. Renal angiography disclosed a proximal left renal artery stenosis secondary to a fibromuscular dysplasia that was successfully treated by angioplasty. The facial nerve paresis resolved within 6 weeks, after having brought BP under control (at that time BP was 115/74 mm Hg). On follow-up, after 6 months, antihypertensive treatment could be tapered off and BP remained within the normal range 1 year later.

Analysis of all cases

Demographics. Of the 24 patients reported in the literature and the presented two cases with severe systemic hypertension complicated by peripheral facial nerve palsy, 16 were female, 10 male. Median age was 9.5 years (IQR, 2.5–12 years; range, 11 weeks–62 years). Twenty-three patients (88%) were children 15 years of age or younger (Table 1, Figure 1). The mean modified severity index of arterial BP was 1.67 (IQR, 1.39–1.73)/1.58 (IQR, 1.36–1.84).

Characteristics of peripheral facial palsy. At presentation the facial palsy was unilateral in 25 cases (left-sided, $n = 14$;

Table 1. Characteristics of 26 patients^a with severe hypertension and peripheral facial nerve paresis

Reference number	Age (years)	Gender	Additional presenting symptoms	Blood pressure (mm Hg)	Underlying disease	Treatment other than antihypertensive medication	Neuroimaging	Recurrence of facial palsy	Time to resolution of palsy	Resolution of palsy
Case I	5	M	H	220/160	CAKUT	No		Yes	2 months	Complete
Case II	11	F	C	230/170	Renal artery stenosis	Renal angioplasty			1.5 months	Complete
5	47	M	A, O, V	216/142	Primary hypertension	No	MRI: Ischemic infarct of dorsal pons		?	?
6	9	F	A, C, H, O, V	200/150	CAKUT	No	MRI: Pontine hemorrhage	Yes	0.5 months	Complete
7	5	M	A	260/175	Pheochromocytoma	No		Yes	Died after 4 months	—
8	62	F	—	220/98	Renal artery stenosis	No	CT: No acute changes, persistent chronic lesions	Yes	6 months	Partial
9	11	F	H, F, V	215/135	Primary hypertension	No	MRI: Hypertensive encephalopathy	Yes	0.5 months	Almost complete
10	14	F	H	230/150	Renal adenocarcinoma	No		Yes	1 month	Complete
11	10	M	H	140/100	Guillain-Barré syndrome	No		Yes	6 months	Complete
12	42	F	—	200/150	Primary hypertension	No		Yes	?	?
13	0.9	F	—	200/160	Mid aortic syndrome	No			6 months	Complete
14	1	M	—	240/130	Malignant hypertension of unknown origin	No			2 months	Complete
15—I	0.2	M	—	133/94	Coarctation	Surgical correction	MRI: Normal		Few days	Complete
15—II	13	M	—	218/122	Coarctation	Surgical correction			Few days	Complete
16	0.3	M	—	200/-	Coarctation	No			3 weeks	Complete
17—I	10	F	—	190/130	Primary hypertension	No		Yes	Several months	Complete
17—II	7	F	—	192/120	CAKUT	Nephrectomy			3 months	Complete
17—III	10	F	O	205/153	CAKUT	No	MRI: Multiple ischemic bilateral insular, occipital and basal ganglia infarcts		9 months	Almost complete
18	4	M	O	270/160	Renal artery stenosis	Surgical correction	MRI: Ischemic nucleus lenticularis and periventricular infarcts	Yes	12 months	Complete
19—I	5	F	H, O	130/100	Guillain-Barré syndrome	IVIg	MRI: Enhancement of the lumbosacral spinal nerve roots		4 months	Partial
19—II	3	F	O	126/110	Guillain-Barré syndrome	IVIg	MRI: Enhancement of the lumbosacral spinal nerve roots		3 months	Complete
20—I	12	F	V	220/140	CAKUT	No	CT: Normal		6 months	Complete
20—II	13	F	—	200/140	CAKUT	No	MRI: Normal		8 months	Complete
21—I	0.7	F	C	220/170	CAKUT	Nephrectomy and facial nerve decompression			1 months	Complete
21—II	12	F	H, V	230/170	?	No			Several weeks	Complete
22	1	M	C	220/120	?	No		Yes	1 months	Complete

Abbreviations: A, altered mental status; C, convulsions; CAKUT, congenital anomalies of the kidney and urinary tract; CT, computed tomography; F, fatigue; H, headache; IVIG, intravenous immunoglobulines; MRI, magnetic resonance imaging; O, other central neurological manifestations; V, vomiting.
^aSixteen female and 10 male subjects, aged between 0.2 and 62 years (median, 9.5 years).

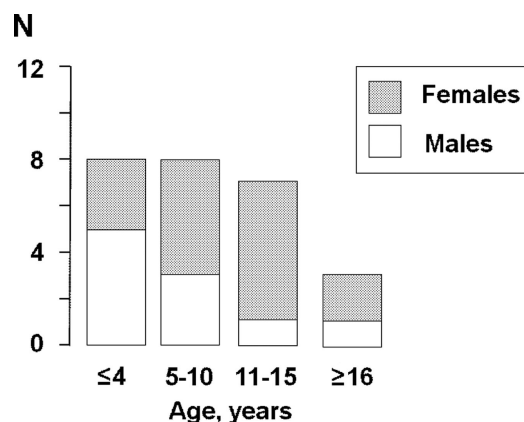


Figure 1. Age distribution of the 26 patients with severe hypertension and peripheral facial nerve palsy. No significant difference was noted in the gender distribution between the age groups (Fisher exact test).

right-sided, $n = 11$) and bilateral in one case. Recurrence of peripheral facial palsy was reported in nine patients, occurring ipsilaterally in five^{6-7,17,22} and contralaterally in another four.^{9-10,12,18} Facial nerve dysfunction was mild in four and severe in eight patients (no information on grading of the peripheral facial palsy is available for the remaining cases). No correlation was found in these patients between severity of facial palsy and the modified BP severity index.

Concomitant signs and symptoms. Additional signs of nervous system dysfunction were described in 16 patients, consisting of headache ($n = 7$), vomiting ($n = 5$), convulsions ($n = 4$), hyperactive reflexes ($n = 2$), positive Babinski sign ($n = 1$), altered level of consciousness ($n = 3$), visual field defect ($n = 1$), internuclear ophthalmoplegia ($n = 1$), and not further described transient double vision ($n = 1$), as depicted in Table 1. In three patients, peripheral facial nerve palsy and severe systemic hypertension were associated with Guillain-Barré syndrome.^{11,19}

Diagnosis of arterial hypertension. The time elapsed between the first facial symptoms and the diagnosis of severe systemic hypertension lasted a median of 45 days (range, 0 days–2 years) in 16 cases in which this information was provided. In nine patients, BP was not recorded initially and the preliminary diagnosis of idiopathic facial nerve palsy made, although in six of these patients additional neurological signs and symptoms were present.^{6-7,9-10,17-18,21-22} Both systolic and diastolic severe hypertension were disclosed in 24 and severe systolic hypertension in the remaining two patients (Table 1). In the three adult patients, facial palsy was found some years after the diagnosis of arterial hypertension. In these cases, facial palsy occurred when BP was not well controlled (nonadherence of antihypertensive treatment) and severe hypertension exacerbated.^{5,8,12} The etiology of arterial hypertension was established in 19 patients, consisting of congenital anomalies of the kidney and urinary tract,^{6,17,20-21} aortic coarctation,^{13,15-16} renal artery stenosis,^{8,18} renal adenocarcinoma,¹⁰ and pheochromocytoma⁷(Table 1). In the three children with Guillain-Barré syndrome,^{11,19} both isolated peripheral facial nerve palsy and severe systemic

hypertension were the presenting signs before further features of the polyneuropathy were apparent. The cause of arterial hypertension remained unknown or classified as primary hypertension in seven patients.^{5,9,12,14,17,21-22}

Site of the lesion. Neuroimaging was described in 11 patients, nine of whom were children (Table 1).^{5-6,8-9,15,17-20} Computed tomography was performed in two and magnetic resonance imaging (MRI) in nine patients. Cerebral MRI revealed a pontine hemorrhage at the site of the facial nucleus in a 9-year-old girl,⁶ and an ischemic stroke in the dorsal pons affecting the post-nuclear facial fibers in a 47-year-old man.⁵ Four patients had signs of multiple ischemic infarcts in the periventricular white matter; three showed involvement of the thalamus and the basal ganglia, one had additional lesions in the insular and occipital cortex.^{8-9,17-18} In two patients with Guillain-Barré syndrome and gadolinium enhancement of spinal nerve roots on MRI, no cerebral or cranial nerve abnormalities were described.¹⁹ In three patients, one of whom had a computed tomography, neuroimaging was normal (Table 1).^{15,20}

No electrophysiological findings specifically addressing the facial nerve were reported.

An edematous nerve sheath with vessel engorgement without hemorrhage was revealed in the child who underwent decompression of the facial nerve from the cochleariform process to the stylomastoid foramen.²¹

Therapeutic approaches and outcome. In 23 patients, BP reduction after correction of the underlying disorder or antihypertensive drug management was followed by a gradual resolution of the facial nerve palsy (19 complete and four partial resolutions, median time to resolution was 2 [IQR, 0.9–6] months; Table 1). In an 8-month-old girl facial nerve palsy resolved following surgical removal of a nonfunctioning kidney, medical stabilization of BP and surgical decompression of the facial nerve.²¹ The child with persisting facial nerve palsy reported by Bialestock in 1961 died because of very severe, refractory hypertension.⁷

Steroids were prescribed in three cases reported in the literature and in our case II.^{6,17-18} All four of these patients were children in whom BP had not been measured at initial diagnosis of peripheral facial nerve palsy, which had been interpreted as Bell's palsy and subsequently treated with corticosteroids. No information on dosage and duration of steroid treatment was available in the three patients found in the literature.

Peripheral facial nerve palsy in publications dealing with nervous system involvement in the context of severe hypertension

Forty-one cases of peripheral facial nerve palsy were found in five publications which specifically addressed the neurological signs of systemic hypertension in a total of 860 severely hypertensive children (4.8%, Table 2).^{14,23-26} Headache was by far the most common neurological complication in children with severe arterial hypertension, followed in decreasing order by altered level of consciousness and vomiting, convulsions, focal central nervous system deficit, and peripheral facial nerve palsy.

Table 2. Peripheral facial nerve palsy noted in five pediatric case series with a total of 860 patients affected by severe hypertension

First Author	Leumann ²³	Trompeter ²⁵	Deal ²⁶	Rance ²⁴	Lloyd ¹⁴	Total
Total number of patients	600	45	110	70	35	860
Patients with facial nerve paralysis (%)	20 (3.3)	2 (4.4)	10 (9.1)	2 (2.8)	7 (20)	41 (4.8)

These cases were only listed and not described in detail, permitting only analysis of prevalence.

DISCUSSION

The main finding of this study is the fact that peripheral facial nerve palsy associated with severe arterial hypertension is primarily described in children and adolescents. The long time to diagnosis of arterial hypertension, lasting a median of 45 days, indicates that this association is not widely recognized. Particularly in children, BP measurement is not firmly considered as a critical component of the routine physical examination. However, recent clinical reviews addressing the management of peripheral facial palsy in childhood mention severe systemic hypertension as a specific cause.^{1, 27} Within the group of severely hypertensive children and adolescents, peripheral facial palsy was described in 4.8% (41/860) ranging from 2.8% to 20% as indicated in five publications dealing with the complications of severe childhood hypertension.^{14, 23–26} Moreover, in a survey dealing with the different etiologies of peripheral facial nerve palsy, arterial hypertension was the cause in 7 of 87 (8%) children.¹⁴

Lower motor neuron facial palsy has previously been associated with the hypertensive disorders of pregnancy and puerperium,²⁸ and a recent case-control study suggests that chronic, nonsevere hypertension may increase the risk of lower motor neuron facial nerve palsy in subjects older than 40 years of age.²⁹

A timely diagnosis of arterial hypertension in the case of peripheral facial palsy is crucial in order to start adequate antihypertensive treatment. The majority of the cases showed full recovery of the facial palsy some weeks after onset of treatment. It remains unclear whether medication directly affects speed and degree of resolution or acts only to prevent further recurrence, since some cases demonstrated spontaneous resolution prior to the diagnosis of arterial hypertension. In the three adult cases with known chronic arterial hypertension, facial palsy occurred during exacerbation of severe arterial hypertension due to nonadherence of medication and immediately resolved after better BP control, suggesting a direct relationship between BP lowering and resolution of facial palsy.^{5,8,12} Corticosteroids, the standard treatment of Bell's palsy, potentially exacerbate arterial hypertension and are therefore not indicated.

The putative mechanisms underlying the dysfunction of the facial nerve or its nucleus were addressed in a minority of the affected patients. These include a swelling of the facial nerve in its bony canal associated with vessel engorgement, a hemorrhage into the facial canal, as reported in two necropsies,^{3, 30} an ischemic stroke affecting the postnuclear fibers of the nerve, or a bleeding in the facial nerve nucleus. These mechanisms may be implicated also in the development of facial palsy during preeclampsia.²⁸

Both lower motor neuron facial nerve palsy and arterial hypertension have independently been described as features of Guillain-Barré syndrome.³¹ Whether the cases of facial nerve palsy reported in three children with Guillain-Barré syndrome included in this analysis were caused by severe hypertension or were a first manifestation of the polyneuropathy remains uncertain.

The most important limitation of this review lies in the small number of reported patients affected by peripheral facial nerve palsy caused by severe systemic hypertension and the retrospective nature of the analysis. A second limitation is that adequate neuroimaging studies were rarely performed. Finally, the degree of facial palsy was not assessed using a facial nerve grading system.

In conclusion, this review provides evidence that there might be an association of uncontrolled hypertension and facial palsy that warrants additional evaluation. With effective acute and chronic antihypertensive therapy, the prognosis of facial palsy is excellent. A gradual normalization of BP in 2–3 days is advised.^{4,32–33}

DISCLOSURE

The authors declared no conflict of interest.

REFERENCES

- Riordan M. Investigation and treatment of facial paralysis. *Arch Dis Child* 2001;84:286–288.
- Anonymous. Facial paralysis in hypertension. *Br Med J* 1966;2:1547.
- Moxon W. Apoplexy Into the canal of fallopius in a case of Bright's disease causing facial paralysis. *Trans Path Soc* 1869;20:420–421.
- National high blood pressure education program working group on high blood pressure in children and adolescents. The fourth report on the diagnosis, evaluation, and treatment of high blood pressure in children and adolescents. *Pediatrics* 2004;114:555–576.
- Agarwal R, Manandhar L, Saluja P, Grandhi B. Pontine stroke presenting as isolated facial nerve palsy mimicking Bell's palsy: a case report. *J Med Case Rep* 2011;5:287.
- Aynaci FM, Sen Y. Peripheral facial paralysis as initial manifestation of hypertension in a child. *Turk J Pediatr* 2002;44:73–75.
- Bialestock D. Hyperplasia of the adrenal medulla in hypertension of children. *Arch Dis Child* 1961;36:465–473.
- Ellis SL, Carter BL, Leehey MA, Conry CM. Bell's palsy in an older patient with uncontrolled hypertension due to medication nonadherence. *Ann Pharmacother* 1999;33:1269–1273.
- Harms MM, Rottevel JJ, Kar NC, Gabreels FJ. Recurrent alternating facial paralysis and malignant hypertension. *Neuropediatrics* 2000;31:318–320.
- Kumar S, Winearls CG, Owen DL. Facial palsy with severe hypertension due to renal tumour. *Br Med J (Clin Res Ed)* 1982;285:1266.
- Laufer J, Passwell J, Keren G, Brandt N, Cohen BE. Raised plasma renin activity in the hypertension of the Guillain-Barre syndrome. *Br Med J (Clin Res Ed)* 1981;282:1272–1273.

12. Lavin PJ, Weissman BM. 'Bell's palsy' in accelerated hypertension. *Postgrad Med* 1985;77:165, 168.
13. Lewis VE, Peat DS, Tizard EJ. Hypertension and facial palsy in middle aortic syndrome. *Arch Dis Child* 2001;85:240–241.
14. Lloyd AV, Jewitt DE, Still JD. Facial paralysis in children with hypertension. *Arch Dis Child* 1966;41:292–294.
15. Margabanthu G, Brooks J, Barron D, Miller P. Facial palsy as a presenting feature of coarctation of aorta. *Interact Cardiovasc Thorac Surg* 2003;2:91–93.
16. Moore P, Fiddler GI. Facial palsy in an infant with coarctation of the aorta and hypertension. *Arch Dis Child* 1980;55:315–316.
17. Siegler RL, Brewer ED, Corneli HM, Thompson JA. Hypertension first seen as facial paralysis: case reports and review of the literature. *Pediatrics* 1991;87:387–389.
18. Smilari P, Incorpora C, Polizzi A, Sciacca P, Musi L, Petrillo G, Distefano G, Pavone L. [Recurrent facial paralysis in a child with renovascular hypertension]. *Pediatr Med Chir* 1995;17:461–463.
19. Smith N, Grattan-Smith P, Andrews IP, Kainer G. Acquired facial palsy with hypertension secondary to Guillain-Barre syndrome. *J Paediatr Child Health* 2010;46:125–127.
20. Tirodker UH, Dabbagh S. Facial paralysis in childhood hypertension. *J Paediatr Child Health* 2001;37:193–194.
21. Voorhees RL, Zeitzer LD, Ross M. Hypertension and associated peripheral facial paralysis. *Laryngoscope* 1972;82:899–902.
22. Zeis PM, Rao S, John EG, Aschinberg LC. "Stress" polycythaemia and peripheral facial palsy complications of severe hypertension. *Acta Paediatr Scand* 1979;68:287–289.
23. Leumann EP. Blood pressure and hypertension in childhood and adolescence. *Ergeb Inn Med Kinderheilkd* 1979;43:109–183.
24. Rance CP, Arbus GS, Balfe JW, Kooh SW. Persistent systemic hypertension in infants and children. *Pediatr Clin North Am* 1974;21:801–824.
25. Trompeter RS, Smith RL, Hoare RD, Neville BG, Chantler C. Neurological complications of arterial hypertension. *Arch Dis Child* 1982;57:913–917.
26. Deal JE, Barratt TM, Dillon MJ. Management of hypertensive emergencies. *Arch Dis Child* 1992;67:1089–1092.
27. Singhi P, Jain V. Bell's palsy in children. *Semin Pediatr Neurol* 2003;10:289–297.
28. Shmorgun D, Chan WS, Ray JG. Association between Bell's palsy in pregnancy and pre-eclampsia. *QJM* 2002;95:359–362.
29. Savadi-Oskouei D, Abedi A, Sadeghi-Bazargani H. Independent role of hypertension in Bell's palsy: a case-control study. *Eur Neurol* 2008;60:253–257.
30. Monier-Vinard, Puech P. Nephrite Chronique et Paralyse Faciale. *Bull et Memoires de la Soc Med des Hopitaux de Paris* 1930;20:977–980.
31. Shah DN. The spectrum of Guillain-Barre syndrome. *Dis Mon* 2010;56:262–265.
32. Chobanian AV, Bakris GL, Black HR, Cushman WC, Green LA, Izzo JL, Jr., Jones DW, Materson BJ, Oparil S, Wright JT, Jr., Roccella EJ. Seventh report of the Joint National Committee on Prevention, Detection, Evaluation, and Treatment of High Blood Pressure. *Hypertension* 2003;42:1206–1252.
33. Flynn JT, Tullus K. Severe hypertension in children and adolescents: pathophysiology and treatment. *Pediatr Nephrol* 2009;24:1101–1112.