



ELSEVIER

European Journal of Cardio-thoracic Surgery 40 (2011) 522–524

EUROPEAN JOURNAL OF
CARDIO-THORACIC
SURGERYwww.elsevier.com/locate/ejcts

How-to-do-it

Imaging for trans-catheter pulmonary stent-valve implantation without angiography: role of intravascular ultrasound

Enrico Ferrari^{*}, Lars Niclauss, Denis Berdajs, Ludwig Karl von Segesser*Department of Cardiovascular Surgery, University Hospital of Lausanne, CH-1011, Lausanne, Switzerland*

Received 29 October 2010; received in revised form 1 December 2010; accepted 6 December 2010; Available online 15 January 2011

Abstract

Patients with stenosed biologic pulmonary conduits require redo cardiac surgery to prevent severe right ventricular dysfunction. Following the latest trends, the trans-catheter pulmonary stent-valve implantation represents a new fascinating alternative carrying a lower operative risk, compared with the standard open-heart re-intervention. Traditionally, the pulmonary stent valve is positioned off pump, under fluoroscopic control, and requires angiographies. However, alternative tools not requiring contrast injections for the intra-operative cardiac imaging have to be also considered strongly. The usefulness of intravascular ultrasound for the positioning of aortic endoprosthesis has already been proven in previous reports and, following the same principle, we have started to routinely implant balloon-expandable stent valves (Edwards SapienTM THV) in stenosed pulmonary valve conduits using intravascular ultrasound for the stent-valve positioning without angiography. We describe the intra-operative intravascular imaging technique with technical details.

© 2010 European Association for Cardio-Thoracic Surgery. Published by Elsevier B.V. All rights reserved.

Keywords: Intravascular ultrasound; Trans-catheter pulmonary valve implantation; Pulmonary conduits

1. Introduction

Stenosis is a complication following surgery for pulmonary outflow trunk reconstruction with biological conduits, such as homografts or bovine jugular veins (Contegra[®], Medtronic, Minneapolis, MN, USA), and redo cardiac surgery for the conduit replacement still represents a challenging procedure. Minimal invasive off-pump trans-catheter techniques for pulmonary stent-valve implantation carry a lower operative risk and represent, nowadays, a clinical reality in several cardiac centers [1–4]. Traditionally, stent-valve positioning and implantation are based on intra-operative angiographic images requiring several contrast injections, and the stent valve is introduced through a transfemoral venous access. Nevertheless, we have demonstrated that the subxyphoidian approach for pulmonary trans-catheter valve implantation is a safe and feasible alternative [5], and we have also demonstrated that the angiography is no longer necessary during trans-catheter procedures [6]. Following our experience regarding endovascular aortic stent-graft implantations without angiographies [7], we are routinely implanting pulmonary stent valves using intravascular

ultrasound (IVUS) for the valve positioning and for the post-implantation control [8].

2. Procedural details

Preoperatively, all patients undergo cardiac computed tomography (CT) scans and heart catheterizations (Fig. 1(A)) with low doses of contrast medium. Then, with a patient under general anesthesia and in the operative theater, we proceed as follows: our surgical access of choice is subxyphoidian and the scar of the previous intervention (median sternotomy) is extended for approximately 5–8 cm under the xyphoid apophysis. Then, the diaphragmatic face of the right ventricle is carefully exposed and pacemaker wires are fixed and tested for rapid pacing. A double 3/0 or 2/0 polypropylene purse-string suture reinforced with pledgets (Teflon felts, 1 × 0.5 cm) is prepared where coronary arteries are not visible. After heparinization (100 UI kg⁻¹), a guide wire and an 11-F sheet are introduced into the right ventricle toward the pulmonary trunk (straightforward). Then, the soft guide wire is passed through the stenosed pulmonary valve conduit and placed in the right pulmonary artery under fluoroscopic guidance. An IVUS probe (9F, AcusonTM by Siemens) is guided, over-the-wire, into the right ventricle and across the stenosed pulmonary valve: using the pullback technique, the pulmonary bifurcation, the pulmonary artery (Fig. 1(B)), the distal end (Fig. 1(C)), and the proximal end

^{*} Corresponding author. Address: Department of Cardiovascular Surgery, Centre Hôpitalier Universitaire Vaudois (CHUV), 46, rue du Bugnon, CH-1011, Lausanne, Switzerland. Tel.: +41 793101386; fax: +41 (0)21 3142879. E-mail address: enricoferrari@bluewin.ch (E. Ferrari).

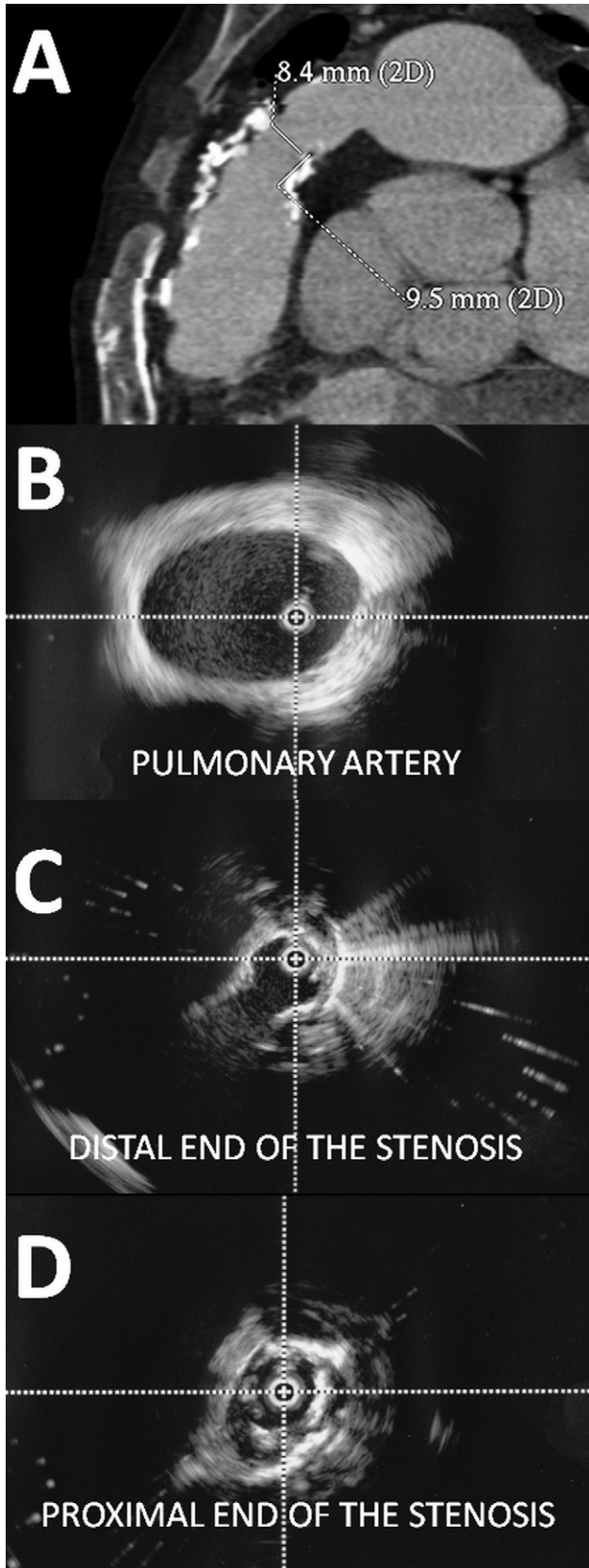


Fig. 1. (A) Preoperative CT-scan showing the severely stenosed pulmonary valve conduit; (B) IVUS imaging of the pulmonary artery; (C) IVUS imaging of the distal end of the stenotic pulmonary valve conduit; and (D) IVUS imaging of the proximal end of the stenotic pulmonary valve conduit.

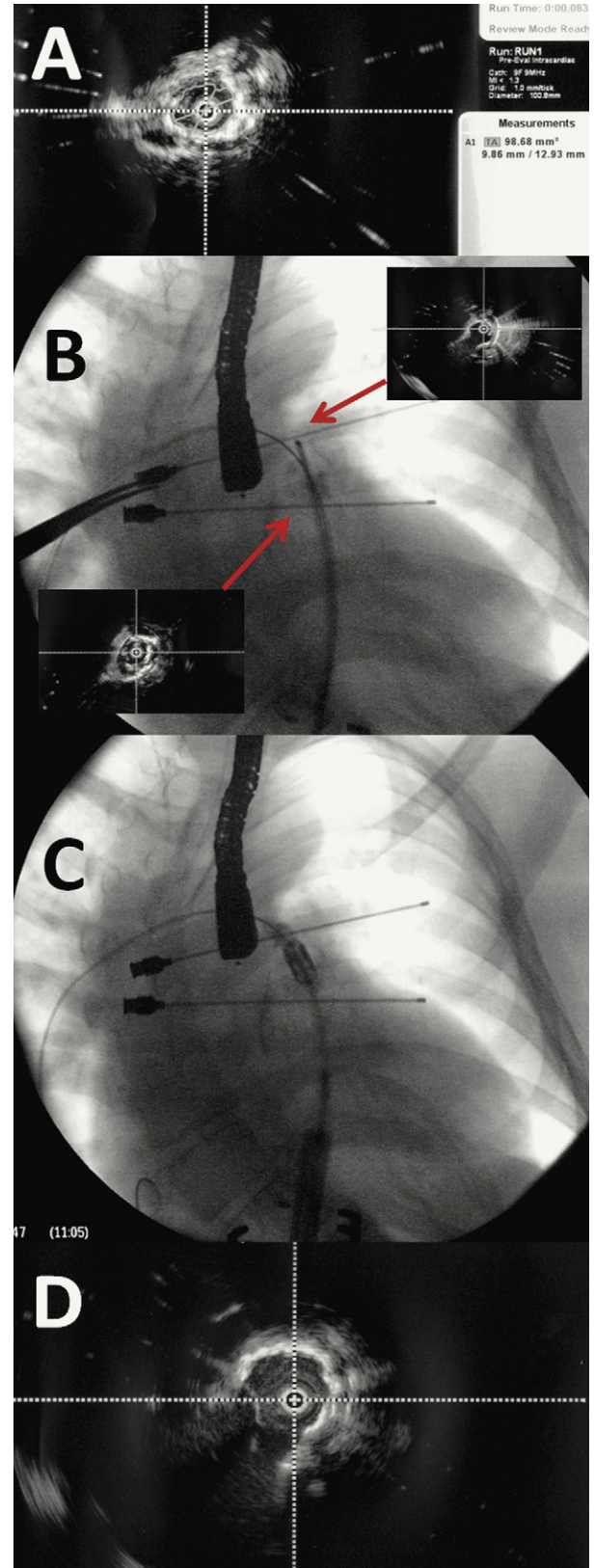


Fig. 2. (A) Measurements of the stenotic pulmonary valve conduit by IVUS; (B) fluoroscopic imaging showing the IVUS probe and the metal markers for the distal and the proximal end of the diseased pulmonary valve conduit; (C) the stent-valve (Edwards Sapien™ THV, Edwards Lifesciences, Irvine, CA, USA) positioning under fluoroscopy using the metal markers as landmarks; and (D) IVUS final control after the stent-valve implantation.

(Fig. 1(D)) of the stenotic portion of the valve conduit are easily identified and measured with IVUS (Fig. 2(A)), and then marked, under fluoroscopy, with metal markers placed in the operative field (Fig. 2(B)), as already reported for the endovascular aorta repair technique [7]. From this moment, it becomes necessary to fix the fluoroscopy system in its final position (we routinely use an high-quality portable C-arm fluoroscopy by Philips, Eindhoven, the Netherlands) to avoid tactless movements after the markers' fixation. Thus, the IVUS is pulled out, the soft guide wire is replaced by a super-stiff guide wire, and the 11-F sheet is replaced by the Edwards Ascendra™ system (26F) for the valvuloplasty and for the Sapien™ valve implantation (Edwards Lifesciences, Irvine, CA, USA). The fluoroscopy is required for the positioning of the balloon catheters in the ideal landing zone, in between the metal markers identifying the beginning and the end of the stenotic portion (Fig. 2(C)), and for the control of the balloon inflation during the valvuloplasty and the valve deployment. We usually do not implant vascular stents before the Sapien™ implantation. After the pulmonary valvuloplasty and the stent-valve deployment under rapid cardiac pacing, the IVUS probe is inserted again through the prosthesis to verify the circularity of the deployed stent valve, the leaflets' motion, and the presence of residual stenosis requiring further dilatations (Fig. 2(D)). Then, the IVUS probe, the guide wire, and the sheet are pulled out, and the purse-string sutures are tied.

Usually, the entire procedure is performed without contrast injections, and the results we collected so far (five cases) are excellent with transesophageal echocardiographic hemodynamic findings confirming low gradients and absence of leaks. Moreover, the total fluoroscopy time is not longer than a comparable procedure performed with repeated angiographies.

3. Conclusion

Less invasiveness in cardiac surgery is an emerging and attractive concept that increasingly involves the valvular field. In particular, the trans-catheter heart valve replacement is a promising procedure with a lower operative risk, and a special indication for patients requiring redo open-heart surgery. However, less invasivity can also mean less medications, less radiation doses, or less contrast medium

injected intra-operatively for the cardiac imaging (to prevent postoperative acute kidney insufficiency).

Following this principle, we have explored alternative tools (IVUS) for cardiac imaging during trans-catheter pulmonary stent-valve implantations: in our limited clinical experience, the IVUS represents a useful tool allowing the identification of the ideal landing zone in the diseased pulmonary valve conduit, and the measurement of diameters. Moreover, the postoperative IVUS control, coupled with transesophageal echocardiography and fluoroscopy without angiography, identifies residual stenosis, unexpanded stent valves and leaks. The IVUS can be easily performed, by an experienced team, both through a trans-venous femoral access and through a subxyphoidian surgical access, which is a valid alternative in case of inaccessibility to the iliac/femoral vein axes or presence of cava filters. In conclusion, the subxyphoidian trans-catheter pulmonary stent-valve implantation is a full intrapericardial minimally invasive valve procedure and, using the IVUS-guided Sapien™ THV implantation, can be performed without contrast injections.

References

- [1] Khambadkone S, Bonhoeffer P. Percutaneous implantation of pulmonary valves. *Expert Rev Cardiovasc Ther* 2003;1(4):541–8.
- [2] Coats L, Tsang V, Khambadkone S, van Doorn C, Cullen S, Deanfield J, de Leval MR, Bonhoeffer P. The potential impact of percutaneous pulmonary valve stent implantation on right ventricular outflow tract re-intervention. *Eur J Cardiothorac Surg* 2005;27:536–43.
- [3] Rodés-Cabau J, Houde C, Perron J, Benson LN, Pibarot P. Delayed improvement in valve hemodynamic performance after percutaneous pulmonary valve implantation. *Ann Thorac Surg* 2008;85:1787–8.
- [4] Lurz P, Coats L, Khambadkone S, Nordmeyer J, Boudjemline Y, Schievano S, Muthurangu V, Lee TY, Parenzan G, Derrick G, Cullen S, Walker F, Tsang V, Deanfield J, Taylor AM, Bonhoeffer P. Percutaneous pulmonary valve implantation: impact of evolving technology and learning curve on clinical outcome. *Circulation* 2008;117:1964–72.
- [5] Ferrari E, Sulzer C, Rizzo E, von Segesser LK. Transcatheter stent-valve implantation in a stenotic pulmonary conduit via a sub-xyphoidian access. *Eur J Cardiothorac Surg* 2009;36:595–7.
- [6] Ferrari E, Sulzer C, Marcucci C, Rizzo E, Tozzi P, von Segesser LK. Transapical aortic valve implantation without angiography—proof of concept. *Ann Thorac Surg* 2010;89:1925–32.
- [7] von Segesser LK, Marty B, Ruchat P, Bogen M, Gallino A. Routine use of intravascular ultrasound for endovascular aneurysm repair: angiography is not necessary. *Eur J Vasc Endovasc Surg* 2002;23:537–42.
- [8] Huber CH, Nasratulla M, Augstburger M, von Segesser LK. Ultrasound navigation through the heart for off-pump aortic valved stent implantation: new tools for new goals. *J Endovasc Ther* 2004;11:503–10.