

CARDIOVASCULAR FLASHLIGHT

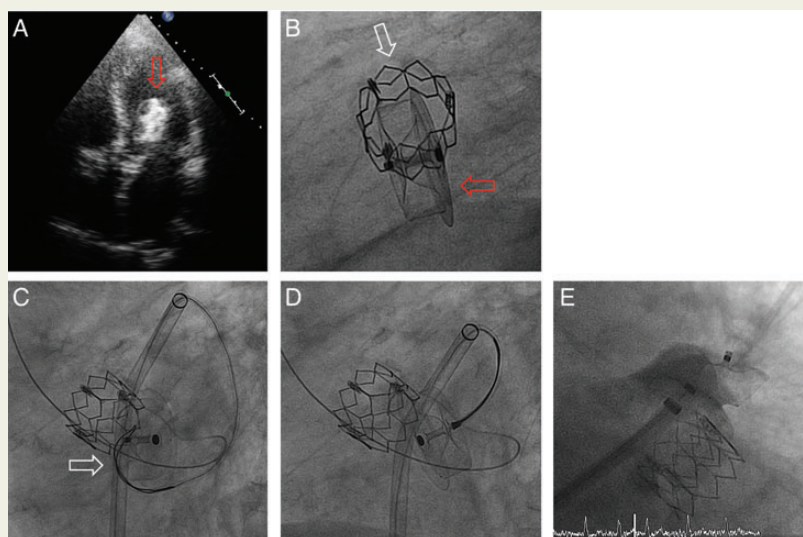
doi:10.1093/eurheartj/eh472

Catch me if you can**Adrian Attinger-Toller, Thomas F. Lüscher, Ulf Landmesser, and Fabian Nietlisbach***

University Heart Center, Department of Cardiology, University Hospital Zurich, Zurich, Switzerland

* Corresponding author. Email: fabian.nietlisbach@usz.ch**This paper was guest edited by Brahmajee Nallamothu, Associate Professor, Department of Internal Medicine, University of Michigan, bnallamo@umich.edu**

The 92-year-old patient with severe, symptomatic aortic stenosis, a 90% proximal LAD-stenosis and in chronic atrial fibrillation, was referred to our centre. In the same setting, using local anaesthesia and fluoroscopic guidance only, the proximal LAD-stenosis was stented (drug-eluting stent), followed by transfemoral implantation of an Edwards Sapien XT 26 mm valve and occlusion of the left atrial appendage (LAA; Amplatzer Amulet 31 mm). On transthoracic echocardiography the following day, the LAA-occluder was found embolized in the left ventricular outflow tract (A and B; red arrow: Amplatzer Amulet 31 mm; white arrow: Edwards Sapien XT 26 mm). During the urgent re-intervention, the left atrium was accessed through the pre-existing transeptal puncture. Using another 14 French Amplatzer TorqueVue sheath, a 25 mm Goose-neck snare (C; white arrow) and a JL4 catheter, the LAA-occluder was rotated on its own axis in order to catch the screw on the opposite side of the device (D). After successful snaring, a smaller LAA-occluder (25 mm) was deployed in the LAA with good sealing (E). Phenprocoumon was stopped and dual-antiplatelet therapy with aspirin and clopidogrel was started. Three days after the second intervention, the patient developed acute anaemia and endoscopy revealed a duodenal ulcer (Forrest Ib), which was coagulated with a gold probe.



During the urgent re-intervention, the left atrium was accessed through the pre-existing transeptal puncture. Using another 14 French Amplatzer TorqueVue sheath, a 25 mm Goose-neck snare (C; white arrow) and a JL4 catheter, the LAA-occluder was rotated on its own axis in order to catch the screw on the opposite side of the device (D). After successful snaring, a smaller LAA-occluder (25 mm) was deployed in the LAA with good sealing (E). Phenprocoumon was stopped and dual-antiplatelet therapy with aspirin and clopidogrel was started. Three days after the second intervention, the patient developed acute anaemia and endoscopy revealed a duodenal ulcer (Forrest Ib), which was coagulated with a gold probe.

Device embolization is a rare, but dreaded complication after LAA-occlusion (0.6% in the PROTECT AF and 0% in the CAP Registry). In this patient, the LAA-occluder embolized most likely due to oversizing. Fortunately, the dislocated LAA-occluder could be removed safely by antegrade snaring through the pre-existing transeptal puncture. In addition, subsequent implantation of a smaller LAA-occluder may have prevented this patient from an even more dangerous complication of his upper GI-bleeding and given his HASBLED-Score of 4 will prevent him from future bleeding complications.