



Editorial

The myocardial band: fiction or fact?

The anatomy of the heart is certainly of major interest to all of us who are involved in its surgical repair. Over the years, various concepts have been introduced with regard to the structure of the heart, but some degree of controversy has always been around.

As a matter of fact, the plates in the very famous *De humanis corporis fabrica* by A Vesalius from 1543 [1] show cross sections of the heart indicating its layered structure, whereas one can read in *Heister's anatomy* from 1753 [2], that the fibers of the heart are crossing in various fashions (Fig. 1). The 1778 edition of the *Encyclopédie* [3] mentions, that the dissection of the heart reveals a double layer of spiral fibers, the outer layer forming some sort of screw between the base and apex.

More recently, Torrent-Guasp has reviewed the macroscopic structure of the heart and introduced the concept of the myocardial band [4], a dissection of the three dimensional, four chambered heart, resulting in one single strip of muscle (the myocardial band). There can be no doubt that this type of dissection can be realized in reproducible fashion. Likewise, during surgery, e.g. pulmonary auto-graft harvesting for the Ross procedure, a plane can sometimes be developed within the inter-ventricular septum (personal experience), which greatly facilitates this crucial step.

Torrent-Guasp and colleagues have also developed new concepts about the functional impact of the myocardial band [5]. The latter have triggered an extremely intriguing discussion [6], which is ongoing in this issue with papers by Lunkenheimer [7], Torrent Guasp [8], and Buckberg [9].

It has to be added here, that new knowledge is gathered permanently in many fields that interfere with the discussion mentioned above. At the embryologic level, it is traditionally accepted that the heart forms out of bilateral cardiac mesoderm, which migrates from the lateral region of the embryo to the ventral midline, where it fuses. The fact, that a recent study [10] looking into cardiac morphogenesis showed that highly differentiated four-chambered mammalian hearts can be formed in each bilateral heart forming region of *Foxp4* mutant mice, makes clear, that during evolution, various concepts can emerge and it seems that some may even coexist. Considering the current developments in the field of restoration of the heart at the cellular level, this finding adds also further evidence that pluripotent cells are present at multiple locations of the body.

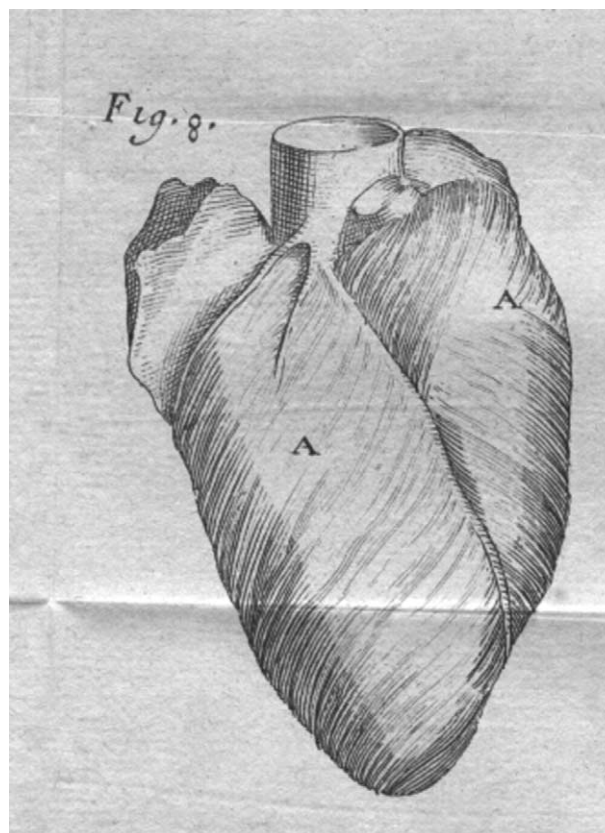


Fig. 1. Reproduction from Heister's anatomy (1753) plate 2, Fig. 8 showing that the fibers of the heart are crossing in various fashions as mentioned in his text.

Obviously not everything is carved in stone, and some degree of flexibility appears to be necessary for improved understanding of the structure of both, the normal and the pathological heart, which in turn is of prime importance for surgical restoration of its form and function.

References

- [1] Vesalii A. *Humani corporis fabrica*. Basel, 1543:180-183.
- [2] Heister. *L'anatomie*. Vincent, Paris, 1753;2:225, plate 2.
- [3] Diderot M, D'Alambert M. *Encyclopédie*. vol. 8. Genève: Pellet; 1778 p. 405.
- [4] Torrent-Guasp F. Estructura y función del corazón. *Rev Esp Cardiol* 1998; 51:91-102.

- [5] Torrent-Guasp F, Kocica MJ, Corno A, Komeda M, Cox J, Flotats F, Ballester-Rodes M, Carreras-Costa F. Systolic ventricular filling. *Eur J Cardiothorac Surg* 2004;25:376-86.
- [6] Anderson RH. Systolic ventricular filling. *Eur J Cardiothorac Surg* 2004; 26:461.
- [7] Schmid P, Jaermann T, Boesiger P, Niederer PF, Lunkenheimer PP, Cryer CW, Anderson RH. Ventricular myocardial architecture as visualised in postmortem swine hearts using magnetic resonance diffusion tensor imaging. *Eur J Cardiothorac Surg* 2005;27(3):in press.
- [8] Torrent-Guasp F, Kocica MJ, Corno AF, Komeda M, Carreras Costa F, Flotats A, Cosin-Aguillar J, Wen H. Towards new understanding of the heart structure and function. *Eur J Cardiothorac Surg* 2005;27:191-201.
- [9] Buckberg G. Architecture must document functional evidence to explain the living rhythm. *Eur J Cardiothorac Surg* 2005;27:202-9.
- [10] Li S, Zhou D, Lu MM, Morrisey EE. Advanced cardiac morphogenesis does not require heart tube fusion. *Science* 2004;305:1619-22.

Ludwig K. von Segesser*

*Department of Cardio-Vascular Surgery,
Centre Hospitalier Universitaire Vaudois,
CH-1011 Lausanne, Switzerland*

*Tel.: +41 21 314 2695; fax: +41 21 314 2879

E-mail address: ludwig.von-segesser@chuv.hospvd.ch

URL: <http://www.cardiovasc.net>¹