

CORRESPONDENCE

© 1984 by The University of Chicago. All rights reserved.
0022-1899/84/4905-0032\$01.00

Hematogenous Hexamitiasis in a Macaque Monkey with an Immunodeficiency Syndrome

COLLEAGUES—Protozoans of the *Hexamita* species are common gastrointestinal parasites of poultry, mice, rats, and hamsters [1] and have been reported as occasional gastrointestinal parasites in nonhuman primates [2]. We have observed the first case of hematogenous hexamitiasis in a primate. It occurred as an opportunistic infection in a rhesus monkey with the macaque immunodeficiency syndrome. An 11-month-old *M. mulatta* was observed to have diffuse lymphadenopathy. At that time serum-chemistry showed elevated liver-function tests; hematologic studies showed a leukocyte count of $1.4 \times 10^3/\text{mm}^3$ with a differential of 26% neutrophils, 32% lymphocytes, 22% monocytes, and 20% large, atypical mononuclear cells with vacuolated cytoplasm and prominent nucleoli. Flagellated parasites with the morphological appearance of *Hexamita* organisms were seen at a frequency of 6–8 per high-power field on the peripheral blood smear. Although a course of treatment with metronidazole substantially decreased this hematogenous protozoal burden, the animal died two weeks later of an overwhelming bacterial pneumonia. At necropsy all examined lymph nodes had an absence of follicles, marked lymphocytic depletion, and extensive histiocytosis. The stroma of the nodes had a hyalinized appearance, and blood vessels were prominent.

This macaque showed evidence of a process (similar to acquired immune deficiency syndrome) that we have recently observed in macaque monkeys housed at the New England Regional Primate Research Center [3]. Monkeys with this immunodeficiency syndrome have died of unusual opportunistic infections and tumors. Dramatically diminished responses of peripheral-blood lymphocytes to lectins and antigens have been noted in these animals. The hematologic abnormalities seen in

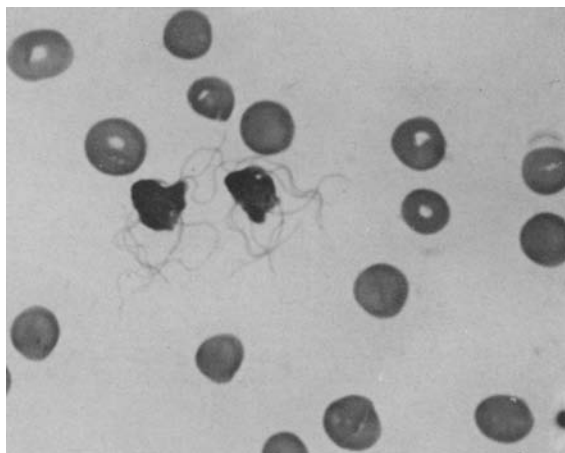


Figure 1. Two *Hexamita* species organisms in a routine peripheral blood smear (Wright-Giemsa stain) of a *Macaca mulatta* $\times 2,000$.

the present case—that is, neutropenia, monocytosis, and the presence of an atypical circulating mononuclear cell with prominent nucleoli and vacuolated cytoplasm—are characteristic findings in this syndrome. Hepatitis and histological evidence of both histiocytosis and a dramatic depletion of normal cellular elements in lymph nodes are also common in affected macaques.

Opportunistic infections strikingly similar to those described in humans with acquired immune deficiency syndrome have been seen in these immunodeficient macaques. The infectious agents have included *Candida albicans*, *Pneumocystis carinii*, *Mycobacterium avium-M intracellulare*, and cytomegalovirus. The unusual form of protozoal infection that we describe here illustrates the remarkable diversity of infections that can occur in the immunocompromised host.

NORMAN L. LETVIN, MICHAEL J. O'CONNELL,
BEVERLY J. BLAKE, NORVAL W. KING

Harvard Medical School,
New England Regional Primate Research Center,
Southborough, Massachusetts

This work was supported by National Institutes of Health Division of Research Resources grant RR-00168 to the New England Regional Primate Research Center and by ROI-AI-20729 from the National Institute of Allergy and Infectious Diseases. Dr. Letvin is a recipient of an American Cancer Society Junior Faculty Research Award.

Please address reprint requests to Dr. Norman L. Letvin, New England Regional Primate Research Center, One Pine Hill Drive, Southborough, Massachusetts 01772.

References

1. Wagner JE, Doyle RE, Ronald NC, Garrison RG, Schmitz JA. Hexamitiasis in laboratory mice, hamsters, and rats. *Lab Anim Sci* 1974;24:349–54
2. Wenrich DH. A species of *Hexamita* (Protozoa, Flagellata) from the intestine of a monkey (*Macacus rhesus*). *J Parasitol* 1933;19:225–9
3. Letvin NL, Eaton KA, Aldrich WR, Sehgal PK, Blake BJ, Schlossman SF, King NW, Hunt RD. Acquired immunodeficiency syndrome in a colony of macaque monkeys. *Proc Natl Acad Sci USA* 1983;80:2718–22

© 1984 by The University of Chicago. All rights reserved.
0022-1899/84/4905-0033\$01.00

Acquired Immune Deficiency Syndrome: Is Disseminated Aspergillosis Predictive of Underlying Cellular Immune Deficiency?

TO THE EDITOR—I read with interest the summary by Dr. Jaffe et al. [1] of the epidemiological features of the first 1,000 cases of acquired immune deficiency syndrome (AIDS) reported from the United States. In their case definition they state that disseminated aspergillosis is at least moderately suggestive of underlying cellular immune deficiency and is thus a marker-infection for the diagnosis of AIDS. However, this view of the

role of T cell-dependent immunity in aspergillosis is not supported by the published literature.

Clinical observations suggest that neutropenia [2, 3], immunosuppression with corticosteroids [2, 4, 5], and chronic childhood granulomatous disease [6] are the main risk factors for disseminated aspergillosis. The protective role of the neutrophil in resistance to the invasive hyphae in the absence of specific immune mechanisms has been well characterized experimentally both in vitro [7, 8] and in vivo [8]. Cortisone has been shown to both suppress the unspecific phagocytic resistance to *Aspergillus* organisms provided by alveolar macrophages and neutrophils and affect normal and athymic mice alike [8]. Thus, the fact that steroids render patients susceptible to aspergillosis cannot be taken as evidence for a role of T cell-mediated immunity in aspergillosis. Finally, there are no experimental data supporting a role for T lymphocytes in immunity to aspergillosis [9].

While disseminated or extensively invasive aspergillosis is extremely rare in normal healthy people and is therefore given minor consideration in epidemiological studies of AIDS, the seemingly unjustified statement that aspergillosis is predictive of a cellular immune deficiency might have an important impact on the general understanding of fungal immunology and on the evaluation of immune deficiencies other than deficient cell-mediated immunity in individual patients with AIDS.

In the absence of clinical or experimental data suggesting a connection between aspergillosis and deficient T cell-mediated immunity, the following questions occur regarding a possible correlation between AIDS and aspergillosis: (1) what is the frequency in AIDS of proven infection with this ubiquitous organism, (2) has aspergillosis been observed as an early manifestation of AIDS or only as a late complication after multiple infections or malignancy in severely debilitated patients, (3) is there any evidence either of neutropenia or of extensive pulmonary damage that might possibly interfere with resistance provided by macrophages in these patients, and (4) has the antifungal activity of the two phagocytic cell lines involved in protection against aspergillus infection been studied in patients with both AIDS and aspergillosis. Until these questions are answered it would be advisable to avoid imputing a link between aspergillosis and T cell-mediated immunity and to continue to consider this mycosis as indicative of defective unspecific phagocytic resistance.

ANDREAS SCHAFFNER

Department of Medicine, University of Zurich,
Zurich, Switzerland

Please address requests for reprints to Dr. Andreas Schaffner, Medizinische Klinik, Room CH 13, Universitätsspital, CH-8091 Zurich, Switzerland.

References

- Jaffe HW, Bregman DJ, Selik RM. Acquired immune deficiency syndrome in the United States: The first 1,000 cases. *J Infect Dis* 1983; **148**:339-45
- Bodey GP. Fungal infections complicating acute leukemia. *J Chronic Dis* 1966; **19**:667-87
- Krick JA, Remington JS. Opportunistic invasive fungal infections in patients with leukaemia and lymphoma. *Clin Haematol* 1976; **5**:249-310
- Gustafson TL, Schaffner W, Lavelly GB, Stratton CW, Johnson HK, Hutcheson RH Jr. Invasive aspergillosis in renal transplant recipients: correlation with corticosteroid therapy. *J Infect Dis* 1983; **148**:230-8
- Carbone PP, Sabesin SM, Sidransky H, Frei E III. Secondary aspergillosis. *Ann Intern Med* 1964; **60**:556-67
- Cohen MS, Isturiz RE, Malech HL, Root RK, Wilfert CM, Gutman L, Buckley RH. Fungal infection in chronic granulomatous disease: the importance of the phagocyte in defense against fungi. *Am J Med* 1981; **71**:59-66
- Diamond RD, Krzesicki R, Epstein B, Jao W. Damage to hyphal forms of fungi by human leukocytes in vitro: a possible host defense mechanism in aspergillosis and mucormycosis. *Am J Pathol* 1978; **91**:313-28
- Schaffner A, Douglas H, Braude A. Selective protection against conidia by mononuclear and against mycelia by polymorphonuclear phagocytes in resistance to aspergillus: observations on these two lines of defense in vivo and in vitro with human and mouse phagocytes. *J Clin Invest* 1982; **69**:617-31
- Schaffner A, Douglas H, Braude AI, Davis CE. Killing of *Aspergillus* spores depends on the anatomical source of the macrophage. *Infect Immun* 1983; **42**:1109-15

Reply

TO THE EDITOR — We thank Dr. Schaffner for his very informative letter. Of 1,762 AIDS case reports we have analyzed, only three included disseminated aspergillosis as a diagnosis. One of these patients also had pneumocystis pneumonia; the other two patients did not have any other clinical features suggestive of AIDS. Results of T cell studies were not reported for any of these patients.

In view of the lack of aspergillus infections among reported AIDS patients and the comments of Dr. Schaffner—and of Dr. Louise Hawley, who wrote to us directly—we have deleted aspergillosis from the list of infections considered at least moderately predictive of AIDS.

HAROLD W. JAFFE, RICHARD M. SELIK
*AIDS Activity, Center for Infectious Diseases,
Centers for Disease Control, Atlanta, Georgia*

© 1984 by The University of Chicago. All rights reserved.
0022-1899/84/4905-0034\$01.00

Endemic Chickenpox Infection on a Cancer Ward

TO THE EDITOR — Second episodes of varicella after a definite primary exposure to chickenpox are well known in immunosuppressed children. We here report an endemic outbreak in adult patients with cancer. The onset of one part of the endemia was a widespread herpes-zoster infection in the left cervical dermatome (located at the C 3, C 4, and C 5 vertebrae) of patient 1, a 50-year-old man being treated for Hodgkin's disease. Concurrently residing in the same room was patient 2, a 25-year-old man receiving chemotherapy for abdominal liposarcoma, who had no history of the disease but developed typical chickenpox 21 days later, after having been discharged. The course of his disease was complicated by varicella-related pneumonitis with bilateral "fluffy" nodular infiltrations (as indicated