



## Images in cardio-thoracic surgery

## Scimitar syndrome in association with intrapulmonary sequestration

 Michel Gonzalez <sup>a,\*</sup>, Pierre Bize <sup>b</sup>, Hans-Beat Ris <sup>a</sup>, Thorsten Krueger <sup>a</sup>
<sup>a</sup>Service of Thoracic and Vascular Surgery, Centre Hospitalier Universitaire Vaudois Lausanne, Switzerland

<sup>b</sup>Department of Radiology, Centre Hospitalier Universitaire Vaudois Lausanne, Switzerland

Received 3 September 2010; received in revised form 9 November 2010; accepted 11 November 2010; Available online 11 January 2011

Keywords: Pulmonary sequestration; Scimitar syndrome

A 62-year-old woman was referred for repetitive hemoptysis. Chest computed tomography scan revealed intrapulmonary sequestration of the right lower lobe with an aberrant artery arising from the sub-diaphragmatic descending-

ing aorta (Fig. 1(A) and (B)). In addition, the right lower lobe showed an anomalous venous drainage directly in the inferior vena cava (Scimitar syndrome) (Fig. 2(A) and (B)) (3D video).

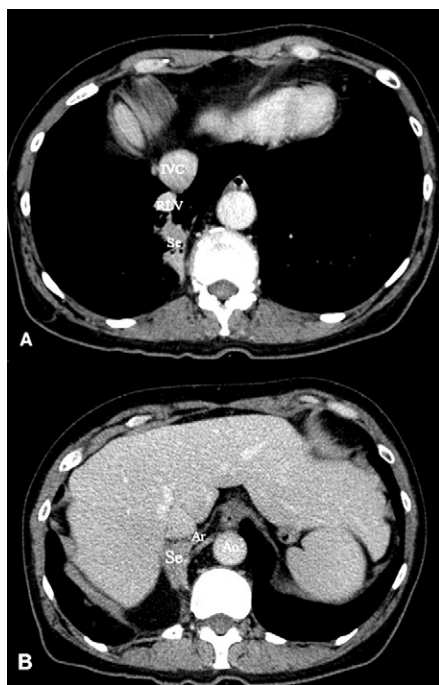


Fig. 1. (A) Chest computed tomography scan showed intrapulmonary sequestration (Se) of the right lower lobe. The right lower vein (RLV) is anterior to the sequestration with drainage directly in the inferior vena cava. (B) Vascularisation of the sequestration by an aberrant artery (Ar) arising from the sub-diaphragmatic descending aorta (Ao).

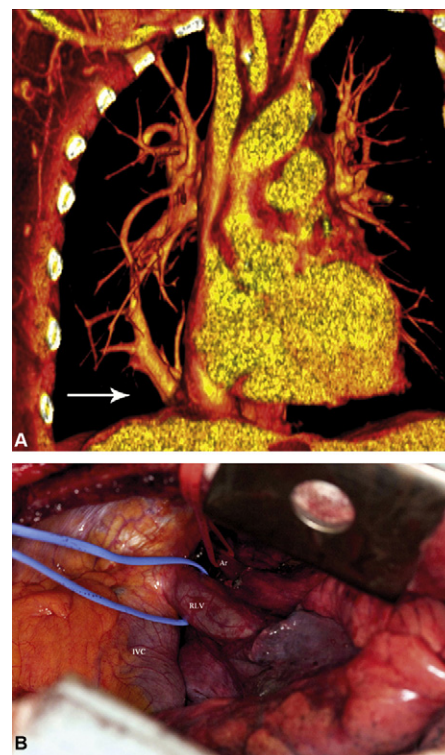


Fig. 2. (A) Three dimensional reconstructed computed tomography image showing the venous drainage of the right lower lobe directly in the inferior vena cava (white arrow). (B) Intra-operative view with aberrant artery of the intrapulmonary sequestration (Ar) and venous drainage of the right lower lobe (RLV) directly in the inferior vena cava (IVC) just above the diaphragm. The patient underwent right lower lobectomy with uneventful recovery.

\* Corresponding author. Address: Thoracic and Vascular Surgery Service, Centre Hospitalier Universitaire Vaudois, Rue du Bugnon 46, 1011-Lausanne, Switzerland. Tel.: +41 79 556 38 20; fax: +41 21 314 23 58.

E-mail address: [Michel.Gonzalez@chuv.ch](mailto:Michel.Gonzalez@chuv.ch) (M. Gonzalez).

## Appendix A. Supplementary data

Supplementary data associated with this article can be found, in the online version, at [doi:10.1016/j.ejcts.2010.11.033](https://doi.org/10.1016/j.ejcts.2010.11.033).