



# Impact of incomplete stent apposition on long-term clinical outcome after drug-eluting stent implantation

Stéphane Cook<sup>1†</sup>, Parham Eshtehardi<sup>1†</sup>, Bindu Kalesan<sup>1,2</sup>, Lorenz Räber<sup>1</sup>, Peter Wenaweser<sup>1</sup>, Mario Togni<sup>1</sup>, Aris Moschovitis<sup>1</sup>, Rolf Vogel<sup>1</sup>, Christian Seiler<sup>1</sup>, Franz R. Eberli<sup>3</sup>, Thomas Lüscher<sup>3</sup>, Bernhard Meier<sup>1</sup>, Peter Jüni<sup>2,4</sup>, and Stephan Windecker<sup>1,4\*</sup>

<sup>1</sup>Department of Cardiology, Bern University Hospital, Bern 3010, Switzerland; <sup>2</sup>Institute of Social and Preventive Medicine, University of Bern, Bern, Switzerland;

<sup>3</sup>Department of Cardiology, University Hospital, Zurich, Switzerland; and <sup>4</sup>Clinical Trials Unit, Bern University Hospital, Bern, Switzerland

Received 16 January 2011; revised 1 September 2011; accepted 8 December 2011; online publish-ahead-of-print 26 January 2012

This paper was guest edited by William Wijns, co-director Cardiovascular Center, OLV Ziekenhuis 117, Mooreselbann, Aalst B9300, Belgium

See page 1305 for the editorial comment on this article (doi:10.1093/eurheartj/ehs039)

## Aims

Late acquired incomplete stent apposition (ISA) is more common after drug-eluting stent (DES) than bare metal stent (BMS) implantation and has been associated with vascular hypersensitivity and stent thrombosis (ST). We investigated the impact of incidentally discovered ISA as assessed by intravascular ultrasound (IVUS) 8 months after DES implantation on the long-term clinical outcome.

## Methods and results

A total of 194 patients with 221 lesions were prospectively followed through 5 years. At 8 months, IVUS showed evidence of ISA among 37 patients with 39 lesions (18%) (mean  $ISA_{max}$   $4.7 \pm 5.0$  mm<sup>2</sup>), whereas no ISA was observed among 157 patients with 182 lesions. Incomplete stent apposition was more prevalent among segments treated with sirolimus-eluting ( $n = 103$ ) than paclitaxel-eluting stents ( $n = 118$ ) (27 vs. 9%,  $P = 0.001$ ). Between IVUS investigation at the 8-month and 5-year follow-up, major adverse cardiac events occurred more frequently in patients with (18.9%,  $n = 7$ ) than without ISA (7.0%,  $n = 11$ ) (HR = 2.71, 95% CI: 1.05–6.96,  $P = 0.031$ ). While there were no differences with respect to death, the rate of myocardial infarction was higher among patients with (13.5%,  $n = 5$ ) than without ISA (1.9%,  $n = 3$ ) (HR = 7.53, 95% CI: 1.79–31.6,  $P = 0.001$ ). Very late ST was more common among patients with than without ISA [Academic Research Consortium-definite ST:13.5% ( $n = 5$ ) vs. 0.6% ( $n = 1$ ) HR = 23.2, 95% CI: 2.65–203,  $P < 0.001$ ].

## Conclusion

In the present study, the presence of ISA as assessed by IVUS 8 months after DES implantation was associated with a higher rate of myocardial infarction and very late stent thrombosis during long-term follow-up. The prognostic impact of ISA on long-term clinical outcomes requires further investigation.

## Keywords

Coronary artery • Drug-eluting stent • Intravascular ultrasound • Incomplete stent apposition

## Introduction

Incomplete stent apposition (ISA) is a morphological feature assessed by intravascular imaging, such as intravascular ultrasound (IVUS), or optical coherence tomography and describes the lack of

contact between stent struts and the adjacent arterial wall. The timing of intravascular imaging relative to the index procedure allows to distinguish between post-procedural, persistent, and late acquired phenotypes. Incomplete stent apposition assessed by IVUS has been reported in up to one-third of treated segments

† These authors contributed equally to this article.

\* Corresponding author. Tel: +41 31 632 44 97, Fax: +41 31 632 47 70, E-mail: [stephan.windecker@insel.ch](mailto:stephan.windecker@insel.ch)

Published on behalf of the European Society of Cardiology. All rights reserved. © The Author 2012. For permissions please email: [journals.permissions@oup.com](mailto:journals.permissions@oup.com)

after drug-eluting stents (DES) implantation,<sup>1</sup> and has been related to various causes such as inhomogeneous stent expansion at the time of stent implantation, dissolution of thrombus behind stent struts in the setting of acute myocardial infarction (MI), chronic stent recoil, or positive arterial remodelling with an increase in the external elastic membrane (EEM) out of proportion to the increase in peri-stent plaque and media.<sup>2,3</sup> The latter phenomenon may be of particular importance in patients treated with DES.

An exceedingly high incidence of ISA (>75%) has been observed among patients presenting with very late stent thrombosis (ST).<sup>3-5</sup> In addition, the extent of positive vessel remodelling associated with ISA among patients suffering from very late ST has been correlated with the amount of inflammatory infiltrates at the vicinity of stent struts, suggesting an underlying vascular toxicity in the pathogenesis of very late ST. Conversely, the clinical impact of incidentally discovered ISA in otherwise asymptomatic patients is debated. Late acquired ISA has been reported in 2–5% of segments after bare metal stent (BMS)<sup>6,7</sup> and in 7–21% after DES implantation,<sup>8,9</sup> and several studies failed to observe untoward adverse events related to ISA.<sup>8-14</sup> However, these studies were limited by small patient populations and a short follow-up duration, prohibiting firm conclusions. The aim of the present study was therefore to investigate the long-term clinical outcome up to 5 years among patients with compared with those without ISA as assessed by IVUS 8 months after DES implantation.

## Methods

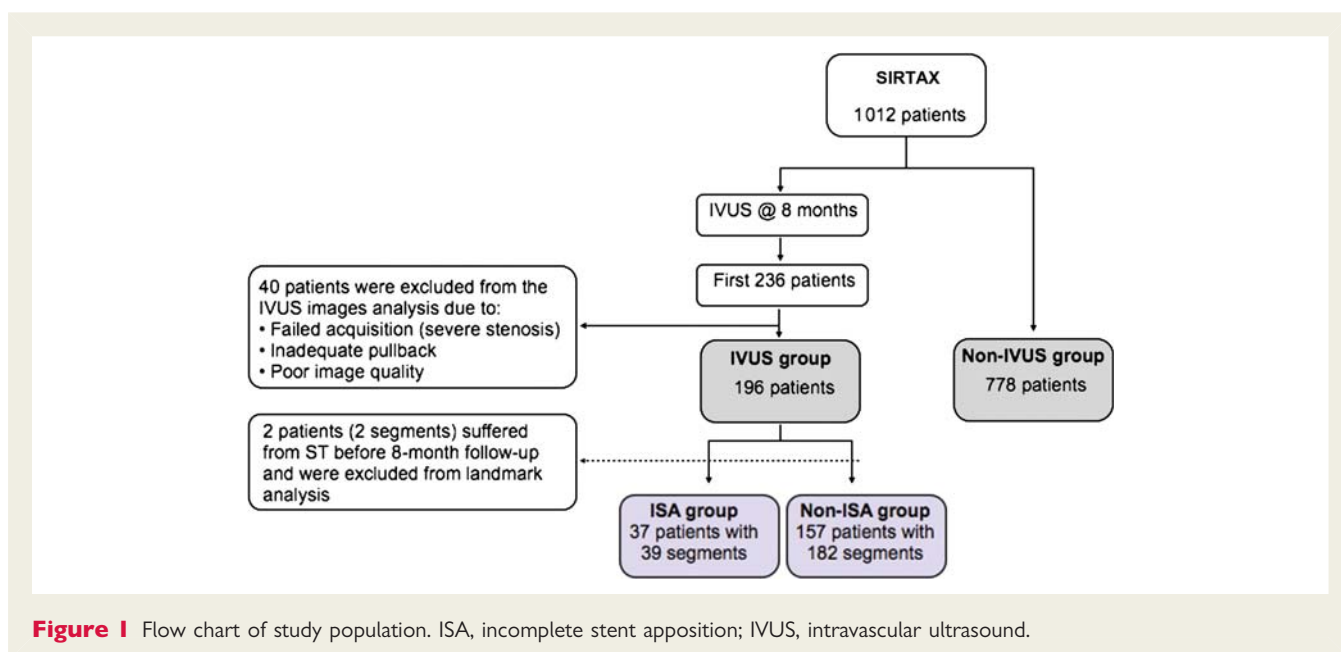
### Patient population

Patients of the present study constitute a subpopulation of the SIRTAX trial.<sup>15</sup> In this prospective, single blind, randomized trial, 1012 patients were treated with either sirolimus-eluting (SES) (Cypher and Cypher Select, Cordis, Miami Lakes, Florida) (503 patients), or

paclitaxel-eluting stents (PES) (Taxus Express 2, Boston Scientific Corp., Natick, Massachusetts) (509 patients). Of the overall SIRTAX trial population, 540 patients underwent repeat angiography at 8 months. The first 234 patients (323 segments) of the angiographic follow-up cohort also underwent IVUS investigation (Figure 1). After exclusion of 38 patients (50 segments) from the IVUS image analysis due to failed acquisition, inadequate pullback, or poor image quality, IVUS analysis at 8 months was possible in 196 patients (223 segments). For the purpose of the current analysis, two patients who suffered from ST between the time of stent implantation and IVUS investigation at 8-month follow-up were excluded from the analysis. The remaining 194 patients (free of MI at 8 months) with 221 DES segments constitute the patient population with a landmark analysis of clinical outcome between 8 months after DES implantation (time point of IVUS investigation) and 5 years of follow-up. We compared the baseline characteristics and clinical outcome between patients with and without IVUS investigation at 8 months, and between patients with and without ISA. Of note, IVUS imaging was not performed at baseline but only at the time of angiographic follow-up precluding the differentiation between persistent and late acquired ISA. The institutional review board of both participating institutions approved the study. All patients provided written informed consent. The study complied with the declaration of Helsinki regarding investigations in humans and was approved by the Ethics Committees at the Bern University Hospital and University Hospital Zurich, both in Switzerland.

### Quantitative coronary angiographic analysis

Coronary angiograms were digitally recorded at baseline, immediately after the procedure, and at follow-up and analysed by personnel unaware of the type of the implanted stent. Digital angiograms were analysed with the use of an automated edge-detection system (CAAS II, Pie Medical Imaging). Quantitative measurements included the diameter of the reference vessel, the minimal luminal diameter, and per cent diameter stenosis (defined as the diameter of the reference vessel minus the minimal luminal diameter, divided by the reference diameter and multiplied by 100).



**Figure 1** Flow chart of study population. ISA, incomplete stent apposition; IVUS, intravascular ultrasound.

## Intravascular ultrasound image acquisition and analysis

The protocol sequence to obtain IVUS imaging at the 8-month follow-up has been previously described in detail.<sup>3</sup> Briefly, the IVUS catheter (Eagle Eye® scanner, Volcano Therapeutics, Inc.) was positioned >10 mm beyond the distal edge of the study stent and was withdrawn using a motorized pullback (0.5 mm/s). Quantitative IVUS analyses were performed off-line according to the criteria of the clinical expert consensus document on IVUS using computerized planimetry (In-Vision View® 1.0, Medimatic, Inc.).<sup>16</sup> Quantitative measures included the EEM, lumen, and stent cross-sectional area (CSA) at stented and reference segments. The image slice with the smallest stent and lumen CSA, and the image slice with the greatest EEM were also analysed. The proximal and distal reference segments selected for the analysis were the most normal-appearing cross-sections within 10 mm proximal or distal to the lesion but before any side branch. Incomplete stent apposition was defined as lack of contact between at least one strut and the underlying arterial wall intima that did not overlap a side branch with evidence of blood flow behind the strut. The length of the ISA site was measured from multiple longitudinal views. When the patient had ISA sites separated from each other by areas of completely apposed stented segments, the total length of the ISA was defined as the sum of the lengths of each ISA segment. In the segment with ISA, the lumen contours were delineated within and outside the stent strut boundaries.<sup>17</sup> Within the ISA segment, stent and lumen CSA were measured every 0.5 mm.

## Study endpoints and definitions

All patients were prospectively followed per protocol at 1, 6, and 9 months, and 1, 2, 3, 4, and 5 years after stent implantation. An independent clinical events committee blinded to treatment assignment and IVUS findings adjudicated all endpoints. Major adverse cardiac

events (MACEs) were defined as the composite of cardiac death, MI, or clinically driven target lesion revascularization (TLR). Target lesion revascularization and target vessel revascularization (TVR) were considered to be clinically driven if the stenosis of the target lesion or vessel was >50% on the basis of quantitative coronary angiography in the presence of ischaemic signs or symptoms, or if there was a stenosis of >70% in the absence of ischaemic signs or symptoms. Target lesion revascularization was defined as a repeated revascularization based on a stenosis within the stent or within the 5-mm borders proximal or distal to the stent. The diagnosis of MI after the intervention was established whenever new Q-waves of at least 0.4 s duration in at least two contiguous leads appeared on the electrocardiogram with an elevated creatine kinase MB fraction level, or in the absence of pathological Q-waves, an elevation in creatine kinase levels to more than twice the upper limit of normal with an elevated creatine kinase MB or troponin I level. Definite ST fulfilled the Academic Research Consortium (ARC)<sup>18</sup> criteria and was defined as an acute coronary syndrome with angiographic documentation of either target vessel occlusion or thrombus within or adjacent to the previously successfully stented segment.

## Statistical analysis

Normally distributed variables were analysed using parametric tests and non-normally distributed data using non-parametric tests. Continuous variables are expressed as mean  $\pm$  standard deviation and differences were compared using Student's *t* test or Mann–Whitney *U* test. Categorical variables are expressed as counts and percentages and differences were assessed by the Fisher exact test or  $\chi^2$  test, as appropriate. The comparison between the groups were carried out using a mixed model and *P*-values are derived using maximum likelihood logistic and linear-regression models based on robust standard errors that allow for the correlation of multiple lesions within patients. Event-free survival was analysed with the Kaplan–Meier method, and

**Table 1** Baseline clinical characteristics among non-intravascular ultrasound participants and intravascular ultrasound participants in the SIRTAX study, and among patients with and without incomplete stent apposition in the intravascular ultrasound study

Patients	SIRTAX study (n = 972)			IVUS study (n = 194)		
	IVUS (n = 194)	Non-IVUS (n = 778)	P-value	ISA (n = 37)	Non-ISA (n = 157)	P-value
Age, mean $\pm$ SD	59.5 $\pm$ 10.4	62.9 $\pm$ 11.2	0.001	58.0 $\pm$ 9.3	59.9 $\pm$ 10.6	0.32
Male [n (%)]	159 (82.0)	587 (75.5)	0.055	30 (81.1)	129 (82.2)	0.88
Hypertension [n (%)]	105 (54.1)	493 (63.4)	0.018	16 (43.2)	89 (56.7)	0.14
Current smoking [n (%)]	81 (41.8)	274 (35.2)	0.091	20 (54.1)	61 (38.9)	0.09
Diabetes mellitus [n (%)]	32 (16.5)	163 (21.0)	0.17	5 (13.5)	27 (17.2)	0.59
Dyslipidaemia [n (%)]	119 (61.3)	453 (58.2)	0.43	24 (64.9)	95 (60.5)	0.62
Family history of CAD [n (%)]	78 (39.8)	295 (37.9)	0.63	16 (43.2)	61 (38.9)	0.62
Indication at baseline [n (%)]			0.27			0.72
Stable angina pectoris	104 (53.6)	364 (46.8)		18 (48.6)	86 (54.8)	
ACS—STEMI	42 (21.7)	180 (23.1)		10 (27.0)	32 (20.4)	
ACS—NSTEMI	41 (21.1)	186 (23.9)				
Unstable	7 (3.6)	48 (6.2)		7 (18.9)	34 (21.7)	
Multivessel disease [n (%)]	118 (60.8)	459 (59.0)	0.64	24 (64.9)	94 (59.9)	0.58
LVEF, mean% $\pm$ SD	58.3 $\pm$ 10.3	56.3 $\pm$ 12.1	0.029	57.1 $\pm$ 9.5	58.6 $\pm$ 10.5	0.41

ACS, acute coronary syndrome; CAD, coronary artery disease; IVUS, intravascular ultrasound study; LVEF, left ventricular ejection fraction; (N-) STEMI, (non-)ST-segment elevation myocardial infarction; SD, standard deviation.

the corresponding probability value was obtained from a log-rank test. The Mantel–Cox method was used to estimate hazard ratios and 95% confidence intervals for comparisons of clinical outcomes between groups and the log-rank test to calculate corresponding *P*-values. No adjustments were made for multiple comparisons in secondary analyses; *P*-values are two-sided; the significance level was set at 0.05. Analyses were performed in STATA (Stata, Inc., College Station, TX, USA).

## Results

### Baseline clinical, angiographic, and procedural characteristics

Baseline clinical and angiographic characteristics of patients undergoing IVUS at 8 months and those not undergoing IVUS are summarized in Table 1. Compared with patients not undergoing IVUS, those undergoing IVUS were younger ( $59.5 \pm 10.4$  vs.  $62.9 \pm 11.2$  years,  $P = 0.001$ ), more frequently male (82.0 vs. 75.5%,  $P = 0.055$ ), less frequently hypertensive (54.1 vs. 63.4%,  $P = 0.018$ ), and had better left ventricular function ( $58.3 \pm 10.3$  vs.  $56.3 \pm 12.1\%$ ,  $P = 0.029$ ). A total of 194 patients with 221

segments treated with 103 SES and 118 PES underwent IVUS 8 months after DES implantation. Among patients undergoing IVUS, baseline angiographic variables were well balanced between SES and PES. Lesion length amounted to  $12.9 \pm 6.8$  and  $14.2 \pm 8.4$  mm in SES- and PES-treated segments, respectively ( $P = 0.24$ ), and reference vessel diameter was  $2.81 \pm 0.43$  and  $2.83 \pm 0.44$  mm, respectively ( $P = 0.25$ ). Stent length (SES:  $18.5 \pm 8.5$  mm vs. PES:  $19.1 \pm 10.1$  mm,  $P = 0.64$ ) and stent diameter (SES:  $2.93 \pm 0.32$  mm vs. PES:  $2.97 \pm 0.34$  mm,  $P = 0.32$ ) were similar for both groups. Maximal implantation pressure was slightly higher in the SES group ( $14.1 \pm 2.6$  vs.  $13.4 \pm 2.7$  atm,  $P = 0.21$ ).

### Intravascular ultrasound findings at 8-month follow-up

Incomplete stent apposition was documented in 39 segments (18% of stented segments) of 37 patients at the 8-month IVUS investigation and constitutes the ISA group. One hundred fifty-seven patients with 182 segments showed no evidence of ISA (non-ISA group). Baseline clinical characteristics were similar for patients with or without ISA (Table 1). Of note, there was no difference with respect to age, diabetes mellitus, dyslipidaemia, and acute coronary syndrome as indication for the index procedure. While baseline angiographic characteristics were comparable for patients with or without ISA, stent length was longer in patients with than without ISA ( $22.1 \pm 11.6$  vs.  $18.1 \pm 8.7$  mm,  $P = 0.048$ ) (Table 2). Intravascular ultrasound data at 8 months are summarized in Table 3. We observed no difference in terms of reference vessel

**Table 2** Baseline angiographic and procedural characteristics in segments with and without incomplete stent apposition

Segments	ISA (n = 39)	Non-ISA (n = 182)	<i>P</i> -value
Target vessel, n (%)			0.68
Left anterior descending artery	15 (39)	81 (45)	
Right coronary artery	14 (36)	63 (35)	
Left circumflex artery	10 (26)	38 (21)	
Before procedure			
Lesion length, mm $\pm$ SD	$13.6 \pm 6.4$	$13.4 \pm 7.3$	0.88
RVD, mm $\pm$ SD	$2.82 \pm 0.42$	$2.86 \pm 0.44$	0.61
MLD, mm $\pm$ SD	$0.35 \pm 0.38$	$0.48 \pm 0.42$	0.043
Stenosis, % $\pm$ SD	$87.1 \pm 14.3$	$83.3 \pm 13.5$	0.12
During procedure			
Type of stent, n (%)			0.001
SES	28 (72)	75 (41)	
PES	11 (28)	107 (59)	
Stent diameter, mm $\pm$ SD	$2.95 \pm 0.30$	$2.96 \pm 0.34$	0.82
Stent length, mm $\pm$ SD	$22.1 \pm 11.6$	$18.1 \pm 8.7$	0.048
Maximal balloon pressure, atm $\pm$ SD	$13.8 \pm 2.9$	$14.2 \pm 2.6$	0.48
Maximal balloon diameter/RVD (balloon to artery ratio), mean $\pm$ SD	$1.12 \pm 0.15$	$1.13 \pm 0.20$	0.27

ISA, incomplete stent apposition; MLD, minimal lumen diameter; PES, paclitaxel-eluting stent; RVD, reference vessel diameter; SD, standard deviation; SES, sirolimus-eluting stent. *P*-values were derived using maximum-likelihood logistic and linear-regression models based on robust standard errors that allowed for the correlation of multiple segments within a patient.

**Table 3** Intravascular ultrasound measurements at 8 months

Segments	ISA (n = 39)	Non-ISA (n = 182)	<i>P</i> -value
Reference segment			
EEM-CSA, mm <sup>2</sup> $\pm$ SD	$15.3 \pm 4.7$	$14.4 \pm 4.7$	0.29
Lumen-CSA, mm <sup>2</sup> $\pm$ SD	$9.6 \pm 3.7$	$8.0 \pm 2.8$	0.015
Stent segment			
EEM-CSA, mm <sup>2</sup> $\pm$ SD	$17.1 \pm 4.6$	$15.8 \pm 4.6$	0.14
Stent-CSA, mm <sup>2</sup> $\pm$ SD	$6.9 \pm 1.4$	$6.9 \pm 2.0$	0.83
Minimum Stent-CSA, mm <sup>2</sup> $\pm$ SD	$6.2 \pm 1.4$	$6.1 \pm 1.9$	0.86
Minimum Stent-CSA <5 mm <sup>2</sup> , n (%)	4 (10.3)	44 (24.2)	0.061
Stent expansion $\pm$ SD	$0.7 \pm 0.2$	$0.8 \pm 0.2$	0.001
Remodelling index $\pm$ SD	$1.3 \pm 0.3$	$1.3 \pm 0.7$	0.68
In-stent lumen-CSA, mm <sup>2</sup> $\pm$ SD	$6.9 \pm 1.4$	$6.7 \pm 1.9$	0.50
NIH, mm <sup>2</sup> $\pm$ SD	$0.1 \pm 0.2$	$0.2 \pm 0.5$	0.004
Percentage of stent volume obstruction, % $\pm$ SD	$1.3 \pm 2.3$	$2.8 \pm 5.0$	0.004

CSA, cross-sectional area; EEM, external elastic membrane; ISA, incomplete stent apposition; NIH, neointimal hyperplasia; SD, standard deviation. *P*-values were derived using maximum-likelihood logistic and linear-regression models based on robust standard errors that allowed for the correlation of multiple segments within a patient.

and stented segment CSA, whereas patients with ISA showed a lower degree of stent expansion ( $0.7 \pm 0.2$  vs.  $0.8 \pm 0.2$ ,  $P = 0.001$ ) (Table 3). Incomplete stent apposition was longer and three times more frequent in SES- than PES-treated segments (Table 4). Similarly, stent-CSA (PES:  $7.3 \pm 1.9$  vs. SES:  $6.4 \pm 1.8$  mm<sup>2</sup>,  $P = 0.001$ ) and stent expansion index (PES:  $0.87 \pm 0.21$  vs. SES:  $0.77 \pm 0.19$ ,  $P = 0.002$ ) were lower for SES- than PES-treated segments.

## Clinical outcomes

The long-term clinical outcomes through 5 years of patients with and without IVUS investigation at 8 months as well as of patients with and without ISA are summarized in Table 5. Compared with patients who did not undergo IVUS at 8 months, those with IVUS had a lower rate of MACE (12.4 vs. 21.9%, HR = 0.53, 95% CI: 0.34–0.81,  $P = 0.003$ ), cardiac death (1.0 vs. 7.1%, HR = 0.14, 95% CI: 0.03–0.57,  $P = 0.001$ ) and a trend towards fewer MIs (4.1 vs. 7.2%, HR = 0.47, 95% CI: 0.26–1.14,  $P = 0.10$ ), but a similar risk of definite ST (3.1 vs. 4.5%, HR = 0.65, 95% CI: 0.27–1.56,  $P = 0.33$ ).

At 5 years of follow-up, 24 patients (12.4%) of the overall IVUS group had suffered from at least one MACE event. There were no significant differences regarding overall mortality, cardiac death, TLR, TVR, and MACE among patients with or without ISA. However, MI was more common among patients with than without ISA (13.5 vs. 1.9%, HR = 7.53, 95% CI: 1.79–31.6,  $P = 0.001$ ). Figure 2 shows the cumulative frequency of MACE and the composite of cardiac death or MI up to 5 years. In terms of cardiac death or MI, we did not observe any difference between patients with and without ISA up to 2 years of follow-up. However, event curves did separate beyond 2 years and continued to diverge up to 5 years in disfavour of patients with ISA. The increased rate of MI was directly related to an increased rate of very late ST in patients with ISA when compared with those without ISA (ARC-definite ST: 13.5 vs. 0.6%, HR = 23.2, 95% CI: 2.65–203,  $P < 0.001$ ). We observed no significant difference in the rate of ST between the two stent types [SES 4 (4.4%) when

compared with PES 2 (1.9%), HR = 0.44 95% CI: 0.08–2.43,  $P = 0.34$ ]. Figure 3 demonstrates examples of patients with incidental ISA documented at the 8-month follow-up suffering from very late ST during the subsequent clinical follow-up period.

## Discussion

The present study with the longest reported follow-up of patients with incidentally discovered ISA has the following principal findings:

- (1) Compared with the unselected all-comer patient population included into the SIRTAX trial, patients enrolled in the IVUS substudy had a lower cardiovascular risk profile and consequently showed a lower risk of MACE during extended clinical follow-up.
- (2) The presence of ISA as detected by IVUS at 8 months after DES implantation is associated with an impaired clinical outcome. The increased risk of death or MI was directly related to the increased risk of very late ST.

### Selection bias of patients included into the intravascular ultrasound substudy

Enrollment into the IVUS substudy was limited to the first 234 patients included into the SIRTAX trial returning for follow-up angiography at 8 months. This resulted in a selection bias towards the inclusion of lower risk patients compared with the overall study population. This phenomenon has been previously observed in some<sup>19,20</sup> but not all<sup>9,21,22</sup> IVUS studies and has been related to the omission of IVUS among patients with severely obstructive vessels and among patients with MACE.

### Incidence of incomplete stent apposition

Incomplete stent apposition was found in 18% of the patients in the current analysis and was particularly frequent (approximately one-quarter) among patients treated with SES, a finding that is consistent with previous reports. In the RAVEL study, 21% of SES-treated segments showed evidence of ISA.<sup>9</sup> In a pooled analysis of 180 SES included into RAVEL, e-SIRIUS, and SIRIUS, Hoffmann et al.<sup>23</sup> reported a 25% incidence of ISA after SES implantation. The incidence of ISA 6–9 months after implantation of PES has been reported to range from 4.4 to 8.0% in the TAXUS-II and -IV trials.<sup>14,24,25</sup> One possible explanation of an increased incidence of ISA in SES-compared with PES-treated segments may be the lower reported rate of late loss in SES compared with PES. The other possible explanation may be related to inhomogeneous stent expansion at the time of stent implantation or chronic recoil. Thus, we observed smaller stent-CSA, stent expansion index and in-stent lumen-CSA with SES than PES despite a similar stent diameter and a somewhat higher implantation pressure with SES. These findings are consistent with data previously reported by Cheneau et al.<sup>25</sup>

### Incomplete stent apposition and stent thrombosis

Very late ST after coronary stent implantation is a complex and multifactorial process. Incomplete stent apposition has been associated with delayed endothelial healing and drug-induced

**Table 4** Incomplete stent apposition in paclitaxel-eluting stents and sirolimus-eluting stents

Segments	All (n = 221)	PES (n = 103)	SES (n = 118)	P-value
ISA, n (%)	39 (18%)	11 (9%)	28 (27%)	0.001
ISA <sub>max</sub> -CSA, mm <sup>2</sup>	4.6 ± 5.0	5.0 ± 5.1	4.5 ± 5.0	0.90
Total ISA length, mm	1.9 ± 1.4	1.0 ± 0.9	2.3 ± 1.4	0.003
Maximal ISA depth, mm	0.8 ± 0.5	0.8 ± 0.6	0.8 ± 0.4	0.89
Maximal ISA angle, °	114 ± 60	92 ± 42	120 ± 63	0.076
Coronary aneurysm, n (%)	2 (1%)	0 (0%)	2 (2%)	0.57

CSA, cross-sectional area; ISA, incomplete stent apposition; ISA<sub>max</sub>-CSA, maximal ISA-CSA; PES, paclitaxel-eluting stent; SES, sirolimus-eluting stent. P-values were derived using maximum-likelihood logistic and linear-regression models based on robust standard errors that allowed for the correlation of multiple lesions within a patient. P-value for coronary aneurysm is based on Fisher's exact test.

**Table 5** Clinical outcomes

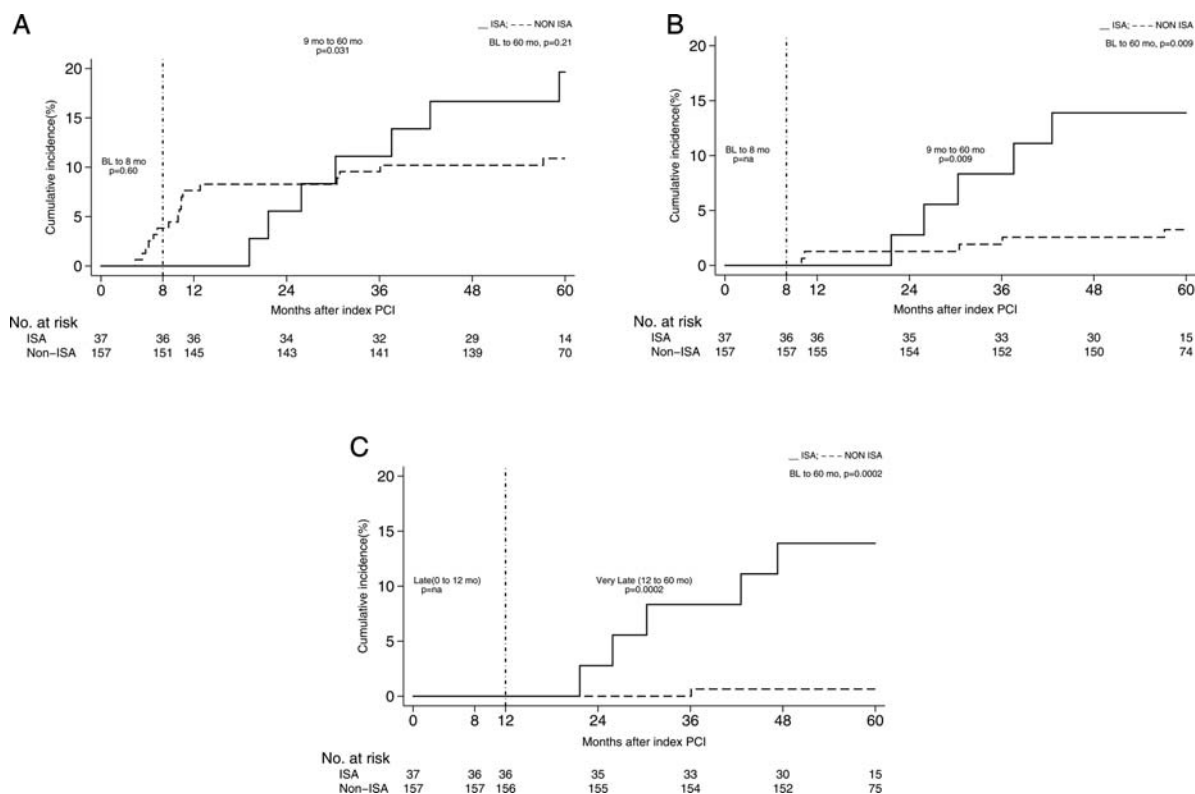
	IVUS	Non-IVUS	HR (95% CI)	P-value	ISA	Non-ISA	HR (95% CI)	P-value
No. of patients	194	778			37	157		
From stent implantation to IVUS investigation at 8 months								
Death	0 (0)	15 (1.9)	0.13 (0.01–2.11)	0.052	0 (0)	0 (0)	—	
Cardiac death	0 (0)	10 (1.3)	0.19 (0.01–3.20)	0.23	0 (0)	0 (0)	—	
MI	0 (0)	29 (3.7)	0.07 (0.00–1.06)	0.003	0 (0)	0 (0)	—	
Death or MI	0 (0)	42 (5.4)	0.04 (0.00–0.72)	<0.001	0 (0)	0 (0)	—	
Clinically driven TLR	6 (3.1)	46 (5.9)	0.51 (0.22–1.19)	0.11	0 (0)	6 (3.8)	0.31 (0.02–5.40)	0.60
Clinically driven TVR	7 (3.6)	52 (6.7)	0.52 (0.24–1.15)	0.10	0 (0)	7 (4.5)	0.27 (0.02–4.58)	0.35
MACE	6 (3.1)	63 (8.1)	0.37 (0.16–0.85)	0.015	0 (0)	6 (3.8)	0.31 (0.02–5.40)	0.60
From stent implantation to 5 years								
Death	3 (1.5)	97 (12.5)	0.12 (0.04–0.37)	<0.001	0 (0)	3 (1.9)	0.59 (0.03–11.2)	1.00
Cardiac death	2 (1.0)	55 (7.1)	0.14 (0.03–0.57)	0.001	0 (0)	2 (1.3)	0.83 (0.04–16.9)	1.00
MI	8 (4.1)	56 (7.2)	0.54 (0.26–1.14)	0.10	5 (13.5)	3 (1.9)	7.53 (1.79–31.6)	0.001
Death or MI	11 (5.7)	144 (18.5)	0.29 (0.15–0.53)	<0.001	5 (13.5)	6 (3.8)	3.75 (1.14–12.3)	0.019
Clinically driven TLR	19 (9.8)	111 (14.3)	0.64 (0.40–1.05)	0.07	6 (16.2)	13 (8.3)	1.94 (0.74–5.09)	0.17
Clinically driven TVR	27 (13.9)	133 (17.1)	0.76 (0.50–1.15)	0.20	7 (18.9)	20 (12.7)	1.48 (0.63–3.50)	0.37
MACE	24 (12.4)	170 (21.9)	0.53 (0.34–0.81)	0.003	7 (18.9)	17 (10.8)	1.75 (0.73–4.20)	0.21
From IVUS investigation to 5 years								
Death	3 (1.5)	82 (10.5)	0.14 (0.04–0.44)	<0.001	0 (0)	3 (1.9)	0.59 (0.03–11.2)	1.00
Cardiac death	2 (1.0)	45 (5.8)	0.17 (0.04–0.70)	0.005	0 (0)	2 (1.3)	0.83 (0.04–16.9)	1.00
MI	8 (4.1)	27 (3.5)	1.09 (0.50–2.41)	0.82	5 (13.5)	3 (1.9)	7.53 (1.79–31.6)	0.001
Death or MI	11 (5.7)	102 (13.1)	0.40 (0.21–0.74)	0.003	5 (13.5)	6 (3.8)	3.75 (1.14–12.3)	0.019
Clinically driven TLR	13 (6.7)	65 (8.4)	0.74 (0.41–1.34)	0.31	6 (16.2)	7 (4.5)	3.60 (1.22–10.7)	0.013
Clinically driven TVR	20 (10.3)	81 (10.4)	0.91 (0.56–148)	0.71	7 (18.9)	13 (8.3)	2.28 (0.91–5.73)	0.07
MACE	18 (9.3)	107 (13.8)	0.61 (0.37–1.01)	0.053	7 (18.9)	11 (7.0)	2.71 (1.05–6.96)	0.031
ARC-definite stent thrombosis								
Early	0 (0)	15 (1.9)	0.13 (0.01–2.11)	0.052	0 (0)	0 (0)	—	
Late	0 (0)	3 (0.4)	0.57 (0.03–11.0)	1.0	0 (0)	0 (0)	—	
Very late	6 (3.1)	17 (2.3)	1.31 (0.52–3.33)	0.57	5 (13.5)	1 (0.6)	23.2 (2.65–203)	<0.001
Overall	6 (3.1)	35 (4.5)	0.65 (0.27–1.56)	0.33	5 (13.5)	1 (0.6)	23.2 (2.65–203)	<0.001
ARC-definite or probable stent thrombosis								
Early	0 (0)	16 (2.1)	0.12 (0.01–1.97)	0.053	0 (0)	0 (0)	—	
Late	0 (0)	3 (0.4)	0.57 (0.03–11.0)	1.0	0 (0)	0 (0)	—	
Very late	7 (3.7)	17 (2.3)	1.53 (0.64–3.70)	0.34	5 (13.5)	2 (1.3)	11.6 (2.21–60.6)	0.0002
Overall	7 (3.6)	36 (4.7)	0.74 (0.33–1.67)	0.47	5 (13.5)	2 (1.3)	11.6 (2.21–60.6)	0.0002

ARC, Academic Research Consortium; ISA, incomplete stent apposition; MACE, Major adverse clinical events: cardiac death, myocardial infarction and TLR, target-lesion revascularization; TVR, target-vessel revascularization. HR, hazard ratios using the Mantel–Cox method. Relative risks were calculated after a continuity correction of 0.5 when one of the cell sizes was zero; P-values are from two-sided Fisher's exact test.

hypersensitivity reactions with exaggerated positive vessel remodelling. The impact of ISA on the long-term clinical outcome has been the subject of debate since its initial description.<sup>26</sup> Several studies have used IVUS to describe morphological changes of arterial structure among patients presenting with very late ST. Feres *et al.*<sup>27</sup> and two previous reports from our group<sup>3,4</sup> found an exceedingly high rate of ISA among patients presenting with very late ST. In these patients, ISA was not only found to be much more frequent but also characterized by a larger CSA with evidence of vessel remodelling. The correlation between the

extent of inflammatory infiltrates as obtained from thrombus aspirates and evidence of vessel remodelling by IVUS suggested a link between the presence of ISA and the pathogenesis of very late ST.<sup>28</sup>

In contrast, ISA as incidentally observed during routine IVUS investigation in asymptomatic patients may be related to various causes such as inhomogeneous stent expansion, dissolution of thrombus behind the stent struts or stent recoil, and its impact on the clinical outcome remains incompletely understood.<sup>2,3</sup> Several previous reports failed to demonstrate a significant adverse effect of ISA on the clinical outcome during short- to



**Figure 2** Kaplan–Meier cumulative event curves (%) for patients with (black line) and without (dashed line) incomplete stent apposition. The vertical dashed line marks the 8-month intravascular ultrasound study. (A) Major adverse clinical events: cardiac death, myocardial infarction, and target-lesion revascularization. (B) Myocardial infarction or cardiac death. (C) Definite stent thrombosis. IVUS, intravascular ultrasound; ISA, incomplete stent apposition; PCI, percutaneous coronary intervention.

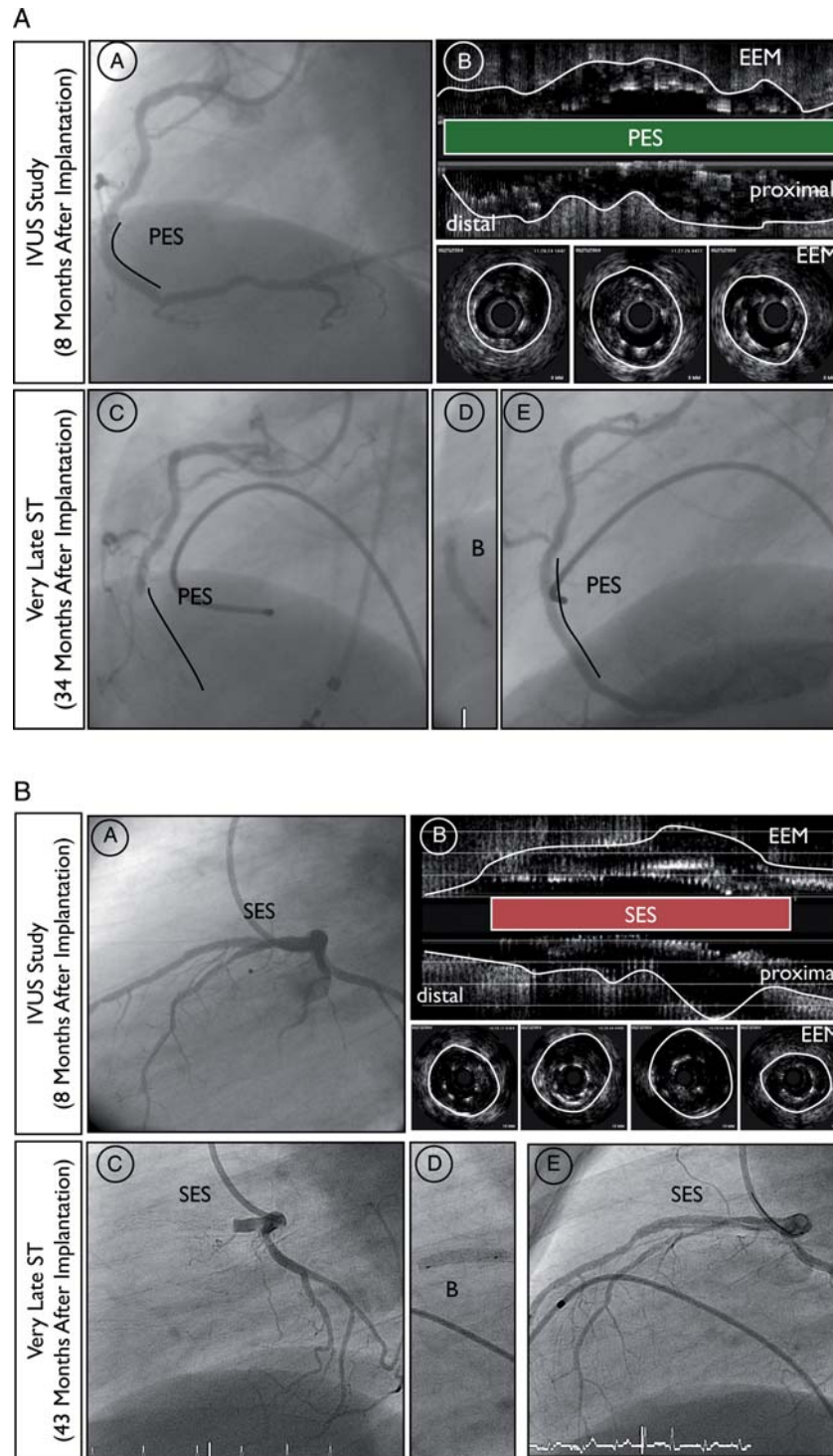
mid-term follow-up up to 12 months.<sup>8,10,14,17,29</sup> However, ISA may affect the clinical course only during longer-term follow-up especially as it relates to the incidence of very late ST. Three studies suggest an association between the observed presence of ISA and subsequent adverse events during long-term examination up to 4 years. Hoffmann *et al.*<sup>23</sup> found ISA in 45 of 180 SES segments and in 12 of 145 BMS segments at 6–8 months IVUS follow-up. Although the authors observed no difference in MACE, the rate of MI was significantly higher among patients with ISA than without ISA (16 vs. 5%,  $P = 0.02$ ). Moreover, the only single very late ST event occurred in the ISA group ( $P = NS$ ). Qian *et al.*<sup>30</sup> discovered ISA in 13 of 76 patients (17%) at 6 months after DES implantation. At  $34 \pm 5$ -month follow-up, 3 of 13 patients (23%) with ISA suffered from very late ST, MI, and TLR, and one patient died during the hospitalization. In a study of 195 patients investigated with IVUS at baseline and at 6–8-month follow-up, Siqueira *et al.*<sup>5</sup> reported the clinical outcome of 13 patients (6.7%) with persistent ISA and 10 patients (5.1%) with late acquired ISA during a mean follow-up of  $29 \pm 15$  months. Patients with late acquired ISA were significantly more prone to very late ST (20 vs. 0%,  $P = 0.002$ ), TLR (20 vs. 0.6%,  $P = 0.007$ ), and MI (20 vs. 0%,  $P = 0.002$ ) than patients without ISA ( $n = 172$ ) in this study. Finally, a meta-analysis of 17 trials showed an increased risk of ST in patients with late acquired ISA compared with those without ISA (odds ratio: 6.51, 95% CI: 1.34–34.91,  $P = 0.02$ ).<sup>31</sup>

## Incomplete stent apposition and restenosis

We found no significant difference regarding the risk for revascularization and MACE between patients with or without ISA. This is likely explained by the fact that the increased rate of ST in the ISA group was balanced by more frequent revascularization procedures in the non-ISA group. This finding is in line with reports from Hong *et al.*<sup>8</sup> and Kimura *et al.*<sup>29</sup> who observed less intimal hyperplasia in the presence of ISA.

## Study limitations

Several limitations require consideration when interpreting the results of the present study. The most important limitation is the lack of a reference IVUS examination at baseline, which precludes any conclusion regarding the cause of ISA found at IVUS follow-up, particularly as it relates to the assessment of late acquired ISA. Moreover, it should be acknowledged that the number of patients included into this IVUS study is relatively small and therefore underpowered to evaluate safety endpoints and predictors of ISA. In addition, the patients who underwent an 8-month IVUS investigation were at lower risk compared with patients who did not undergo an 8-month IVUS investigation in the SIRTAX trial. Nevertheless, we observed more frequent clinical events in patients with ISA than without ISA. Finally, ISA has been delineated



**Figure 3** Examples of very late ST in patients with incidental incomplete stent apposition documented at 8-month angiographic follow-up. (A) Angiographic and (B) intravascular ultrasound findings at the 8-month follow-up (C) angiographic findings before, (D) during and (E) at the end of the revascularization procedure at the time of very late ST. (A) Angiographic and intravascular ultrasound findings 8 months after primary PCI with implantation of paclitaxel-eluting stent in the right coronary artery of a 53-year-old male treated for acute inferior ST-elevation MI. The clinical follow-up was complicated by very late ST 34 months after the index procedure (26 months after angiographic follow-up). (B) Angiographic and intravascular ultrasound findings 8-month after PCI with implantation of sirolimus-eluting stent in the left anterior descending artery of a 43-year-old male treated for a non-ST elevation MI. The clinical follow-up was complicated by very late ST 43 months after the index procedure (35 months after angiographic follow-up). EEM, external elastic membrane; IVUS, intravascular ultrasound; PES, paclitaxel-eluting stent; SES, sirolimus-eluting stent; ST, stent thrombosis.



using IVUS, and the use of new intravascular imaging techniques with superior resolution may provide more insight into the morphology and clinical sequelae of ISA.

## Conclusion

In the present study, the presence of ISA as assessed by IVUS 8 months after DES implantation was associated with a higher rate of MI and ST during long-term follow-up through 5 years. Incomplete stent apposition appears to be one of multiple factors accounting for the ongoing risk of very late ST after DES implantation, and its prognostic impact requires further investigation.

## Funding

This work was supported by intramural research grants from Bern University Hospital and University Hospital Zurich and a grant to T.L., P.J. and S.W. by the Swiss National Science Foundation (Grant 33CM30-124112). There was no industry involvement in the design, conduct, or analysis of the study.

**Conflict of interest:** B.M. receives research grants and speaker fees from Abbott, Boston Scientific, Medtronic, and Johnson and Johnson. S.W. receives lecture and consulting fees from Abbott, Boston Scientific, Biosensors, Cordis, and Medtronic. All other authors declare that they have no conflict of interest.

## References

- van der Hoeven BL, Liem SS, Dijkstra J, Bergheanu SC, Putter H, Antoni ML, Atsma DE, Bootsma M, Zeppenfeld K, Jukema JW, Schalij MJ. Stent malapposition after sirolimus-eluting and bare-metal stent implantation in patients with ST-segment elevation myocardial infarction: acute and 9-month intravascular ultrasound results of the MISSION! intervention study. *JACC Cardiovasc Interv* 2008;**1**:192–201.
- Mintz GS. What to do about late incomplete stent apposition? *Circulation* 2007;**115**:2379–2381.
- Cook S, Wenaweser P, Togni M, Billinger M, Morger C, Seiler C, Vogel R, Hess O, Meier B, Windecker S. Incomplete stent apposition and very late stent thrombosis after drug-eluting stent implantation. *Circulation* 2007;**115**:2426–2434.
- Cook S, Ladich E, Nakazawa G, Eshtehardi P, Neidhart M, Vogel R, Togni M, Wenaweser P, Billinger M, Seiler C, Gay S, Meier B, Pichler WJ, Juni P, Virmani R, Windecker S. Correlation of intravascular ultrasound findings with histopathological analysis of thrombus aspirates in patients with very late drug-eluting stent thrombosis. *Circulation* 2009;**120**:391–399.
- Siqueira DA, Abizaid AA, Costa Jde R, Feres F, Mattos LA, Staico R, Abizaid AA, Tanajura LF, Chaves A, Centemero M, Sousa AG, Sousa JE. Late incomplete apposition after drug-eluting stent implantation: incidence and potential for adverse clinical outcomes. *Eur Heart J* 2007;**28**:1304–1309.
- Shah VM, Mintz GS, Apple S, Weissman NJ. Background incidence of late malapposition after bare-metal stent implantation. *Circulation* 2002;**106**:1753–1755.
- Nakamura M, Kataoka T, Honda Y, Bonneau HN, Hibi K, Kitamura K, Tamai H, Aizawa T, Yock PG, Fitzgerald PJ. Late incomplete stent apposition and focal vessel expansion after bare metal stenting. *Am J Cardiol* 2003;**92**:1217–1219.
- Hong MK, Mintz GS, Lee CW, Park DW, Park KM, Lee BK, Kim YH, Song JM, Han KH, Kang DH, Cheong SS, Song JK, Kim JJ, Park SW, Park SJ. Late stent malapposition after drug-eluting stent implantation: an intravascular ultrasound analysis with long-term follow-up. *Circulation* 2006;**113**:414–419.
- Serruys PW, Degertekin M, Tanabe K, Abizaid A, Sousa JE, Colombo A, Guagliumi G, Wijns W, Lindeboom WK, Ligthart J, de Feyter PJ, Morice MC. Intravascular ultrasound findings in the multicenter, randomized, double-blind RAVEL (RAnomized study with the sirolimus-eluting VELOCITY balloon-expandable stent in the treatment of patients with de novo native coronary artery lesions) trial. *Circulation* 2002;**106**:798–803.
- Ako J, Morino Y, Honda Y, Hassan A, Sonoda S, Yock PG, Leon MB, Moses JW, Bonneau HN, Fitzgerald PJ. Late incomplete stent apposition after sirolimus-eluting stent implantation: a serial intravascular ultrasound analysis. *J Am Coll Cardiol* 2005;**46**:1002–1005.
- Hong MK, Mintz GS, Lee CW, Kim YH, Lee SW, Song JM, Han KH, Kang DH, Song JK, Kim JJ, Park SW, Park SJ. Incidence, mechanism, predictors, and long-term prognosis of late stent malapposition after bare-metal stent implantation. *Circulation* 2004;**109**:881–886.
- Hong MK, Mintz GS, Lee CW, Park DW, Lee SW, Kim YH, Kang DH, Cheong SS, Song JK, Kim JJ, Park SW, Park SJ. Impact of late drug-eluting stent malapposition on 3-year clinical events. *J Am Coll Cardiol* 2007;**50**:1515–1516.
- Steinberg DH, Mintz GS, Mandinov L, Yu A, Ellis SG, Grube E, Dawkins KD, Ormiston J, Turco MA, Stone GW, Weissman NJ. Long-term impact of routinely detected early and late incomplete stent apposition: an integrated intravascular ultrasound analysis of the TAXUS IV, V, and VI and TAXUS ATLAS workhorse, long lesion, and direct stent studies. *JACC Cardiovasc Interv* 2010;**3**:486–494.
- Tanabe K, Serruys PW, Degertekin M, Grube E, Guagliumi G, Urbaszek W, Bonnier J, Lablanche JM, Siminiak T, Nordrehaug J, Figulla H, Drzewiecki J, Banning A, Hauptmann K, Dudek D, Bruining N, Hamers R, Hoye A, Ligthart JM, Disco C, Koglin J, Russell ME, Colombo A. Incomplete stent apposition after implantation of paclitaxel-eluting stents or bare metal stents: insights from the randomized TAXUS II trial. *Circulation* 2005;**111**:900–905.
- Windecker S, Remondino A, Eberli FR, Juni P, Raber L, Wenaweser P, Togni M, Billinger M, Tuller D, Seiler C, Roffi M, Corti R, Sutsch G, Maier W, Luscher T, Hess OM, Egger M, Meier B. Sirolimus-eluting and paclitaxel-eluting stents for coronary revascularization. *N Engl J Med* 2005;**353**:653–662.
- Mintz GS, Nissen SE, Anderson WD, Bailey SR, Erbel R, Fitzgerald PJ, Pinto FJ, Rosenfield K, Siegel RJ, Tuzcu EM, Yock PG. American College of Cardiology Clinical Expert Consensus Document on Standards for Acquisition, Measurement and Reporting of Intravascular Ultrasound Studies (IVUS). A report of the American College of Cardiology Task Force on Clinical Expert Consensus Documents. *J Am Coll Cardiol* 2001;**37**:1478–1492.
- Degertekin M, Serruys PW, Tanabe K, Lee CH, Sousa JE, Colombo A, Morice MC, Ligthart JM, de Feyter PJ. Long-term follow-up of incomplete stent apposition in patients who received sirolimus-eluting stent for de novo coronary lesions: an intravascular ultrasound analysis. *Circulation* 2003;**108**:2747–2750.
- Cutlip DE, Windecker S, Mehran R, Boam A, Cohen DJ, van Es GA, Steg PG, Morel MA, Mauri L, Vranckx P, McFadden E, Lansky A, Hamon M, Krucoff MW, Serruys PW. Clinical end points in coronary stent trials: a case for standardized definitions. *Circulation* 2007;**115**:2344–2351.
- Kataoka T, Grube E, Honda Y, Morino Y, Hur SH, Bonneau HN, Colombo A, Di Mario C, Guagliumi G, Hauptmann KE, Pitney MR, Lansky AJ, Sertzer SH, Yock PG, Fitzgerald PJ. 7-hexanoyleluting stent for prevention of neointimal growth: an intravascular ultrasound analysis from the Study to COmpare REstenosis rate between QueST and QuaDS-QP2 (SCORE). *Circulation* 2002;**106**:1788–1793.
- Sonoda S, Morino Y, Ako J, Terashima M, Hassan AH, Bonneau HN, Leon MB, Moses JW, Yock PG, Honda Y, Kuntz RE, Fitzgerald PJ. Impact of final stent dimensions on long-term results following sirolimus-eluting stent implantation: serial intravascular ultrasound analysis from the sirius trial. *J Am Coll Cardiol* 2004;**43**:1959–1963.
- Sabate M, Jimenez-Quevedo P, Angiolillo DJ, Gomez-Hospital JA, Alfonso F, Hernandez-Antolin R, Goicolea J, Banuelos C, Escaned J, Moreno R, Fernandez C, Fernandez-Aviles F, Macaya C. Randomized comparison of sirolimus-eluting stent vs. standard stent for percutaneous coronary revascularization in diabetic patients: the diabetes and sirolimus-eluting stent (DIABETES) trial. *Circulation* 2005;**112**:2175–2183.
- Weissman NJ, Koglin J, Cox DA, Hermlinger J, O'Shaughnessy C, Mann JT, Turco M, Caputo R, Bergin P, Greenberg J, Kutcher M, Wong SC, Strickland W, Mooney M, Russell ME, Ellis SG, Stone GW. Polymer-based paclitaxel-eluting stents reduce in-stent neointimal tissue proliferation: a serial volumetric intravascular ultrasound analysis from the TAXUS-IV trial. *J Am Coll Cardiol* 2005;**45**:1201–1205.
- Hoffmann R, Morice MC, Moses JW, Fitzgerald PJ, Mauri L, Breithardt G, Schofer J, Serruys PW, Stoll HP, Leon MB. Impact of late incomplete stent apposition after sirolimus-eluting stent implantation on 4-year clinical events: intravascular ultrasound analysis from the multicentre, randomised, RAVEL, E-SIRIUS and SIRIUS trials. *Heart* 2008;**94**:322–328.
- Weissman NJ, Ellis SG, Grube E, Dawkins KD, Greenberg JD, Mann T, Cannon LA, Cambier PA, Fernandez S, Mintz GS, Mandinov L, Koglin J, Stone GW. Effect of the polymer-based, paclitaxel-eluting TAXUS Express stent on vascular tissue responses: a volumetric intravascular ultrasound integrated analysis from the TAXUS IV, V, and VI trials. *Eur Heart J* 2007;**28**:1574–1582.
- Cheneau E, Satler LF, Escolar E, Suddath WO, Kent KM, Weissman NJ, Waksman R, Pichard AD. Underexpansion of sirolimus-eluting stents: incidence and relationship to delivery pressure. *Catheter Cardiovasc Interv* 2005;**65**:222–226.
- Nakamura S, Colombo A, Gaglione A, Almagor Y, Goldberg SL, Maiello L, Finci L, Tobis JM. Intracoronary ultrasound observations during stent implantation. *Circulation* 1994;**89**:2026–2034.

27. Feres F, Costa JR Jr, Abizaid A. Very late thrombosis after drug-eluting stents. *Catheter Cardiovasc Interv* 2006;**68**:83–88.
28. Virmani R, Guagliumi G, Farb A, Musumeci G, Grieco N, Motta T, Mihalcsik L, Tsepili M, Valsecchi O, Kolodgie FD. Localized hypersensitivity and late coronary thrombosis secondary to a sirolimus-eluting stent: should we be cautious? *Circulation* 2004;**109**:701–705.
29. Kimura M, Mintz GS, Carlier S, Takebayashi H, Fujii K, Sano K, Yasuda T, Costa RA, Costa JR Jr, Quen J, Tanaka K, Lui J, Weisz G, Moussa I, Dangas G, Mehran R, Lansky AJ, Kreps EM, Collins M, Stone GW, Moses JW, Leon MB. Outcome after acute incomplete sirolimus-eluting stent apposition as assessed by serial intravascular ultrasound. *Am J Cardiol* 2006;**98**:436–442.
30. Qian JY, Zhang F, Fan B, Ge L, Wang QB, Ge JB. A more than 2-year follow-up of incomplete apposition after drug-eluting stent implantation. *Chin Med J (Engl)* 2008;**121**:498–502.
31. Hassan AK, Bergheanu SC, Stijnen T, van der Hoeven BL, Snoep JD, Plevier JW, Schalij MJ, Wouter Jukema J. Late stent malapposition risk is higher after drug-eluting stent compared with bare-metal stent implantation and associates with late stent thrombosis. *Eur Heart J* 2010;**31**:1172–1180.

## CARDIOVASCULAR FLASHLIGHT

doi:10.1093/eurheartj/ehs087

Online publish-ahead-of-print 27 March 2012

### Arrhythmogenic cardiomyopathy suspected by electrocardiogram: confirmed by angiography

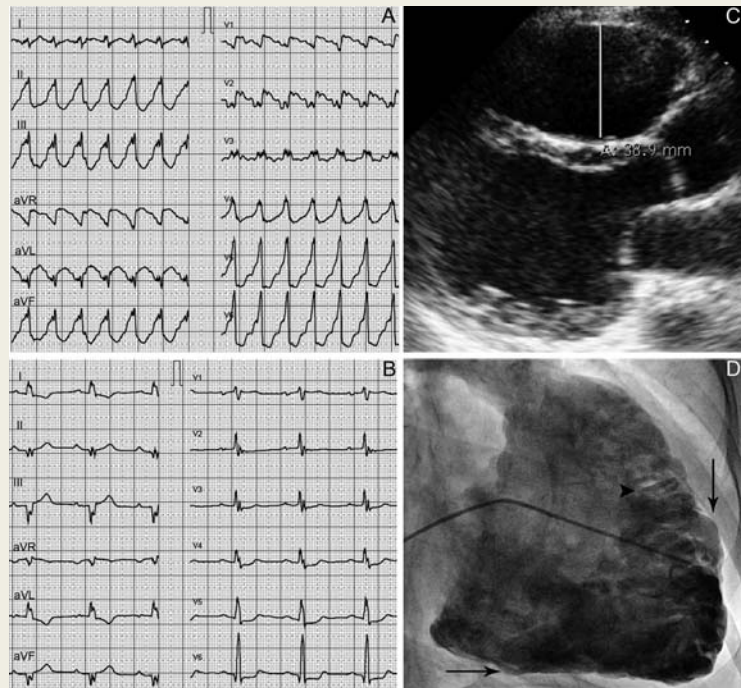
Ardan M. Saguner<sup>1</sup>, Laurent M. Haegeli<sup>1</sup>, Christian Templin<sup>1</sup>, Thomas Wolber<sup>1</sup>, Ulf Landmesser<sup>1,2</sup>, and Firat Duru<sup>1,2\*</sup>

<sup>1</sup>Clinic for Cardiology, Cardiovascular Center, University Hospital Zurich, Rämistrasse 100, CH-8091 Zurich, Switzerland; and <sup>2</sup>Center for Integrative Human Physiology, University of Zurich, Zurich, Switzerland

\*Corresponding author. Tel: +41 44 2553565, Fax: +41 44 2554401, Email: [firat.duru@usz.ch](mailto:firat.duru@usz.ch)

This paper was guest edited by Prof. Frank Rademakers, University Hospital Gasthuisberg, Leuven, Belgium

A 58-year-old woman was hospitalized for presyncope. The 12-lead surface electrocardiogram (ECG) in the emergency room showed a sustained ventricular tachycardia (VT) at a rate of 143 b.p.m. with a left bundle branch block (LBBB) morphology and inferior axis (Panel A). The ECG was remarkable for pronounced notching of the QRS complexes across multiple leads. Idiopathic right ventricular (RV) outflow tract tachycardia (RVOT-VT) was initially suspected. Intravenous metoprolol, verapamil, and amiodarone were administered without success. Electrical cardioversion (150 J biphasic) converted the arrhythmia into sinus rhythm at a rate of 57 b.p.m. with first-degree atrioventricular block and late potentials suggesting epsilon waves as well as ST-T wave changes in various leads (Panel B). Transthoracic echocardiography revealed regional wall motion abnormalities, a dilated RVOT (22.7 mm<sup>2</sup> at parasternal long axis), and a reduced RV fractional area change (18%) with extensive left ventricular (LV) involvement (ejection fraction biplane 26%) (Panel C; see Supplementary material online, *Movie S1*). Angiography showed a reduced global RV function, RV dilatation, and regional wall motion abnormalities (dyskinesia and aneurysm of the inferior RV wall and the apex) (Panel D, arrows; Supplementary material online, *Movie S2*). The pile d'assiettes sign—a pathognomonic angiographic sign for advanced RV involvement—was visible (Panel D, arrowhead). The diagnosis of arrhythmogenic RV cardiomyopathy (ARVC) was made on the basis of two major (epsilon wave and RV aneurysm) and one minor criterion (LBBB-VT with inferior axis) according to the Revised Task Force Criteria. On surface ECG, the presence of multiple QRS notches across several leads during VT with LBBB morphology and inferior axis represents a conduction delay due to fibro-fatty replacement and is highly suggestive for the presence of ARVC when compared with idiopathic RVOT-VT.



Supplementary material is available at *European Heart Journal* online.