

# Nervous system dysfunction in Henoch–Schönlein syndrome: systematic review of the literature

Luca Garzoni<sup>1</sup>, Federica Vanoni<sup>1</sup>, Mattia Rizzi<sup>1,2</sup>, Giacomo D. Simonetti<sup>2,3</sup>, Barbara Goeggel Simonetti<sup>2</sup>, Gian P. Ramelli<sup>1</sup> and Mario G. Bianchetti<sup>1</sup>

**Objective.** CNS or peripheral nervous system dysfunction sometimes occurs in Henoch–Schönlein patients.

**Methods.** We review all Henoch–Schönlein cases published after 1969 with CNS dysfunction without severe hypertension and neuroimaging studies ( $n=35$ ), cranial or peripheral neuropathy ( $n=15$ ), both CNS and peripheral nervous system dysfunction without severe hypertension ( $n=2$ ) or nervous system dysfunction with severe hypertension ( $n=2$ ). Forty-four of the 54 patients were <20 years of age.

**Results.** In patients with CNS dysfunction without or with severe hypertension the following presentations were observed in decreasing order of frequency: altered level of consciousness, convulsions, focal neurological deficits, visual abnormalities and verbal disability. Imaging studies disclosed the following lesions: vascular lesions almost always involving two or more vessels, intracerebral haemorrhage, posterior subcortical oedema, diffuse brain oedema and thrombosis of the superior sagittal sinus. Following lesions were noted in the subjects with cranial or peripheral neuropathy without severe hypertension: peroneal neuropathy, peripheral facial palsy, Guillain–Barré syndrome, brachial plexopathy, posterior tibial nerve neuropathy, femoral neuropathy, ulnar neuropathy and mononeuritis multiplex. Persisting signs of either CNS ( $n=9$ ) or peripheral ( $n=1$ ) nervous system dysfunction were sometimes reported.

**Conclusions.** In Henoch–Schönlein syndrome, signs of nervous system dysfunction are uncommon but clinically relevant. This review helps clinicians managing Henoch–Schönlein syndrome with nervous system dysfunction.

**KEY WORDS:** Vasculitis, Henoch–Schönlein syndrome, Stroke, Posterior reversible encephalopathy syndrome, Peripheral neuropathy.

## Introduction

The characteristic clinical features of Henoch–Schönlein syndrome, the most common vasculitis disorder of childhood, include palpable purpura concentrated in dependent areas, arthralgia or arthritis, abdominal pain and glomerulonephritis [1, 2].

Headache is rather common in this small vessel vasculitis [1, 2]. More rarely, Henoch–Schönlein patients present with signs of either CNS or peripheral nervous system dysfunction. Reports available until the mid-seventies that deal with nervous system involvement in Henoch–Schönlein syndrome were aggregated by French authors in two reviews [3, 4]. Since imaging is currently integral to the diagnostic assessment of vasculitides affecting the CNS [5], we performed an extensive review of the literature dealing with nervous system dysfunction in Henoch–Schönlein syndrome. We included the patients with signs of CNS dysfunction, neuroimaging studies and those with cranial or peripheral neuropathy.

## Materials and methods

Between November 2008 and April 2009, we performed a thorough computer-based search of the terms anaphylactoid purpura, Henoch, Henoch–Schönlein, Schönlein, Schönlein–Henoch, nervous system, vasculitis and angitis in the US National Library of Medicine database and in the web-based search engine Google. Articles published after 1969 as full-length articles or letters in peer-reviewed scientific literature were considered. Pertinent secondary references were also reviewed. Reports published in languages other than English, French, German, Italian or Spanish were not included.

Using the above-mentioned research technique, we were able to accumulate 37 cases of Henoch–Schönlein syndrome with signs of CNS dysfunction without severe arterial hypertension and CT or MRI of the brain [6–42], which were published between 1983 and 2009. Henoch–Schönlein patients with headache but without any abnormal neurological signs were not included.

In two of the aforementioned 37 cases [12, 41], a concurrent involvement of the peripheral nervous system was noted. In 15 further cases of Henoch–Schönlein syndrome, which were reported between 1970 and 2009, a cranial or peripheral neuropathy without severe hypertension and without any CNS dysfunction was noted [9, 43–56].

Severe arterial hypertension, which is common in Henoch–Schönlein glomerulonephritis, may cause widespread brain abnormalities or peripheral facial palsy [57, 58]. As a consequence, two Henoch–Schönlein children with blood pressure  $\geq$  (99th percentile + 5 mm Hg), signs of nervous system dysfunction and MRI were analysed separately [59, 60].

The diagnosis of Henoch–Schönlein syndrome was based on the classical palpable purpuric rash in the presence of at least one of the following [61]: diffuse abdominal pain, arthritis or arthralgia or a pathological urinalysis. A biopsy showing predominant IgA deposition was performed in 31 (57%) of the 54 patients (7, 9, 10, 12, 14–16, 19, 20, 22, 23, 25, 26, 28, 29, 31, 32, 35, 37–39, 43–47, 50, 51, 53, 61 and 62): skin biopsy ( $n=15$ ), renal biopsy ( $n=11$ ), both skin and renal biopsy ( $n=5$ ). Testing for IgG ANCA was negative in 14 patients with this examination (6, 8, 12, 19, 20, 25, 29, 32, 35, 43, 45, 51, 53, 54).

Of the 54 patients, 32 were male and 21 were female subjects (information unavailable [52] in one case), ranging in age between 3 and 68 years. Forty-four (81%) of the patients were <20 years of age (Fig. 1). They had been reported from the following continents: 24 from Europe (France,  $n=3$ ; Germany,  $n=2$ ; Italy,  $n=6$ ; Portugal,  $n=1$ ; Romania,  $n=1$ ; Spain,  $n=2$ ; Switzerland,  $n=1$ ; Turkey,  $n=6$ ; and UK,  $n=2$ ), 18 from Asia (India,  $n=2$ ; Iran  $n=1$ ; Japan,  $n=6$ ; Korea,  $n=4$ ; Saudi Arabia,  $n=1$ ; Taiwan,  $n=3$ ; and Thailand,  $n=1$ ), 10 from North America (Canada,  $n=2$  and USA,  $n=8$ ) and each 1 from Africa (Morocco) and Australia. The case of a patient with a peripheral neuropathy,

<sup>1</sup>Department of Paediatrics, Mendrisio and Bellinzona Hospitals, <sup>2</sup>Department of Paediatrics, University Children's Hospital Bern, University of Bern, Bern, Switzerland and <sup>3</sup>Center for Paediatric and Adolescent Medicine, University of Heidelberg, Heidelberg, Germany.

Submitted 1 February 2009; revised version accepted 4 August 2009.

Correspondence to: Mario G. Bianchetti, San Giovanni Hospital, 6500 Bellinzona, Switzerland. E-mail: [mario.bianchetti@pediatrician.ch](mailto:mario.bianchetti@pediatrician.ch)

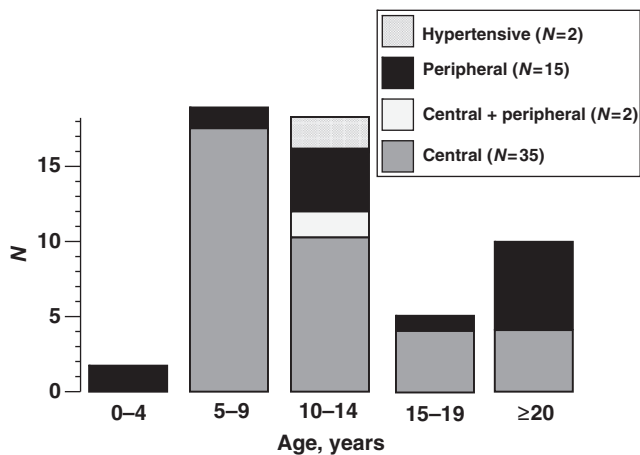


FIG. 1. Age distribution in 54 Henoch-Schönlein patients (32 male and 21 female subjects; information unavailable in one case) with nervous system dysfunction.

complicating Henoch-Schönlein syndrome reported within a case series of patients affected by vasculitic peripheral neuropathy, was not included due to scanty data available [62].

## Results

### *CNS dysfunction without severe hypertension*

In 31 (84%) of the 37 patients with CNS dysfunction without severe hypertension, the corresponding signs appeared in subjects concomitantly presenting the distinctive rash of Henoch-Schönlein syndrome. The diagnosis was more tricky in the remaining six cases (16%), considering that four patients developed the rash from 10 h until 8 days [9, 11, 21, 40] after onset of CNS symptoms. Furthermore, in two cases [27, 34], CNS dysfunction developed in subjects with past history of Henoch-Schönlein syndrome but without any cutaneous, articular or renal signs since 5, respectively, 9 years. Apart from headache, following neurological presentations were observed (Table 1): altered level of consciousness, convulsions, visual abnormalities and verbal disability. Imaging (MRI in 17 and CT alone in the remaining 19 patients) was normal in five patients (14%); three patients with MRI and two with CT). Following anomalies were disclosed in the remaining 32 (86%) patients: ischaemic vascular lesions almost always involving two or more vessels, intracerebral haemorrhages, diffuse (mainly posterior) brain oedema [21, 42] or thrombosis of the superior sagittal sinus (Table 2 and Fig. 2).

A secondary deficiency of clotting factor XIII was disclosed in three patients [24, 27, 29] and vitamin K-dependent factors in one [16] (with concurrent intestinal involvement). Testing for aPL antibodies was strongly positive in the patient with thrombosis of the superior sagittal sinus [6], and in a patient with an extensive infarction involving lenticular nucleus, caudate nucleus and periopercular region [37], but was never performed in the remaining patients with CNS dysfunction.

A large haemorrhage was drained surgically in three patients [7, 16, 34]. A 14-year-old boy with a strongly reduced activity of the clotting factor XIII and a large haemorrhage penetrating the left ventricle died in spite of emergency neurosurgery [29]. The management was conservative in the remaining patients: parenteral steroids were used in almost all patients ( $n=32$ ; 86%), sometimes ( $n=6$ ; 17%) in association with cyclophosphamide ( $n=2$ ; 6%) [25, 32], AZA ( $n=1$ ; 3%) [26], plasmapheresis ( $n=2$ ; 5%) [18, 39] or intravenous immune globulin ( $n=1$ ; 3%) [35]. Clotting factor XIII was administered in two patients with a reduced activity of this factor [24, 27]. Heparin, and, subsequently,

TABLE 1. Clinical presentation in 54 Henoch-Schönlein patients (32 male and 21 female subjects; information unavailable in one case) with neurological involvement

Characteristics	<i>n</i> (%)
<b>CNS dysfunction without severe hypertension</b>	
Altered level of consciousness	
Glasgow coma scale 10-12	10 (19)
Glasgow coma scale $\leq 9$	19 (35)
Convulsions	
Partial	4 (7)
Generalized	18 (33)
Focal neurological deficits	14 (26)
Visual abnormalities	12 (22)
Verbal disability	
Mild	2 (4)
Severe	3 (6)
<b>Nervous system dysfunction with severe hypertension</b>	
Glasgow coma scale $\leq 9$	2 (4)
Generalized convulsions	2 (4)
Visual abnormalities	1 (2)
<b>Cranial or peripheral neuropathy without severe hypertension</b>	
Peripheral facial palsy	3 (6)
Guillain-Barré syndrome	3 (6)
Brachial plexopathy	3 (6)
Peroneal neuropathy <sup>a</sup>	4 (7)
Posterior tibial nerve neuropathy	1 (2)
Femoral neuropathy	1 (2)
Ulnar neuropathy (bilateral)	1 (2)
Mononeuritis multiplex <sup>b</sup>	1 (2)

<sup>a</sup>Bilateral in one case (testing for aPL antibodies was performed in one patient and found to be normal [52]). <sup>b</sup>Median, superficial peroneal and medial plantar nerve.

TABLE 2. Cerebral lesions detected by neuroimaging in 37 Henoch-Schönlein patients with CNS dysfunction but without severe arterial hypertension

	<i>n</i> (%)
Normal neuroimaging	5 (14)
Ischaemic lesion	
One-vessel disease	1 <sup>a</sup> (3)
Two or more vessels disease	16 (43)
Intracerebral haemorrhage	11 (30)
Two or more vessels disease and haemorrhage	1 (3)
Diffuse brain oedema	2 (5)
Sagittal sinus thrombosis	1 (3)

<sup>a</sup>Middle cerebral artery [36].

warfarin were used in the patient with thrombosis of the superior sagittal sinus and positive testing for aPL antibodies [6].

Minor sequelae at follow-up, which was sometimes rather short ( $\leq 3$  months), were observed in eight patients (13, 16, 21, 24, 25, 36, 37, 41): visual field defects ( $n=3$ ), verbal disabilities ( $n=2$ ), focal neurological deficits ( $n=2$ ) and partial epilepsy ( $n=1$ ).

### *Nervous system dysfunction with severe hypertension*

In two children [59, 60] with Henoch-Schönlein glomerulonephritis and severe arterial hypertension, who presented with headache, decreased level of consciousness, visual changes and convulsions, MRI disclosed a mainly posterior subcortical oedema. In both patients, control of hypertension was followed by a full remission of the CNS dysfunction.

### *Cranial or peripheral nervous system dysfunction without severe hypertension*

Signs of peripheral nervous system dysfunction appeared in 17 subjects concomitantly presenting the distinctive rash of Henoch-Schönlein syndrome. The lesions, which appear in Table 1, included polyneuropathy, mononeuropathy or mononeuropathy multiplex. A secondary deficiency of the clotting

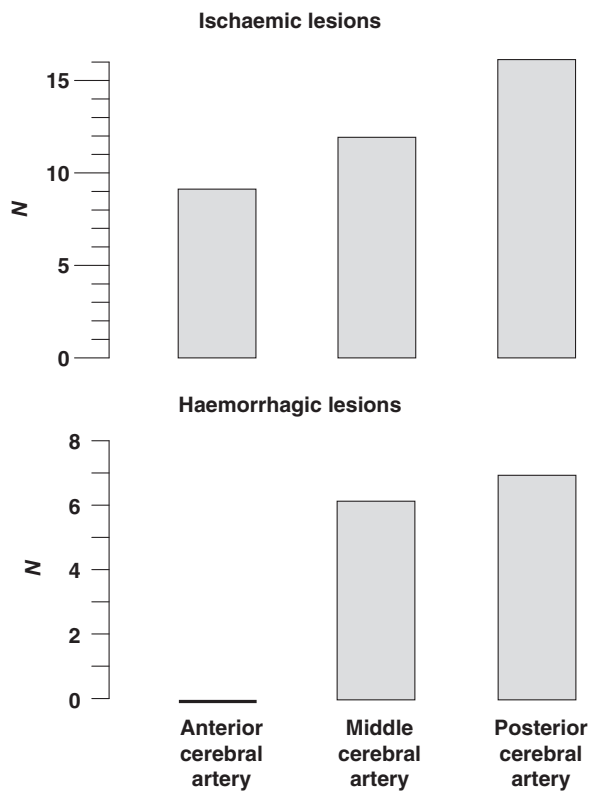


FIG. 2. Ischaemic or haemorrhagic vascular lesions detected by neuroimaging in 29 patients with Henoch-Schönlein syndrome and CNS dysfunction, but without severe arterial hypertension.

factor XIII occurred in one patient [53]. The management was expectative in all cases with the exception of intravenous immune globulin, which was prescribed in each one patient with Guillain-Barré syndrome [51] and brachial plexopathy [41]. A persisting nervous dysfunction was noted in an 11-year-old boy with brachial neuropathy [41].

#### Renal disease and uncommon features

Nephrotic-range proteinuria, a marker of rather severe kidney disease, was noted in 29 (54%) of the 54 patients with nervous system dysfunction (Table 3). Further uncommon features (Table 3), including severe gastroduodenal involvement ( $n=2$ ), gastric and colonic ulcers ( $n=1$ ), abdominal wall haematoma ( $n=1$ ), retroperitoneal haematoma ( $n=1$ ), pulmonary oedema associated with retinal artery occlusion ( $n=1$ ), pericardial tamponade ( $n=1$ ), pericardial tamponade associated with necrosis of the small intestine ( $n=1$ ) and myocarditis ( $n=1$ ), were noted in 9 (17%) of the 54 patients.

#### Discussion

Although the long-term prognosis of Henoch-Schönlein syndrome is almost entirely attributable to the kidney disease [1, 2], some rare extrarenal features may produce substantial morbidity and mortality. The present review indicates that in Henoch-Schönlein syndrome, a clinically relevant neurological disease is very rare and mostly affects subjects with either a rather severe kidney disease or uncommon features. However, in two case series [52, 63], including 39 unselected children affected by Henoch-Schönlein syndrome with normal neurological examination and blood pressure, headache was reported in 11 (28%) of them. More importantly, transient electroencephalographic

TABLE 3. Severe kidney disease and uncommon features in 32 (59%) of the 54 Henoch-Schönlein patients with nervous system dysfunction

	Nephrotic-range proteinuria	Uncommon features	Total <sup>a</sup>
CNS dysfunction	19	7	20
Peripheral nervous system dysfunction	8	2	10
CNS and peripheral nervous system dysfunction	2	0	2

<sup>a</sup>Either nephrotic-range proteinuria or uncommon features.

abnormalities including focal or generalized slow wave activity, sharp waves, focal attenuation of the voltage activity and sometimes also paroxysmal activity occurred in 21 (55%) of the 39 cases, indicating that in Henoch-Schönlein syndrome mild cerebral involvement is the rule rather than the exception. Similarly, clinically relevant pulmonary disease is exceptional in this vasculitis. Nonetheless, the lung transfer for carbon monoxide is altered in most Henoch-Schönlein children [64].

#### CNS dysfunction without severe hypertension

Like in other cerebral vasculitides, in Henoch-Schönlein patients with cerebral involvement, neuroimaging characteristically discloses ischaemic lesions secondary to vessel wall proliferation with resultant luminal obliteration (or thrombotic occlusion) or haemorrhages with or without secondary ischaemia to vessel wall proliferation with rupture of necrotic walls [65-67].

#### Nervous system dysfunction with severe hypertension

Altered level of consciousness, visual changes, convulsions and MRI studies disclosing a mainly posterior subcortical oedema, currently designated as reversible posterior leucoencephalopathy syndrome, characterize hypertensive encephalopathy [68, 69]. The present experience confirms that posterior leucoencephalopathy sometimes occurs also in normotensive (or slightly hypertensive) patients with cerebral vasculitis [68, 69].

Lower motor neuron facial palsy sometimes occurs in children with severe arterial hypertension [59, 60]. As a consequence, in Henoch-Schönlein syndrome peripheral facial palsy may result not only from a vasculitic neuropathy (see below) but also from severe hypertension. However, peripheral facial palsy has so far never been associated with severe hypertension in Henoch-Schönlein syndrome.

#### Cranial or peripheral nervous system dysfunction without severe hypertension

Vasculitides may cause inflammation in the walls of the vasa nervorum and induce critical ischaemia to nerves. However, sometimes lesions may result from compression by haematoma or localized oedema [58].

In Churg-Strauss syndrome, WG and microscopic polyangiitis, the most common vasculitides that affect the peripheral nervous system, the corresponding clinical patterns are mononeuritis multiplex, polyneuropathy, radiculopathy and neural plexopathy [55]. In Henoch-Schönlein patients with peripheral or cranial neuropathy, facial palsy, Guillain-Barré syndrome, brachial plexopathy, peroneal neuropathy, posterior tibial nerve neuropathy, femoral neuropathy and mononeuritis multiplex were observed.

#### Diagnostic work up

Generally, there is little diagnostic doubt in a subject with acute CNS or peripheral nervous system dysfunction concurrently

TABLE 4. Conditions that deserve consideration in patients with suspected neurological manifestations of Henoch-Schönlein syndrome

	CNS	Peripheral or cranial nervous system
Arterial hypertension (severe)	++	+
Vasculitides		
IgG-ANCA positive <sup>a</sup>	++	++
Primary CNS vasculitis	++	-
Behçet disease	+	-
Takayasu disease	(+) <sup>b</sup>	-
Kawasaki disease	(+)	-
Polyarteritis nodosa	++	++
SLE	++	+
SSc	+	+
juvenile idiopathic arthritis and AS	(+)	++
Sarcoidosis	++	+
Familial mediterranean fever	-	(+)
CINCA syndrome	++	(+)
Infections		
Non-opportunistic		
Syphilis	++	-
Borreliosis	++	+
Cat-scratch disease	+	-
Tuberculosis	+	(+)
Varicella zoster virus infection	+	++
Cytomegalovirus infection	++	+
HAV and HBV	+	+
Opportunistic	++	-
Adverse effects of drugs		
NSAIDs, salicylates	++	-
Steroids	++	-
Cyclophosphamide	+	-
MTX	+	-
Cyclosporin	++	+
IFN	+	+
TNF inhibitors	+	-
Thalidomide	-	+

<sup>a</sup>WG, microscopic polyangiitis and Churg-Strauss syndrome. <sup>b</sup>Ischaemic stroke.

affected with the characteristic rash of Henoch-Schönlein syndrome. It is worthy of mention, however, that in cerebral Henoch-Schönlein syndrome CNS vasculitis sometimes precedes or follows the rash. On the other side, clinicians must remember that severe arterial hypertension and vasculitides associated with IgG ANCA, primary central nervous system vasculitis, Behçet disease, Takayasu disease, Kawasaki disease, polyarteritis nodosa or cryoglobulinaemic vasculitis [59, 60, 70-77] are possible causes of both peripheral vasculitic neuropathy or CNS vasculitis, whose presentation may often mimic or overlap with Henoch-Schönlein syndrome (Table 4). SLE, SSc, AS, juvenile idiopathic arthritis, anti-phospholipid syndrome, sarcoidosis, familial Mediterranean fever, CINCA syndrome (i.e. chronic infantile, neurological, cutaneous and articular syndrome) and a number of both non-opportunistic and opportunistic infections may also mimic cerebral vasculitis [72, 78-81]. Furthermore, CNS or peripheral nervous system adverse effects have been sometimes linked with drugs used in the management of the aforementioned conditions [72].

In patients with suspected CNS or peripheral nervous system Henoch-Schönlein syndrome, history and clinical presentation are strongly variable. As a consequence, a strictly standardized diagnostic work up is not advised. Nonetheless, considering that 'non-Henoch-Schönlein vasculitides' affect the nervous system more frequently than Henoch-Schönlein syndrome, we urge testing for aPL, ANA and IgG ANCA in all cases. Furthermore, considering the possible confusion with other vasculitides and the role of IgA tissue deposits in Henoch-Schönlein syndrome, the detection of IgA in tissue-like skin or kidney appears imperative in most cases. Neuroimaging is crucial to the diagnostic assessment of suspected cerebral vasculitides: although catheter angiography remains the gold standard, in clinical practice MRI is usually the study of choice [5, 66].

## Management

Controlled trials with significant and homogeneous case numbers are not feasible with very rare and heterogeneous diseases such as nervous system dysfunction in Henoch-Schönlein syndrome [82]. With these limitations in mind, the data of the present review prompt us to suggest the following management.

**CNS.** Like in adults with stroke, the initial management of patients with suspected cerebral Henoch-Schönlein syndrome includes control of arterial hypertension, seizures and repair of disordered hemostasis [83, 84]. In patients with intracerebral haemorrhage, the indications for surgery are controversial and vary with the site and the size of the bleed. Like in severe Henoch-Schönlein glomerulonephritis [85, 86], combined therapy with corticoids and cyclophosphamide is appropriate in a patient with relevant ischaemic cerebral lesions and Henoch-Schönlein syndrome. Anti-coagulation is advised in patients with secondary anti-phospholipid syndrome [79].

**Peripheral or cranial nervous system.** Corticoids and cyclophosphamide are not advised for Henoch-Schönlein patients with a peripheral or a cranial neuropathy, considering that these conditions mostly tend to full spontaneous recovery. In Henoch-Schönlein purpura complicated by Guillain-Barré syndrome, management with intravenous immune globulin (or plasma exchange) is, like in the classical form of this polyneuropathy, recommended [87].

In conclusion, the present systematic review helps clinicians in the management of Henoch-Schönlein patients with signs of nervous system dysfunction.

## Rheumatology key messages

- In Henoch-Schönlein syndrome, relevant neurological disease is rare but produces substantial morbidity and mortality.
- CNS dysfunction results from a vascular obstruction, from an intracerebral haemorrhage or from severe hypertension.
- Peripheral nervous system dysfunction presents as polyneuropathy, mononeuropathy or mononeuropathy multiplex.

## Acknowledgement

G.D.S. is currently recipient of a Swiss Society of Hypertension AstraZeneca Scholarship.

**Disclosure statement:** The authors have declared no conflicts of interest.

## References

- 1 Bucher B, Fiore E, Bernasconi M *et al.* Childhood Henoch-Schönlein syndrome—common and uncommon features, complications, Finkelstein-Seidlmayer variant and management. *Ther Umsch* 2008;65:269-77.
- 2 Dillon MJ. Henoch-Schönlein purpura: recent advances. *Clin Exp Rheumatol* 2007; 25:S66-8.
- 3 de Montis G, Turpin JC. Rheumatoid purpura and neurologic manifestations. *Ann Méd Interne* 1971;122:841-8.
- 4 de Montis G, Desmarchelier T, Bacri JL, Carnot JF, Rossier A. Complications rares du purpura rhumatoïde. Discussion pathogénique. *Ann Pédiatr* 1977;24:17-22.
- 5 Amezcua-Guerra LM, Pineda C. Imaging studies in the diagnosis and management of vasculitis. *Curr Rheumatol Rep* 2007;9:320-7.
- 6 Abend NS, Licht DJ, Spencer CH. Lupus anticoagulant and thrombosis following Henoch-Schönlein purpura. *Pediatr Neurol* 2007;36:345-7.
- 7 Altinörs N, Cepoglu C. Surgically treated intracerebral hematoma in a child with Henoch-Schönlein purpura. *J Neurosci Sci* 1991;35:47-9.
- 8 Bakkaloglu SA, Ekim M, Tümer N, Deda G, Erden I, Erdem T. Cerebral vasculitis in Henoch-Schönlein purpura. *Nephrol Dial Transplant* 2000;15:246-8.
- 9 Belman AL, Leicher CR, Moshé SL, Mezey AP. Neurologic manifestations of Schönlein-Henoch purpura: report of three cases and review of the literature. *Pediatrics* 1985;75:687-92.

- 10 Benhamou B, Balafrej A, Jaritz E, Mikou N, Baroudi A. Cerebral ischemia and severe digestive manifestations during rheumatoid purpura. *Ann Pédiatr* 1991;38:484–6.
- 11 Bonora G, Malorgio C. Una porpora di Schönlein-Henoch plurisintomatica. *Medico e Bambino* 2002, [http://www.medicoebambino.com/?id=CL0204\\_10.html](http://www.medicoebambino.com/?id=CL0204_10.html) (April 2002, date last accessed).
- 12 Bulun A, Topaloglu R, Duzova A, Saatci I, Besbas N, Bakkaloğlu A. Ataxia and peripheral neuropathy: rare manifestations in Henoch-Schönlein purpura. *Pediatr Nephrol* 2001;16:1139–41.
- 13 Brunod R, Arthuis M. Neurologic manifestations in rheumatoid purpura. *Arch Fr Pédiatr* 1983;40:33–4.
- 14 Chen CL, Chiou YH, Wu CY, Lai PH, Chung HM. Cerebral vasculitis in Henoch-Schönlein purpura: a case report with sequential magnetic resonance imaging changes and treated with plasmapheresis alone. *Pediatr Nephrol* 2000;15:276–8.
- 15 Chiaretti A, Caresta E, Piastra M, Pulitanò S, Di Rocco C. Cerebral hemorrhage in Henoch-Schönlein syndrome. *Childs Nerv Syst* 2002;18:365–7.
- 16 Clark JH, Fitzgerald JF. Hemorrhagic complications of Henoch-Schönlein syndrome. *J Pediatr Gastroenterol Nutr* 1985;4:311–5.
- 17 Elinson P, Foster KW Jr, Kaufman DB. Magnetic resonance imaging of central nervous system vasculitis. A case report of Henoch-Schönlein purpura. *Acta Paediatr Scand* 1990;79:710–3.
- 18 Eun SH, Kim SJ, Cho DS, Chung GH, Lee DY, Hwang PH. Cerebral vasculitis in Henoch-Schönlein purpura: MRI and MRA findings, treated with plasmapheresis alone. *Pediatr Int* 2003;45:484–7.
- 19 Fanos V. Cerebral vasculitis and nephritis in a child: complicated Henoch-Schönlein purpura or a rare case of Wegener's granulomatosis? *J Paediatr Child Health* 2009;45:163–5.
- 20 Fielding RE, Hawkins CP, Hand MF, Heath PD, Davies SJ. Seizures complicating adult Henoch-Schönlein purpura. *Nephrol Dial Transplant* 1998;13:761–2.
- 21 Fösel S, Artmann H. Severe encephalopathy in Schönlein-Henoch purpura (case-report). *Klin Pädiatr* 1990;202:109–11.
- 22 Gonçalves C, Ferreira G, Mota C, Vilarinho A. Cerebral vasculitis in Henoch-Schönlein purpura. *Ann Pediatr (Barc)* 2004;60:188–9.
- 23 Ha TS, Cha SH. Cerebral vasculitis in Henoch-Schönlein purpura: a case report with sequential magnetic resonance imaging. *Pediatr Nephrol* 1996;10:634–6.
- 24 Imai T, Okada H, Nanba M, Kawada K, Kusaka T, Itoh S. Henoch-Schönlein purpura with intracerebral hemorrhage. *Brain Dev* 2002;24:115–17.
- 25 Karamadokis L, Ludeman L, Williams AJ. Henoch-Schönlein purpura with intracerebral haemorrhage in an adult patient: a case report. *J Med Case Rep* 2008;2:200.
- 26 Mattoo TK, al-Mutair A, al-Khatib Y, Ali A, al-Sohaibani MO. Group A beta-haemolytic streptococcal infection and Henoch-Schönlein purpura with cardiac, renal and neurological complications. *Ann Trop Paediatr* 1997;17:381–6.
- 27 Migita M, Hayakawa J, Shima H *et al.* A case of Henoch-Schönlein purpura with rare complications: necrosis of the small intestine, neurological symptoms, and pericardial tamponade. *J Nippon Med Sch* 2005;72:383–6.
- 28 Misra AK, Biswas A, Das SK, Gharai PK, Roy T. Henoch-Schönlein purpura with intracerebral haemorrhage. *J Assoc Phys India* 2004;52:833–4.
- 29 Murakami H, Takahashi S, Kawakubo Y, Kinukawa N, Funaki S, Harada K. Adolescent with Henoch-Schönlein purpura glomerulonephritis and intracranial hemorrhage possibly secondary to the reactivation of latent CMV. *Pediatr Int* 2008;50:112–15.
- 30 Ng CC, Huang SC, Huang LT. Henoch-Schönlein purpura with intracerebral hemorrhage: case report. *Pediatr Radiol* 1996;26:276–7.
- 31 Ortega M, Trejo O, Perea M, Aguirreola N. Neurologic manifestations of Schoenlein-Henoch purpura. *Med Clin* 2000;114:356.
- 32 Özkaya O, Bek K, Alaca N, Ceyhan M, Açıkçöz Y, Taşdemir HA. Cerebral vasculitis in a child with Henoch-Schönlein purpura and familial Mediterranean fever. *Clin Rheumatol* 2007;26:1729–32.
- 33 Palesse N, Marrelli A, Legge MP, Gallucci M. Neurological complications of Schönlein-Henoch syndrome: contribution of MR to the diagnosis. Case report. *Ital J Neurol Sci* 1989;10:351–5.
- 34 Paolini S, Ciappetta P, Piattella MC, Domenicucci M. Henoch-Schönlein syndrome and cerebellar hemorrhage: report of an adolescent case and literature review. *Surg Neurol* 2003;60:339–42.
- 35 Perez C, Maravi E, Olier J, Guarch R. MR imaging of encephalopathy in adult Henoch-Schönlein purpura. *AJR Am J Roentgenol* 2000;175:922–3.
- 36 Scattarella V, Pannarale P, D'Angelo V, Contratti F, Penza R. Occipital hemorrhage in a child with Schönlein-Henoch syndrome. *J Neurosurg Sci* 1983;27:37–9.
- 37 Sokol DK, McIntyre JA, Short RA *et al.* Henoch-Schönlein purpura and stroke: antiphosphatidylethanolamine antibody in CSF and serum. *Neurology* 2000;55:1379–81.
- 38 Temkiatvises K, Nilanont Y, Pongvarin N. Stroke in Henoch-Schönlein purpura associated with methicillin-resistant *Staphylococcus aureus* septicemia: report of a case and review of the literature. *J Med Assoc Thai* 2008;91:1296–301.
- 39 Wen YK, Yang Y, Chang CC. Cerebral vasculitis and intracerebral hemorrhage in Henoch-Schönlein purpura treated with plasmapheresis. *Pediatr Nephrol* 2005;20:223–5.
- 40 Woolfenden AR, Hukin J, Poskitt KJ, Connolly MB. Encephalopathy complicating Henoch-Schönlein purpura: reversible MRI changes. *Pediatr Neurol* 1998;19:74–7.
- 41 Yilmaz C, Caksen H, Arslan S, Anlar O, Ataş B, Güven AS, Odaş D. Bilateral brachial plexopathy complicating Henoch-Schönlein purpura. *Brain Dev* 2006;28:326–8.
- 42 Salloum AC, Cuisset JM, Vermelle M, Loeuille GA, Mukuna D, Blanckaert D. Posterior reversible encephalopathy as a complication of rheumatoid purpura: a case study. *Arch Pédiatr* 2009;16:284–6.
- 43 Amini M, Najafi I, Ganji MR, Hakemi MS, Nouri M. Foot-drop: an unusual complaint in Henoch-Schönlein purpura. *Pediatr Nephrol* 2009;24:219–20.
- 44 Ansell BM. Henoch-Schönlein purpura with particular reference to the prognosis of the renal lesion. *Br J Dermatol* 1970;82:211–5.
- 45 Campbell SB, Hawley CM, Staples C. Mononeuritis multiplex complicating Henoch-Schönlein purpura. *Aust N Z J Med* 1994;24:580.
- 46 Choi SJ, Park SK, Uhm WS *et al.* A case of refractory Henoch-Schönlein purpura treated with thalidomide. *Korean J Intern Med* 2002;17:270–3.
- 47 Goraya JS, Jayashree M, Ghosh D, Singh S, Singhi SC, Kumar L. Guillain-Barré syndrome in a child with Henoch-Schönlein Purpura. *Scand J Rheumatol* 1998;27:310–2.
- 48 Kaplan JM, Quintana P, Samson J. Facial nerve palsy with anaphylactoid purpura. *Am J Dis Child* 1970;119:452–3.
- 49 Kómár J, Cziffer A, Szegvári M. Iliac tunnel syndrome as a complication of Schönlein-Henoch purpura. *Nervenarzt* 1979;50:405–7.
- 50 Moreau BA, Schuller E, Georges B. Association of Guillain-Barré syndrome and Henoch-Schönlein purpura: is immunoglobulin A responsible for the neurologic syndrome? *Am J Med Sci* 1988;296:198–201.
- 51 Mutsukura K, Tsuboi Y, Fujiki F, Fujioka S, Inoue H, Yamada T. Acute motor sensory axonal neuropathy associated with Henoch-Schönlein purpura. *J Neurol Sci* 2007;263:169–73.
- 52 Niederhoff H, Pernice W, Sedlacek HH, Schindera F, Schütte B, Strassburg HM. Henoch-Schönlein purpura. *Dtsch Med Wochenschr* 1979;104:1567–71.
- 53 Ohnuma K, Hosono O, Kawasaki H *et al.* An adult case of Henoch-Schönlein purpura complicating common peroneal nerve mononeuropathy. *Mod Rheumatol* 2009;19:73–9.
- 54 Ramelli GP, Bianchetti MG. Dapsone in cutaneous Henoch-Schönlein syndrome - worth a trial. *Acta Paediatr* 1997;86:337.
- 55 Ritter FJ, Seay AR, Lahey ME. Peripheral mononeuropathy complicating anaphylactoid purpura. *J Pediatr* 1983;103:77–8.
- 56 Shin JI, Lee JS, Kim HD, Lee JS, Lee YM. Neurologic manifestations and treatment of Henoch-Schönlein purpura. *Brain Dev* 2006;28:547.
- 57 Lloyd AV, Jewitt DE, Still JD. Facial paralysis in children with hypertension. *Arch Dis Child* 1966;41:292–4.
- 58 Siegler RL, Brewer ED, Corneli HM, Thompson JA. Hypertension first seen as facial paralysis: case reports and review of the literature. *Pediatrics* 1991;87:387–9.
- 59 Özçakar ZB, Ekim M, Fitoz S *et al.* Hypertension induced reversible posterior leukoencephalopathy syndrome: a report of two cases. *Eur J Pediatr* 2004;163:728–30.
- 60 Sasayama D, Shimojima Y, Gono T, Kaneko K, Matsuda M, Ikeda S. Henoch-Schönlein purpura nephritis complicated by reversible posterior leukoencephalopathy syndrome. *Clin Rheumatol* 2007;26:1761–3.
- 61 Ozen S, Ruperto N, Dillon MJ *et al.* EULAR/PReS endorsed consensus criteria for the classification of childhood vasculitides. *Ann Rheum Dis* 2006;65:936–41.
- 62 Mathew L, Talbot K, Love S, Puvanarajah S, Donaghy M. Treatment of vasculitic peripheral neuropathy: a retrospective analysis of outcome. *Q J Med* 2007;100:41–51.
- 63 Ostergaard JR, Storm K. Neurologic manifestations of Schönlein-Henoch purpura. *Acta Paediatr Scand* 1991;80:339–42.
- 64 Chaussain M, de Boissieu D, Kalifa G *et al.* Impairment of lung diffusion capacity in Schönlein-Henoch purpura. *J Pediatr* 1992;121:12–16.
- 65 Benseler SM. Central nervous system vasculitis in children. *Curr Rheumatol Rep* 2006;8:442–9.
- 66 Calabrese LH. Diagnostic strategies in vasculitis affecting the central nervous system. *Cleve Clin J Med* 2002;69:S1105–8.
- 67 West SG. Central nervous system vasculitis. *Curr Rheumatol Rep* 2003;5:116–27.
- 68 Bartynski WS. Posterior reversible encephalopathy syndrome, part 1: fundamental imaging and clinical features. *AJNR Am J Neuroradiol* 2008;29:1036–42.
- 69 Bartynski WS. Posterior reversible encephalopathy syndrome, part 2: controversies surrounding pathophysiology of vasogenic edema. *AJNR Am J Neuroradiol* 2008;29:1043–9.
- 70 Calamia KT, Kaklamanis PG. Behçet's disease: recent advances in early diagnosis and effective treatment. *Curr Rheumatol Rep* 2008;10:349–55.
- 71 Colmegna I, Maldonado-Cocco JA. Polyarteritis nodosa revisited. *Curr Rheumatol Rep* 2005;7:288–96.
- 72 Duzova A, Bakkaloğlu A. Central nervous system involvement in pediatric rheumatic diseases: current concepts in treatment. *Curr Pharm Des* 2008;14:1295–301.
- 73 Ferri C, Mascia MT. Cryoglobulinemic vasculitis. *Curr Opin Rheumatol* 2006;18:54–63.
- 74 Moser M, Izzo JL Jr, Bisognano J. Hypertensive emergencies. *J Clin Hypertens* 2006;8:275–81.
- 75 Pagnoux C, Guilpain P, Guillevin L. Churg-Strauss syndrome. *Curr Opin Rheumatol* 2007;19:25–32.
- 76 Tabarki B, Mahdhaoui A, Selmi H, Yacoub M, Essoussi AS. Kawasaki disease with predominant central nervous system involvement. *Pediatr Neurol* 2001;25:239–41.
- 77 Woywodt A, Haubitz M, Haller H, Matteson EL. Wegener's granulomatosis. *Lancet* 2006;367:1362–6.
- 78 D'Cruz DP. Systemic lupus erythematosus. *Br Med J* 2006;332:890–4.
- 79 Gezer S. Antiphospholipid syndrome. *Dis Mon* 2003;49:696–741.
- 80 Iannuzzi MC, Rybicki BA, Teirstein AS. Sarcoidosis. *N Engl J Med* 2007;357:2153–65.
- 81 Yao Q, Furst DE. Autoinflammatory diseases: an update of clinical and genetic aspects. *Rheumatology* 2008;47:946–51.

- 82 Behera M, Kumar A, Soares HP, Sokol L, Djulbegovic B. Evidence-based medicine for rare diseases: implications for data interpretation and clinical trial design. *Cancer Control* 2007;14:160–6.
- 83 Michel P. General principles of acute stroke management. *Handb Clin Neurol* 2008; 94:1129–54.
- 84 Broderick J, Connolly S, Feldmann E *et al.* Guidelines for the management of spontaneous intracerebral hemorrhage in adults: 2007 update: a guideline from the American Heart Association/American Stroke Association Stroke Council, High Blood Pressure Research Council, and the Quality of Care and Outcomes in Research Interdisciplinary Working Group. *Stroke* 2007;38:2001–23.
- 85 Jindal KK. Management of idiopathic crescentic and diffuse proliferative glomerulonephritis: evidence-based recommendations. *Kidney Int Suppl* 1999;70:S33–40.
- 86 Niaudet P, Habib R. Methylprednisolone pulse therapy in the treatment of severe forms of Schönlein-Henoch purpura nephritis. *Pediatr Nephrol* 1998;12:238–43.
- 87 Kuwabara S. Guillain-Barré syndrome: epidemiology, pathophysiology and management. *Drugs* 2004;64:597–610.