

clinical practice guidelines

Annals of Oncology 26 (Supplement 5): v40–v55, 2015
doi:10.1093/annonc/mdv277

Thymic epithelial tumours: ESMO Clinical Practice Guidelines for diagnosis, treatment and follow-up[†]

N. Girard¹, E. Ruffini², A. Marx³, C. Faivre-Finn⁴ & S. Peters⁵, on behalf of the ESMO Guidelines Committee*

¹Department of Respiratory Medicine, Expert Centre for Thymic Malignancies, Reference Centre for Orphan Pulmonary Diseases, Hôpital Louis Pradel, Hospices Civils de Lyon, Lyon, France; ²Department of Thoracic Surgery, University of Torino, Turin, Italy; ³Institute of Pathology, University Medical Centre Mannheim, University of Heidelberg, Mannheim, Germany; ⁴Institute of Cancer Sciences, The University of Manchester, Manchester Academic Health Science Centre, The Christie NHS Foundation Trust, Manchester, UK; ⁵Department of Medical Oncology, Centre Hospitalier Universitaire Vaudois (CHUV), Lausanne, Switzerland

incidence and epidemiology

Thymic epithelial tumours represent a heterogeneous group of rare thoracic cancers, with reported annual incidence ranging from 1.3 to 3.2 per million [1]. Thymic epithelial tumours are classified according to the World Health Organization (WHO) histopathological classification, which distinguishes thymomas from thymic carcinomas.

thymomas

Thymomas are further subdivided into different types (called A, AB, B1, B2, B3 and rare others) based upon the morphology of epithelial tumour cells, the relative proportion of the non-tumoural lymphocytic component (decreasing from type B1 to B3) and resemblance to normal thymic architecture (Table 1) [2, 3]. The term 'benign thymoma' should be avoided. Thymomas are far more frequent than thymic carcinomas, which have an incidence of 0.2 to 0.5 per million [3].

thymic carcinomas

Thymic carcinomas are similar to their extrathymic counterpart, the most frequent subtype being squamous cell carcinoma. Neuroendocrine tumours may occur in the thymus, and will not be discussed in these guidelines; while localised primary thymic neuroendocrine tumours may benefit from surgical resection, similar to other thymic carcinomas, the prognosis is poor given frequent recurrences; for recurrent, advanced and metastatic tumours, the management actually follows that of extra-thoracic neuroendocrine tumours.

epidemiology

Mean age at diagnosis is 50–60 years of age, but thymic tumours may actually be diagnosed in children as well as in elderly patients. There is no consistent gender predilection in thymomas

overall, even if a slight female preponderance has been reported for type A, AB and B1 subtypes in most studies, and a male predominance in carcinomas [2–7].

No environmental or infectious factors have been demonstrated to play a role in the pathogenesis of thymic epithelial tumours. Reports on development of thymoma after radiation, solid-organ transplantation and immunosuppression, including the context of human immunodeficiency virus infection, are rare; differential diagnosis with thymic rebound hyperplasia may be discussed in this setting (see below).

Genetic risk factors, such as multiple endocrine neoplasia 1 (MEN1), may influence the development of thymomas, as well as thymic carcinoids, given their reported familial occurrence as well as their association with cancer susceptibility syndromes [8].

Moreover, extrathymic haematopoietic cancers (mostly diffuse large B-cell lymphoma and leukaemia) and a broad spectrum of solid cancers (stomach, pancreas, colon and thyroid) have been reported to occur more frequently in thymoma patients, particularly subsequently [9]. This might be related to a shared unknown oncogenic trigger, a thymoma-associated immune deficiency or (less likely) to adverse effects of treatments.

diagnosis

imaging and laboratory tests

Standard imaging for thymic tumours is i.v. contrast-enhanced computed tomography (CT) scan of the thorax, allowing a complete exploration of the mediastinum and the pleura from the apex to the costodiaphragmatic recesses [IV, A]. CT is equal or superior to magnetic resonance imaging (MRI) for the diagnosis of mediastinal anterior masses, except in the setting of cystic lesions [IV, B] [10].

One-third of patients with thymoma present with autoimmune disorders (Table 2), mainly myasthenia gravis which is particularly common in type AB, B1 and B2 thymomas and almost always associated with anti-acetylcholine receptor antibodies (Table 1) [11]. Other frequent disorders include pure red cell aplasia (5% of cases) and hypogammaglobulinaemia (Good syndrome: 5% of cases) [12].

*Correspondence to: ESMO Guidelines Committee, ESMO Head Office, Via L. Taddei 4, CH-6962 Viganello-Lugano, Switzerland.
E-mail: clinicalguidelines@esmo.org

[†]Approved by the ESMO Guidelines Committee: July 2015.

Table 1. Histological subtypes of thymic epithelial tumours: relative frequency, frequency of myasthenia gravis and correlation with stage

	Relative frequency	Myasthenia gravis	Masaoka stage				
			I	II	III	IVA	IVB
Type A	12% (3%–26%)	15% (0%–35%)	60%	31%	8%	<1%	<1%
Type AB	28% (15%–43%)	20% (5%–42%)	67%	26%	6%	1%	1%
Type B1	18% (6%–53%)	40% (5%–69%)	50%	37%	9%	3%	1%
Type B2	26% (8%–41%)	50% (23%–73%)	32%	29%	28%	8%	3%
Type B3	16% (3%–35%)	50% (25%–65%)	19%	36%	27%	15%	3%
Carcinoma	18% (1%–28%)	<5%	10%	10%	45%	15%	20%

Data are based on references [5–8].

In addition to recording a complete history and conducting a full clinical examination (looking especially at neurological signs), systematic immunological check-up is recommended when a diagnosis of thymic epithelial tumour is suspected, including complete blood cells count with reticulocytes and serum protein electrophoresis, as well as anti-acetylcholine receptor and anti-nuclear antibodies tests [V, A]. Indeed, frequent immune disorders associated with thymoma may impact the course of all therapeutic interventions including surgery, radiotherapy as well as chemotherapy.

diagnosis approach

The diagnosis of any thymic epithelial tumour relies on making the differential diagnosis with other anterior mediastinal tumours and non-malignant thymic lesions [13]. CT is the imaging modality of choice. The need for pretreatment biopsy depends on the resectability of the tumour [14–16].

Thymic epithelial tumours are the most frequent cause of anterior mediastinal mass, accounting for 35% of cases; the most relevant differential diagnoses include lymphomas (Hodgkin's or non-Hodgkin's) in ~25% of cases and germ-cell tumours (teratoma or seminoma/non-seminomatous tumours) in ~20% of cases [13]. Thymic carcinoma must be differentiated from lung carcinoma, as well as from rarer entities, such as *NUT* carcinomas [17].

Clinical judgement based on a complete history and physical, especially neurological, examination, correlated with laboratory tests and radiological features, helps to develop a presumptive diagnosis. Thymoma is the most likely diagnosis when facing a mediastinal mass associated with one of the above autoimmune diseases, while thymic carcinoma patients typically have unspecific local symptoms [IV, A]. Lymphoma may be considered in case of rapid onset of B-signs, coexistent lymphadenopathy or elevated lactate dehydrogenase. Teratoma usually shows a heterogeneous morphology on imaging, with fat and cystic pattern [18]. Seminomas and non-seminomatous germ-cell tumours may be large and have a fulminant onset. Elevated serum β -human chorionic gonadotropin may be observed in seminomas, along with elevated alphafetoprotein in non-seminomatous germ-cells tumours.

Differentiating thymic malignancy from hyperplasia or non-involved thymus may be challenging. Thymic rebound hyperplasia should be considered after stress, injuries, chemotherapy, radiotherapy, anti-hormonal treatment or

Table 2. Autoimmune disorders associated with thymoma [11, 12]

Neuromuscular	Myasthenia gravis Myotonic dystrophy Limbic encephalitis Peripheral neuropathy Autonomic neuropathy Acquired neuromyotonia Morvan syndrome (neuromyotonia and encephalitis) Stiff person syndrome Cerebellar degeneration Polymyositis (carcinomas)
Haematological disorders	Red cell aplasia Pernicious anaemia Erythrocytosis Pancytopenia Haemolytic anaemia Leukaemia Multiple myeloma
Collagen and autoimmune disorders	Systemic lupus erythematosus Rheumatoid arthritis Sjogren's syndrome Scleroderma Interstitial pneumonitis
Immune deficiency disorders	Hypogammaglobulinaemia (Good syndrome) T-cell deficiency syndrome
Endocrine disorders	Multiple endocrine neoplasia Cushing's syndrome Thyroiditis
Dermatological disorders	Pemphigus Lichen planus Chronic mucosal candidiasis Alopecia areata
Miscellaneous	Giant cell myocarditis Nephrotic syndrome Ulcerative colitis Hypertrophic osteoarthropathy

corticosteroids. Thymic lymphoid hyperplasia is most commonly observed in myasthenia gravis, but also in the setting of hyperthyroidism, connective tissue or vascular disease. CT

features include low-attenuation, symmetric and fatty pattern maintaining the bi-pyramidal shape of the thymus [18]. In equivocal cases at CT, chemical-shift MRI may detect microscopic fatty infiltration by showing homogeneous signal decrease on opposed phase images relative to in-phase images, which is not observed in thymoma [IV, B] [19]. Therapeutic intervention is usually not required if the lesion is <30 mm, given a low risk of progression or thymic malignancy [III, D] [20].

18-Fluorodeoxyglucose positron emission tomography (PET) scan is generally not recommended to assess thymic masses [IV, C]. Standard uptake values may be higher in type B3 thymomas and thymic carcinomas; however, thymic hyperplasia may also present with hypermetabolism [21]. PET scan is optional in the case of tumours with aggressive histology and an advanced stage to complete the staging work-up or further characterise lesions suspicious for recurrences.

need for biopsy

Pretreatment biopsy is not required if the diagnosis of thymic tumour is highly probable and upfront surgical resection is achievable (see below, definition of resectability) [IV, E]. Biopsy is required in all other clinical situations [IV, A]: approaches may consist of percutaneous core-needle biopsy or incisional surgical biopsy through mediastinotomy or mini-thoracotomy, with sensitivity rates ranging from 40% to 93% [22]. Biopsies that are deep and multiple are preferred. Pleural spaces should be respected to avoid tumour cell seeding. Fine-needle aspiration is generally not recommended [IV, D].

thymomas. Although designed for surgical resection specimens, the WHO classification may be used for small biopsies [V, A]. However, thymoma subtyping on small biopsies is usually not needed for the therapeutically relevant distinction between lymphoma and solid tumour. In any case, diagnostic discrepancies between core-needle and resection specimen histology can be anticipated, given the frequent occurrence of histological tumour heterogeneity that may be missed due to sampling error [23]. The recent proposal of major and minor morphological and immunohistochemical criteria to better individualise each thymic epithelial tumour entity aims at addressing those issues, and has been integrated in the revised WHO classification [3, 24]. Immunohistochemical markers may be helpful, including cytokeratins and p63 expression for normal and neoplastic epithelial cells, and terminal deoxynucleotidyl transferase expression in immature T cells (usually observed in types AB, B1, B2 and B3 thymomas, and absent in carcinomas and type A thymomas) [3].

thymic carcinomas. Immunohistochemistry with anti-CD117/KIT and anti-CD5 antibodies helps to establish the thymic origin in ~80% of mediastinal carcinomas [V, A]. Since these markers are not absolutely specific, correlation with the clinical setting is always recommended, and is mandatory in the subset of 20% of thymic carcinomas without expression of CD117/KIT and CD5 [3].

In thymic tumours showing more than one histological pattern, each component should be listed (starting with the predominant one) and be quantified in 10% increments; a thymic

carcinoma component should always be mentioned first [V, C]. In case of difficult diagnosis, it is recommended to consult a second pathologist or refer the case to a thymic tumour pathology panel.

staging and risk assessment

staging

Thymic epithelial tumours are routinely staged according to the Masaoka-Koga staging system (Table 3) [III, A] [25–27], which is correlated with overall survival (OS) [4, 28, 29]. Masaoka-Koga staging is a surgical pathology system that is assessable only after surgical resection of the tumour. A typical feature of thymic epithelial tumours is the correlation between the WHO classification and stage at diagnosis (Table 1), which may explain its reported prognostic value [4–6] (Figures 1–3).

The International Association for the Study of Lung Cancer (IASLC) Staging Prognostic Factors Committee, together with the International Thymic Malignancy Interest Group (ITMIG), recently proposed a Tumour–Node–Metastasis (TNM)-based staging system for thymic malignancies, based on OS analyses of a retrospective international database of more than 10 000 cases (Table 4) [30]. The TNM-based approach has the advantage of being more appropriate both for thymoma and thymic carcinomas, which present with a higher propensity toward nodal and distant metastatic invasion. The IASLC/ITMIG TNM system of thymic tumours will be incorporated as the official thymic tumour staging system into the 8th edition of the TNM staging system of thoracic malignancies expected in 2016–2017. From our standpoint, the Masaoka-Koga staging should remain the standard for the routine management of patients, pending the approval of the American Joint Committee on Cancer (AJCC) and Union for International Cancer Control (UICC) [III, A]. Moreover, given the major switch that the TNM system represents and the limited amount of fair level of evidence data to support our current treatment strategies (especially postoperative radiotherapy), the value of the TNM system to drive the therapeutic strategy has to be assessed. Correlative clinical data based on this system may be encouraged in a research setting.

The assessment of resectability is mostly based on the surgeon's expertise; it is recommended to discuss indications for surgery in a multidisciplinary tumour board setting [V, B]. There is no recognised clinical staging system, and the treatment strategy for thymic epithelial tumours is primarily based on whether the tumour may be resected upfront or not [IV, A], as complete resection has been identified as the most consistent and significant prognostic factor of disease-free survival and OS [5, 6, 29]. Correlation between clinical and surgical pathology stage is higher in advanced stages, given the identification of vessel invasion, enlarged lymph nodes, pleural/pericardial lesions or even systemic metastases [28]. Preoperative CT findings reported to be associated with tumour invasiveness and/or completeness of resection include: tumour size (>5/7/8 cm, depending on studies), lobulated or irregular contours, calcifications, infiltration of surrounding fat, lung infiltration, great vessel invasion or encirclement [31–33]. The new TNM staging may even provide more help in formalising resectability: T1–3 level of invasion refers to structures amenable to surgical resection, while T4 level of invasion includes unresectable structures (Table 4).

Table 3. Staging of thymic epithelial tumours: Masaoka-Koga-based staging system [25, 26], International Thymic Malignancy Interest Group refinements [27] and overall survival and recurrence-free survival (range)^a [28]

	Masaoka-Koga, 1994	International Thymic Malignancy Interest Group, 2011	10-year overall survival	10-year cumulative incidence of recurrence	
				Thymoma	Thymic carcinoma
Stage I	Grossly and microscopically completely encapsulated tumour	<ul style="list-style-type: none"> - Invasion into but not through the capsule - In the absence of capsule, absence of invasion into surrounding tissues 	84% (81%–86%)		
Stage IIA	Microscopic transcapsular invasion	<ul style="list-style-type: none"> - Microscopic transcapsular invasion (<3 mm) 	83% (79%–87%)	8% (7%–8%)	25% (22%–29%)
Stage IIB	Macroscopic invasion into thymic or surrounding fatty tissue, or grossly adherent to but not breaking through the mediastinal pleura or pericardium	<ul style="list-style-type: none"> - Gross extension into normal thymus or perithymic fat surrounding the tumour (microscopically confirmed) - Adherence to pleura or pericardium, with microscopic confirmation of perithymic invasion 			
Stage III	Macroscopic invasion into neighbouring organ (i.e. pericardium, great vessel or lung)	<ul style="list-style-type: none"> - Microscopic invasion of the mediastinal pleura (either partial or penetrating the elastin layer) - Microscopic invasion of the pericardium (either partial in the fibrous layer or penetrating through to the serosal layer) - Microscopically confirmed direct penetration into the outer elastin layer of the visceral pleura or into the lung parenchyma - Invasion into the phrenic or vagus nerves (microscopically confirmed) - Invasion into or penetration through major vascular structures (microscopically confirmed) - Adherence (i.e. fibrous attachment) of lung or adjacent organs only if there is mediastinal pleural or pericardial invasion (microscopically confirmed) 	70% (64%–75%)	29% (27%–31%)	59% (44%–76%)
Stage IVA	Pleural or pericardial metastasis	<ul style="list-style-type: none"> - Microscopically confirmed separate nodules in the visceral or parietal pleural, pericardial or epicardial surfaces 	42% (26%–58%)	71% (34%–100%)	76% (58%–100%)
Stage IVB	Lymphogenous or haematogenous metastasis	<ul style="list-style-type: none"> - Lymphogenous or haematogenous metastasis 	53% (32%–73%)	57% (24%–90%)	54% (37%–67%)

^aInformation reprinted from [27] with permission of John Wiley & Sons, Inc.

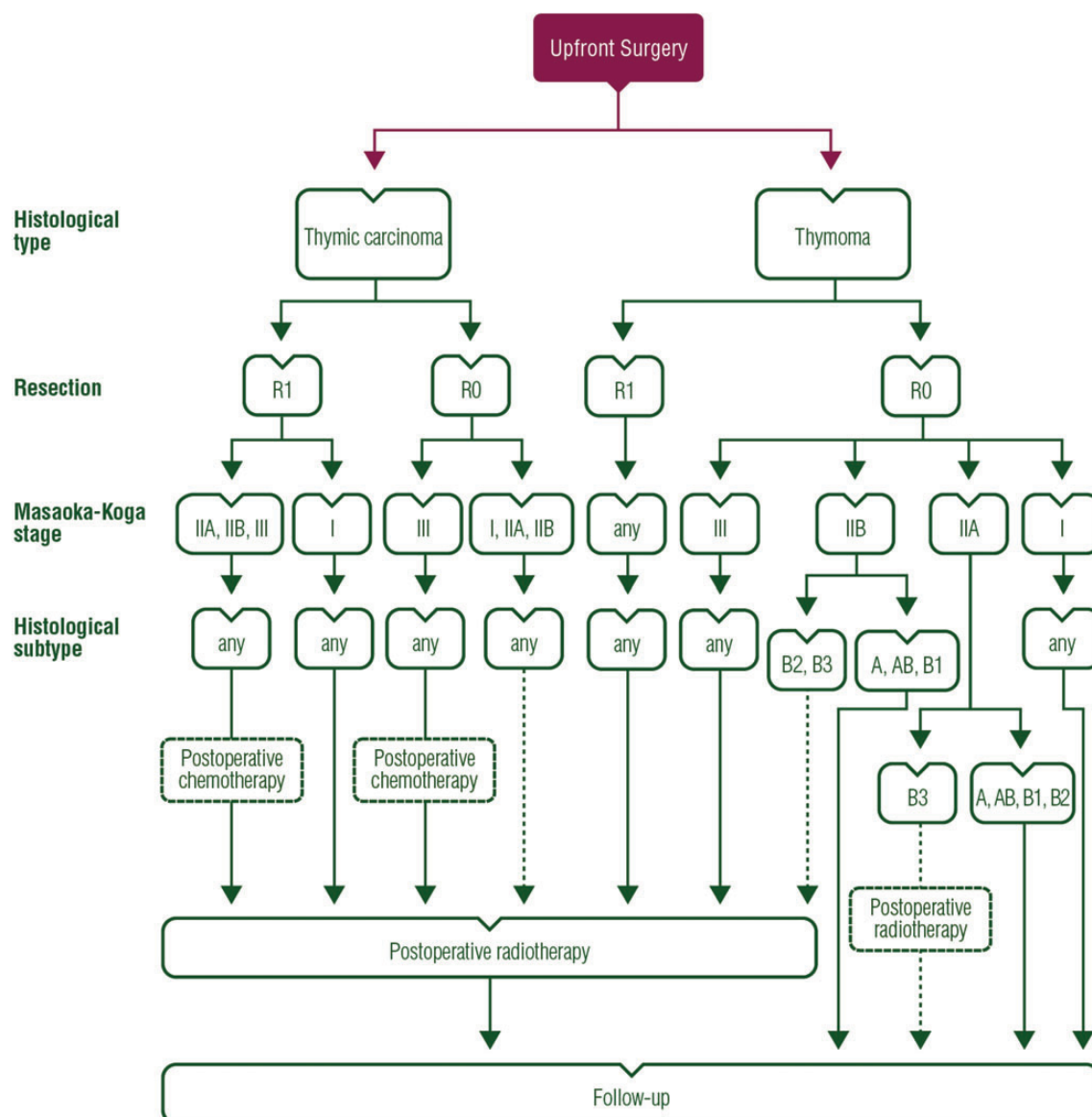


Figure 1. Treatment algorithm for resectable thymic tumour (Masaoka-Koga stage I–III, TNM stage I–IIIA).

risk assessment

Prognostic assessment is challenging, as the impact of tumour stage and histology on OS is superseded by the achievement of a complete resection in reported series [4–7, 28–30]. Moreover, depending on stage, up to 50%–60% of patients actually do not die of progression of the thymic tumour [34]. Autoimmune disorders have been reported as the cause of death in 25% of thymomas, especially those with early-stage tumours. The evolution of these alterations, which are related to the abnormal intrathymomatous selection of constitutively autoreactive lymphocytes, does not parallel that of the tumour. This is contrary to what is observed in paraneoplastic syndromes that are caused by tumour cell-derived cytokines or hormones or by cross-reactive antibodies. The management of autoimmune syndromes will not be discussed in these guidelines, but should be integrated in the oncological management of these patients [V, A].

management of resectable disease

The treatment strategy is based on the resectability of the tumour. If complete resection is deemed to be achievable upfront, as it is the case in Masaoka-Koga stage I/II and some stage III tumours (classified as stage I, II, IIIA/T3 in the IASLC/ITMIG TNM proposed system), surgery represents the first step of the treatment [IV, A], possibly followed by postoperative radiotherapy and, less frequently, chemotherapy (Table 5).

surgical principles

The standard approach is median sternotomy [IV, A], which allows the wide opening of the mediastinum and both pleural cavities, followed by evaluation of macroscopic capsular invasion, infiltration of perithymic and mediastinal fat, peritumoural and pleural adhesions and involvement of surrounding structures [14, 15, 35, 36]. Generally, complete thymectomy

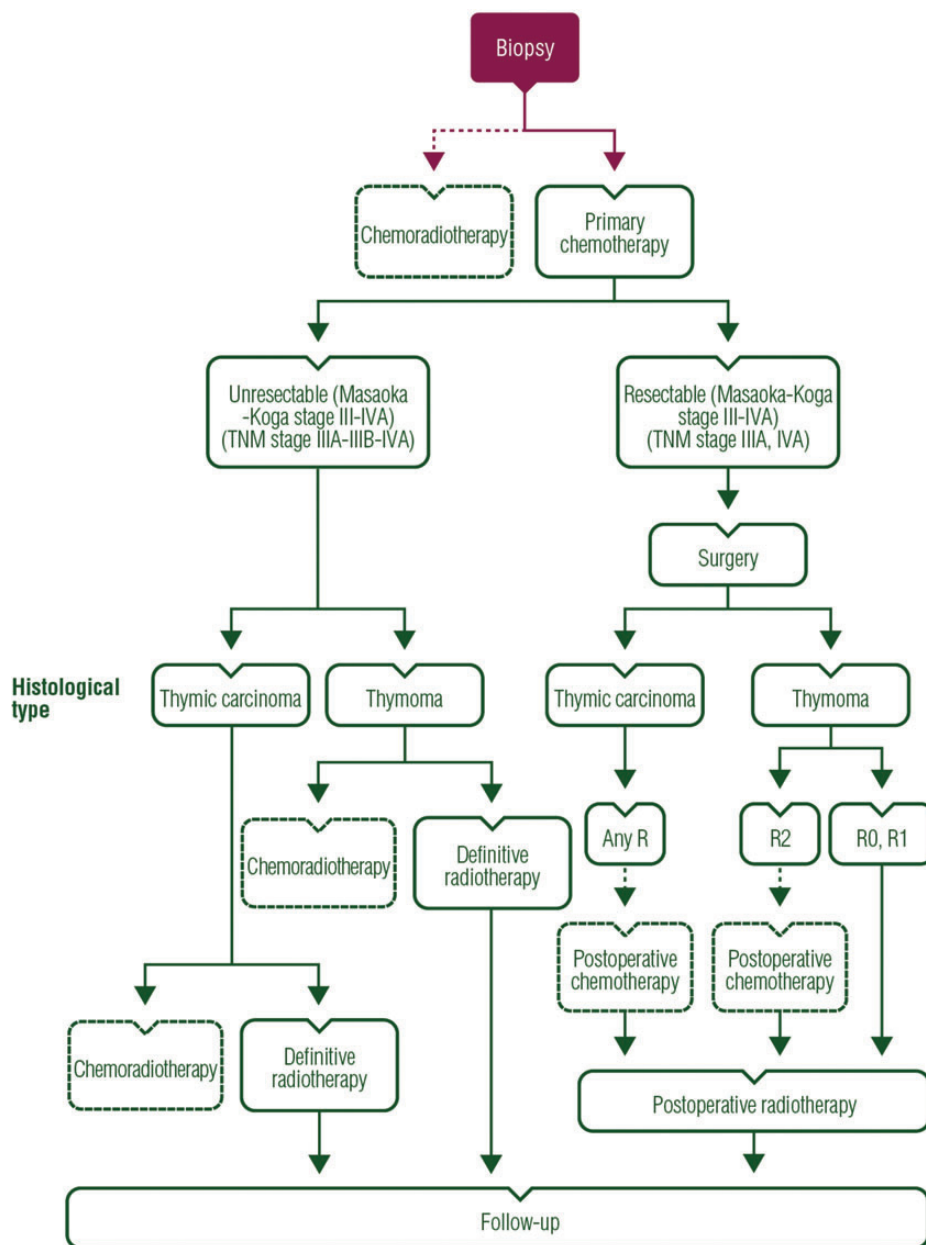


Figure 2. Treatment algorithm for unresectable thymic tumour (Masaoka-Koga stage III–IVA, TNM stage IIIA–III B–IVA).

including the tumour, the residual thymus gland and perithymic fat is preferred because local recurrences have been observed after partial thymectomy when part of the thymus gland is left behind [IV, B]. Thymomectomy—leaving residual thymic tissue and perithymic fat behind—alone is an option in stage I tumours in non-myasthenic patients [IV, C] [14, 37]. If the tumour is widely invasive (stage III/IV), *en bloc* removal of all affected structures, including lung parenchyma (usually through limited resection), pericardium, great vessels, nerves and pleural implants, should be carried out [IV, A]. Resection of venous vascular structures (innominate vein(s) and superior vena cava) include partial resection with suturing or complete resection and vessel reconstruction using vascular prosthesis. Areas of uncertain resection margins are marked with clips to allow precise delivery of postoperative radiotherapy [IV, B]; those

areas are also designated on the resection specimen, as discussed below. Phrenic nerve preservation does not affect OS but increases the risk of local recurrence [IV, C], and should be balanced with the achievement of a complete resection, especially in patients with severe myasthenia gravis [38, 39]. Frozen sections to assess tumour involvement of resection margins are not recommended [V, D], given the high risk of false-negative results [36].

Minimally invasive surgery is an option for presumed stage I and possibly stage II tumours in the hands of appropriately trained thoracic surgeons [IV, C] [14, 35, 40]. This includes transcervical, extended transcervical, video-assisted thoracoscopy (VATS) and robotic approaches (right or left, right and left, right and cervical, left and cervical, subxiphoid and right and left, cervical and subxiphoid); robotic surgery may allow a

better visualisation of the tumour when compared with VATS. The choice for minimally invasive resection should not

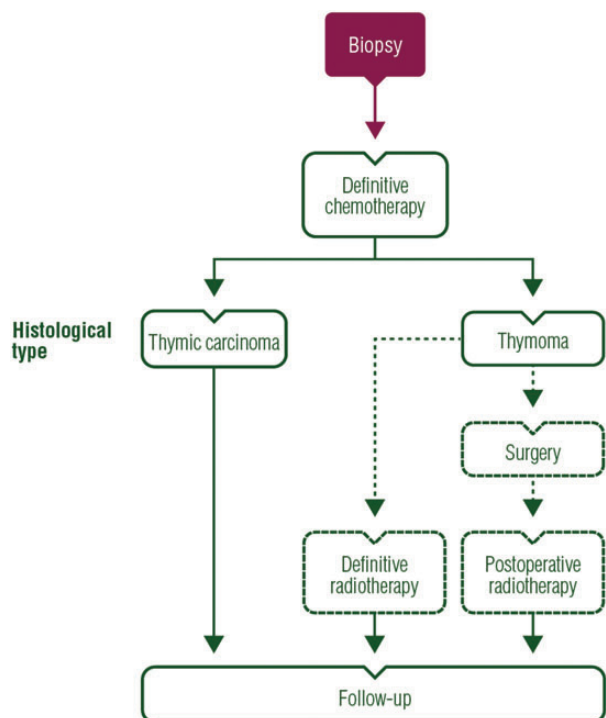


Figure 3. Treatment algorithm for metastatic thymic tumour (Masaoka-Koga stage IVB, TNM stage IVB).

jeopardise or change the principles that are deemed appropriate for an open approach, especially the achievement of complete resection that may ultimately require switching to an open procedure [V, A]. Minimally invasive surgery is not recommended for stage III tumours, given the absence of long-term follow-up data [IV, D].

Lymphadenectomy has historically rarely been carried out after resection of thymic tumours. The new IASLC/ITMIG TNM staging system of thymic tumours, however, leads to the recommendation that locoregional lymphadenectomy should be carried out during resection of all types of thymic tumours. A proposed nodal map is available from ITMIG [41]. The proposed N descriptor in the staging system includes:

- anterior region (N1), which involves the anterior mediastinal nodes (prevascular, para-aortic, ascending aorta, superior and inferior phrenic and supradiaphragmatic) and the anterior cervical nodes (low anterior cervical); and
- the deep region (N2), which includes the middle mediastinal (internal mammary, upper and lower paratracheal, subaortic, subcarinal and hilar) and the deep cervical (lower jugular and supraclavicular).

Routine removal of anterior mediastinal nodes and anterior cervical nodes is recommended [IV, A]. Systematic sampling of other intrathoracic sites is encouraged (i.e. paratracheal, aortopulmonary window and subcarinal areas, depending on tumour location) in stage III/IV tumours [V, B] [36]. Systematic lymphadenectomy (N1 + N2) is strongly recommended in case of

Table 4. Proposed Tumour–Node–Metastasis staging (International Association for the Study of Lung Cancer Prognostic Factors Committee- International Thymic Malignancy Interest Group) [30] and corresponding Masaoka-Koga stage

Stage	Descriptors	
Tumour		
T1	T1a	Encapsulated or unencapsulated, with or without extension into the mediastinal fat
	T1b	Extension into the mediastinal pleura
T2		Direct invasion of the pericardium (partial or full-thickness)
T3		Direct invasion of the lung, the brachiocephalic vein, the superior vena cava, the chest wall, the phrenic nerve and/or hilar (extrapericardial) pulmonary vessels
T4		Direct invasion of the aorta, arch vessels, the main pulmonary artery, the myocardium, the trachea or the oesophagus
Node		
N0		N0 No nodal involvement
N1		N1 Anterior (perithymic) nodes (IASLC levels 1, 3a, 6 and/or supradiaphragmatic/inferior phrenics/pericardial)
N2		N2 Deep intrathoracic or cervical nodes (IASLC levels 2, 4, 5, 7, 10 and/or internal mammary nodes)
Metastasis		
M0		No metastatic pleural, pericardial or distant sites
M1	M1a	Separate pleural or pericardial nodule(s)
	M1b	Pulmonary intraparenchymal nodule or distant organ metastasis
Stage grouping		Corresponding Masaoka-Koga stage
I	T1N0M0	I, IIA, IIB, III
II	T2N0M0	III
IIIA	T3N0M0	III
IIIB	T4N0M0	III
IVA	T any N0,1 M0,1a	IVA, IVB
IVB	T any N0-2 M0-1b	IVB

Table 5. Stage-matched therapeutic strategy

Masaoka-Koga stage	Thymoma	Thymic carcinoma
Stage I	Upfront surgery [IV, A] No biopsy [IV, E] If complete resection (R0): no postoperative radiotherapy [II, E] If incomplete resection (R1): postoperative radiotherapy (50–54 Gy) [IV, B]	Upfront surgery [IV, A] No biopsy [IV, E] If resection complete (R0): consider postoperative radiotherapy (45–50 Gy) [V, C] If incomplete resection (R1): postoperative radiotherapy (50–54 Gy) [IV, B]
Stage IIA	Upfront surgery [IV, A] No biopsy [IV, E] If complete resection (R0): <ul style="list-style-type: none"> – Type A–B2: no postoperative radiotherapy [IV, C] – Type B3: consider postoperative radiotherapy (45–50 Gy) [IV, C] If incomplete resection (R1): <ul style="list-style-type: none"> – Postoperative radiotherapy (50–54 Gy) [IV, B] 	Upfront surgery [IV, A] No biopsy [IV, E] If complete resection (R0): <ul style="list-style-type: none"> – Consider postoperative radiotherapy (45–50 Gy) [IV, B] If incomplete resection (R1): <ul style="list-style-type: none"> – Postoperative radiotherapy (50–54 Gy) [IV, B] – Consider postoperative chemotherapy
Stage IIB	Upfront surgery [IV, A] No biopsy [IV, E] If complete resection (R0): <ul style="list-style-type: none"> – Type A–B1: no postoperative radiotherapy [IV, C] – Type B2–B3: consider postoperative radiotherapy (45–50 Gy) [IV, C] If incomplete resection (R1): <ul style="list-style-type: none"> – Postoperative radiotherapy (50–54 Gy) [IV, B] 	Upfront surgery [IV, A] No biopsy [IV, E] If complete resection (R0): <ul style="list-style-type: none"> – Consider postoperative radiotherapy (45–50 Gy) [IV, B] If incomplete resection (R1): <ul style="list-style-type: none"> – Postoperative radiotherapy (50–54 Gy) [IV, B] – Consider postoperative chemotherapy
Stage III–IVA	Resectable tumour (TNM I–IIIA, i.e. T1–3): <ul style="list-style-type: none"> – Upfront surgery [IV, A] – Postoperative radiotherapy (45–50 Gy), with boost on areas of concern [IV, B] Unresectable tumour (TNM IIIA–B, i.e. T3–T4, IVA): <ul style="list-style-type: none"> – Biopsy – Primary chemotherapy (prefer anthracycline-based) [III, A] – If the tumour becomes resectable: <ul style="list-style-type: none"> – Surgery [III, A] – Postoperative radiotherapy (45–50 Gy), with boost on areas of concern (R0, R1 resection) [IV, B] – If the tumour remains unresectable or R2: <ul style="list-style-type: none"> – Definitive radiotherapy (60 Gy) [IV, B] – Option: chemoradiotherapy – Option: concurrent chemoradiotherapy (platin and etoposide, 60 Gy) [III, B] 	Resectable tumour (TNM I–IIIA, i.e. T1–3): <ul style="list-style-type: none"> – Upfront surgery [IV, A] – Postoperative radiotherapy (40–50 Gy), with boost on areas of concern [IV, B] – Consider postoperative chemotherapy Unresectable tumour (TNM IIIA–B, i.e. T3–T4, IVA): <ul style="list-style-type: none"> – Biopsy – Primary chemotherapy (prefer anthracycline-based) [III, A] – If the tumour becomes resectable: <ul style="list-style-type: none"> – Surgery [III, A] – Postoperative radiotherapy (45–50 Gy), with boost on areas of concern (R0, R1 resection) [IV, B] – Consider postoperative chemotherapy (R0, R1 resection) – If the tumour remains unresectable or R2: <ul style="list-style-type: none"> – Definitive radiotherapy (60 Gy) [IV, B] – Option: chemoradiotherapy – Option: concurrent chemoradiotherapy (platin and etoposide, 60 Gy)
Stage IVB	Definitive chemotherapy [III, A] <ul style="list-style-type: none"> – If the tumour becomes resectable, consider: <ul style="list-style-type: none"> – Surgery and postoperative radiotherapy – Definitive radiotherapy 	Definitive chemotherapy [III, A]

thymic carcinoma due to the high rate of lymphatic spread (20% versus 3% in thymomas) [V, B].

surgical pathology principles

Communication between surgeons and pathologists is required to accurately stage thymic epithelial tumours [V, A] [36]. The proper orientation of the specimen and the designation of

involved structures, organs or areas of likely residual microscopic or macroscopic disease are the primary responsibility of the operating surgeon, and may be done using a mediastinal board [V, B].

The final pathological examination leads to a final histological diagnosis and staging of the tumour, based on the WHO classification and the Masaoka-Koga system, respectively (Tables 1 and 3). Staging according to the proposed IASLC/ITMIG TNM system is optional [V, C]. Given the potential heterogeneity of

thymic epithelial tumours, a sufficient number of representative sections should be examined regardless of the tumour diameter (at least five sections up to a diameter of 5 cm, with one additional block per additional centimetre of maximal diameter); if the margin is <1 mm, at least three additional sections through this area should be obtained [V, B]. Completeness of resection should be assessed, making the distinction between tissues that have been cut or dissected, and a surface bounded by a space (such the mediastinal pleura, pericardium or endothelium of the innominate veins), which should not be designated as a positive margin [V, A].

postoperative radiotherapy

Current practices for postoperative mediastinal radiotherapy are highly variable and there is paucity of prospective, multicentre evidence. The global trend over the past years has been towards a less frequent use of postoperative radiotherapy in thymoma, and to keep it in reserve for high-risk cases (Table 5) [14–16]. This is based on recent reports from large databases [6, 7, 42–45], as well as pooled analyses of retrospective studies [46], indicating:

- the absence of survival benefit after radiotherapy in stage I thymoma, or after R0/I resection of stage II–III thymoma [7, 42, 43];
- a similar rate of recurrence in patients who received postoperative radiotherapy or not, after complete resection of thymoma [46]; and
- a recurrence-free survival (RFS) and OS benefit with postoperative radiotherapy after resection of thymic carcinoma [7, 44, 45].

Stage and completeness of resection are thus the most relevant criteria in the decision making, followed by histology [IV, B]. Those factors are the most significant predictors of RFS [4–7, 28–29]; however, one must take into account that retrospective analyses are likely to be biased, since postoperative radiotherapy is most likely administered in patients with incomplete resection or high-grade tumours. Therefore, the absence of survival differences may then suggest that postoperative radiotherapy reduced or overcame the risk of recurrence in those patients. Another point to consider is that recurrences of thymic epithelial tumours occur outside the mediastinum in more than 60% of cases [47]. The development of the TNM system leads to redefinition of subsets of patients, based especially on the T descriptors, that may help to clarify which patients benefit from postoperative radiotherapy. Meanwhile, the grouping of Masaoka-Koga stage I, IIA, IIB and some stage III tumours in one single T1 category must be assessed in dedicated studies.

Current evidence for postoperative radiotherapy in thymic epithelial tumours support the use of:

- 3D conformal radiotherapy or intensity-modulated radiation therapy targeted to the tumour bed, keeping at-risk thoracic organs within accepted safe constraints [IV, A];—clinical target volume includes the whole thymic space, the tumour and its extensions and the anterior, superior and middle mediastinum [IV, A].
- a total dose of 45–50 Gy after complete resection, 50–54 Gy after R1 resection, with a boost to areas of likely residual disease (as mentioned above, surgical clips may then be useful

to define the target volume) [IV, B]; however, the optimal postoperative dose/fractionation is still to be defined; and

- conventional fractionation scheme consisting of daily doses of 1.8–2 Gy over a 4- to 6-week period [IV, A] [48]. The field may encompass involved nodes [IV, B] and the site of a resected pleural implant [V, C].

Prophylactic irradiation of supraclavicular nodes is not recommended [V, E]. Low-dose entire hemithoracic radiotherapy is also not recommended [IV, C] [49]. Ideally, postoperative radiotherapy should start within 3 months of the surgical procedure [V, B].

thymomas. Postoperative radiotherapy is not indicated after complete resection of Masaoka-Koga stage I thymoma [II, E]. One randomised trial including 29 patients compared postoperative radiotherapy versus surgery alone in this setting, and failed to show any differences in patient outcome [50].

Postoperative radiotherapy is not recommended after complete resection of stage II thymoma [IV, C]. In the ITMIG database, cumulative incidence of mediastinal or extramediastinal recurrence was only 8% at 10 years (Table 2) [28]. Postoperative radiotherapy may be considered in case of aggressive histology (type B2, B3) or extensive transcapsular invasion (stage IIB) [IV, C] [51–53].

Postoperative radiotherapy is recommended after complete resection of stage III/IVA thymoma, in an effort to prolong RFS and OS [IV, B] [54].

thymic carcinoma. After complete resection of thymic carcinoma, postoperative radiotherapy is optional for stage I tumours [V, C], should be considered for stage II tumours [IV, B] and is recommended for stage III/IVA tumours [IV, B] [7, 44, 45]. Postoperative radiotherapy is recommended in case of microscopically (R1) or macroscopically incomplete (R2) resection [IV, B], to a total dose of 50–54 and 60 Gy, respectively, with a 10-Gy boost directed to areas of likely residual disease.

postoperative chemotherapy

thymomas. Postoperative chemotherapy is not recommended after R0–R1 resection of a thymoma [III, E] [6, 14–16, 55].

thymic carcinomas. Since thymic carcinomas do present with frequent and early locoregional and systemic recurrences after incomplete surgery [3, 7, 28, 44, 45], postoperative chemotherapy may be considered as an option in stage II/III/IV thymic carcinomas, especially if not delivered as induction treatment (Table 5) [14–16].

management of advanced disease

If complete resection is deemed not to be achievable upfront on the basis of imaging studies, as it is frequently the case in Masaoka-Koga stage III/IVA tumours (classified as stage IIIA/T3, IIIB/T4, /IVA in the IASLC/ITMIG TNM proposed system), a biopsy should be carried out, followed by primary/induction chemotherapy as part of a curative-intent sequential strategy that integrates subsequent surgery or radiotherapy [14–16].

Table 6. Selected chemotherapy regimens for advanced thymic epithelial tumours assessed in phase II trials (adapted from [60] with permission of Informa Healthcare)

Regimen	Agents	Doses
ADOC	Doxorubicin	40 mg/m ² /3 weeks
	Cisplatin	50 mg/m ² /3 weeks
	Vincristine	0.6 mg/m ² /3 weeks
	Cyclophosphamide	700 mg/m ² /3 weeks
CAP	Cisplatin	50 mg/m ² /3 weeks
	Doxorubicin	50 mg/m ² /3 weeks
	Cyclophosphamide	500 mg/m ² /3 weeks
PE	Cisplatin	60 mg/m ² /3 weeks
	Etoposide	120 mg/m ² × 3 days/3 weeks
VIP	Etoposide	75 mg/m ² × 4 days/3 weeks
	Ifosfamide	1.2 g/m ² × 4 days/3 weeks
	Cisplatin	20 mg/m ² × 4 days/3 weeks
CODE	Cisplatin	25 mg/m ² /1 week
	Vincristin	1 mg/m ² /2 weeks
	Doxorubicin	40 mg/m ² /2 weeks
	Etoposide	80 mg/m ² × 3 days/2 weeks
Carbo-Px	Carboplatin	AUC 5–6/3 weeks
	Paclitaxel	200–225 mg/m ² /3 weeks
CAP-GEM	Capecitabine	650 mg/m ² b.i.d. 14 days/3 weeks
	Gemcitabine	1000 mg/m ² × 2 days/3 weeks

Patients not eligible for local treatment should receive palliative chemotherapy only.

primary chemotherapy

Primary/induction chemotherapy is standard in non-resectable advanced thymic epithelial tumours [III, A] [56–58]. Cisplatin-based combination regimens should be administered; combinations of cisplatin, doxorubicin and cyclophosphamide, and cisplatin and etoposide, are the recommended options (Table 6) [III, A] [59, 60]. Primary chemoradiotherapy with platin and etoposide is an option, especially for thymic carcinomas [III, B] [33, 61].

Usually, two to four cycles are administered before imaging is carried out to reassess resectability of the tumour [III, A]. Surgery should be offered to patients for whom complete resection is deemed achievable, according to principles discussed above [III, A]; extended resection may be required [62]. Hyperthermic intrapleural chemotherapy, as well as extra-pleural pneumonectomy, may be discussed in case of stage IVA tumour [IV, C] [63, 64]. Postoperative radiotherapy delivery should follow.

Subtotal resection, so-called debulking resection, is an option in selected cases of thymoma, aiming at facilitating subsequent definitive radiotherapy [IV, C] [65]. Debulking is not recommended in thymic carcinoma [V, D]. Postoperative chemoradiotherapy (including cisplatin, etoposide chemotherapy and a total dose of radiation of 60 Gy in 30 fractions) may be considered after debulking/R2 resection [IV, B].

definitive radiotherapy

If the patient is not deemed a surgical candidate—either because R0 resection is not thought to be achievable, or because of poor

performance status or co-existing medical conditions—definitive radiotherapy is recommended as part of a sequential chemoradiotherapy strategy [III, A] [56]. Combination with chemotherapy (including cisplatin, etoposide chemotherapy and a total dose of radiation of 60–66 Gy in 30–33 fractions) may be considered [V, C].

definitive chemotherapy

Chemotherapy should be offered as single modality treatment in advanced, non-resectable, non-irradiable or metastatic (stage IVB) thymic epithelial tumours. The aim is to relieve tumour-related symptoms by eliciting tumour shrinkage, while prolonged survival is uncertain [III, A]. Cisplatin-based combination regimens should be administered [III, A] (Table 6) [66–71]. No randomised studies have been conducted and which regimen should be considered standard remains unknown. Multiagent combination regimens and anthracycline-based regimens appear to have improved response rates compared with etoposide-based regimens [59, 60, 72]. Combination of cisplatin, doxorubicin and cyclophosphamide is preferred [III, B]. Combination of carboplatin and paclitaxel is an option for thymic carcinoma [69, 71] [III, B]. Surgery or radiotherapy is possible in rare and selected metastatic cases, without proven outcome benefit [IV, C].

Response Evaluation Criteria in Solid Tumours (RECIST) v1.1 criteria should be used to assess response to chemotherapy [V, A]; adapted criteria for pleural lesions include the use of the short axis as the measurement plane and the unidimensional measurement of two pleural tumour sites at three different levels [73].

recurrences

Recurrences of thymic epithelial tumours are not uncommon (~10%–15% of all-stage resected tumours) and should be managed according to the same strategy as newly diagnosed tumours [IV, A]. The average time-to-recurrence in completely resected thymic tumours is 5 years (with a range of 3–7 years). Complete resection of recurrent lesions represents a major predictor of favourable outcome [74–76], and surgery is then recommended in the case of resectable lesion. Of note, histological switch from lymphocytic lesions to more epithelial tumours has been reported, and may be related to tumour heterogeneity, as well as the effect of previous corticosteroid and chemotherapy treatment [74].

In non-resectable recurrences, several consecutive lines of chemotherapy may be administered when the patient presents with tumour progression (Table 6). The re-administration of a previously effective regimen should be considered [IV, B], especially in case of previous response, late occurring recurrence and, for anthracyclines, a patient in a good medical condition who has not received cumulative doses precluding the safe delivery of at least three additional cycles [77]. Of note, the risk of cardiac toxicity is further increased in patients having received previous mediastinal radiotherapy. Participation to clinical trials is recommended.

Preferred regimens for second-line treatment include carboplatin plus paclitaxel [69], and platin plus etoposide [67] [III, B]; capecitabine plus gemcitabine is an option (Table 6) [III, B]. These regimens were evaluated in dedicated phase II trials.

Table 7. Summary of recommendations**Diagnosis**

- Thymic epithelial tumours are classified according to the WHO histopathological classification.
- Although designed for surgical resection specimen, the WHO classification may be used for small biopsies [V, A].
- Immunohistochemistry with anti-CD117/KIT and anti-CD5 antibodies is useful to establish the thymic primary nature of a mediastinal carcinoma [V, A].
- Each component of heterogeneous tumours may be quantified by 10% increments [V, C].
- Consultation with a second pathologist or referral of the case to a thymic tumour pathology panel is recommended whenever there is any diagnostic difficulty.
- Oncogenetic assessment should be carried out in case of familial thymic epithelial tumour, looking especially at MEN1.

Imaging and diagnostic tests

- Thymoma is the first diagnosis to consider when facing a mediastinal mass associated with autoimmune disease [IV, A].
- The diagnosis of any thymic epithelial tumour relies on making the differential diagnosis with other anterior mediastinal tumours and non-malignant thymic lesions.
- Standard imaging for thymic tumours is i.v. contrast-enhanced (CT) scan of the thorax [IV, A].
- MRI is recommended to differentiate thymic tumour from hyperplasia whenever CT scan is doubtful, or in case of cystic lesion [IV, B].
- PET scan is generally not recommended to assess thymic masses [IV, C].
- Therapeutic intervention is usually not required if the lesion is <30 mm, given a low risk of progression or thymic malignancy [III, D].
- Systematic immunological check-up is recommended, including complete blood cells count with reticulocytes and serum protein electrophoresis, as well as anti-acetylcholine receptor and anti-nuclear antibodies tests [V, A].

Need for a biopsy

- Pretreatment biopsy is not required if the diagnosis of thymic epithelial tumour is highly suspected and upfront surgical resection is achievable [IV, E].
- Biopsy is required in all other clinical situations [IV, A]; approaches may consist of percutaneous core-needle biopsy or incisional surgical biopsy through mediastinotomy or mini-thoracotomy. Fine-needle aspiration is not recommended [IV, D].

Staging

- Thymic epithelial tumours are routinely staged according to the Masaoka-Koga staging system [III, A]. Masaoka-Koga staging is a surgical pathology system that is assessable only after surgical resection of the tumour.
- Staging according to proposed IASLC/ITMIG TNM system is optional [V, C].
- The Masaoka-Koga staging system should remain the standard for the routine management of patients, pending the approval of the AJCC and UICC [III, A].

Risk assessment

- The management of autoimmune syndromes should be integrated in the oncological management of these patients [V, A].

Management of resectable disease

- The treatment strategy for thymic epithelial tumour is primarily based on whether the tumour may be resected upfront or not [IV, A].
- The assessment of resectability is mostly based on the surgeon's expertise; it is recommended to discuss indications for surgery in a multidisciplinary tumour board setting [V, B].
- If complete resection is deemed to be achievable upfront, surgery represents the first step of the treatment [IV, A].

Surgery principles

- Standard approach is median sternotomy [IV, A].
- Complete thymectomy including the tumour, the residual thymus gland and perithymic fat, is preferred [IV, B].
- Thymomectomy alone—leaving residual thymic tissue and perithymic fat behind—is an option in stage I tumours in non-myasthenic patients [IV, C].
- If the tumour is widely extensive invasive (stage III/IV), *en bloc* removal of all affected structures, including lung parenchyma (usually through limited resection), pericardium, venous great vessels, nerves and pleural implants, should be carried out [IV, A].
- Areas of uncertain margins are marked with clips to allow precise delivery of postoperative radiotherapy [IV, B]; those areas are also designated on the resection specimen.
- Phrenic nerve preservation does not affect OS but increases the risk of local recurrence [IV, C].
- Frozen sections to assess tumour involvement of resection margins are not recommended [V, D].
- Minimally invasive surgery is an option for presumed stage I–II tumours in the hands of appropriately trained thoracic surgeons [IV, C].
- The choice for minimally invasive resection should not jeopardise or change the principles that are deemed appropriate for an open approach, especially the achievement of complete resection that may ultimately require switching to an open procedure [V, A].
- Minimally invasive surgery is not recommended for stage III tumours, given the absence of long-term follow-up data [IV, D].
- Routine removal of anterior mediastinal and anterior cervical nodes is recommended [IV, A].
- Systematic sampling of intrathoracic sites is encouraged in stage III/IV tumours [V, B].
- Systematic lymphadenectomy (N1 + N2) is strongly recommended in case of thymic carcinoma due to the high rate of lymphatic spread [V, B].

Continued

Table 7. *Continued***Surgical pathology principles**

- Communication between surgeons and pathologists is required to accurately stage thymic epithelial tumours [V, A].
- The proper orientation of the specimen and the designation of involved structures, organs or areas of likely residual microscopic or macroscopic disease are the primary responsibility of the operating surgeon and may be done using a mediastinal board [V, B].
- A sufficient number of representative sections should be examined regardless of the tumour diameter; if the margin is <1 mm, at least three additional sections through this area should be obtained [V, B].
- Completeness of resection should be assessed, making the distinction between tissues that have been cut or dissected, and a surface bounded by a space, which should not be designated as a positive margin [V, A].

Postoperative radiotherapy

- Postoperative radiotherapy should start within 3 months of the surgical procedure [V, B].
- The use of 3D conformal radiotherapy or intensity-modulated radiation therapy targeted to the tumour bed is recommended [IV, A].
- Clinical target volume includes the whole thymic space, the tumour and its extensions and the anterior, superior and middle mediastinum [IV, A].
- Standard dose constraints for thoracic radiotherapy should be used.
- Total dose of 45–50 Gy after complete resection, 50–54 Gy after R1 resection, with a boost to areas of likely residual disease are recommended (surgical clips may then be useful to define the target volume) [IV, B].
- The use of a conventional fractionation scheme is recommended in daily doses from 1.8 to 2 Gy over a 4- to 6-week period [IV, A].
- The field may encompass involved nodes [IV, B], and the site of a resected pleural implant [V, C].
- Prophylactic irradiation of supraclavicular nodes is not recommended [V, E].
- Low-dose entire hemithoracic radiotherapy is not recommended [IV, C].
- After complete resection of thymoma:
 - Postoperative radiotherapy is not indicated after complete resection of Masaoka-Koga stage I thymoma [II, E].
 - Postoperative radiotherapy is not recommended after complete resection of stage II thymoma [IV, C], but may be considered in case of aggressive histology (type B2, B3) or transcapsular invasion (stage IIB) [IV, C].
 - Postoperative radiotherapy is recommended after complete resection of stage III/IVA thymoma [IV, B].
- After complete resection of thymic carcinoma:
 - postoperative radiotherapy is optional for stage I tumours [V, C],
 - it should be considered for stage II tumours [IV, B] and
 - it is recommended for stage III/IVA tumours [IV, B].
- Postoperative radiotherapy is recommended in case of microscopically (R1) or macroscopically incomplete (R2) resection [IV, B], to a total dose of 50–54 and 60 Gy, respectively, with a 10-Gy boost to areas of likely residual disease.

Postoperative chemotherapy

- Postoperative chemotherapy is not recommended after R0–R1 resection of a thymoma [III, E].
- Postoperative chemotherapy may be considered as an option in stage II/III/IV thymic carcinomas, especially if not delivered as induction treatment.

Management of advanced disease

- If complete resection is deemed not to be achievable upfront, primary/induction chemotherapy is administered, part of curative-intent sequential strategy integrating subsequent surgery or radiotherapy. Cases not eligible for local treatment receive palliative chemotherapy only.

Primary/induction chemotherapy

- Primary/induction chemotherapy is the standard in non-resectable locally advanced thymic epithelial tumours [III, A].
- Cisplatin-based combination regimens should be administered; combinations of cisplatin, doxorubicin and cyclophosphamide, and cisplatin and etoposide are recommended options [III, A].
- Primary chemoradiotherapy with platin and etoposide chemotherapy is an option for thymic carcinomas [III, B].
- Usually, two to four cycles are administered before imaging is carried out to reassess resectability of the tumour [III, A].
- Surgery should be offered to patients for whom complete resection is deemed achievable after primary chemotherapy, according to principles discussed in the text [III, A].
- Hyperthermic intrapleural chemotherapy, as well as extra-pleural pneumonectomy, may be discussed in case of stage IVA tumour [IV, C].
- Postoperative radiotherapy is recommended.
- Subtotal resection, so-called debulking resection, is an option in selected cases of thymoma, aiming at facilitating subsequent definitive radiotherapy [IV, C].
- Debulking is not recommended in thymic carcinoma [V, D].
- Postoperative chemoradiotherapy (including cisplatin, etoposide chemotherapy and a total dose of radiation of 60 Gy) may be considered after debulking/R2 resection [IV, B].

Definitive radiotherapy

- When the patient is not deemed to be a surgical candidate, definitive radiotherapy is recommended as part of a sequential chemoradiotherapy strategy [III, A].
- Combination with chemotherapy (including cisplatin, etoposide chemotherapy and a total dose of radiation of 60–66 Gy) may be considered [V, C].

Continued

Table 7. Continued

Definitive chemotherapy

- Chemotherapy should be offered as the single modality treatment in advanced, non-resectable, non-irradiable or metastatic (stage IVB) thymic epithelial tumour [III, A].
- Cisplatin-based multiagent combination regimens should be administered [III, A].
- Combination of cisplatin, doxorubicin and cyclophosphamide is preferred [III, B].
- Combination of carboplatin and paclitaxel is an option for thymic carcinoma [III, B].
- Surgery or radiotherapy is possible in rare and selected metastatic cases without proven outcome benefit [IV, C].
- RECIST v1.1 criteria should be used to assess response to chemotherapy [V, A].

Recurrences

- Recurrences of thymic epithelial tumours should be managed according to the same strategy as newly diagnosed tumours [IV, A].
- Complete resection of recurrent lesions, when achievable, is recommended.
- Several consecutive lines of chemotherapy may be administered when the patient presents with tumour progression. The re-administration of a previously effective regimen should be considered [IV, B].
- Preferred regimens for second-line treatment include carboplatin plus paclitaxel, and platin plus etoposide [III, B]; capecitabine plus gemcitabine is an option [III, B].
- Options for subsequent lines include pemetrexed [III, B] and oral etoposide.
- In patients with octreoscan-positive thymoma not eligible to receive additional chemotherapy, octreotide alone or with prednisone may represent a valuable option [III, B].

Targeted agents

- *KIT* sequencing (exons 9–17) is an option for refractory thymic carcinomas in the setting of potential access to specific inhibitors, particularly in the context of clinical trials [IV, B].
- It is not recommended to administer imatinib in the absence of a *KIT*-sensitising mutation [III, E].
- Sunitinib is an option as second-line treatment of thymic carcinomas independently from *KIT* status [III, A].
- Everolimus may represent an option for refractory tumours [III, B].

Follow-up

- Baseline thoracic CT scan should be carried out 3–4 months after surgery [V, C].
- For completely resected stage I/II thymomas: CT scan should be done every year for 5 years, then every 2 years [V, C].
- For stage III/IV thymomas, thymic carcinoma or after R1–2 resection: CT scan should be done every 6 months for 2 years, then annually [V, C].
- Follow-up may be continued for 10–15 years [V, C].
- Patients with clinical myasthenia gravis, or even isolated positive anti-acetyl choline receptor antibodies, should be informed and educated about the risks of myasthenic crisis in specific situations such as stress or the administration of certain drugs [V, A].

WHO, World Health Organization; MEN1, multiple endocrine neoplasia 1; CT, computed tomography; MRI, magnetic resonance imaging; PET scan, positron emission tomography scan; AJCC, American Joint Committee on Cancer; UICC, Union for International Cancer Control; OS, overall survival; RECIST, Response Evaluation Criteria in Solid Tumours; IASLC, International Association for the Study of Lung Cancer; ITMIG, International Thymic Malignancy Interest Group; TNM, tumour node metastasis.

Options for subsequent lines include pemetrexed [78] [III, B] and oral etoposide. In patients with octreoscan-positive thymoma not eligible to receive additional chemotherapy, octreotide alone or with prednisone may represent a valuable option [III, B] [79, 80].

personalised medicine

Molecular characterisation of thymic epithelial tumours indicates the occurrence of chromosomal aberrations, altered DNA methylation and deregulated expression of cancer-related genes, such as *CDKN2*, *MGMT*, *FOXCl*, *IGF-1R* [81]; some of those alterations and gene expression signatures were reported to associate preclinically with the efficacy of some targeted agents, or to predict recurrence or survival of patients [81, 82].

Personalised medicine approaches in thymic malignancies are ultimately hampered by the limited amount of available research to identify reliable, validated molecular markers with prognostic

or predictive value. However, the recent identification of molecular alterations occurring in the *KIT*, vascular endothelial growth factor receptors (VEGFRs) and mammalian target of rapamycin (mTOR) signalling pathways, may lead to consideration—in an off-label setting—of the use of targeted agents for the treatment of refractory thymic malignancies.

targeting of KIT

While *KIT* is overexpressed in 80% of thymic carcinomas, *KIT* gene mutations are found only in 9% of cases, consisting of mutations observed in gastrointestinal stromal tumours or melanomas (V560del, L576P), or restricted to thymic carcinomas (H697Y, D820E) [81]. Responses were reported with the use of *KIT* tyrosine kinase inhibitors (TKIs) imatinib, sunitinib or sorafenib, mostly in single-case observations [59]. *KIT*-mutant tumours are not uniformly sensitive to imatinib, based on the clinical and/or the preclinical evidence in thymic carcinoma

and/or other *KIT*-mutant malignancies. *KIT* sequencing (exons 9–17) is an option for refractory thymic carcinomas in the setting of potential access to such inhibitors, particularly in the context of clinical trials [IV, B].

It is not recommended to administer imatinib in the absence of a *KIT*-sensitising mutation, following the report showing the absence of activity in two phase II trials conducted in this setting [III, E] [83, 84].

The use of *KIT* inhibitors is off-label in thymic malignancies.

targeting of angiogenesis

Available *KIT* TKIs also potently inhibit other kinases, including VEGFRs and platelet-derived growth factor receptors activated in thymic malignancies [85, 86]. A phase II trial recently demonstrated the efficacy of sunitinib in terms of response and disease control rate (DCR) in thymic epithelial tumours, including thymic carcinomas [objective response rate (ORR) 26%; DCR: 91%] and, to a lesser extent, thymomas (ORR: 6%; DCR: 81%) [82]. Sunitinib may then represent an off-label option as second-line treatment of thymic carcinomas, independently from *KIT* status [III, A]. There is no reliable clinical data reporting on anti-tumour efficacy of other anti-angiogenic drugs, including aflibercept and bevacizumab.

targeting mammalian target of rapamycin

mTOR is emerging as a potential target in thymic epithelial tumours, following tumour responses observed in phase I trials

[87]. Everolimus was evaluated in thymic epithelial tumours in a recently reported phase II trial reporting on a 22% response rate, as well as a 93% DCR [88]. Everolimus may, therefore, represent an off-label option for refractory tumours [III, B].

follow-up and long-term implications

No prospective data are available to build recommendations about post-treatment oncological follow-up of patients. While a relapse might still be treatable in a curative-intent, patients should benefit from a regular radiological assessment. Based on expert consensus, and data of cumulative incidence of recurrences over time [28], the proposals are the following [V, C]:

- baseline thoracic CT scan 3–4 months after surgery
- for completely resected stage I/II thymomas: CT scan every year for 5 years, then every 2 years
- for stage III/IV thymomas, thymic carcinoma or after R1–2 resection: CT scan every 6 months for 2 years, then annually
- continuation of follow-up for 10–15 years

Secondary tumours may occur. Besides oncological follow-up, clinicians should be aware of the possible late onset of new autoimmune disorders. Patients with clinical myasthenia gravis, or even isolated positive anti-acetyl choline receptor antibodies, should be informed and educated about the risks of myasthenic crisis in specific situations such as stress or the administration of certain drugs [V, A].

Participation in collaborative research initiatives, including regional and international databases, and clinical trials when available, is recommended.

methodology

These clinical practice guidelines were developed in accordance with the ESMO standard operating procedures for clinical practice guidelines development. The relevant literature has been selected by the expert authors, using the Medline database, as well as abstracts lists from major surgery, medical oncology and thoracic oncology meetings, over the past 20 years. A summary of recommendations is presented in Table 7. Levels of evidence and grades of recommendation have been applied using the system shown in Table 8 [89]. Statements without grading were considered justified standard clinical practice by the experts and the ESMO faculty. This manuscript has been subjected to an anonymous peer review process.

acknowledgements

The authors thank Benjamin Besse (Gustave Roussy, Villejuif, France) for reviewing the manuscript. NG thanks all investigators of the RYTHMIC network for their input on the French recommendations, which was valuable for the subsequent development of the present clinical practice guidelines.

conflict of interest

NG has reported consultancy from Amgen, Astra-Zeneca, Bristol-Myers Squibb, Boehringer Ingelheim, Eli-Lilly, Hoffmann-La Roche, Novartis, Pfizer, Teva. SP has provided consultancy, attended

Table 8. Levels of evidence and grades of recommendation (adapted from the Infectious Diseases Society of America–United States Public Health Service Grading System^a)

Levels of evidence	
I	Evidence from at least one large randomised, controlled trial of good methodological quality (low potential for bias) or meta-analyses of well-conducted randomised trials without heterogeneity
II	Small randomised trials or large randomised trials with a suspicion of bias (lower methodological quality) or meta-analyses of such trials or of trials with demonstrated heterogeneity
III	Prospective cohort studies
IV	Retrospective cohort studies or case–control studies
V	Studies without control group, case reports, experts opinions
Grades of recommendation	
A	Strong evidence for efficacy with a substantial clinical benefit, strongly recommended
B	Strong or moderate evidence for efficacy but with a limited clinical benefit, generally recommended
C	Insufficient evidence for efficacy or benefit does not outweigh the risk or the disadvantages (adverse events, costs, ...), optional
D	Moderate evidence against efficacy or for adverse outcome, generally not recommended
E	Strong evidence against efficacy or for adverse outcome, never recommended

^aBy permission of the Infectious Diseases Society of America [89].

advisory boards and/or provided lectures for: F. Hoffmann-La Roche, Eli-Lilly and Company Oncology, Astra-Zeneca, Pfizer, Boehringer Ingelheim, Bristol-Myers Squibb, Daiichi-Sankyo, Morphotek, Merrimack, Merck Serono, MSD, Amgen, Clovis, Astellas and Tesaro. The other authors have declared no potential conflicts of interest.

references

- de Jong WK, Blaauwgeers JL, Schaapveld M et al. Thymic epithelial tumours: a population-based study of the incidence, diagnostic procedures and therapy. *Eur J Cancer* 2008; 44: 123–130.
- Travis WB, Brambilla A, Muller-Hermelinck HK, Marx A. Pathology and genetics of tumours of the lung, pleura, thymus and heart. In: Travis WB (ed), World Health Organization Classification of Tumours. Lyon: IARC Press 2004; p. 146.
- Marx A, Ströbel P, Badve SS et al. ITMIG consensus statement on the use of the WHO histological classification of thymoma and thymic carcinoma: refined definitions, histological criteria, and reporting. *J Thorac Oncol* 2014; 9: 596–611.
- Kondo K, Monden Y. Therapy for thymic epithelial tumors: a clinical study of 1,320 patients from Japan. *Ann Thorac Surg* 2003; 76: 878–884.
- Weis CA, Yao X, Deng Y et al. The impact of thymoma histotype on prognosis in a worldwide database. *J Thorac Oncol* 2015; 10: 367–372.
- Ruffini E, Detterbeck F, Van Raemdonck D et al. Tumours of the thymus: a cohort study of prognostic factors from the European Society of Thoracic Surgeons database. *Eur J Cardiothorac Surg* 2014; 46: 361–368.
- Omasa M, Date H, Sozu T et al. Postoperative radiotherapy is effective for thymic carcinoma but not for thymoma in stage II and III thymic epithelial tumors: The Japanese Association for Research on the Thymus Database Study. *Cancer* 2015; 121: 1008–1016.
- Kojima Y, Ito H, Hasegawa S et al. Resected invasive thymoma with multiple endocrine neoplasia type 1. *Jpn J Thorac Cardiovasc Surg* 2006; 54: 171–173.
- Engels EA, Pfeiffer RM. Malignant thymoma in the United States: demographic patterns in incidence and associations with subsequent malignancies. *Int J Cancer* 2003; 105: 546–551.
- Seki S, Koyama H, Ohno Y et al. Diffusion-weighted MR imaging vs. multi-detector row CT: direct comparison of capability for assessment of management needs for anterior mediastinal solitary tumors. *Eur J Radiol* 2014; 83: 835–842.
- Evoli A, Lancaster E. Paraneoplastic disorders in thymoma patients. *J Thorac Oncol* 2014; 9(Suppl 2): S143–S147.
- Marx A, Hohenberger P, Hoffmann H et al. The autoimmune regulator AIRE in thymoma biology: autoimmunity and beyond. *J Thorac Oncol* 2010; 5(Suppl 4): S266–S272.
- Carter BW, Marom EM, Detterbeck FC. Approaching the patient with an anterior mediastinal mass: a guide for clinicians. *J Thorac Oncol* 2014; 9(Suppl 2): S102–S109.
- Falkson CB, Bezjak A, Darling G et al. The management of thymoma: a systematic review and practice guideline. *J Thorac Oncol* 2009; 4: 911–919.
- Girard N, Mornex F, Van Houtte P et al. Thymoma: a focus on current therapeutic management. *J Thorac Oncol* 2009; 4: 119–126.
- NCCN Clinical Practice Guidelines in Oncology. Thymic malignancies. V.1.2015. www.nccn.org (7 July 2015, date last accessed).
- Evans AG, French CA, Cameron MJ et al. Pathologic characteristics of NUT midline carcinoma arising in the mediastinum. *Am J Surg Pathol* 2012; 36: 1222–1227.
- Ackman JB, Verzosa S, Kovach AE et al. High rate of unnecessary thymectomy and its cause. Can computed tomography distinguish thymoma, lymphoma, thymic hyperplasia, and thymic cysts? *Eur J Radiol* 2015; 84: 524–533.
- Priola AM, Priola SM, Ciccone G et al. Differentiation of rebound and lymphoid thymic hyperplasia from anterior mediastinal tumors with dual-echo chemical-shift MR imaging in adulthood: reliability of the chemical-shift ratio and signal intensity index. *Radiology* 2015; 274: 238–249.
- Henschke CI, Lee IJ, Wu N et al. CT screening for lung cancer: prevalence and incidence of mediastinal masses. *Radiology* 2006; 239: 586–590.
- Kaira K, Endo M, Abe M et al. Biologic correlation of 2-[18F]-fluoro-2-deoxy-D-glucose uptake on positron emission tomography in thymic epithelial tumors. *J Clin Oncol* 2010; 28: 3746–3753.
- Marchevsky A, Marx A, Ströbel P et al. Policies and reporting guidelines for small biopsy specimens of mediastinal masses. *J Thorac Oncol* 2011; 6(Suppl 3): S1724–S1729.
- Wang H, Sima CS, Beasley MB et al. Classification of thymic epithelial neoplasms is still a challenge to thoracic pathologists: a reproducibility study using digital microscopy. *Arch Pathol Lab Med* 2014; 138: 658–663.
- den Bakker MA, Roden AC, Marx A, Marino M. Histologic classification of thymoma: a practical guide for routine cases. *J Thorac Oncol* 2014; 9(Suppl 2): S125–S130.
- Masaoka A, Monden Y, Nakahara K, Tanioka T. Follow-up study of thymomas with special reference to their clinical stages. *Cancer* 1981; 48: 2485–2492.
- Koga K, Matsuno Y, Noguchi M et al. A review of 79 thymomas: modification of staging system and reappraisal of conventional division into invasive and non-invasive thymoma. *Pathol Int* 1994; 44: 359–367.
- Detterbeck FC, Nicholson AG, Kondo K et al. The Masaoka-Koga stage classification for thymic malignancies: clarification and definition of terms. *J Thorac Oncol* 2011; 6(Suppl 3): S1710–S1716.
- Detterbeck F. Towards a TNM based prognostic classification for thymic tumours. *J Thorac Oncol* 2013; 8(Suppl 2): S68 (abst. MS16.2).
- Detterbeck F, Youssef S, Ruffini E, Okumura M. A review of prognostic factors in thymic malignancies. *J Thorac Oncol* 2011; 6(Suppl 3): S1698–S1704.
- Detterbeck FC, Stratton K, Giroux D et al. The IASLC/ITMIG Thymic Epithelial Tumors Staging Project: proposal for an evidence-based stage classification system for the forthcoming (8th) edition of the TNM classification of malignant tumors. *J Thorac Oncol* 2014; 9(Suppl 2): S65–S72.
- Marom EM, Milito MA, Moran CA et al. Computed tomography findings predicting invasiveness of thymoma. *J Thorac Oncol* 2011; 6: 1274–1281.
- Zhao Y, Chen H, Shi J et al. The correlation of morphological features of chest computed tomographic scans with clinical characteristics of thymoma. *Eur J Cardiothorac Surg* 2014 [Epub ahead of print].
- Korst RJ, Bezjak A, Blackmon S et al. Neoadjuvant chemoradiotherapy for locally advanced thymic tumors: a phase II, multi-institutional clinical trial. *J Thorac Cardiovasc Surg* 2014; 147: 36–44.
- Huang J, Detterbeck FC, Wang Z, Loehrer PJ, Sr. Standard outcome measures for thymic malignancies. *J Thorac Oncol* 2011; 6(Suppl 3): S1691–S1697.
- Davenport E, Malthaner RA. The role of surgery in the management of thymoma: a systematic review. *Ann Thorac Surg* 2008; 86: 673–684.
- Detterbeck FC, Moran C, Huang J et al. Which way is up? Policies and procedures for surgeons and pathologists regarding resection specimens of thymic malignancy. *J Thorac Oncol* 2011; 6(Suppl 3): S1730–S1738.
- Nakagawa K, Asamura H, Sakurai H et al. Does the mode of surgical resection affect the prognosis/recurrence in patients with thymoma? *J Surg Oncol* 2014; 109: 179–183.
- Yano M, Sasaki H, Moriyama S et al. Preservation of phrenic nerve involved by stage III thymoma. *Ann Thorac Surg* 2010; 89: 1612–1619.
- Hamdi S, Mercier O, Fadel E et al. Is sacrificing the phrenic nerve during thymoma resection worthwhile? *Eur J Cardiothorac Surg* 2014; 45: e151–e155.
- Toker A, Sonett J, Zielinski M et al. Standard terms, definitions, and policies for minimally invasive resection of thymoma. *J Thorac Oncol* 2011; 6(Suppl 3): S1739–S1742.
- Bhora FY, Chen DJ, Detterbeck FC et al. The ITMIG/IASLC Thymic Epithelial Tumors Staging Project: a Proposed Lymph Node Map for Thymic Epithelial Tumors in the Forthcoming 8th Edition of the TNM Classification of Malignant Tumors. *J Thorac Oncol* 2014; 9(Suppl 2): S88–S96.
- Forquer JA, Rong N, Fakiris AJ et al. Postoperative radiotherapy after surgical resection of thymoma: differing roles in localized and regional disease. *Int J Radiat Oncol Biol Phys* 2010; 76: 440–445.
- Patel S, Macdonald OK, Nagda S et al. Evaluation of the role of radiation therapy in the management of malignant thymoma. *Int J Radiat Oncol Biol Phys* 2012; 82: 1797–1801.
- Ahmad U, Yao X, Detterbeck F et al. Thymic carcinoma outcomes and prognosis: results of an international analysis. *J Thorac Cardiovasc Surg* 2015; 149: 95–100.

45. Ruffini E, Detterbeck F, Van Raemdonck D et al. Thymic carcinoma: a cohort study of patients from the European Society of Thoracic Surgeons Database. *J Thorac Oncol* 2014; 9: 541–548.
46. Korst RJ, Kansler AL, Christos PJ, Mandal S. Adjuvant radiotherapy for thymic epithelial tumors: a systematic review and meta-analysis. *Ann Thorac Surg* 2009; 87: 1641–1647.
47. Rimmer A, Gomez DR, Wu AJ et al. Failure patterns relative to radiation treatment fields for stage II-IV thymoma. *J Thorac Oncol* 2014; 9: 403–409.
48. Gomez D, Komaki R, Yu J et al. Radiation therapy definitions and reporting guidelines for thymic malignancies. *J Thorac Oncol* 2011; 6(Suppl 3): S1743–8.
49. Sugie C, Shibamoto Y, Ikeya-Hashizume C et al. Invasive thymoma: postoperative mediastinal irradiation, and low-dose entire hemithorax irradiation in patients with pleural dissemination. *J Thorac Oncol* 2008; 3: 75–81.
50. Zhang H, Lu N, Wang M et al. Postoperative radiotherapy for stage I thymoma: a prospective randomized trial in 29 cases. *Chin Med J (Engl)* 1999; 112: 136–138.
51. Gao L, Wang C, Fang W et al. Outcome of multimodality treatment for 188 cases of type B3 thymoma. *J Thorac Oncol* 2013; 8: 1329–1334.
52. Utsumi T, Shiono H, Kadota Y et al. Postoperative radiation therapy after complete resection of thymoma has little impact on survival. *Cancer* 2009; 115: 5413–5420.
53. Chen YD, Feng QF, Lu HZ et al. Role of adjuvant radiotherapy for stage II thymoma after complete tumor resection. *Int J Radiat Oncol Biol Phys* 2010; 78: 1400–1406.
54. Weksler B, Shende M, Nason KS et al. The role of adjuvant radiation therapy for resected stage III thymoma: a population-based study. *Ann Thorac Surg* 2012; 93: 1822–1828.
55. Attaran S, McCormack D, Pilling J, Harrison-Phipps K. Which stages of thymoma benefit from adjuvant chemotherapy post-thymectomy? *Interact Cardiovasc Thorac Surg* 2012; 15: 273–275.
56. Loehrer PJ, Sr, Chen M, Kim K et al. Cisplatin, doxorubicin, and cyclophosphamide plus thoracic radiation therapy for limited-stage unresectable thymoma: an intergroup trial. *J Clin Oncol* 1997; 15: 3093–3099.
57. Kim ES, Putnam JB, Komaki R et al. Phase II study of a multidisciplinary approach with induction chemotherapy, followed by surgical resection, radiation therapy, and consolidation chemotherapy for unresectable malignant thymomas: final report. *Lung Cancer* 2004; 44: 369–379.
58. Berruti A, Borasio P, Gerbino A et al. Primary chemotherapy with adriamycin, cisplatin, vincristine and cyclophosphamide in locally advanced thymomas: a single institution experience. *Br J Cancer* 1999; 81: 841–845.
59. Girard M, Lal R, Wakelee H et al. Chemotherapy definitions and policies for thymic malignancies. *J Thorac Oncol* 2011; 6(7 Suppl 3): S1749–S1755.
60. Girard N. Chemotherapy and targeted agents for thymic malignancies. *Expert Rev Anticancer Ther* 2012; 12: 685–695.
61. Wright CD, Choi NC, Wain JC et al. Induction chemoradiotherapy followed by resection for locally advanced Masaoka stage III and IVA thymic tumors. *Ann Thorac Surg* 2008; 85: 385–389.
62. Wright CD. Extended resections for thymic malignancies. *J Thorac Oncol* 2010; 5(10 Suppl 3): S344–S347.
63. Yellin A, Simansky DA, Ben-Avi R et al. Resection and heated pleural chemoperfusion in patients with thymic epithelial malignant disease and pleural spread: a single-institution experience. *J Thorac Cardiovasc Surg* 2013; 145: 83–87.
64. Wright CD. Pleuropneumectomy for the treatment of Masaoka stage IVA thymoma. *Ann Thorac Surg* 2006; 82: 1234–1239.
65. Hamaji M, Kojima F, Omasa M et al. A meta-analysis of debulking surgery versus surgical biopsy for unresectable thymoma. *Eur J Cardiothorac Surg* 2015; 47: 602–607.
66. Loehrer PJ, Sr, Kim K, Aisner SC et al. Cisplatin plus doxorubicin plus cyclophosphamide in metastatic or recurrent thymoma: final results of an intergroup trial. The Eastern Cooperative Oncology Group, Southwest Oncology Group, and Southeastern Cancer Study Group. *J Clin Oncol* 1994; 12: 1164–1168.
67. Giaccone G, Ardzizoni A, Kirkpatrick A et al. Cisplatin and etoposide combination chemotherapy for locally advanced or metastatic thymoma. A phase II study of the European Organization for Research and Treatment of Cancer Lung Cancer Cooperative Group. *J Clin Oncol* 1996; 14: 814–820.
68. Loehrer PJ, Sr, Jiroutek M, Aisner S et al. Combined etoposide, ifosfamide, and cisplatin in the treatment of patients with advanced thymoma and thymic carcinoma: an intergroup trial. *Cancer* 2001; 91: 2010–2015.
69. Lemma GL, Lee JW, Aisner SC et al. Phase II study of carboplatin and paclitaxel in advanced thymoma and thymic carcinoma. *J Clin Oncol* 2011; 29: 2060–2065.
70. Palmieri G, Merola G, Federico P et al. Preliminary results of phase II study of capecitabine and gemcitabine (CAP-GEM) in patients with metastatic pretreated thymic epithelial tumors (TETs). *Ann Oncol* 2010; 21: 1168–1172.
71. Hirai F, Yamanaka T, Taguchi K et al. A multicenter phase II study of carboplatin and paclitaxel for advanced thymic carcinoma: WJOG4207L. *Ann Oncol* 2015; 26: 363–368.
72. Okuma Y, Saito M, Hosomi Y et al. Key components of chemotherapy for thymic malignancies: a systematic review and pooled analysis for anthracycline-, carboplatin- or cisplatin-based chemotherapy. *J Cancer Res Clin Oncol* 2015; 141: 323–331.
73. Benveniste MF, Korst RJ, Rajan A et al. A practical guide from the International Thymic Malignancy Interest Group (ITMIG) regarding the radiographic assessment of treatment response of thymic epithelial tumors using modified RECIST criteria. *J Thorac Oncol* 2014; 9: S119–S124.
74. Sandri A, Cusumano G, Lococo F et al. Long-term results after treatment for recurrent thymoma: a multicenter analysis. *J Thorac Oncol* 2014; 9: 1796–1804.
75. Hamaji M, Allen MS, Cassivi SD et al. The role of surgical management in recurrent thymic tumors. *Ann Thorac Surg* 2012; 94: 247–254.
76. Mizuno T, Okumura M, Asamura H et al. Surgical management of recurrent thymic epithelial tumors: a retrospective analysis based on the Japanese nationwide database. *J Thorac Oncol* 2015; 10: 199–205.
77. Lara PN, Jr, Bonomi PD, Faber LP. Retreatment of recurrent invasive thymoma with platinum, doxorubicin, and cyclophosphamide. *Chest* 1996; 110: 1115–1117.
78. Loehrer PJ, Yiannoutsos CT, Dropcho S et al. A phase II trial of pemetrexed in patients with recurrent thymoma or thymic carcinoma. *J Clin Oncol* 2006; 24(Suppl 18): abstr 7079.
79. Loehrer PJ, Sr, Wang W, Johnson DH et al. Octreotide alone or with prednisone in patients with advanced thymoma and thymic carcinoma: an Eastern Cooperative Oncology Group Phase II Trial. *J Clin Oncol* 2004; 22: 293–299.
80. Palmieri G, Montella L, Martignetti A et al. Somatostatin analogs and prednisone in advanced refractory thymic tumors. *Cancer* 2002; 94: 1414–1420.
81. Rajan A, Girard N, Marx A. State of the art of genetic alterations in thymic epithelial tumors. *J Thorac Oncol* 2014; 9(Suppl 2): S131–S136.
82. Thomas A, Rajan A, Berman A et al. Sunitinib in patients with chemotherapy-refractory thymoma and thymic carcinoma: an open-label phase 2 trial. *Lancet Oncol* 2015; 16: 177–186.
83. Giaccone G, Rajan A, Ruijter R et al. Imatinib mesylate in patients with WHO B3 thymomas and thymic carcinomas. *J Thorac Oncol* 2009; 4: 1270–1273.
84. Salter JT, Lewis D, Yiannoutsos C et al. Imatinib for the treatment of thymic carcinoma. *J Clin Oncol* 2008; 26(15s suppl): abstr 8116.
85. Ströbel P, Bargou R, Wolf A et al. Sunitinib in metastatic thymic carcinomas: laboratory findings and initial clinical experience. *Br J Cancer* 2010; 103: 196–200.
86. Lattanzio R, La Sorda R, Facciolo F et al. Thymic epithelial tumors express vascular endothelial growth factors and their receptors as potential targets of antiangiogenic therapy: a tissue micro array-based multicenter study. *Lung Cancer* 2014; 85: 191–196.
87. Wheler J, Hong D, Swisher SG et al. Thymoma patients treated in a phase I clinic at MD Anderson Cancer Center: responses to mTOR inhibitors and molecular analyses. *Oncotarget* 2013; 4: 890–898.
88. Zucali PA, De Pas TM, Palmieri G et al. Phase II study of everolimus in patients with thymoma and thymic carcinoma previously treated with cisplatin-based chemotherapy. *J Clin Oncol* 2014; 32 (5s suppl): abstr 7527.
89. Dykewicz CA. Summary of the guidelines for preventing opportunistic infections among hematopoietic stem cell transplant recipients. *Clin Infect Dis* 2001; 33: 139–144.