

PDF hosted at the Radboud Repository of the Radboud University Nijmegen

The following full text is a publisher's version.

For additional information about this publication click this link.

<http://hdl.handle.net/2066/174790>

Please be advised that this information was generated on 2017-12-05 and may be subject to change.



Case Report

Adjuvant interferon-gamma immunotherapy in a patient with progressive cerebral Nocardia abscesses



Jenneke Leentjens^{a,b}, Mark S. Gresnigt^a, Frank L. van de Veerdonk^a, Matthijs Kox^b, Bart Jan Kullberg^a, Peter Pickkers^b, Annemarie E. Brouwer^c, Mihai G. Netea^{a,*}

^a Department of Internal Medicine, Radboud university medical center, Radboud Institute for Molecular Life Sciences (RILMS), Nijmegen, the Netherlands

^b Department of Intensive Care Medicine, Radboud university medical center, Radboud Institute for Molecular Life Sciences (RILMS), Nijmegen, the Netherlands

^c Department of Internal Medicine, Elisabeth Hospital, Tilburg, the Netherlands

ARTICLE INFO

Article history:

Received 28 November 2016

Received in revised form 16 March 2017

Accepted 16 March 2017

Corresponding Editor: Eskild Petersen, Aarhus, Denmark

Keywords:

Nocardiosis

Nocardia

Cerebral abscess

IFN-gamma

Immunotherapy

SUMMARY

Despite advances in medical care, mortality due to cerebral Nocardia abscesses remains unacceptably high. The case of a typical immunocompromised patient, who deteriorated clinically despite optimal antimicrobial treatment, is reported here. Adjuvant immunotherapy with interferon-gamma resulted in partial restoration of the immune response and a corresponding clinical and radiographic recovery.

© 2017 The Authors. Published by Elsevier Ltd on behalf of International Society for Infectious Diseases. This is an open access article under the CC BY-NC-ND license (<http://creativecommons.org/licenses/by-nc-nd/4.0/>).

Introduction

Nocardiosis is a rare Gram-positive bacterial infection caused by aerobic actinomycetes of the genus *Nocardia*. *Nocardia* species can cause both localized and disseminated infection (Wilson, 2012). Mortality rates of up to 66% have been reported in patients with multiple lesions (Lee et al., 2002). Because nocardiosis is most commonly observed in individuals with immune defects (Wilson, 2012), adjunctive immunotherapy is a potentially attractive strategy to improve host defence and the outcome of patients with disseminated nocardiosis. Interferon-gamma (IFN- γ), a well-known immunostimulatory cytokine (Leentjens et al., 2013), has shown promising results in the adjunctive treatment of other opportunistic infections (Delsing et al., 2014). Therefore, IFN- γ represents a promising candidate to improve the outcome of invasive Nocardia infections. However, to date, no reports of adjunctive treatment with IFN- γ for patients with Nocardia infections have been reported.

Case report

A 50-year-old male patient with multiple Nocardia cerebral abscesses was referred to the university hospital because of clinical deterioration despite adequate antimicrobial treatment. The patient had been treated with high-dose corticosteroids over the past 6 months for an unidentified interstitial pneumonitis. Two months prior to admission to the university hospital, two cerebral abscesses had been found on cerebral magnetic resonance imaging (MRI). The largest lesion is depicted in Figure 1A. Stereotactic cultures revealed *Nocardia asteroides* (confirmed by 16S RNA analysis: a 100% match with *N. asteroides*). Initial treatment consisted of cefotaxime, ceftazidime, and metronidazole intravenously, which was changed to high-dose trimethoprim-sulfamethoxazole (TMP-SMX, 1920 mg three times daily, intravenously) as soon as culture results became available. Additional susceptibility testing revealed the strain to be susceptible to the prescribed antibiotics. In addition, meropenem treatment was added at day 47 of admission after urine cultures became positive for multi-resistant *Escherichia coli*. Despite this treatment, the patient's clinical condition deteriorated due to exudation of the left abscess into the left ventricle. In addition, after an initial decrease in size (Figure 1B), subsequent sequential

* Corresponding author at: Department of Internal Medicine (463), Radboud University Nijmegen Medical Center, PO Box 9101, 6500 HB Nijmegen, the Netherlands. Tel.: +31 24 3618819. Fax: +31 24 3541734.

E-mail address: mihai.netea@radboudumc.nl (M.G. Netea).

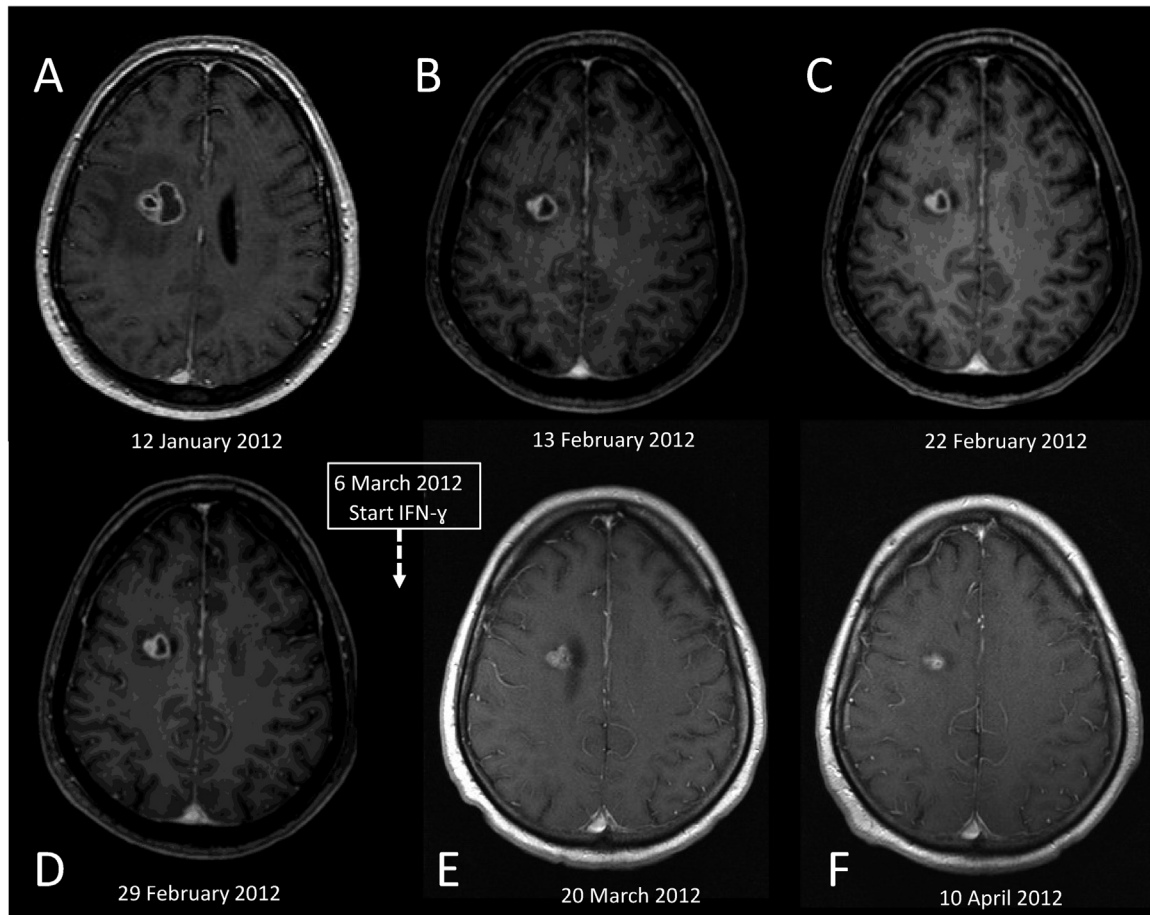


Figure 1. Studies of the largest right paraventricular brain lesion by magnetic resonance imaging (MRI). (A) T1-weighted contrast-enhanced hyperintense MRI image of the right brain lesion at admission on January 12, 2012 (size of lesion $25 \times 22 \times 20$ mm, with extensive surrounding oedema). (B) Culture-guided initial treatment with trimethoprim–sulfamethoxazole resulted in an initial decrease in size and reduction of the oedema (size of lesion $17 \times 15 \times 17$ mm). However, subsequent imaging showed little to no further reduction of the abscess: (C) size of lesion $15 \times 13 \times 19$ mm, (D) size of lesion: $16 \times 13 \times 19$ mm. Therefore, adjunctive immunotherapy with interferon-gamma treatment was initiated on March 6. (E) MRI performed 12 days later showed a decrease in the right paraventricular lesion (size of lesion $12 \times 13 \times 17$ mm). (F) Further improvements were observed on MRI 3 weeks later (size of lesion $12 \times 9 \times 12$ mm). All images are published with the permission of the patient's legal representative.

MRI scans showed no further reduction in size of the lesions and surrounding oedema (Figure 1C, D).

It was considered that the patient would benefit from adjunctive immunotherapy as ‘therapy of last resort’. Therefore, IFN- γ (Boehringer-Ingelheim, Arnhem, the Netherlands) treatment was initiated on day 55 of admission ($50 \mu\text{g}/\text{m}^2$ subcutaneously, three times weekly). Furthermore, 2 days after the initiation of IFN- γ therapy, ceftriaxone was started alongside TMP–SMX and meropenem because of persistent fever. Four days later, meropenem was stopped, as no clear effects on the clinical course were noted despite treatment for 14 days. Compared with the MRI performed 1 week before the initiation of IFN- γ treatment, the MRI performed 14 days later showed a decrease in the right paraventricular lesion (Figure 1E). The fever disappeared 12 days after the initiation of IFN- γ treatment. However, despite combination antimicrobial therapy (TMP–SMX and ceftriaxone), resolution of the fever, and signs of improvement on radiography, the cerebrospinal fluid (CSF) remained purulent and hence intrathecal amikacin was added. Within 2 weeks, the patient's headache had subsided and the CSF became normal; amikacin could be discontinued. One week later, only trunk balance impairment and vertigo with a tendency to fall remained. The patient's condition improved further, and 3.5 months after the initiation of IFN- γ treatment he was discharged. He was able to walk at this time. MRI showed further improvement (Figure 1F). He was

discharged on TMP–SMX and IFN- γ treatment, which were well tolerated.

Unfortunately, 4 days after discharge the patient was readmitted because of free subdiaphragmatic air with pneumatosis intestinalis, a rare complication of high-dose corticosteroid administration. Abdominal surgery showed no additional cause for the free air. He died 17 days later due to cardiovascular problems that were not directly related to the *Nocardia* infection, which was confirmed on autopsy.

Immunological analysis

Although the patient had been treated with corticosteroids, his personal and family histories were negative for immune deficiencies. Additional testing revealed a CD4 lymphopenia ($140 \text{ cells}/\text{mm}^3$) in the absence of HIV infection. This may have been related to the steroid treatment, but a primary cause cannot be excluded. Additional blood was collected to analyze immune responses before and during IFN- γ treatment (see **Supplementary Material** online for methods of blood sampling and cytokine assays). Before IFN- γ treatment, the capacity of peripheral blood mononuclear cells (PBMCs) to produce cytokines upon ex vivo stimulation with *Candida albicans*, lipopolysaccharide (LPS), and phytohaemagglutinin (PHA) was severely blunted (Figure 2A–F). IFN- γ treatment was associated with an increased production of

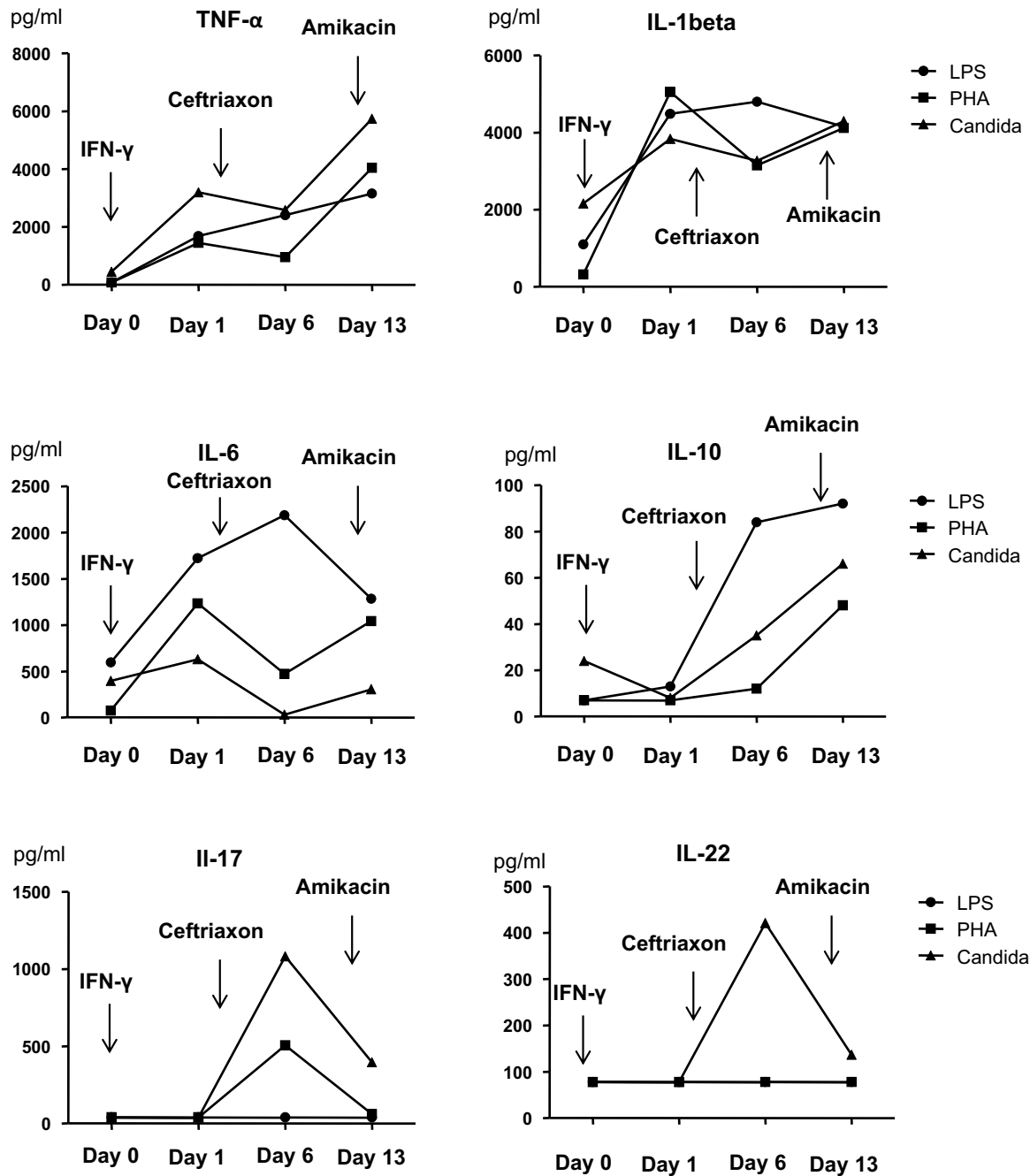


Figure 2. Cytokine production by peripheral blood mononuclear cells stimulated ex vivo with different agents before and during interferon-gamma treatment. IL, interleukin; TNF, tumor necrosis factor; LPS, lipopolysaccharide; PHA, phytohaemagglutinin; IFN, interferon.

interleukin (IL)-1 β , tumour necrosis factor alpha (TNF- α), IL-6, and IL-10 by PBMCs stimulated with all three agents (Figure 2A–D). *C. albicans*-induced ex vivo production of the T-helper 17 (Th17) cytokines IL-17 and IL-22 was also increased, although to a lesser extent (Figure 2E, F).

Discussion

This case report describes how adjunctive immunotherapy with IFN- γ resulted in augmentation of the innate immune response in a patient with progressive Nocardia abscesses, which likely contributed to his clinical recovery.

Patients with impaired cell-mediated immunity (including hematopoietic stem cell transplant patients and patients

receiving long-term treatment with steroids) are at particularly high risk of developing opportunistic infections, including nocardiosis (Wilson, 2012). Immunotherapy to improve cell-mediated immunity is therefore a promising therapy to improve the outcomes of these patients. It has been demonstrated previously that IFN- γ has favourable effects on the outcomes of sepsis patients who exhibit clear signs of suppression of cellular immune responses, which renders them more vulnerable to opportunistic infections (Leentjens et al., 2013). In addition, IFN- γ was found to restore the suppressed cytokine production in vivo in humans in an experimental sepsis model (Leentjens et al., 2013), and in patients with severe invasive fungal infections (Delsing et al., 2014). In the present study, it was demonstrated that IFN- γ improved cellular immune responses in a patient with

cerebral nocardiosis, and this correlated with an improvement in the clinical outcome.

Taking into account all available human data, consisting of data from retrospective studies and small case series, the most appropriate therapeutic agent and treatment duration for Nocardia infections remain to be established. In patients with central nervous system (CNS) involvement, treatment options include antimicrobial therapy alone, or antimicrobial therapy in combination with freehand or stereotactic aspiration, or craniotomy plus enucleation.

With different *Nocardia spp* having different resistance profiles, species identification is crucial to determine the most suitable antibiotic treatment (Brown-Elliott et al., 2006). In the case of CNS involvement, therapy should obviously include drugs with favourable penetration into the CNS (e.g., TMP–SMX and ceftriaxone). In the patient presented here, meropenem instead of ceftriaxone was started alongside TMP–SMX because of the additional presence of multi-resistant *E. coli* in urine cultures. Meropenem is also active against most *Nocardia spp* and can cross the blood–brain barrier.

Despite appropriate combination therapy against *Nocardia spp*, the patient's condition deteriorated. The compromised status of the immune response reflected by the impaired ex vivo cytokine responses may, at least in part, explain his deterioration, and may also be responsible for the high mortality among patients with nocardiosis. Thus, the patient's immunocompromised status may have represented an important compromising factor, which was improved by IFN- γ treatment. However, in the current case, the purulent ventricular involvement could also account for the lack of clinical recovery, and the intraventricular administration of amikacin was probably also an important contributing factor in the patient's clinical recovery. Unfortunately, 3 weeks after the patient recovered and was discharged, he died of complications of end-stage interstitial pneumonitis not related to Nocardia infection.

In conclusion, for the optimal antimicrobial treatment of patients with nocardiosis, the treatment should be individualized according to the species identification, resistance profile, and CNS penetration capacity of the antimicrobial agent for use. In patients with intracerebral Nocardia abscesses who deteriorate despite optimal antimicrobial treatment, the use of immunotherapy with IFN- γ as adjuvant salvage therapy could be considered.

Funding

This research was performed within the framework of CTMM, the Center for Translational Molecular Medicine (<http://www.ctmm.nl>), project MARS (grant 04I-201). M.G.N. was supported by a Vici grant from the Netherlands Organization for Scientific Research. F.L.vdV. was supported by a Veni grant from the Netherlands Organization for Scientific Research. Support for the immunological assessments in this case report was provided by an unrestricted grant from bioMérieux.

Conflict of interest

On behalf of all authors, the corresponding author states that there is no conflict of interest regarding this case report.

Acknowledgements

The authors thank Bram Geurts of the Department of Radiology for his help with the interpretation of the MRI images.

Appendix A. Supplementary data

Supplementary data associated with this article can be found, in the online version, at <http://dx.doi.org/10.1016/j.ijid.2017.03.013>.

References

- Brown-Elliott BA, Brown JM, Conville PS, Wallace Jr. RJ. Clinical and laboratory features of the *Nocardia spp.* based on current molecular taxonomy. *Clinical microbiology reviews* 2006;19:259–82.
- Delsing CE, Gresnigt MS, Leentjens J, Preijers F, Frager FA, Kox M. Interferon-gamma as adjunctive immunotherapy for invasive fungal infections: a case series. *BMC infectious diseases* 2014;14:166.
- Lee GY, Daniel RT, Brophy BP, Reilly PL. Surgical treatment of nocardial brain abscesses. *Neurosurgery* 2002;51:668–71 discussion 71–2.
- Leentjens J, Kox M, van der Hoeven JG, Netea MG, Pickkers P. Immunotherapy for the adjunctive treatment of sepsis: from immunosuppression to immunostimulation. Time for a paradigm change?. *American journal of respiratory and critical care medicine* 2013;187:1287–93.
- Wilson JW. Nocardiosis: updates and clinical overview. *Mayo Clinic proceedings Mayo Clinic* 2012;87:403–7.