

Analysis of the Postoperative Displacement of Trochanteric Fractures on Lateral View Radiographs

Atsuo Furui* and Nobuki Terada

Department of Orthopaedic Surgery, Fujita Health University, Banbuntane Houtokukai Hospital, Nagoya 454-8509, Japan

Achieving sufficient support of the anterior cortex of the femoral neck is a fundamental goal of the reduction of trochanteric fractures. However, anterior-cortex support is often lost after the fracture reduction. Our aim was to analyze factors contributing to the postoperative displacement of an acceptably reduced trochanteric fracture. The cases of 40 patients with a post-reduction Ikuta subtype N fracture alignment were reviewed. All fractures were fixed with 135° free-sliding plates. On postoperative day 14, patients were classified into two groups: those with retention of the Ikuta subtype N alignment, and those with progression to Ikuta subtype P alignment. The clinical and radiological factors were evaluated between the groups. In addition, to define one of the factors, *i.e.*, the postoperative rotational displacement between the proximal and distal fragments, the relationship between radiographic findings and computed tomography image measurements was assessed in 15 of the 40 patients. Angulation at the fracture site on lateral view radiographs was defined as postoperative rotational displacement, and unstable trochanteric fractures and postoperative rotational displacement were identified as significant risk factors for the postoperative displacement. Therefore, cautious and careful follow-up is warranted for patients with unstable trochanteric fractures or fractures having rotational displacement.

Key words: trochanteric fracture, sliding hip screw, subtype, rotational displacement, iliofemoral ligament

A fundamental goal of the reduction of trochanteric fractures is to provide sufficient support to the cortex of the anterior femoral neck by aligning it with the anterior cortex of the diaphysis of the femur (*i.e.*, a subtype A or subtype N alignment on Ikuta's classification of fractures) [1,2]. Reduction to an Ikuta subtype A alignment is preferable, as it provides sufficient support to the anterior femoral neck cortex. Reduction to an Ikuta subtype N alignment is the most commonly encountered treatment and is considered clinically acceptable, but it is also a cause of rotational displacement of the fracture fragments, with a consequent loss of support to the anterior cortex of the femoral neck after reduction (*i.e.*, a subtype P alignment on

Ikuta's classification of fractures) [2,3]; Ikuta's classification of subtype fracture alignments is shown in Fig. 1. The aim of our study was to investigate patient- and fracture-related parameters that could influence the post-reduction displacement of trochanteric fractures, defined as progression from an Ikuta subtype N alignment to a subtype P alignment, during the postoperative period (Fig. 2). Specifically, the effects of age, sex, type of fracture, the positional relationship between the anterior fracture line and the compartment of the iliofemoral ligament (IFL) adherent to the femur, the postoperative rotational displacement between the proximal and distal fragments of the fracture, the postoperative placement of the tip of the lag screw in the femoral head, and the tip-apex distance (TAD) [4] on

Received November 7, 2016; accepted February 16, 2017.

*Corresponding author. Phone: +81-90-6614-7376; Fax: +81-52-332-8634
E-mail: nutsuro_ninja@yahoo.co.jp (A. Furui)

Conflict of Interest Disclosures: No potential conflict of interest relevant to this article was reported.

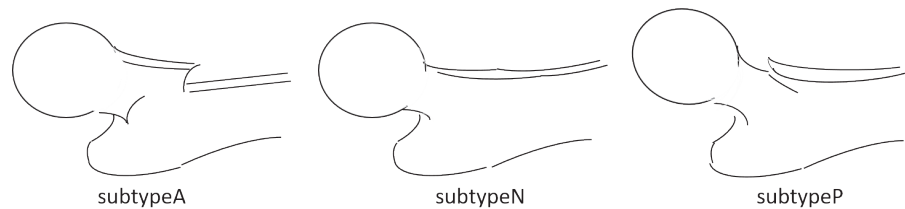


Fig. 1 Ikuta's classification [2] showing: subtype A alignment of the fracture fragments, with the anterior cortex of the femoral neck positioned anteriorly to the anterior cortex of the distal fragment; subtype N alignment, with continuous alignment between the anterior cortex of the femoral neck and the distal fragment; and subtype P alignment, with the anterior cortex of the femoral neck positioned posteriorly to the anterior cortex of the distal fragment.

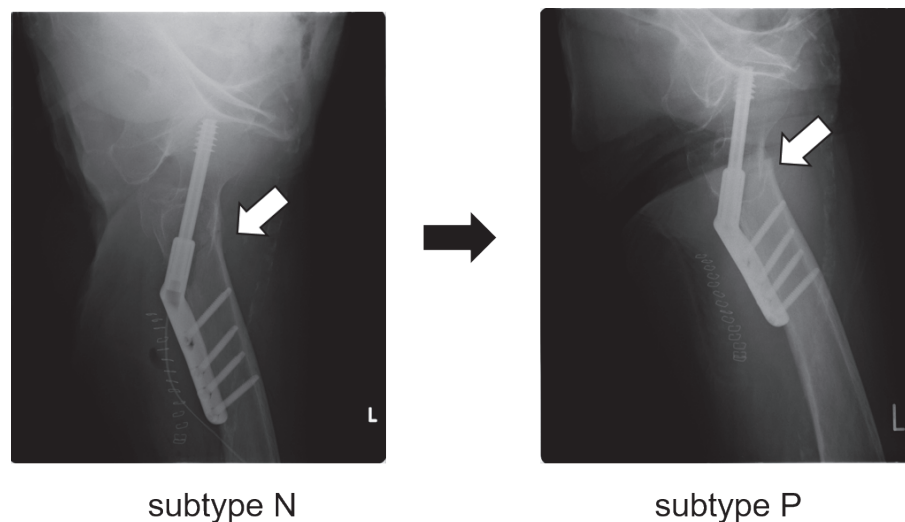


Fig. 2 Postoperative displacement of a reduced trochanteric fracture. The left-hand diagram shows the postoperative lateral view radiograph, confirming reduction to an Ikuta subtype N alignment. The solid white arrow indicates the continuous anterior cortex. The right-hand diagram shows a lateral view radiograph, obtained on postoperative day 14, confirming the postoperative displacement to an Ikuta subtype P alignment. The solid white arrow indicates the anterior femoral neck cortex positioned posteriorly to the anterior cortex of the distal fragment.

post-reduction displacement were evaluated. In addition, to define the postoperative rotational displacement of the fracture fragments by radiographic findings, the relationship between computed tomography image (CT) measurements and the angulation at the fracture site on lateral view radiographs was assessed.

Materials and Methods

Chart review

1. Study 1. The study was approved by the ethics committee of Fujita Health University (HM16-213, HM15-268), and written informed consent for study publication was obtained from all patients. Of the 75

trochanteric fractures treated at our hospital between May 2015 and October 2016, a clinically acceptable reduction, defined by confirmation of an Ikuta subtype N alignment on postoperative lateral view radiographs, was identified in 40 cases. The clinical and radiographic data from these 40 cases were used for the analysis. The study group included 10 males and 30 females, with a mean age at the time of surgery of 80.7 years (range, 41-97 years). All fractures were fixed using free-sliding plates, with the neck of the femur placed at an angle of 135° (Advanced Hip Screw: AHS, Meira Corporation, Seki, Gifu, Japan). Full weight-bearing was initiated soon after the surgery.

2. Study 2. Among the 40 cases described above,

15 cases treated between May 2015 and October 2015 were used for the assessment of postoperative rotational displacement between the proximal and distal fragments using postoperative CT scan.

Operative technique. Surgery was performed under C-arm fluoroscopy on a standard traction table, with patients in a supine position. Routine closed reduction maneuvers, including abduction, traction and internal rotation, were performed to achieve fracture alignment, which was confirmed by fluoroscopy. Direct reduction maneuvers, via an elevator, were only performed for cases with a preoperative Ikuta subtype P alignment (Fig. 3). In brief, we were not necessarily particular about achieving a reduction to Ikuta subtype A alignment; cases with an Ikuta subtype N alignment were considered acceptable. As a result, 10 patients (13%) were reduced to an Ikuta subtype A alignment, 40 cases (53%) were reduced to an Ikuta subtype N alignment, and 25 cases (33%) were reduced to an Ikuta subtype P alignment.

Radiographic assessment.

1. Study 1. Based on lateral view radiographs obtained on postoperative day 14, the patients in our study group were classified into 2 groups: group A, formed of all patients in whom an Ikuta subtype N fracture alignment was retained postoperatively; and group B, formed of all patients in whom fracture alignment progressed from a subtype N to a subtype P during the postoperative period.

The type of fracture was defined using Jensen's classification [5] of trochanteric fractures and evaluated from preoperative radiographs or CT scans (Fig. 4A). According to Jensen's classification, type I and II fractures are stable, and type III, IV and V fractures are unstable. We also classified the position of the anterior

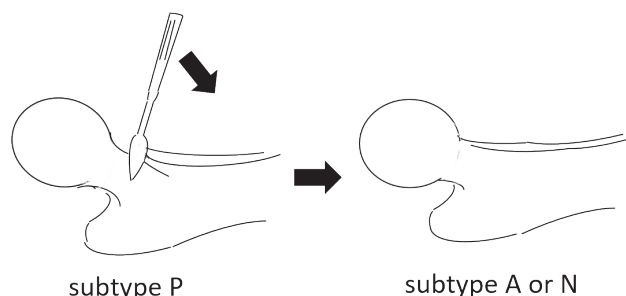


Fig. 3 Schematic of a direct reduction to provide sufficient support to the anterior femoral neck cortex, including elevation of the proximal fragment via an elevator.

fracture line as being either “proximal” or “distal” to the compartment of the IFL adherent to the femur from anterior-posterior views of preoperative radiographs or CT scans. The IFL is the strongest ligament in the hip joint, and it has a flabellate attachment above the intertrochanteric line [6]. Localized disruption in the cortex of the bone outside of the intertrochanteric line was considered to be part of the adherent component of the IFL (Fig. 4B). Placement of the tip of the lag screw in the femoral head was determined from postoperative radiographs by subdividing the head of the femur into six areas: the superior and inferior areas (S and I, respectively), which were evaluated on anterior-posterior radiographs, and the anterior, middle and posterior areas (A, M and P, respectively), which were evaluated on lateral radiographs (Fig. 4C). TAD was the sum of the distance from the tip of the lag screw to the apex of the femoral head on postoperative anterior-posterior and lateral radiographs [4] (Fig. 4D). Angulation at the fracture site on postoperative lateral view radiographs was defined as postoperative rotational displacement between the proximal and distal fragments of the fracture (Fig. 4E). However, the cases in which fracture site angulation was easily reduced by pressure from the anterior direction were excluded from the designation of postoperative rotational displacement.

2. Study 2. To assess rotational displacement between the proximal and distal fragments accurately, CT has been proven to be the most reliable method [7]. We utilized the CT-based method described by Jeanmart *et al.* [8] (Fig. 5). The difference in torsion angle between the injured and uninjured side determines any rotational displacement. Cases with a difference in torsion angle of 15° or more have been considered to have true rotational displacement [9]; however, many studies on rotational displacement have focused on femoral shaft and distal fractures, and there have been few studies on rotational displacement in trochanteric fractures [10]. We defined cases with a difference in torsion angle of 20° or more as cases of rotational displacement. Fifteen cases were classified into 2 groups: cases with angulation at the fracture site on postoperative lateral view radiographs, and cases without angulation on postoperative lateral view radiographs; postoperative CT measurement was performed in both groups.

Statistical analysis. Patient- and fracture-specific

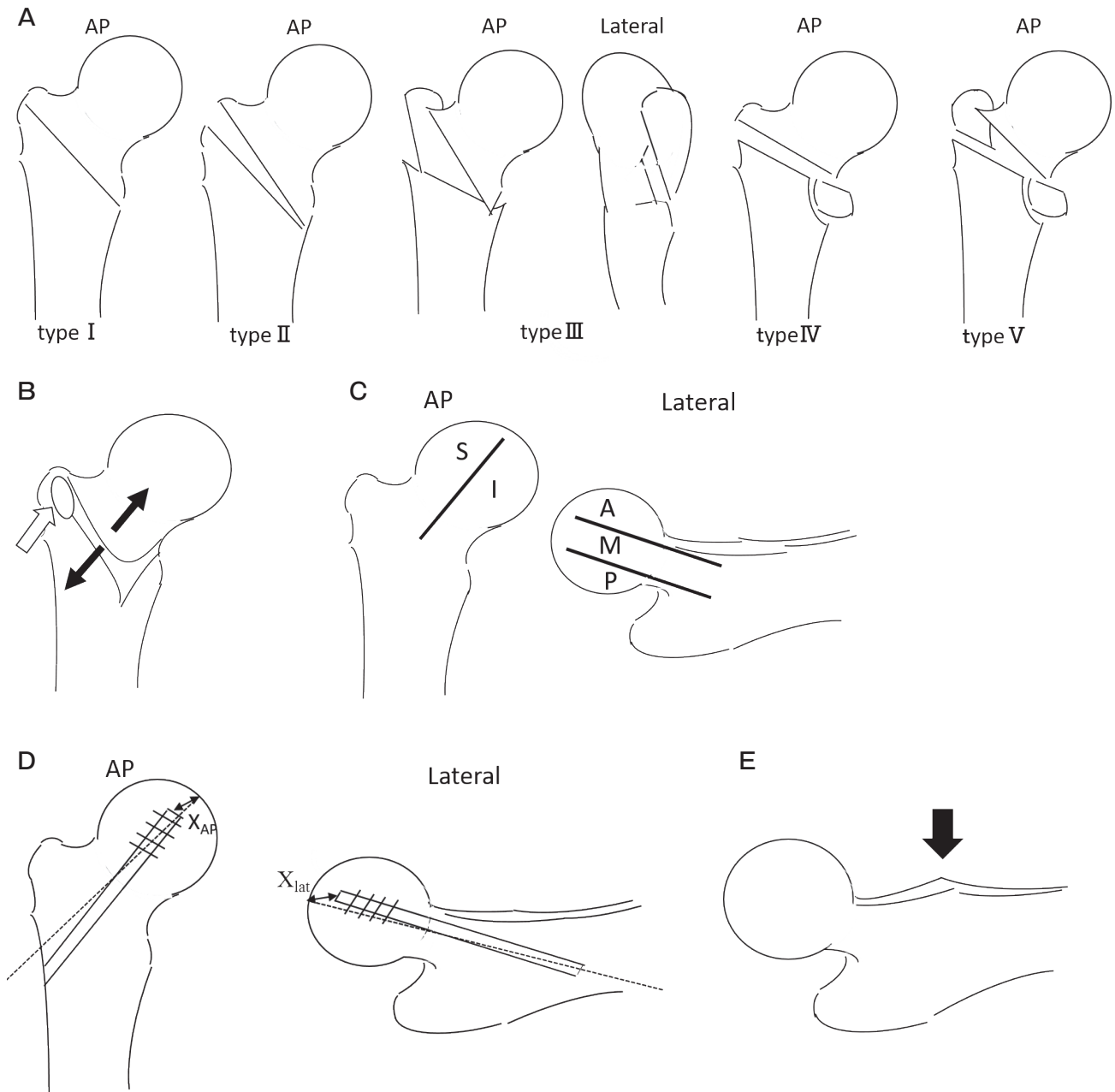


Fig. 4 (A) Jensen's classification [5] of trochanteric fractures: type I, undisplaced 2-fragment fracture; type II, displaced 2-fragment fracture; type III, 3-fragment fracture without posterolateral support; type IV, 3-fragment fracture without medial support; and type V, 4-fragment fracture without posterolateral and medial support. (B) Anterior-posterior view of the positional relationship between the anterior fracture line and the compartment of the iliofemoral ligament adherent to the femur. The ligament has a flabellate attachment above the intertrochanteric line. The solid white arrow indicates a local disruption in the cortex of the bone, which is considered to be part of the adherent component of the iliofemoral ligament. Patients were classified into two groups based on the position of the anterior fracture line (black arrows). (C) Different positions of the tip of the lag screw in the femoral head: S, superior area; I, inferior area; A, anterior area; M, middle area; and P, posterior area. (D) The tip-apex distance [4] is the sum of X_{AP} and X_{lat} . (E) Lateral view radiograph, with the black arrow indicating the angulation at the fracture site resulting from rotational displacement between the proximal and the distal fracture fragments.

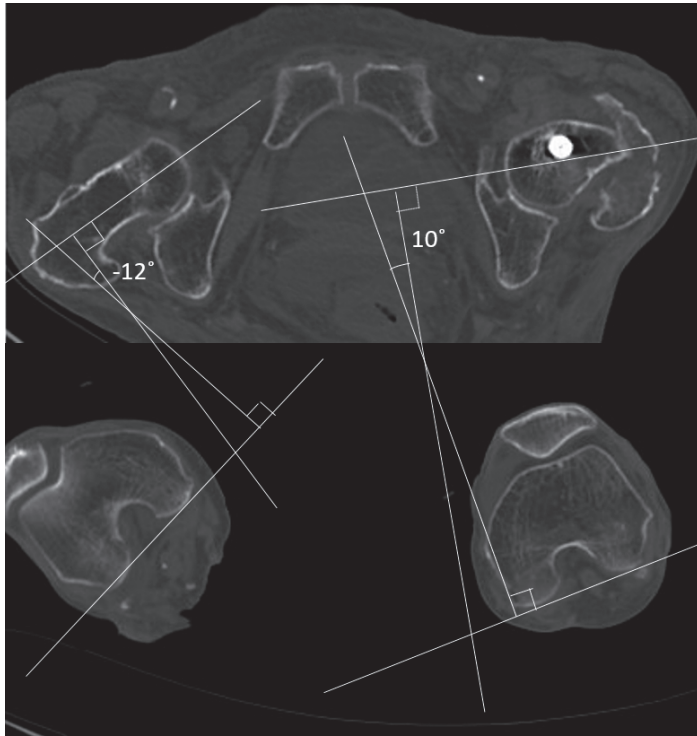


Fig. 5 Determination of rotational displacement using CT-torsion measurement according to Jeanmart *et al.* [17]. On the injured left side there is an increase of 22° (10°, 12°) in the rotation angle. This denotes an internal displacement of 22°.

parameters were evaluated between groups: age, sex, type of fracture, the positional relationship between the anterior fracture line and the compartment of the IFL adherent to the femur, the postoperative rotational displacement between the proximal and distal fragments of the fracture, the postoperative placement of the tip of the lag screw in the femoral head, and the TAD.

Between-group comparisons of age and TAD were performed using the nonparametric Mann–Whitney U test, since the hypothesis of normal distribution was rejected throughout the Kolmogorov–Smirnov test. The Fisher’s exact probability test was used for between-group comparisons of sex, type of fractures (stable or unstable), the proximal or distal position of the anterior fracture line relative to the adherent compartment of the IFL, the postoperative rotational displacement between the proximal fragment and the distal fragment, and the placement of the screw tip in the femoral head. Multivariate analysis was performed for the 2 groups using logistic regression. The proximal or distal position of the anterior fracture line relative to the adherent compartment of the IFL and the postoperative rotational displacement between the proximal and distal fracture fragments were entered as explanatory factors in the regression model. Statistical analyses were per-

formed using the bell curve application of the Excel software package, version 2.0.2 (Social Survey Research Information Co., Ltd., Tokyo, Japan). A p -value < 0.05 was used as the criterion of significance for all parameters.

Results

Study 1. Among the 40 patients forming our study group, 28 were classified into group A and 12 into group B. Relevant patient- and fracture-specific characteristics for the 2 groups are summarized in Table 1. The distribution of fractures was as follows. Group A included type I (N=4), type II (N=5), type III (N=14), type IV (N=2), and type V (N=3) fractures, with 19 fractures classified as unstable (types III, IV and V). Group B included type III (N=10) and type V (N=2) fractures, with all fractures classified as unstable. Therefore, the prevalence of unstable fracture types was significantly higher in group B than in group A ($p=0.038$). Although the anterior fracture line was localized distal to the adherent compartment of the IFL in 28% more cases in group B than in group A, this between-group difference was not significant ($p=0.152$). Optimal placement of the tip of the lag screw in the I-M

area of the femoral head was confirmed in 90% of cases, with no between-group difference ($p > 0.99$). Similarly, no significant difference in mean TAD was seen between the 2 groups ($p = 0.734$). There was a significant between-group difference in the prevalence of postoperative rotational displacement between the proximal and distal fracture fragments ($p = 0.001$), with rotational displacement identified in 7% of cases in group A and 58% of cases in group B.

Multivariate analysis demonstrated that there was a significant difference in postoperative rotational displacement between the proximal and distal fracture fragments between the two groups (odds ratio: 17.20; $p = 0.003$; Table 2).

Study 2. Among the 15 patients, all cases in the group with angulation had a serious internal rotation of 20° or more compared with the other unaffected side, and none of the cases in the group without angulation had rotational displacement (Table 3).

Table 2 Results of the multivariate analysis using logistic analysis

Parameter	<i>P</i> values	OR ^a (95% CI ^b)
Anterior fracture line (proximal/distal)	0.184	3.87 (−0.64–3.35)
Rotational displacement	0.003	17.20 (0.92–4.77)

^aodds ratio; ^bconfidence interval.

Table 1 Clinical and radiological findings of Groups A and B

Parameter	group A (n=28)	group B (n=12)	<i>P</i> values
Age (years)	79.8 (83.5 ^a)	82.8 (85.0 ^a)	0.825
Sex (male/female)	7/21	3/9	> 0.99
Fracture type (stable/unstable)	9/19	0/12	0.038
Anterior fracture line (proximal/distal)	12/15 ^b	2/10	0.152
TAD ^c (mm)	18.3 (18.1 ^a)	17.6 (16.3 ^a)	0.734
Placement of tip of lag screw (I-M/others)	25/3	11/1	> 0.99
Rotational displacement	2 (7%)	7 (58%)	0.001

^amedian; ^ba case excluded due to reversed obliquity of the anterior fracture line; ^ctip-apex distance.

Table 3 Results of the between-group comparison of rotational displacement using CT measurement

	a group with angulation (n = 5)	a group without angulation (n = 10)
$0^\circ < \text{Rotation} < 20^\circ$	0	10
$\text{Rotation} \geq 20^\circ$	5	0
Internal rotation $\geq 20^\circ$	5	0

Discussion

There is always the possibility of a loss of alignment of a trochanteric fracture post-reduction. Clinically, such loss of alignment is defined by a change in the Ikuta classification from a subtype N alignment to a subtype P alignment, as confirmed on lateral view radiographs. Shiokawa *et al.* reported a 26% incidence rate of post-reduction loss of alignment [11], while we observed a 30% rate in our study group on postoperative day 14. However, there has been no previous statistical analysis of risk factors for post-reduction displacement that could be used for comparison to our present findings.

From the results shown in Table 3, it would be possible to define angulation at the fracture site on the postoperative lateral view radiographs as postoperative rotational displacement (*i.e.*, the distal fragment being in a position of internal rotation relative to the proximal fragment), and this finding could provide a simple marker to identify rotational displacement during the intraoperative period. Applying this definition, we identified a significantly higher prevalence of postoperative rotational displacement among patients in group B than in group A. Apart from stable fractures, this result may have been due to excessive internal rotation of the leg during reduction. Therefore, in cases with angulation on lateral view radiographs, achieving an intraoperative reduction of the distal fragment in a position of external rotation is recommended. In some

cases, direct reduction maneuvers via an elevator may need to be considered to reduce this rotational displacement (Fig.6). We recognized the disappearance of angulation on lateral view radiographs as proof of correct repositioning. Nsouli *et al.* further promoted the use of temporary fixation of the proximal fragment for displaced lateral trochanteric fractures [12].

Based on previously published research, the IFL can hinder contact between the anterior cortex of the femoral neck and the distal diaphyseal fragment of the fracture if the anterior fracture line is located proximal to the IFL compartment, and this can lead to post-reduction displacement [3]. However, Tronzo stipulated that obtaining a stable reduction of the fracture is difficult when the anterior fracture line is distal to the adherent IFL compartment, regardless of the intraoperative procedures [13,14]. Moreover, in these cases, angulation at the fracture site on lateral view radiographs tends to remain postoperatively, such that when a lag screw is inserted or tapped in, the rotation of the proximal fragment is likely to be accentuated [15,16]. As mentioned earlier, the IFL attaches broadly above the intertrochanteric line. Because of this, cases in which the anterior fracture line crosses over the adherent IFL com-

partment can exist. Therefore, the results of the above studies may have differed depending on whether the position of the anterior fracture line in these cases was proximal or distal to the adherent IFL compartment. In our study, the position of the anterior fracture line in such cases was classified as being distal to the adherent IFL compartment as in the reports of Tronzo [13,14]. No between-group difference in the position of the anterior fracture line was observed, but the anterior fracture line was localized distal to the adherent IFL compartment in 28% more cases in group B than in group A. Additionally, the fracture line was identified as being distal to the adherent component of the IFL in 7 of the 25 cases (28%) in which angulation was identified on the postoperative lateral view radiographs. Thus further studies on the relationship between the position of the anterior fracture line and postoperative rotational displacement will also be needed.

It was of particular relevance that all our cases in group B were classified as unstable fractures (Jansen's type III, IV or V), and the overall ratio of unstable fractures was significantly lower in group A. The plausible association between an unstable fracture and post-reduction displacement is likely due to an insuffi-

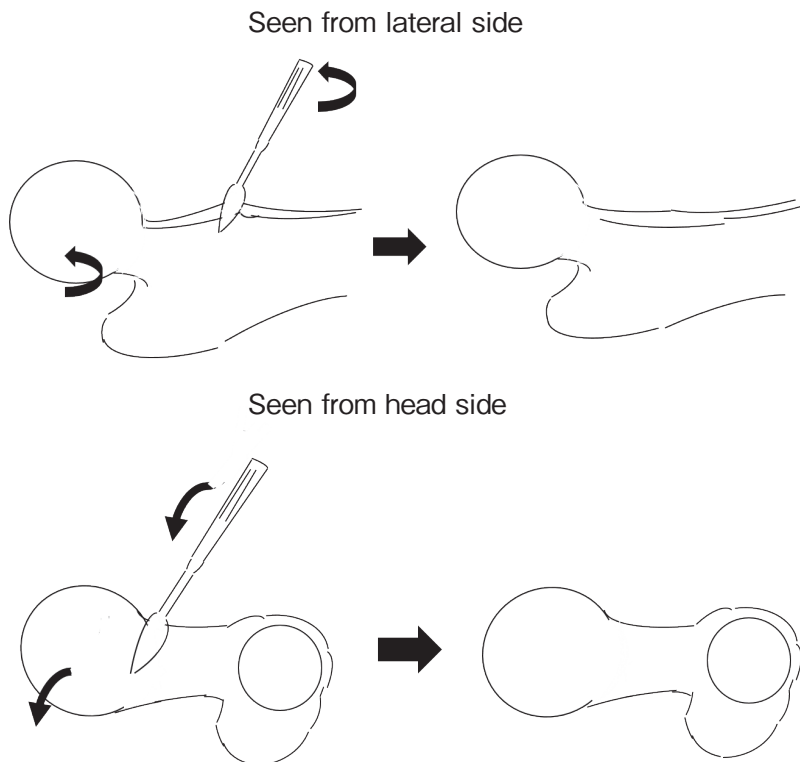


Fig. 6 A schematic diagram of the direct reduction of rotational displacement between the proximal and distal fracture fragments on right side when seen from the lateral side and the head side, showing internal rotation of the proximal fragment in the counterclockwise direction via an elevator.

cient area of bone contact at the fracture site to support the anterior cortex of the femoral neck, with subsequent rotation of the proximal fragment being more likely [10,11]. In our study, all fractures including unstable types of fractures were fixed using free-sliding plates rather than intramedullary nails. Our decision was based on the fact that a short femoral nail is more likely to be inserted in the fractured part when the nail is employed for unstable trochanteric fractures (Jansen's type III or V) [17], and a nail would avoid the need for a renewed skin incision if direct reduction maneuvers were needed. Shiota *et al.* [11] further recommended using a stabilizing plate with a free-sliding plate to achieve stable reconstruction of the posterolateral portion in unstable trochanteric fractures.

The two main methods for quantifying the placement of the lag screw that have been described are the proportional method of Parker [18] and TAD method of Baumgaertner *et al.* [4]. The optimal placement of the lag screw is in the inferior area of the femoral head on the anterior-posterior view and in the middle (central) area on the lateral view, with this I-M placement lowering the risk of cut-out of the lag screw in the femoral head [19]. Placement of the lag screw in the central area of the femoral head also reduces the risk of rotation of the femoral head and neck around the screw due to a small, but significant, torsional moment that can occur with an eccentric placement of the screw [20]. Regarding TAD, some studies have taken the view that the ideal would be <20 mm [21,22]. In our dataset, an optimal I-M placement of the screw was obtained in 90% of cases, with a suboptimal placement identified in only 4 of 40 patients, and the mean TAD was less than 20 mm in both groups. Therefore, evaluation of the specific influence of suboptimal placement of the lag screw and TAD beyond the upper limit on postoperative displacement was not possible.

Limitations. While our study provided a statistical analysis of risk factors for loss of alignment of a trochanteric fracture post-reduction, the number of cases was smaller than in other similar studies, especially with respect to the CT-based analysis of rotational displacement. Also, the follow-up period was short. Therefore, analysis with a greater number of cases and long-term observation will be necessary in the future.

Conclusions. Our data underscore the importance of achieving sufficient support of the anterior cortex of the femoral neck, with careful reduction of the

rotational displacement between fracture fragments to maintain an Ikuta subtype N alignment postoperatively. In some cases, direct reduction maneuvers, via an elevator, may need to be considered to reduce the rotational displacement. Additionally, we considered that angulation at the fracture site visible on a lateral view radiograph is useful as a simple marker to identify the rotational displacement (*i.e.*, the distal fragment in a position of internal rotation relative to the proximal fragment). Finally, particular care is indicated to maintain the reduction in unstable trochanteric fractures, for which the risk of postoperative displacement is increased.

Acknowledgments. We thank Dr. Kusakabe for his helpful suggestions regarding this study.

References

1. Sarmiento A: Intertrochanteric fractures of the femur. *J Bone Joint Surg* (1963) 45: 706–722.
2. Ikuta T: Classification of trochanteric fracture of the femur. *Kossetsu* (2002) 24: 158–162 (in Japanese).
3. Uchino T, Kawakami Y, Maeda K, Moritani S, Imatani J and Hayashi M: Evaluation of the unstable intertrochanteric fracture type by 3DCT. *Kossetsu* (2015) 37: 91–94 (in Japanese).
4. Baumgaertner MR and Solberg BD: Awareness of tip-apex distance reduces failure of fixation of trochanteric fractures of the hip. *J Bone Joint Surg Br* (1997) 79: 969–971.
5. Jensen JS, Sonne-Holm S and Tøndevold E: Unstable trochanteric fractures: a comparative analysis of four methods of internal. *Acta Orthop Scand* (1980) 51: 949–962.
6. Ochi T, Nakano T, Inaba D, Yasuoka K, Bakahara J and You T: Diagnosis imaging of femoral trochanteric fracture. *Kossetsu* (2015) 37: 242–246 (in Japanese).
7. Wisshig H and Spira G: Determination of rotational defects of the femur by computer tomographic determination of anterorsion angle of the femoral neck. *Unfallchirurgie* (1986) 12: 1–11 (in German).
8. Jeanmart L, Baert AL and Wackenheimer A: Computer Tomography of Neck, Chest, Spine and Limbs; in *Atlas of Pathologic Computer Tomography*, Springer-Verlag, New York (1983) pp171–177.
9. Braten M, Terjesen T and Rossvoll I: Femoral anterversion in normal adults: ultrasound measurements in 50 men and 50 women. *Acta Orthop Scand* (1992) 63: 29–32.
10. Kim TY, Lee YB, Chang JD, Lee SS, Yoo JH, Chung KJ and Hwang JH: Torsional malalignment, how much significant in the trochanteric fractures?. *Injury* (2015) 46: 2196–2200.
11. Shiota N, Sato T, Tetsunaga T, Yoshida M, Mochizuki Y, Yamada K and Okazaki Y: Evaluation of intraoperative reduction for femoral intertrochanteric fractures. *Kossetsu* (2013) 35: 345–348 (in Japanese).
12. Nsouli AZ and Haddad FF: Reduction of lateral trochanteric fractures in external rotation. *Orthop Rev* (1992) 21: 355–357, 360.
13. Tronzo RG: Fractures of the hip; in *Surgery of the Hip Joint*, Tronzo RG eds, Lea and Febiger, Philadelphia (1973) pp559–562.
14. Tronzo RG: Fractures of the hip in adults; in *Surgery of the Hip*

- joint, Tronzo RG eds, 2nd Ed, Springer-Verlag, New York (1978) pp265–285.
15. Suzuki M, Ihara H, Utsunomiya H, Kondo H and Nakai K: The classification and reduction of trochanteric fractures. *Journal of Joint Surgery* (2006) 25: 102–112 (in Japanese).
 16. Maeoka H, Okada M, Tomidokoro J, Hiromura K, Miaki K, Yokoyama M and Matsumoto T: Reduction of trochanteric fractures in anterior displacement. *Kossetsu* (2007) 29: 308–310 (in Japanese).
 17. Shouda E and Kitada S: CT evaluation of femoral trochanteric fracture treated with Japanese PFNA: classification and intra- and postoperative complications. *Kossetsu* (2013) 35: 80–83 (in Japanese).
 18. Parker MJ: Cutting-out of the dynamic hip screw related to its position. *J Bone Joint Surg Br* (1992) 74: 625.
 19. Kawatani Y, Nishida K, Anraku Y, Kunitake K and Tsutsumi Y: Clinical results of trochanteric fractures treated with the TARGON proximal femur intramedullary nailing fixation system. *Injury* (2011) 42: S22–S27.
 20. Den Hartog BD, Bartal E and Cooke F: Treatment of the unstable intertrochanteric fracture. Effect of the placement of the screw, its angle of insertion, and osteotomy. *J Bone Joint Surg Am* (1991) 73: 726–733.
 21. Wolfgang GL, Bryant MH and O'Neill JP: Treatment of intertrochanteric fracture of the femur using sliding screw plate fixation. *Clin Orthop Relat Res* (1982) 163: 148–158.
 22. Baumgaertner MR, Curtin SL, Lindskog DM and Keggi JM: The value of the tip-apex distance in predicting failure of fixation of peritrochanteric fractures of the hip. *J Bone Joint Surg Am* (1995) 77: 1058–1064.