

Table: Subject background

	Median	Quartile (25%–75%)	Range
All subjects (n=330)			
Age (y)	49	43–57	30–85
Breast thickness* (mm)	46	42–51	23–72
Number of collected tissue samples	3	3–6	3–9
Eligible subjects: comparison of two methods (n=28)			
Age (y)	54	47–57	33–66
Breast thickness* (mm)	46	41–49	23–56
Number of collected tissue samples	3	3–6	3–9
Interval between biopsy and mammography (days)	543	368–685	152–2029
Interval between first and second mammography (days)	370	362–491	154–1828
Eligible subjects: Three-dimensional measurement of clip placement (n=71)			
Age (y)	52	47–58	33–70
Breast thickness* (mm)	46	41–50	23–72
Number of collected tissue samples	3	3–6	3–9
Interval between biopsy and mammography (days)	64	26–420	7–2029

* Breast thickness at the time of tissue collection

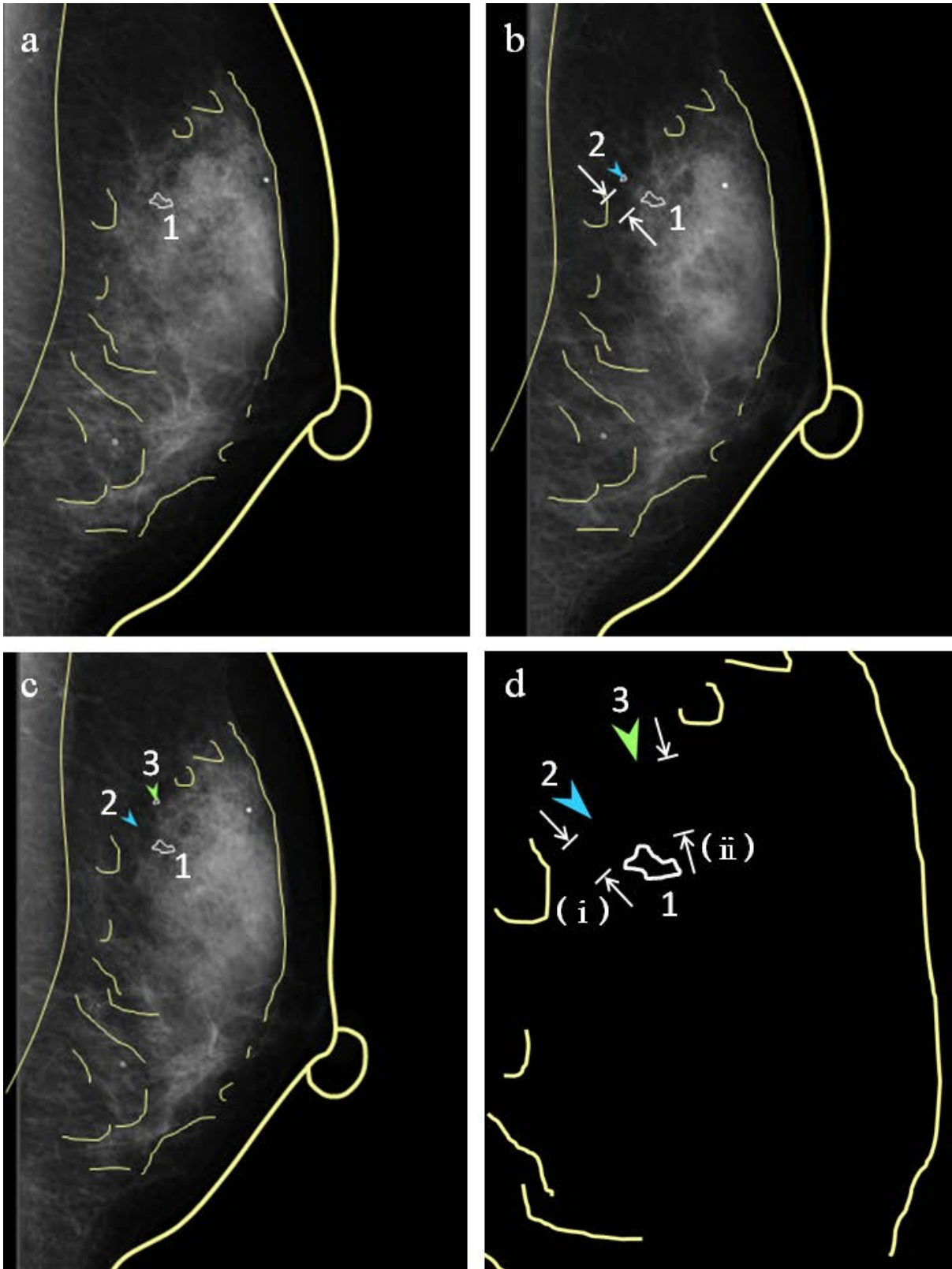
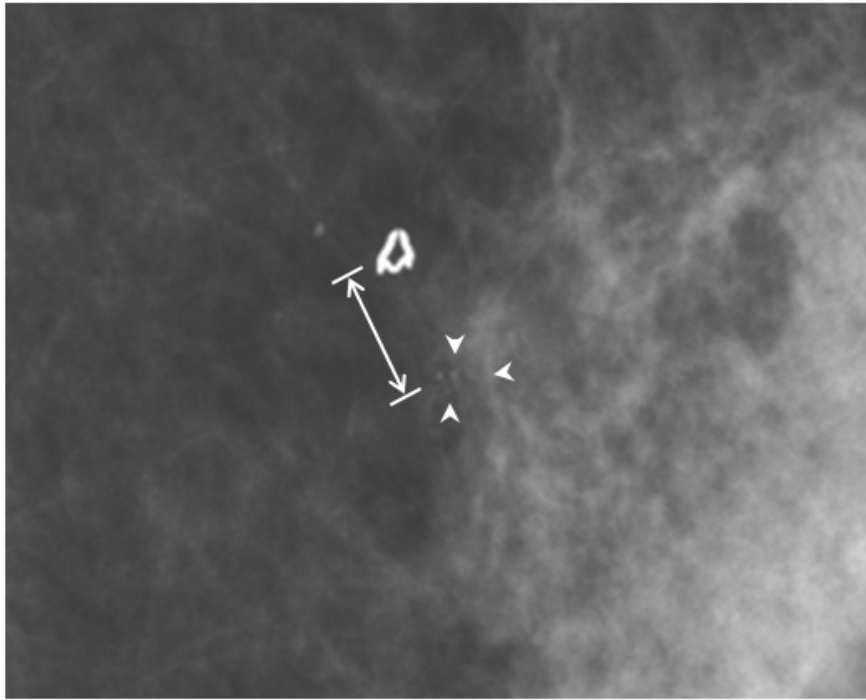
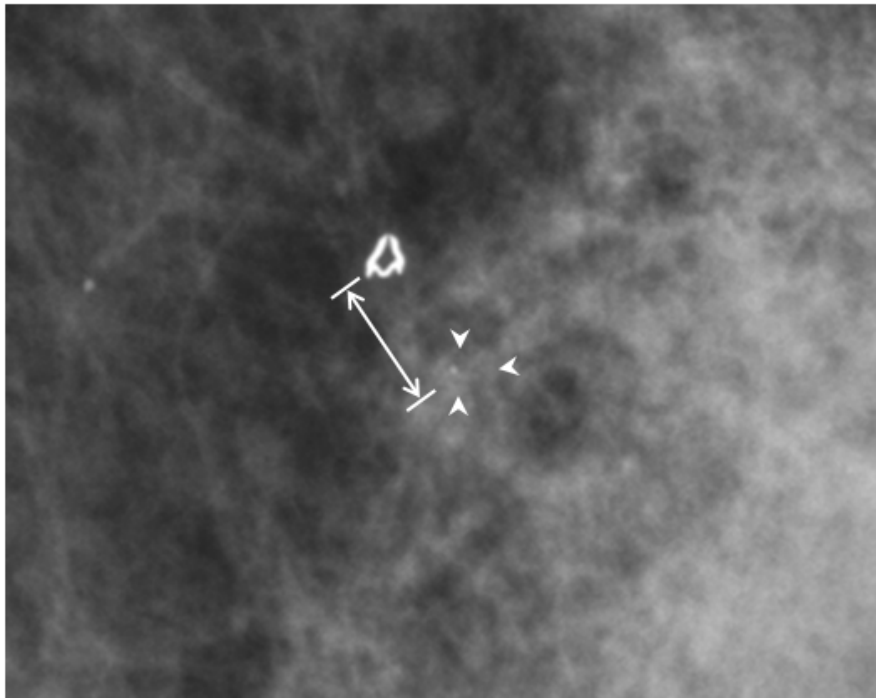


Figure 1: Conventional method and assessment of reproducibility for this method. a: A transparent film is overlapped on a mammogram before biopsy, the skin line, nipple,

mammary gland and pectoralis are outlined with a marker pen, and the targeted cluster calcification is noted (red area). b: The plotted film is overlapped on the mammogram after biopsy and the clip (blue mark) is marked. To measure distance from the calcifications (red area) to the clip (green mark) is the conventional method. c: To assess reproducibility conventional method, the plotted film is overlapped on another mammogram taken on another day and the clip (green mark) is marked. d: Distance (i) from the calcification (red area) to the clip (blue mark) and distance (ii) from the calcification (red area) to the clip (green mark) are measured. Reproducibility was defined as the difference between distances (i) and (ii).



a



b

Figure 2: Direct method and assessment of reproducibility for this method. On mammogram before biopsy, clustered small round calcifications were observed (category 3) [15]. On

mammogram after biopsy, residual calcifications were visualized. The biopsy result was fibroadenomatoid hyperplasia. The distance was measured from the center of a clip with a 2-mm diameter to a nearest residual calcification after biopsy. a: The mammogram after biopsy measured using the conventional method (Fig. 1b) was also evaluated using the direct method. b: A mammogram taken on another day and measured using the conventional method (Fig. 1c) was also evaluated using the direct method.

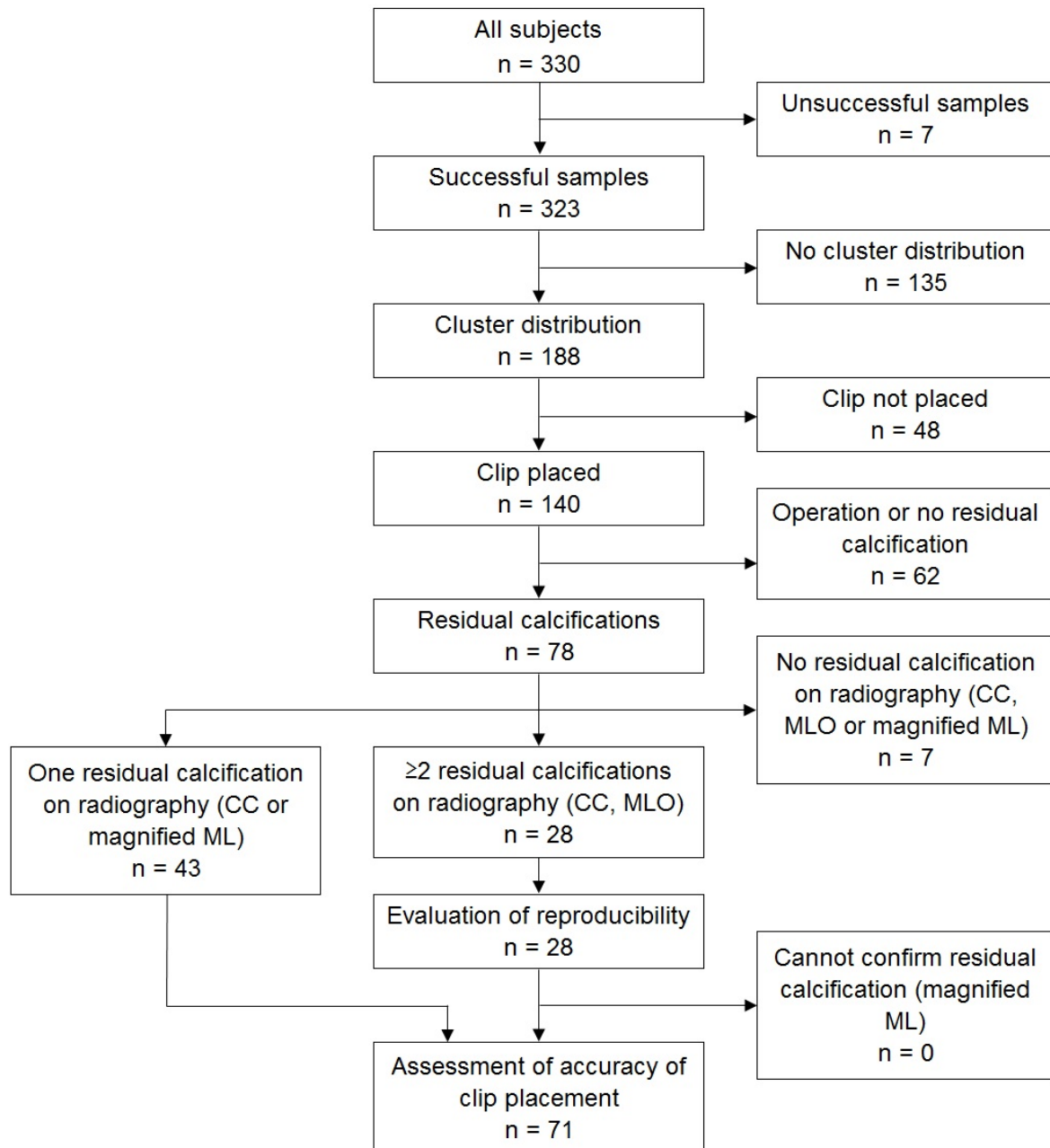


Figure 3: Flowchart of the study

CC: Craniocaudal, MLO: Mediolateral oblique, ML: Mediolateral

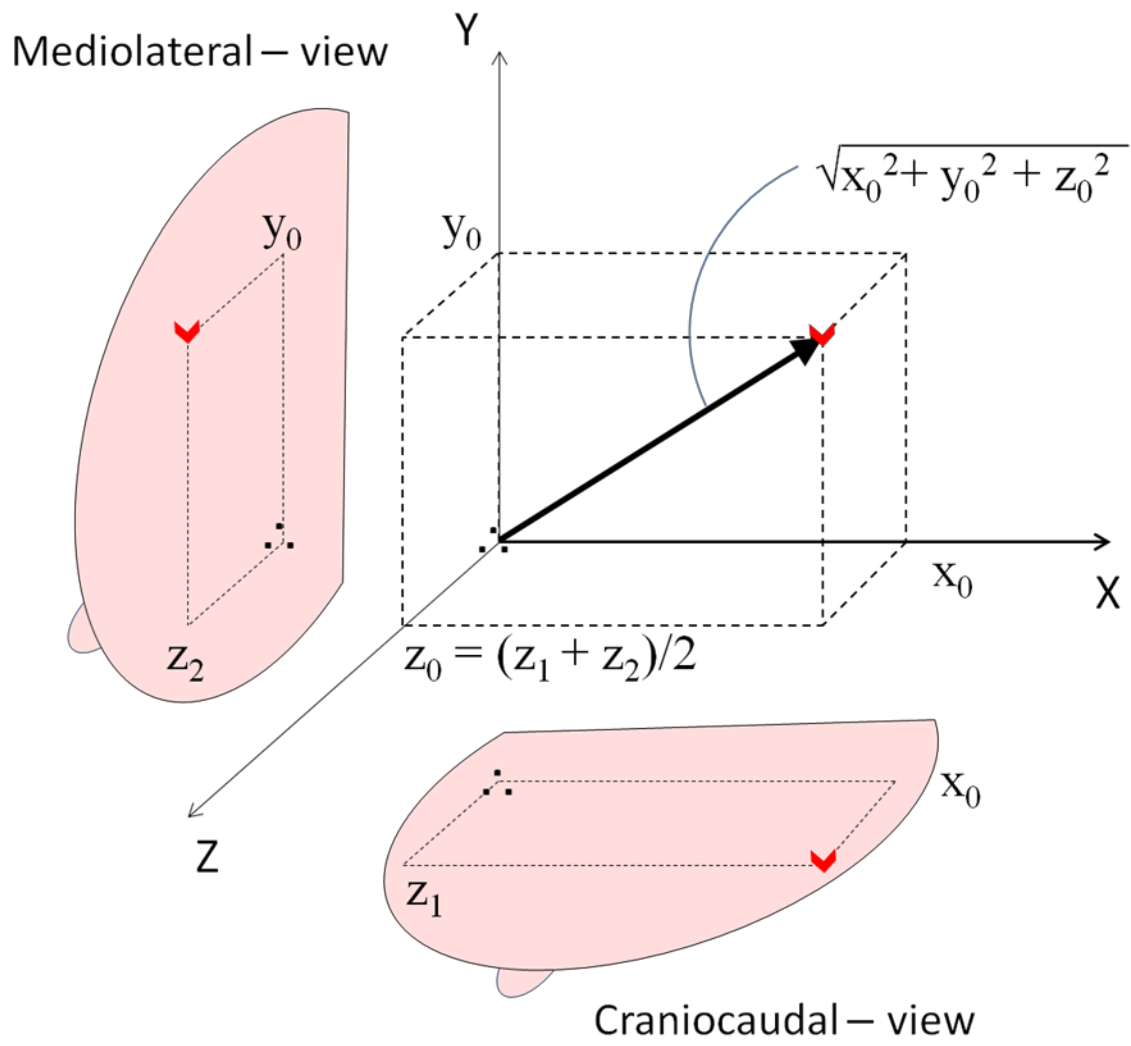


Figure 4: Three-dimensional measurement of the clip-to-residual calcification distance.

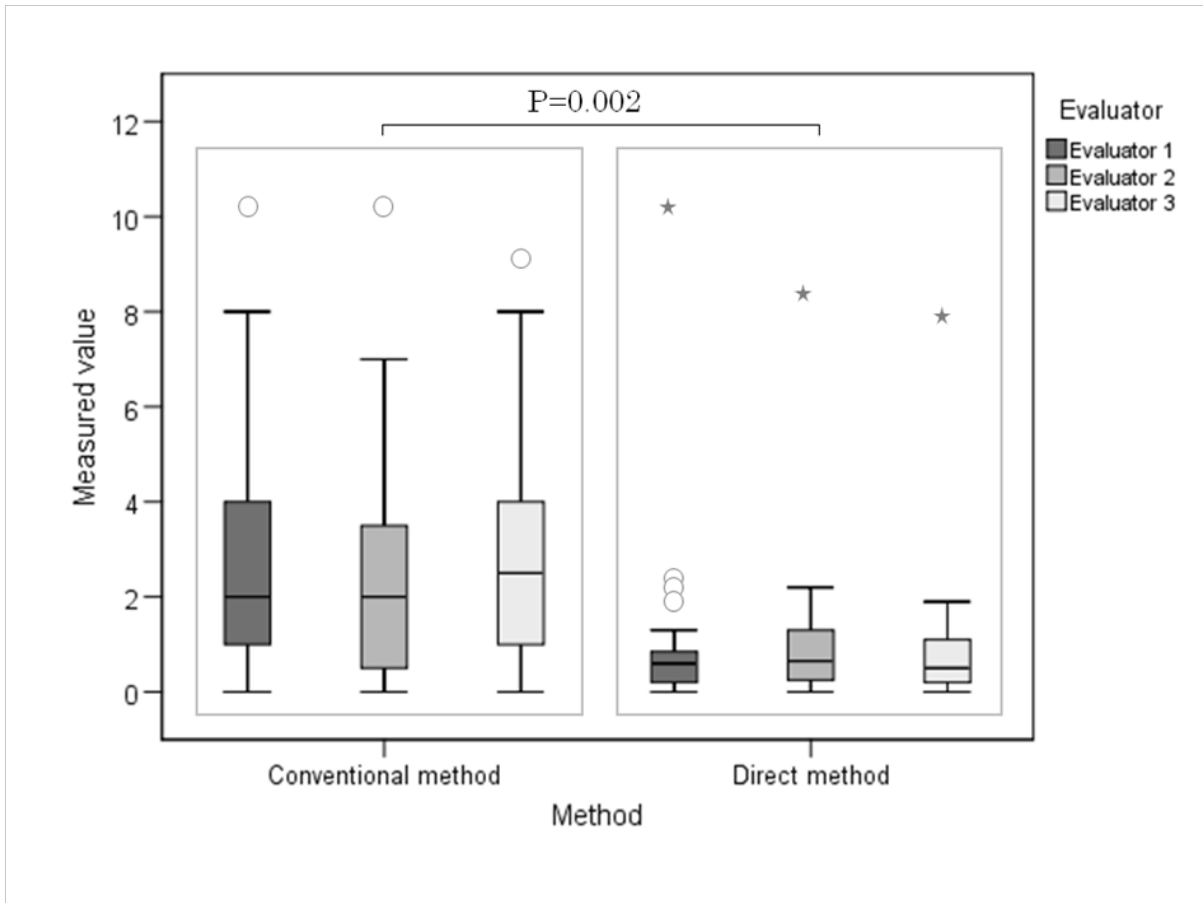


Figure 5: Comparison of reproducibility in the craniocaudal view between the conventional and direct measurements. Data are shown as differences in clip-to-residual calcification distances between the first and second mammography.

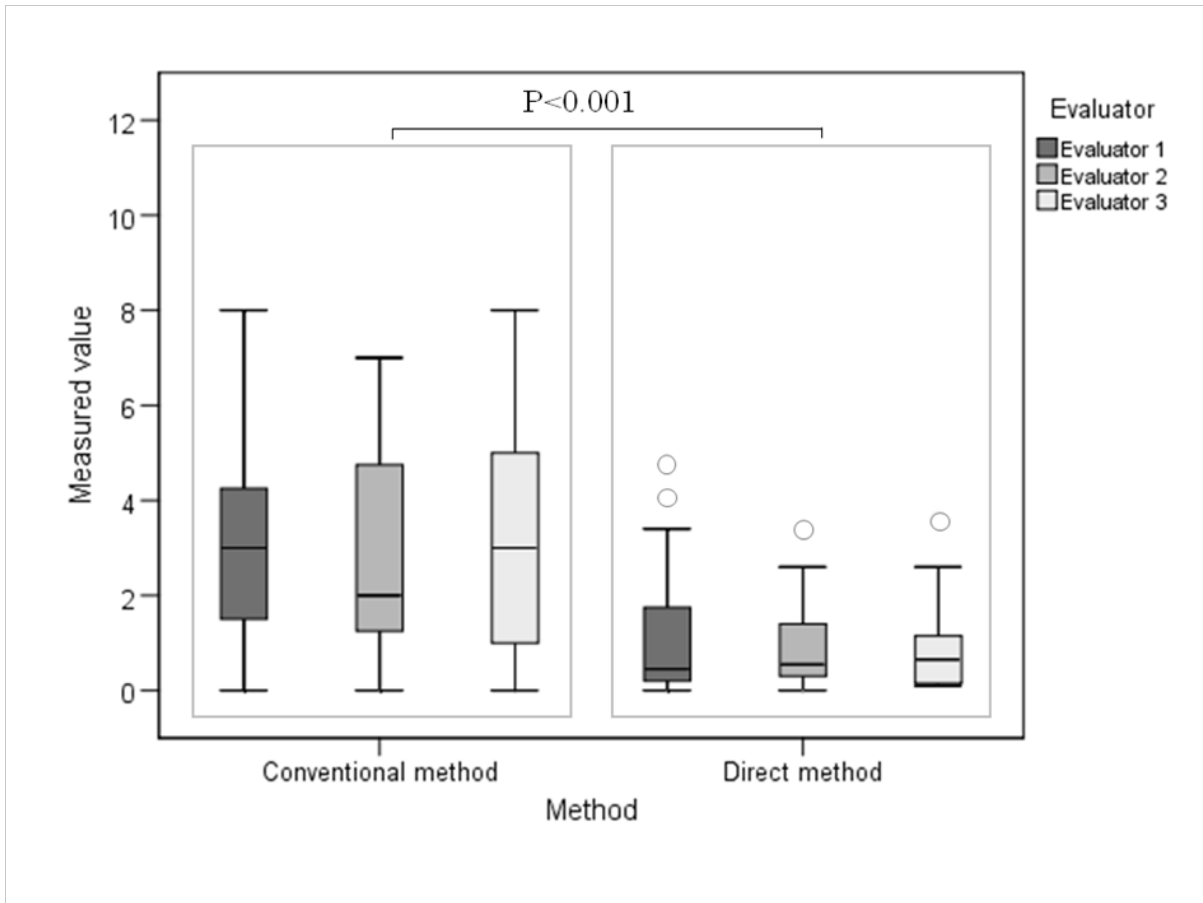


Figure 6: Comparison of reproducibility in the mediolateral-oblique view between the conventional and direct measurement. Data are the differences in clip-to-residual calcification distances between the first and second mammograms.

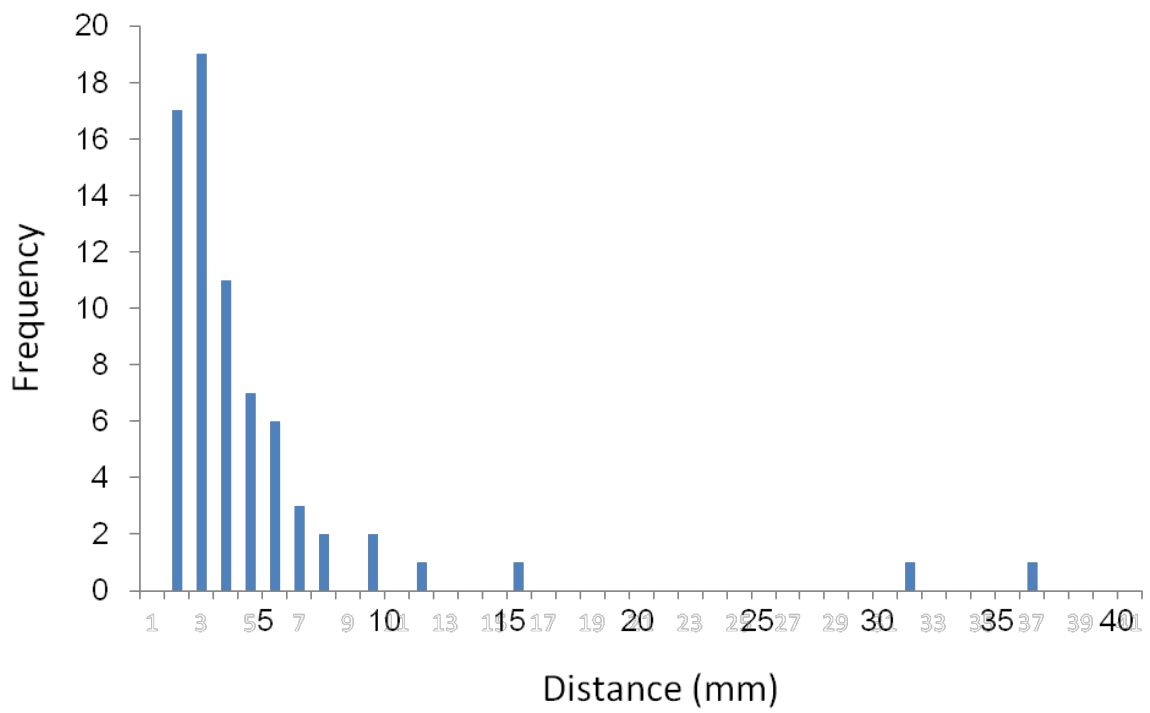


Figure 7: Histogram of the three dimensional clip-to-residual calcification distance from direct measurement.