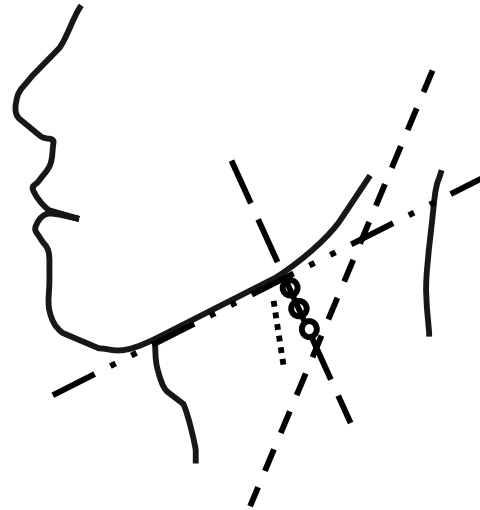
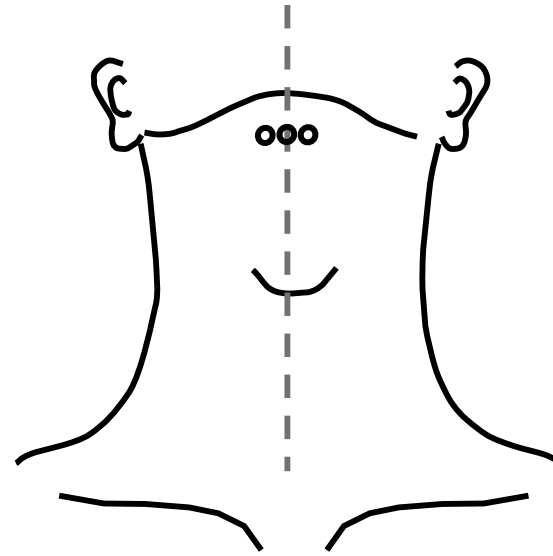


Fig. 1

(a)



(b)



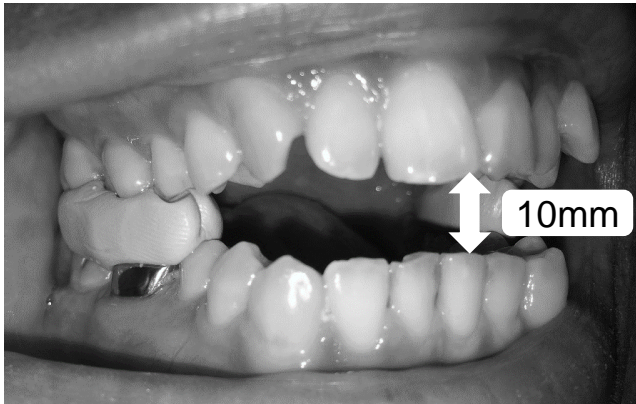
- - - anterior border of sternocleidomastoid muscle
- — center line of electrodes (perpendicular to mandibular plane)
- . . - mandibular plane
- posterior border of mylohyoid muscle

Fig. 2

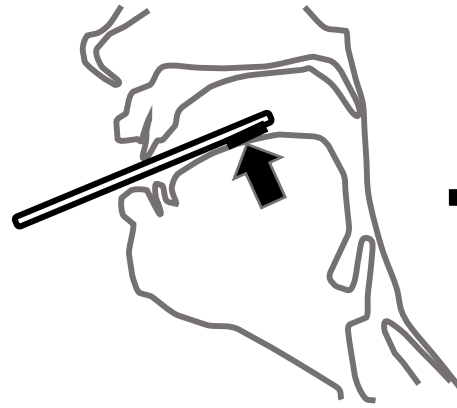
(a)



(b)



(c)



EMG amplitude
Tongue Pressure
Sensor output (V)

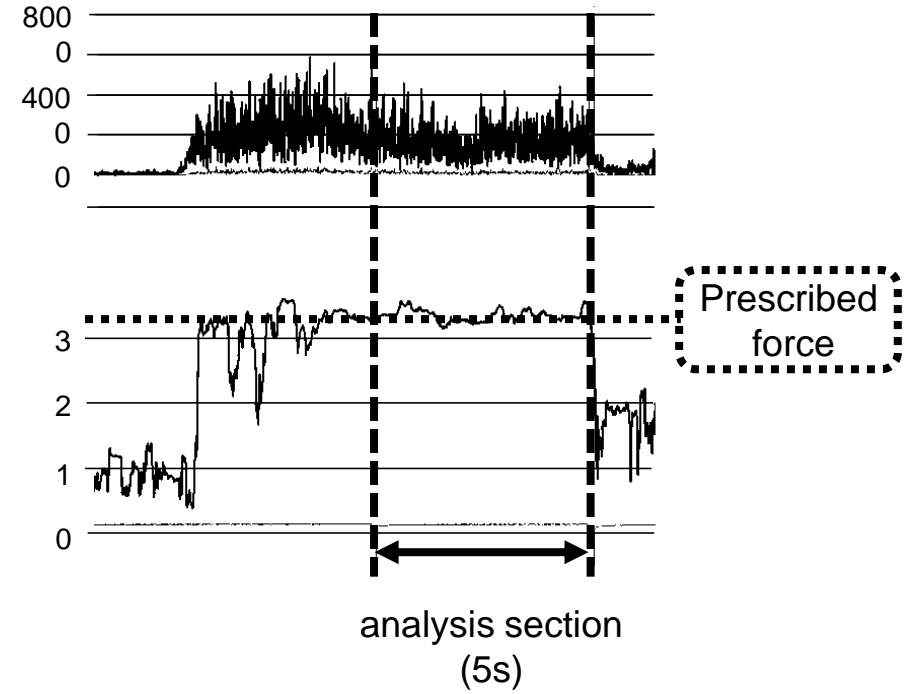


Fig. 3

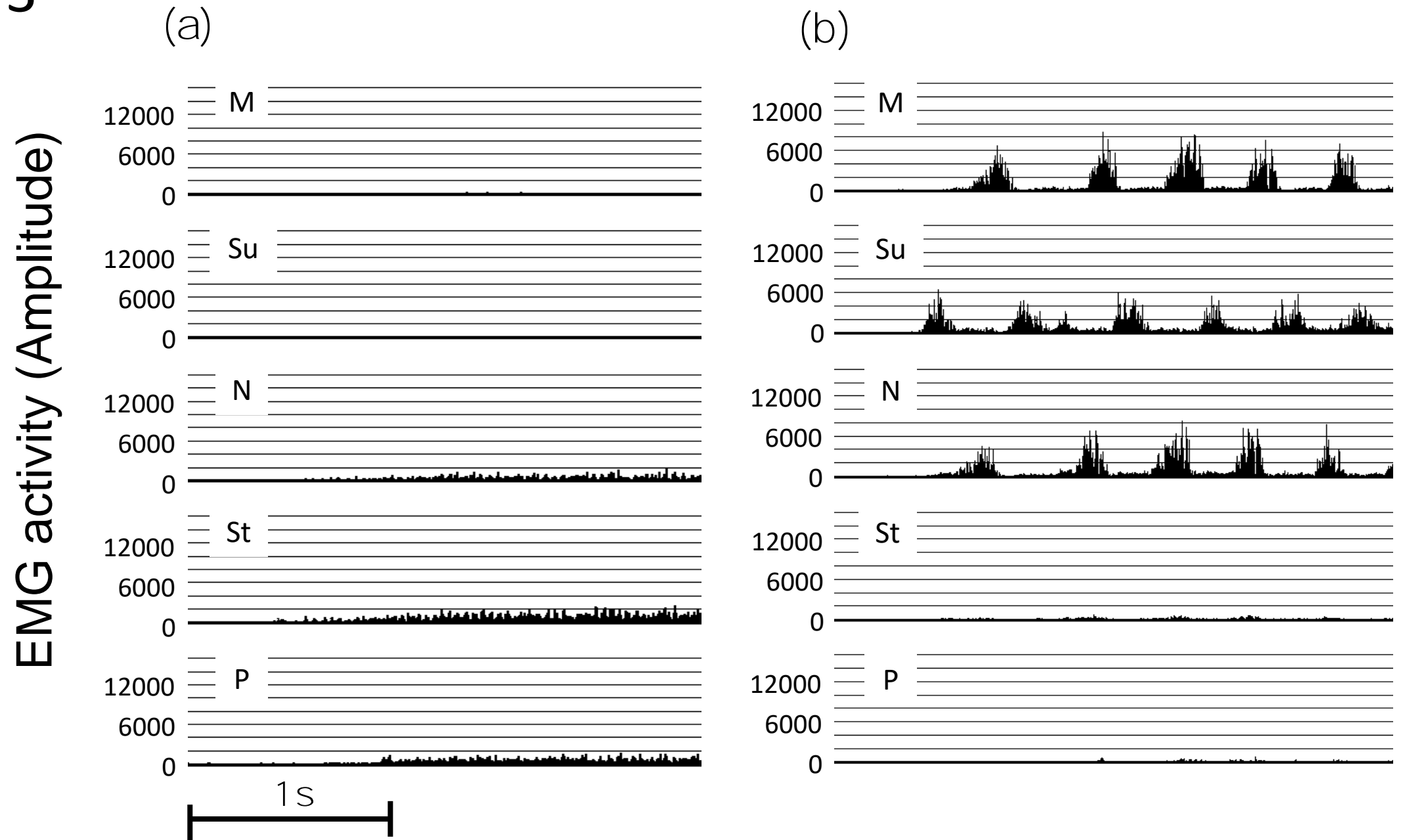


Fig. 4

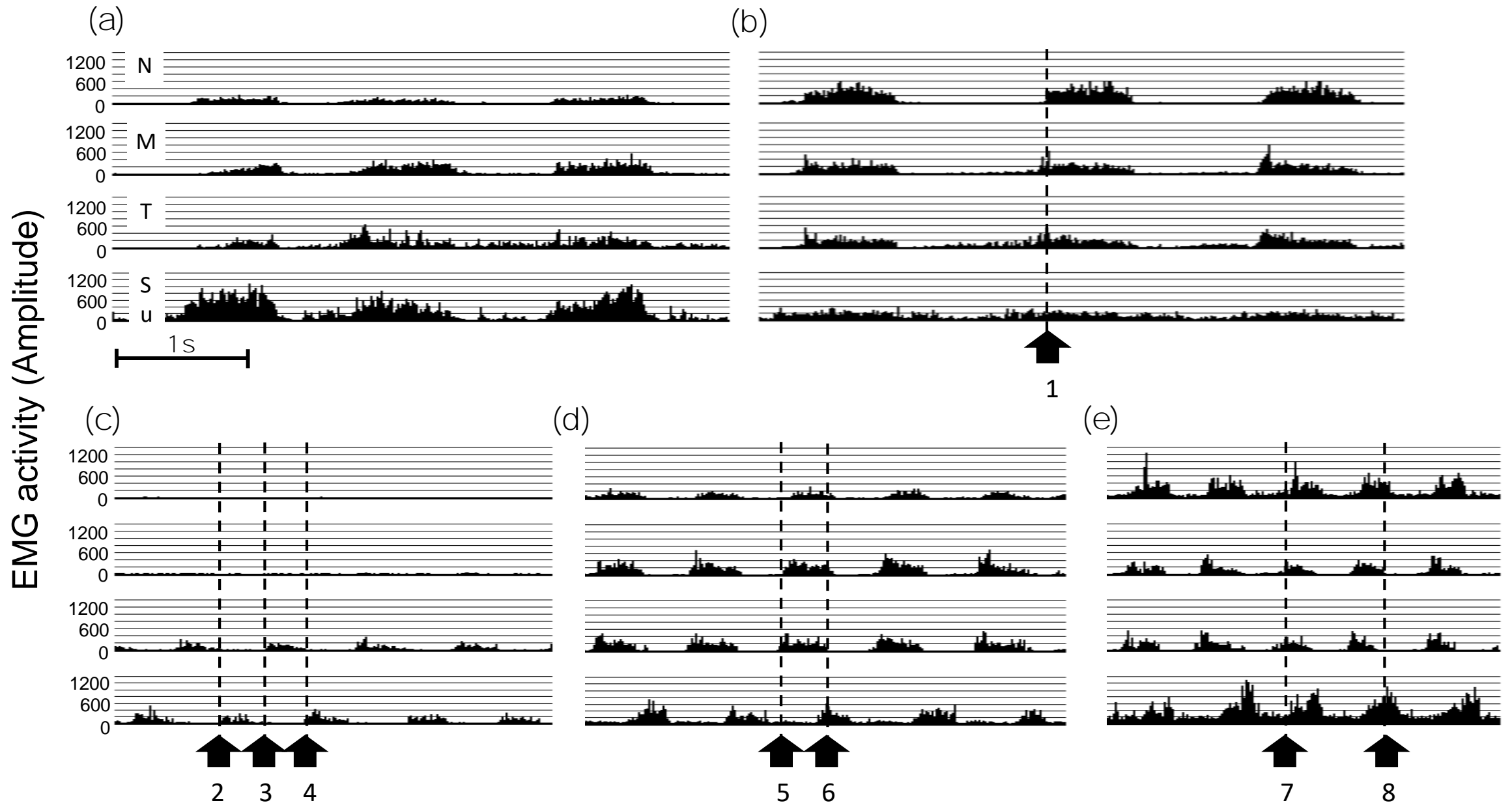


Fig. 5

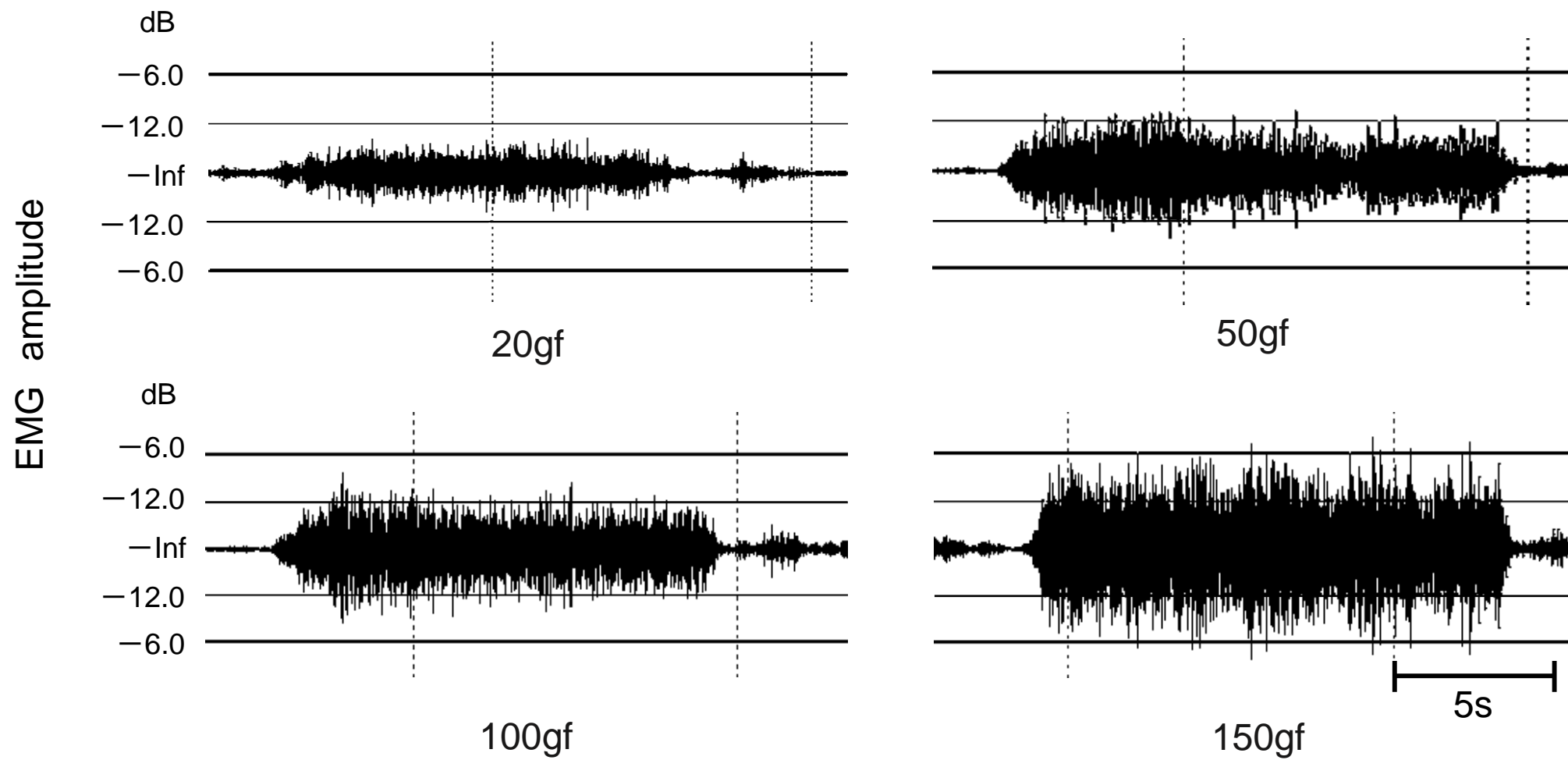


Fig. 6

