

Title

Laminar closure rates in patients with cervical myelopathies treated with either open-door laminoplasty with reattachment of spinous processes and extensor musculature or Hirabayashi open-door laminoplasty:

A case-control study

A concise and informative title

Laminar closure of modified laminoplasty

The names of the authors

Kentaro Yamane, MD, orthopaedic surgeon

Yoshihisa Sugimoto, MD, orthopaedic surgeon

Masato Tanaka, MD, orthopaedic surgeon

Shinya Arataki, MD, orthopaedic surgeon

Tomoyuki Takigawa, MD, orthopaedic surgeon

Toshifumi Ozaki, MD, orthopaedic surgeon

The affiliations of the authors

(a) Kentaro Yamane, MD, orthopaedic surgeon

Okayama university Graduate School of Medicine (Department of Orthopaedic Surgery)

(b) Yoshihisa Sugimoto, MD, orthopaedic surgeon

Okayama university Graduate School of Medicine (Department of Orthopaedic Surgery)

(c) Masato Tanaka, MD, orthopaedic surgeon

Okayama university Graduate School of Medicine (Department of Orthopaedic Surgery)

(d) Shinya Arataki, MD, orthopaedic surgeon

Okayama university Graduate School of Medicine (Department of Orthopaedic Surgery)

(e)Tomoyuki Takigawa, MD, orthopaedic surgeon

Okayama university Graduate School of Medicine (Department of Orthopaedic Surgery)

(f)Toshifumi Ozaki, MD, orthopaedic surgeon

Okayama university Graduate School of Medicine (Department of Orthopaedic Surgery)

Conflict of interest: The authors declare that they have no conflict interests.

The e-mail, telephone and fax numbers of the communicating author

Kentaro Yamane, MD

Fax: 81-86-223-9727, Telephone: 81-86-235-7273

E-mail address: woodblocks0311@gmail.com, Zip cord 700-8558

Address: 2-5-1, Shikata-cho, Kita-ku, Okayama City, Japan

Laminar closure rates in patients with cervical myelopathies treated with either open-door laminoplasty with reattachment of spinous processes and extensor musculature or Hirabayashi open-door laminoplasty:

A case-control study

Concise title: Laminar closure of modified laminoplasty

Structured abstract

**Purpose:** The presence of preoperative kyphosis has been identified as a risk factor for laminar closure (LC). We have been performing modified open-door laminoplasty with reattachment of the spinous processes and extensor musculature for patients with reduced cervical lordosis because this procedure can prevent progression of cervical kyphosis. This procedure may also prevent LC. The purpose of this study was to evaluate the rate of LC after the modified open-door laminoplasty.

**Methods:** A total of 104 patients who underwent open-door laminoplasty were retrospectively reviewed. Of these patients, 18 underwent modified open-door laminoplasty (group M), whereas the other 86 underwent Hirabayashi open-door laminoplasty (group H). Group H was divided into two classes according to the preoperative cervical lordosis angle (group H1  $\leq 10^\circ$  vs. group H2  $\geq 11^\circ$ ). All 18 patients in group M had a preoperative lordosis angle  $\leq 10^\circ$ . The outcomes were assessed using the rate of LC, the cross-sectional area (CSA) of the erector muscle on magnetic resonance imaging, and the Japanese Orthopaedic Association Score (JOA score).

**Results:** The rate of laminar closure was significantly lower in group M (39%) than in group H1 (76%) ( $P < 0.01$ ). The CSAs tended to be larger in the muscle preservation side of group M than in the other groups. There was no significant difference in the JOA score among the 3 groups.

**Conclusions:** Although patients with decreased cervical lordosis have a higher risk of LC, the results suggested that modified open-door laminoplasty could reduce the rate of LC compared with Hirabayashi

open-door laminoplasty.

### Key words

open-door laminoplasty; modified open-door laminoplasty; laminar closure; cervical myelopathy; cervical kyphosis

### Introduction

Hirabayashi open-door laminoplasty has been used for the treatment of cervical myelopathy [1-4], but laminar closure is one of the complications following this technique [5-8]. The opened laminae can gradually close because only stay sutures through the laminae and the facet capsule support the lifted laminae. There are a few previous reports about laminar closure after open-door laminoplasty [9-12]. The presence of preoperative kyphosis was identified as a risk factor for laminar closure by Matsumoto et al [9]. They explained biomechanically that the opened laminae may be subject to more compression force by the posterior tissues in the presence of cervical kyphosis. To prevent the progression of preoperative kyphosis, we have been performing a modified open-door laminoplasty [13] for patients with reduced cervical lordosis. This procedure consists of the reattachment of the spinous processes and the preservation of unilateral extensor musculature [13]. This reconstruction may prevent laminar closure, as well as cervical kyphosis. The purposes of this study were to compare the rate of postoperative laminar closure and clinical outcomes between the modified open-door laminoplasty and Hirabayashi open-door laminoplasty.

### Materials and Methods

A total of 104 patients who underwent open-door laminoplasty in our institute between 2004 and 2012 were retrospectively reviewed. The minimum follow-up period was 12 months. Of these patients, 18

underwent modified open-door laminoplasty (group M), whereas the other 86 patients underwent Hirabayashi open-door laminoplasty (group H). Group H was divided into two classes according to the preoperative cervical lordosis angle. Group H1 included patients with preoperative lordosis  $\leq 10^\circ$  (n=21), while group H2 had preoperative lordosis  $\geq 11^\circ$  (n=65). The modified open-door laminoplasty was mainly used in patients with reduced cervical lordosis before surgery. All 18 patients in group M had a preoperative lordosis angle  $\leq 10^\circ$ . The detailed demographic data are shown in Table 1.

### Surgical technique

Hirabayashi open-door laminoplasty was performed as described previously [2, 3]. Modified open-door laminoplasty was designed to preserve unilateral back muscles [13]. The midline skin incision is made from C3 to C7 in most patients. After dissecting unilateral paracervical muscles of the open side, the ipsilateral laminae are exposed. The spinous processes are cut at the base using a bone-saw or bone-chisel. Contralateral paracervical muscles with separated spinous processes are peeled off from the laminae to make a gutter of the hinge side. The lamina door is lifted, and sutures are tied to prevent the closure of the laminae in the same way as in Hirabayashi's method. The surface of the lifted laminae is decorticated by a high-speed drill. Bone holes are made by a high-speed drill at both of the separated spinous processes and lifted laminae, and sutures are placed through the holes. To fix the separated spinous processes on the lifted laminae, sutures previously placed through the bone holes are securely tied. In both surgical procedures, no additional device, such as a spacer or plate, was used in the open side. (Figure 1)

### Imaging and clinical assessment

The outcomes were assessed among the groups using the cervical lordosis angle, the rate of laminar closure, the cross-sectional area (CSA) of the erector muscle on cervical magnetic resonance imaging (MRI), and the Japanese Orthopaedic Association Score for cervical myelopathy (JOA score). The

lordosis angle was measured before surgery and at the final follow-up as the angle formed by the 2 tangential lines to the posterior wall of the C2 and C6 vertebrae. Positive numbers indicate lordosis. Laminar closure was calculated with the canal-to-body ratio (CBR) on lateral cervical radiographs, as described [9]. CBR was determined by dividing the anteroposterior diameter of the spinal canal by that of the vertebral body at each level from C3 to C6. Laminar closure was defined as present when the CBR measured immediately after surgery was reduced by  $\geq 15\%$  at the final follow-up, at 1 or more vertebral levels. Bony fusion between the spinous process and the lamina at each level from C3 to C6 was investigated in all group M patients using the lateral cervical radiographs at the final follow-up. MRI analysis was performed in patients with preoperative lordosis  $\leq 10^\circ$ . A total of 21 patients, including 9 in group M and 12 in group H1, underwent MRI 1 year postoperatively. All images were obtained using a T2-weighted fast spin echo pulse sequence. The percentage of CSAs of bilateral lean erector muscles, avoiding nearby fat, bony structures, and other soft tissues, was quantified using ImageJ software. The axial sections of MRI at the center level of surgery were used for quantification. The JOA score was recorded before surgery and at the final follow-up. The recovery rate was calculated using the formula established by Hirabayashi.

### Statistical analysis

All data are expressed as means  $\pm$  standard deviation. Comparative analyses among groups were performed with ANOVA for continuous variables and the chi-square test for categorical variables. The Tukey-Kramer multiple comparison procedure was used to identify differences among the groups after ANOVA was found to be significant. Residual analysis was used for identifying the categories responsible for a significant chi-squared statistic. P-values of less than 0.05 were considered significant.

### Results

The mean lordosis angles before surgery were  $0.7 \pm 6.3^\circ$  (range  $-13$  to  $7^\circ$ ) in group M,  $4.2 \pm 5.6^\circ$  (range  $-9$  to  $10^\circ$ ) in group H1, and  $22.4 \pm 8.5^\circ$  (range  $11$  to  $53^\circ$ ) in group H2 ( $P < 0.001$ ), while at final follow-up they were  $0.5 \pm 8.8^\circ$  (range  $-21$  to  $14^\circ$ ),  $0.8 \pm 12.2^\circ$  (range  $-25$  to  $27^\circ$ ), and  $20.9 \pm 10.4^\circ$  (range  $-7$  to  $49^\circ$ ) ( $P < 0.001$ ), respectively. The differences in the lordosis angles before surgery and at final follow-up were  $-0.2 \pm 9.3^\circ$  in group M,  $-3.4 \pm 9.7^\circ$  in group H1, and  $-1.8 \pm 8.3^\circ$  in group H2. (Table 1)

The rate of laminar closure was significantly lower in group M (7/18, 39%) than in group H1 (16/21, 76%) ( $P < 0.01$ ). The number of laminae with closure was also significantly lower in group M (12/70, 17%) than in group H1 (30/80, 38%) ( $P < 0.01$ ). The rate of laminar closure in group H2 was 51% (33/65). The percentage of laminae with closure in group H2 was 22% (54/242). (Figures 2, 3)

In the cases that underwent modified open-door laminoplasty, the bony fusion rate between the spinous process and the lamina at each level from C3 to C6 was 93% (66/71). Twelve of 18 patients (67%) in group M showed bony fusion between the spinous process and the lamina at every level, and 6 patients (33%) showed nonunion at only one level. (Figure 2C)

The CSAs tended to be larger in the hinge side of group M than in the other groups. The percentages of CSAs of bilateral lean erector muscles were  $60.9\% \pm 4.1\%$  in the open side and  $68.1\% \pm 10.1\%$  in the hinge side in group M, and  $60.6\% \pm 5.4\%$  in the open side and  $62.7\% \pm 4.6\%$  in the hinge side in group H.

JOA scores were  $11.1 \pm 2.7$  in group M,  $12.6 \pm 1.8$  in group H1, and  $11.3 \pm 2.5$  in group H2 before surgery, and  $13.4 \pm 2.2$ ,  $14.5 \pm 2.5$ , and  $14.3 \pm 2.0$ , respectively, at the final follow-up. The mean recovery of JOA scores was  $46\% \pm 24\%$  in group M,  $44\% \pm 45\%$  in group H1, and  $54\% \pm 27\%$  in group H2. There was no significant difference among the 3 groups. (Table 1)

### Discussion

The reported laminar closure rate after open-door laminoplasty varies from 10% to 45% [9-12]. Laminar

closure rarely causes critical outcomes over the long-term surgical course. However, additional operations are sometimes required because of the deterioration of neurologic outcomes. Greater attention is needed after Hirabayashi open-door laminoplasty because this procedure requires no additional supportive devices except stay sutures. Some authors have described the disadvantages of laminar closure [9-12]. Matsumoto et al. reported that laminar closure tended to decrease patient satisfaction, and the recovery rate of the JOA score also tended to decrease in patients with laminar closure [9, 10]. Lee et al. reported that laminar closure was associated with remaining spinal cord compression on MRI [11]. Wang et al. reported that postoperative neurologic deficits were associated with laminar closure [12]. According to these reports, we should consider measures to decrease laminar closure. In this study, the impact of laminar closure after modified open-door laminoplasty with reconstruction of spinous processes and preservation of unilateral back muscles was examined.

The only reported risk factor for laminar closure is preoperative cervical kyphosis [9]. Our series of Hirabayashi open-door laminoplasty showed a similar tendency. In this study, reduced cervical lordosis was defined as  $\leq 10^\circ$ . Patients with a preoperative lordosis angle  $\leq 10^\circ$  were unintentionally selected as group M since we started the modified open-door laminoplasty. This is because we used the modified open-door laminoplasty for patients with decreased cervical lordosis in case cervical kyphosis should progress. The criteria for laminar closure vary by author [9-12]. The CBR method was used to measure it because all patients had had radiographs at follow-up examinations. Laminar closure was defined as a 15% decrease in CBR in the present study. A previous report by Matsumoto et al. considered that the clinical outcomes were not significantly affected by laminar closure with CBR decrease  $\geq 10\%$  [9, 10]. In the present study, a slightly more aggressive standard, a CBR decrease of  $\geq 15\%$ , was established.

Various modified open-door laminoplasties with devices such as screws, spacers, or plates have been used to prevent laminar closure [14-19], while the simplicity, lack of need for artificial devices, and low cost of the classic methods are still impressive. The present modified open-door laminoplasty can prevent



laminar closure without additional artificial devices. The rate of bony fusion between the spinous process and the lamina was high. It indicated that the tensile force of the paraspinal muscles to the laminae was well preserved. This tensile force can act advantageously to prevent laminar closure and kyphosis after surgery. In contrast, in Hirabayashi open-door laminoplasty, there is no connection between the lifted laminae and the back muscles. In that situation, the back muscles work only as a compression force to the lifted laminae, especially with cervical kyphosis, as previously described [9, 20]. The mechanical advantage of modified open-door laminoplasty can be substantiated by the results of the high rate of bony fusion between the spinous process and the lamina, the rate of laminar closure, the progression of the kyphosis angle, and the percentages of CSAs of bilateral lean erector muscles in the present study. Specifically, the rate of laminar closure was significantly lower in group M than in group H1. MRI assessment supported the protective effect of the unilateral erector muscles on the hinge side. However, there was no significant difference in the mean recovery of the JOA score among the three groups, and no cases required reoperation because of neurological deterioration in the present series. This is because there were no severe laminar closures in this study. Moreover, previous reports showed that cervical kyphosis does not necessarily affect surgical outcomes. [21, 22] Nevertheless, laminar closure has a potential for neurological deterioration and the need for re-operation, as previously reported, and careful attention should be paid to laminar closure.

Though the present study's findings regarding laminar closure after modified open-door laminoplasty with reattachment of the spinous processes and unilateral extensor musculature are interesting, some limitations were present. First, the study was retrospective in nature, and the number of patients, especially in group M, was relatively small. Advanced imaging, such as computed tomography (CT) or MRI, was not performed, and patient-oriented outcome measures were not assessed in every patient. Gu et al. proposed the optimal opening size and angle following cervical laminoplasty using CT. [23, 24] Applying these surgical and measuring methods can bring a more relevant comparison of laminar closure

and clinical outcomes. Furthermore, there is no standard definition of laminar closure. The criteria of laminar closure and the way to measure it vary by authors, and simple comparisons among them are difficult. To solve these limitations, a further study, such as a prospective study that satisfies the above conditions, is needed. Despite these limitations, this study is the first to investigate the rate of laminar closure by comparing modified and classic open-door laminoplasties, and we believe that this study has great value for clinical practice.

### Conclusion

In this retrospective study, modified open-door laminoplasty with reattachment of the spinous processes and unilateral extensor musculature was applied mainly to patients with decreased cervical lordosis because this procedure can prevent the progression of cervical kyphosis. Although such patients with decreased cervical lordosis have a higher risk of laminar closure, the results suggested that modified open-door laminoplasty could reduce the rate of laminar closure compared with the classic open-door laminoplasty.

Conflict of interest: The authors declare that they have no conflict interests.

### Reference

1. Chiba K, Ogawa Y, Ishii K, Takaishi H, Nakamura M, Maruiwa H, Matsumoto M, Toyama (2006) Long-term results of expansive open-door laminoplasty for cervical myelopathy--average 14-year follow-up study. *Spine (Phila Pa 1976)* Dec 15;31(26):2998-3005
2. Hirabayashi K , Miyakawa J , Satomi K , Maruyama T, Wakano K (1981) Operative results and postoperative progression of ossification among patients with ossification of cervical posterior longitudinal ligament . *Spine (Phila Pa 1976)* 6:354-364

3. Hirabayashi K, Watanabe K, Wakano K, Suzuki N, Satomi K, Ishii Y (1983) Expansive open-door laminoplasty for cervical spinal stenotic myelopathy. *Spine (Phila Pa 1976)* 8:693-699
4. Hirabayashi K, Toyama Y, Chiba K (1999) Expansive laminoplasty for myelopathy in ossification of the longitudinal ligament. *Clin Orthop Relat Res Feb;(359):35-48*
5. Hirabayashi K, Satomi K (1988) Operative procedure and results of expansive open-door laminoplasty. *Spine (Phila Pa 1976)* Jul;13(7):870-876
6. Patel CK, Cunningham BJ, Herkowitz HN (2002) Techniques in cervical laminoplasty. *Spine J* Nov-Dec;2(6):450-455.
7. Satomi K, Nishu Y, Kohno T, Hirabayashi K (1994) Long-term follow-up studies of open-door expansive laminoplasty for cervical stenotic myelopathy. *Spine (Phila Pa 1976)*19:507-510
8. Satomi K, Ogawa J, Ishii Y, Hirabayashi K (2001) Short-term complications and long-term results of expansive open-door laminoplasty for cervical stenotic myelopathy. *Spine J* 1:26-30
9. Matsumoto M, Watanabe K, Tsuji T, Ishii K, Takaishi H, Nakamura M, Toyama Y, Chiba K (2008) Risk factors for closure of lamina after open-door laminoplasty. *J Neurosurg Spine* 9:530-537
10. Matsumoto M, Watanabe K, Hosogane N, Tsuji T, Ishii K, Nakamura M, Chiba K, Toyama Y (2012) Impact of lamina closure on long-term outcomes of open-door laminoplasty in patients with cervical myelopathy. *Spine (Phila Pa 1976)* Jul 1;37(15):1288-1291
11. Lee DH, Park SA, Kim NH, Hwang CJ, Kim YT, Lee CS, Riew KD (2011) Laminar closure after classic Hirabayashi open-door laminoplasty. *Spine (Phila Pa 1976)* Dec 1;36(25):E1634-1640
12. Wang HQ, Mak KC, Samartzis D, El-Fiky T, Wong YW, Luo ZJ, Kang X, Cheung WY, Luk KD, Cheung KM. (2011) "Spring-back" closure associated with open-door cervical laminoplasty. *Spine J* Sep;11(9):832-838
13. Hayashi M, Ogino T, Itoh T, Takei H, Hashimoto J, Ohshima Y (1997) The progress of OPLL after cervical laminoplasty –At least 3 years follow-up. *Spinal Surgery* 11(1):61-66 (in Japanese)

14. Duetzmann S, Cole T, Ratliff JK (2015) Cervical laminoplasty developments and trends, 2003-2013: a systematic review. *J Neurosurg Spine* Jul;23(1):24-34
15. Itoh T, Tsuji H (1985) Technical improvements and results of laminoplasty for compressive myelopathy in the cervical spine. *Spine (Phila Pa 1976)*10:729-736
16. Lee JY, Hanks SE, Oxner W, Tannoury C, Donaldson WF 3rd, Kang JD (2007) Use of small suture anchors in cervical laminoplasty to maintain canal expansion: a technical note. *J Spinal Disord Tech* 20:33-35
17. O'Brien MF, Peterson D, Casey AT, Crockard HA (1996) A novel technique for laminoplasty augmentation of spinal canal area using titanium miniplate stabilization. A computerized morphometric analysis. *Spine (Phila Pa 1976)* 21:474-484
18. Tanaka N, Nakanishi K, Fujimoto Y, Sasaki H, Kamei N, Hamasaki T, Yamada K, Yamamoto R, Nakamae T, Ochi M (2008) Expansive laminoplasty for cervical myelopathy with interconnected porous calcium hydroxyapatite ceramic spacers: comparison with autogenous bone spacers. *J Spinal Disord Tech* Dec;21(8):547-552
19. Wang JM, Roh KJ, Kim DJ, Kim DW (1998) A new method of stabilizing the elevated laminae in open-door laminoplasty using an anchor system. *J Bone Joint Surg Br* 80:1005-1008
20. Harrison DE, Harrison DD, Janik TJ, William Jones E, Cailliet R, Normand M (2001) Comparison of axial and flexural stresses in lordosis and three buckled configurations of the cervical spine. *Clin Biomech (Bristol, Avon)* May;16(4):276-284
21. Kawakami M, Tamaki T, Ando M, Yamada H, Yoshida M (2002) Relationships between sagittal alignment of the cervical spine and morphology of the spinal cord and clinical outcomes in patients with cervical spondylotic myelopathy treated with expansive laminoplasty. *J Spinal Disord Tech* Oct;15(5):391-397
22. Kim SW, Hai DM, Sundaram S, Kim YC, Park MS, Paik SH, Kwak YH, Kim TH (2013) Is cervical

lordosis relevant in laminoplasty? *Spine J* Aug;13(8):914-921

23. Gu Z, Zhang A, Shen Y, Li F, Sun X, Ding W (2015) Relationship between the laminoplasty opening size and the laminoplasty opening angle, increased sagittal canal diameter and the prediction of spinal canal expansion following open-door cervical laminoplasty. *Eur Spine J.* Aug;24(8):1613-1620

24. Gu ZF, Zhang AL, Shen Y, Ding WY, Li F, Sun XZ (2015) The relationship between laminoplasty opening angle and increased sagittal canal diameter and the prediction of spinal canal expansion following double-door cervical laminoplasty. *Eur Spine J.* Aug;24(8):1597-1604

#### Figure legends

##### Fig. 1

Modified open-door laminoplasty with reconstruction of the spinous processes and preservation of unilateral back muscles. 1. After dissecting unilateral paracervical muscles of the open side, 2. the spinous processes are cut at the base, and the contralateral paracervical muscles with separated spinous processes are peeled off from the laminae (A). To fix the separated spinous processes on the lifted laminae, sutures placed through the bone holes are securely tied (B). Postoperative CT image (C).

##### Fig. 2

Representative cases of the pre and postoperative courses of the two groups. Each case had reduced cervical lordosis before surgery (A, D). Immediately after surgery (B, E). At final follow-up, the patient with modified open-door laminoplasty did not experience laminar closure (C), while the patient with the Hirabayashi method developed cervical kyphosis and laminar closure (F). Bony fusion between the spinous process and the lamina was obtained at C3, 4, 6. Nonunion was seen at C5 (C).

##### Fig. 3

## Laminar closure of modified laminoplasty

The rate of laminar closure is significantly lower in group M (7/18, 39%) than in group H1 (16/21, 76%) ( $P < 0.01$ ). The percentage of laminae with closure is also significantly lower in group M (12/70, 17%) than in group H1 (30/80, 38%) ( $P < 0.01$ ).

Table 1. Demographic data and outcomes for Group M and Group H

Preoperative lordosis angle	Group M	Group H		P value
	( $\leq 10^\circ$ )	H1 ( $\leq 10^\circ$ )	H2 ( $\geq 11^\circ$ )	
Number of patients	18	21	65	
Age (years)	61.3 $\pm$ 13.7	59.3 $\pm$ 10.9	65.9 $\pm$ 9.4 <sup>a</sup>	0.115
Follow-up (months)	48.4 $\pm$ 18.6	39.0 $\pm$ 23.3	34.3 $\pm$ 22.1 <sup>b</sup>	0.054
Causative disease				
CSM	8	4	41	
OPLL	10	16	23	
CDH	0	1	1	
Lordosis angle* ( $^\circ$ )				
At pre-operation	0.7 $\pm$ 6.3	4.2 $\pm$ 5.6	22.4 $\pm$ 8.5 <sup>ab</sup>	<0.001
At final follow-up	0.5 $\pm$ 8.8	0.8 $\pm$ 12.2	20.9 $\pm$ 10.4 <sup>ab</sup>	<0.001
Difference**	-0.2 $\pm$ 9.3	-3.4 $\pm$ 9.7	-1.8 $\pm$ 8.3	0.511
JOA score				
At pre-operation	11.1 $\pm$ 2.7	12.6 $\pm$ 1.8	11.3 $\pm$ 2.5	0.094
At final follow-up	13.4 $\pm$ 2.2	14.5 $\pm$ 2.5	14.3 $\pm$ 2.0	0.208
Recovery rate# (%)	46 $\pm$ 24	44 $\pm$ 45	54 $\pm$ 27	0.396

The values are given as the mean and the standard deviation.

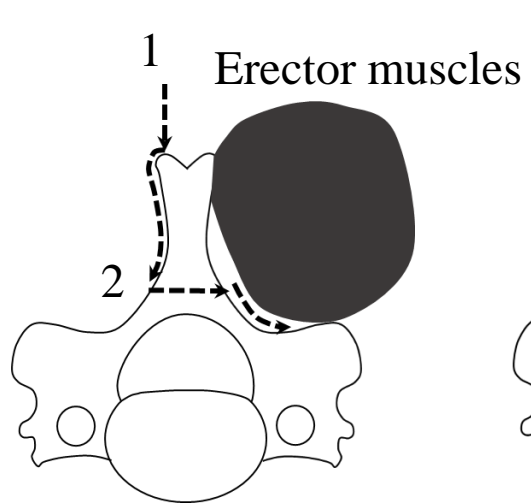
\*Positive numbers in lordosis angle indicate lordosis.

\*\*Negative numbers in difference of lordosis angle indicate that lordosis angle decreased.

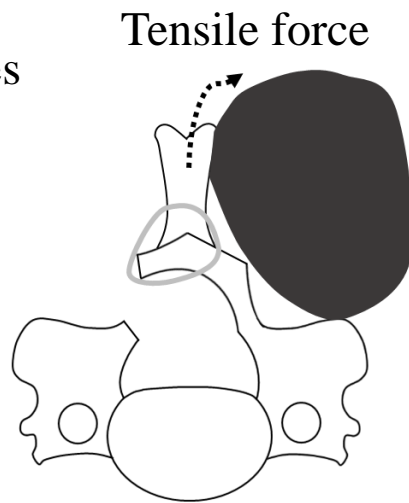
# Recovery rate was calculated using the following formula established by Hirabayashi: (postoperative JOA score – preoperative JOA score) / (17 – preoperative JOA score)  $\times$  100%.

Group M, Modified open-door laminoplasty; Group H, Hirabayashi open-door laminoplasty; CSM, Cervical spondylotic myelopathy; OPLL, Ossification of posterior longitudinal ligament; CDH, Cervical disc herniation; JOA, The Japanese Orthopaedic Association

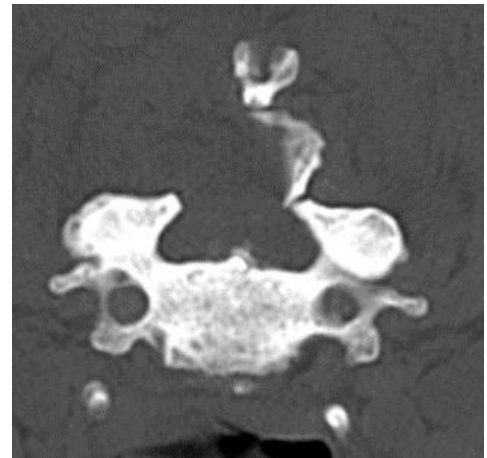<sup>a</sup> P<0.05 vs. Group H1    <sup>b</sup> P<0.05 vs. Group M



A



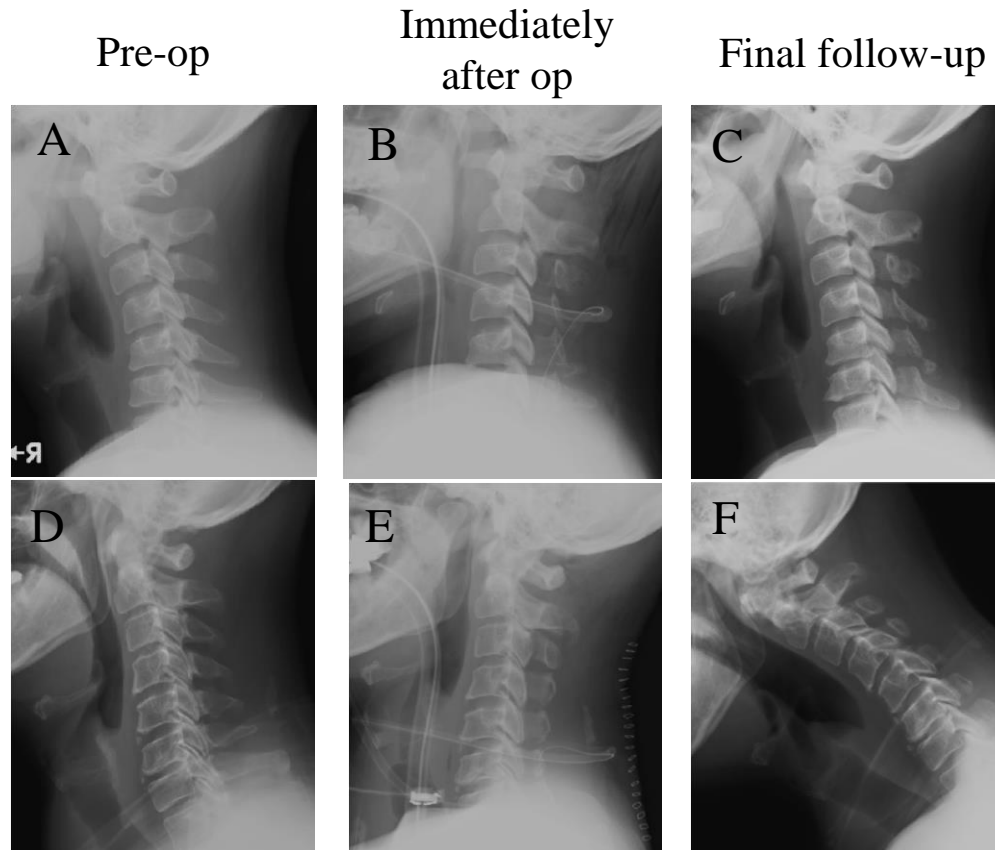
B



C

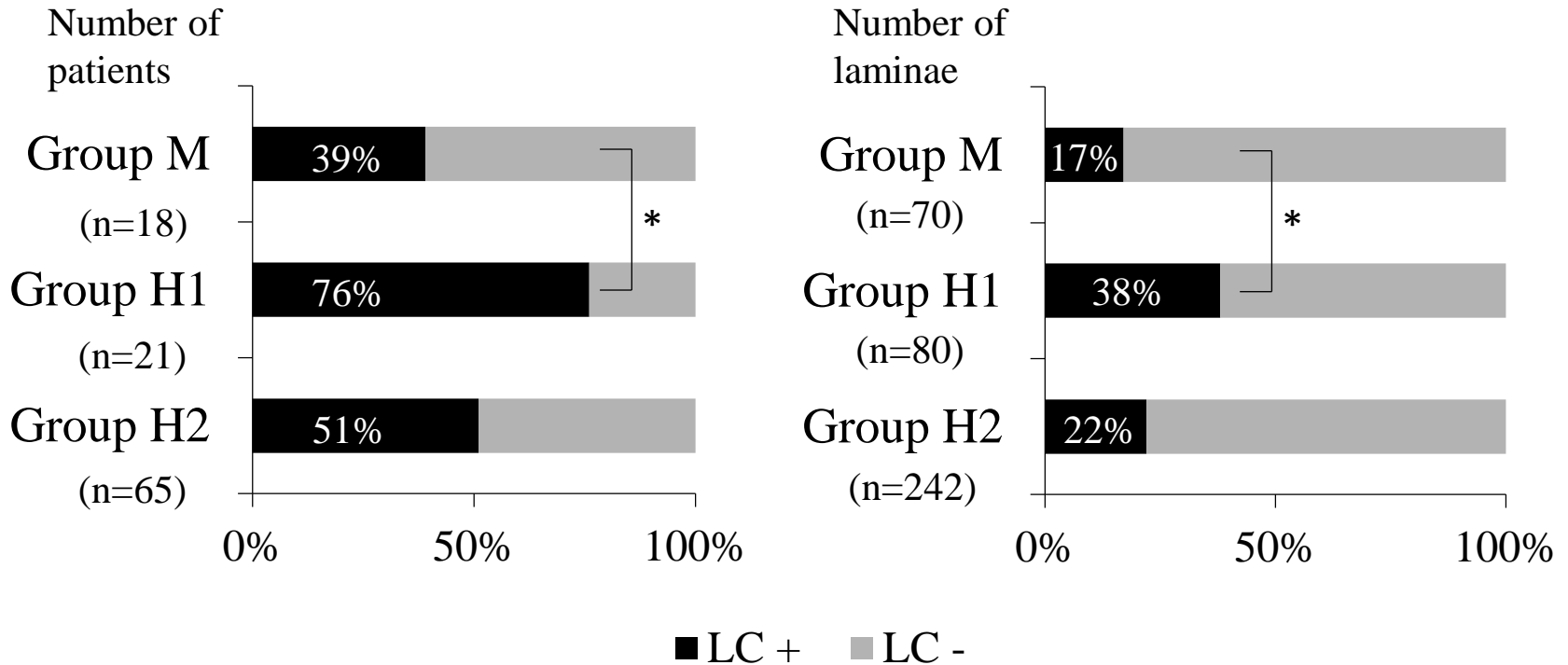


Modified open-door laminoplasty



Hirabayashi method

## Incidence of laminar closure



Group M: Modified open-door laminoplasty

Group H1: Hirabayashi open-door laminoplasty with preoperative lordosis  $\leq 10^\circ$

Group H2: Hirabayashi open-door laminoplasty with preoperative lordosis  $\geq 11^\circ$

LC: Laminar closure

\*  $P < 0.01$