

Xanthoma-like Skin Changes in an Elderly Woman with a Normal Lipid Profile

Dear Editor,

An 83-year-old woman developed yellow-brownish infiltrates, nodules, and tumors mimicking xanthomas, mostly involving the periorbital and chest area within three months (Figure 1). She had no abnormalities in serum cholesterol or triglycerides levels. A detailed laboratory analysis revealed the presence of mild monoclonal gammopathy with a presence of immunoglobulin G (IgG) kappa light chains; however, according to hematologist consultation, it did not require medical intervention. Imaging assessment and ultrasound examination did not show any specific involvement of internal organs. The skin biopsy demonstrated necrobiotic areas alternated with foci of xanthogranulomatous infiltration throughout the reticular dermis with extension into subcutaneous tissue. The granulomatous infiltrate was composed of epithelioid, foamy histiocytes in addition to conspicuous giant cells of the Touton type and foreign body type, as well as variable numbers of lymphocytes, plasma cells, and neutrophils. Lipid vacuoles were seen within the foci of necrobiosis and xanthogranulomatous infiltration (Figure 2). Two months af-

ter first admission to our department, the first signs of necrosis within the lesions were noted, and massive necrosis of skin lesions occurred after the following 5 months (Figure 1).

Based on the clinical manifestation and histological and laboratory findings, the diagnosis of necrobiotic xanthogranuloma (NXG) was established. In our patient, the extremely late onset of the disease, its very aggressive course, and the absence of malignant hematological disorder were remarkable. The general condition improved after local treatment and a low dose of prednisone. However, patient anamnesis revealed myocardial infarction in the past, congestive heart failure, and atrial fibrillation. Eventually, the patient died due to acute heart failure before alkylating agents could be administered; we consider the patient's death to have been unrelated to NXG.

NXG is a rare, chronic granulomatous disorder which was first described in 1980 by Kossard and Winkelmann (1). Currently, less than one hundred fifty cases of this syndrome have been reported in the

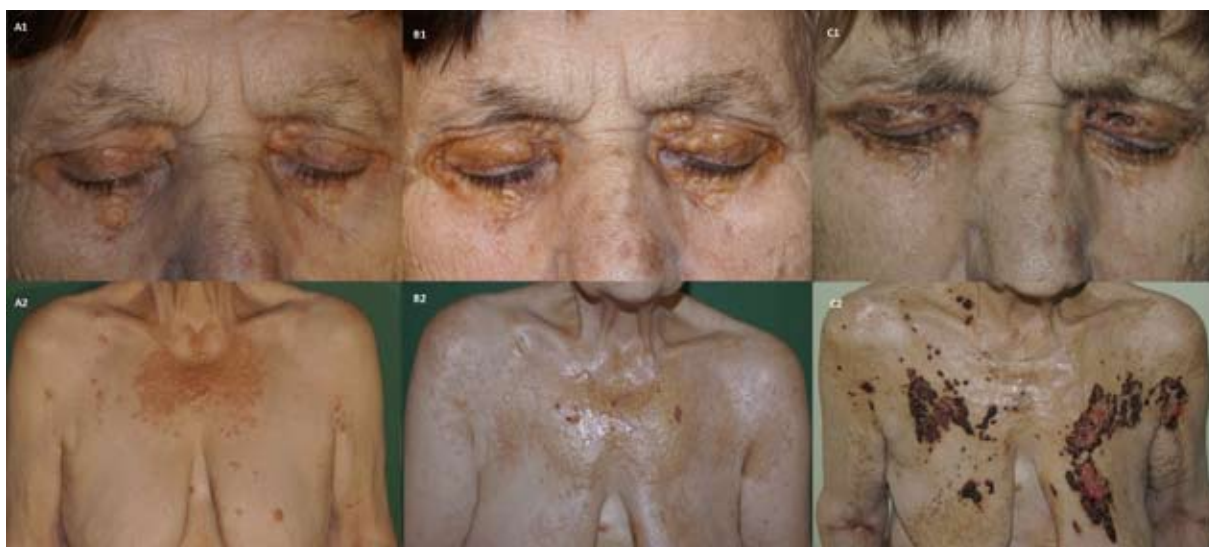

Figure 1. Skin changes by the first (a1, a2), second (b1, b2), and third hospitalization (c1, c2).

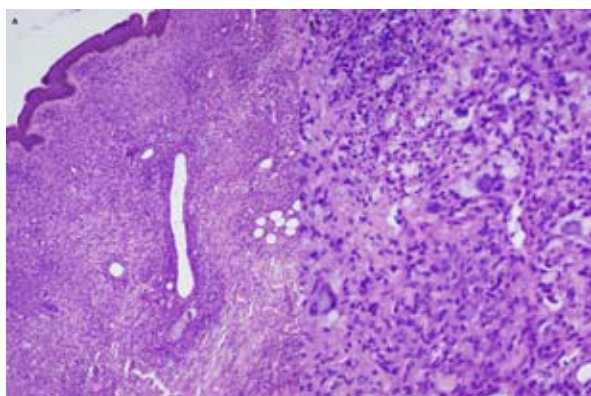


Figure 2. Hematoxylin-eosin stained skin biopsy specimen, magnification: $\times 100$ (a, survey) and $\times 400$ (b, detailed).

literature worldwide (2,3). The disease occurs during adulthood, slightly more frequently in women, and usually after the age of 60 years, although the youngest reported patient was 17 years old (3).

The disease initially manifests as xanthoma-like eruptions of yellowish or red-orange papules and nodules that coalesce into indurated plaques (4). The size of the lesions typically increases over time or with the next recurrences. In comparison to hyperlipemic and normolipemic xanthomas, the lesions are firmer, more prominent, and more polymorphic (3) with superficial telangiectasias, sometimes erythematous and/or violaceous borders, and atrophy (5). Ulcerations of the lesions were observed in about 50% of patients and tended to be extensive and progressive (4). Skin lesions of NXG can occur anywhere on the body. However, about two-thirds of patients had periorbital involvement, particularly on the upper and/or lower eyelids or elsewhere on the face. The second most commonly affected site was the trunk, predominantly the chest (3-6). However, many skin lesions first appear on the trunk or extremities and subsequently involve the periorbital area (4). More than one body area was affected in about 90% of the published cases (3,4). In individual cases, the occurrence of NXG was noted within scars, after trauma, or in a previously X-ray irradiated area (5). Lesions may be asymptomatic; however, over half of patients asked reported various symptoms, predominantly itching but also burning, tenderness, and even pain (4,5).

Periorbital skin lesions are often accompanied by ophthalmic manifestations, mainly scleritis, choroiditis, or conjunctivitis (3), and with complications such as blepharoptosis, restricted ocular motility, and proptosis (4,5). Extracutaneous lesions are most commonly seen in the respiratory tract, including the lungs and larynx, followed by the myocardium, oral cavity, skeletal muscles, kidneys, ovaries, intestine,

and other sites (5,6). Extracutaneous involvement was reported in less than 20% of cases (3), but its frequency seems to have increased in recent years (5).

Regarding laboratory abnormalities, the majority of patients with NXG (70% and up to 90% depending on the studied population) have a monoclonal gammopathy (more often IgG-kappa than IgG-lambda). Elevated erythrocyte sedimentation rate, anemia, leukopenia, low C1 and C4 levels, and cryoglobulinemia are also frequently present (3-6). Incisional biopsy is recommended to confirm the diagnosis of NXG, but correlations between the clinical presentation and specific histopathologic findings have been poorly characterized so far. The histopathology shows an inflammatory infiltrate composed of macrophages, foam cells, plasma cells, and other inflammatory cells as well as Touton and foreign body-type giant cells in the dermis and subcutaneous tissue. Necrobiosis is usually present, and nodular lymphoid aggregates are common. Cholesterol clefts or asteroid bodies are rare or absent. The epidermis may be atrophic or normal. Special stains are not helpful in establishing the diagnosis of NXG, but immunohistochemistry for CD68 is positive while it is always for CD1a and PS100 negative, like in non-X histiocytosis (4,5). In patients without a known myeloproliferative disorder, bone marrow biopsy may reveal atypical or increased plasma cells and, very rarely, true multiple myeloma (5).

As mentioned above, NXG can be a manifestation of multiple myeloma. However, chronic lymphocyte leukemia, B-cell lymphoma, and other lymphoproliferative diseases have also been reported in patients with NXG (3). Remarkably, hematological disorders may emerge many years before or after the onset of skin lesions (even up to 11 years) (4).

According to available literature data, the course of the disease is usually chronic and slowly progressive, and the prognosis is relatively good in the absence of co-occurrence of malignant hematological disorders (5-7). Aside from hyperlipemic and normolipemic xanthomas, the differential diagnosis of NXG includes multifocal necrobiosis lipoidica, granuloma annulare, foreign-body granuloma, juvenile xanthogranuloma, rheumatoid nodules, and amyloidosis (4). In 5 cases from the literature, xanthoma and NXG were present at the same time (3).

Despite several hypotheses, the etiopathogenesis of NXG remains unknown (3,4,8). For that reason and due to the rarity of the disease, the optimal therapy has not been defined. Frequently, chlorambucil or melphalan have been used alone or in combination with prednisone (4). Treatment may result in remission of symptoms on the skin, but it does not provide

a permanent cure (8). There are also single reports of the successful use of thalidomide, lenalidomide, cyclophosphamide, dexamethasone, interferon 2a and 2b, plasmapheresis and hydroxychloroquine, azathioprine, infliximab, and autologous bone marrow transplantation (3). Methotrexate seems to be ineffective (9). Local therapy, including local steroids, laser CO₂, or radiotherapy, results in partial improvement (3,4). Skin lesions which relapsed or were unresponsive to treatment could be excised surgically and the defects resurfaced with skin grafts. [2].

References:

1. Kossard S, Winkelmann RK. Necrobiotic xanthogranuloma with paraproteinaemia. *J Am Acad Dermatol* 1980;3:257-70.
2. Bortolani A, Barisoni D, Bontempini L. Necrobiotic xanthogranuloma of the eyelids with paraproteinemia. *Eur J Plast Surg* 1999;22:36-9.
3. Szalat R, Arnulf B, Karlin L, Rybojad M, Asli B, Malphettes M, *et al.* Pathogenesis and treatment of xanthomatosis associated with monoclonal gammopathy. *Blood* 2011;118:3777-84.
4. Wood AJ, Wagner VU, Abbott JJ, Gibson LE. Necrobiotic Xanthogranuloma. A Review of 17 Cases With Emphasis on Clinical and Pathologic Correlation. *Arch Dermatol* 2009;145:279-84.
5. Spicknall KE, Mehregan DA. Necrobiotic xanthogranuloma. *Int J Dermatol* 2009;48:1-10.
6. Mehregan DA, Winkelmann RK. Necrobiotic xanthogranuloma. *Arch Dermatol* 1992;128:94-100.
7. Granados ESR, Moya IM, López SV, Palazón LT, Reina AG. Extensive necrobiotic xanthogranuloma. *Eur J Intern Med* 2009;20:S58-S59.
8. Fernández-Herrera J, Pedraz J. Necrobiotic xanthogranuloma. *Semin Cutan Med Surg* 2007;26:108-13.
9. Goede JS, Misselwitz B, Taverna C, Schanz U, Dispenzieri A, Hummel Y, *et al.* Necrobiotic xanthogranuloma successfully treated with autologous stem cell transplantation. *Ann Hematol* 2007;86:303-6.

**Piotr Nockowski¹, Zdzisław Woźniak²,
Adam Reich¹, Joanna Maj¹**

¹*Department and Clinic of Dermatology, Venereology and Allergology, Wrocław Medical University, Wrocław, Poland*

²*Department of Pathomorphology, Wrocław Medical University, Wrocław, Poland*

Corresponding author:

Professor Joanna Maj, MD, PhD

Department and Clinic of Dermatology, Venereology and Allergology, Wrocław Medical University

Chałubińskiego 1

PL-50-368 Wrocław

Poland

joanna.maj@umed.wroc.pl

Received: June 29, 2016

Accepted: May 25, 2017