

## Antibiotic-induced Toxic Epidermal Necrolysis – A Case Report

Tino Klancir<sup>1</sup>, Višnja Neseck Adam<sup>1,2</sup>, Martina Matolić<sup>1</sup>, Elvira Grizelj Stojčić<sup>1</sup>, Maja Karaman Ilić<sup>1,2</sup>

<sup>1</sup>Department of Anesthesiology, Reanimatology and Intensive Care, Clinical Hospital Sveti Duh, Zagreb, Croatia; <sup>2</sup>Josip Juraj Strossmayer University of Osijek, School of Medicine, Osijek, Croatia

### Corresponding author:

Višnja Neseck Adam, MD  
Žerjavićeva 12  
10000  
Zagreb  
Croatia  
[visnja.nesek@hotmail.com](mailto:visnja.nesek@hotmail.com)

**ABSTRACT** Toxic epidermal necrolysis (TEN) is severe cutaneous hypersensitivity reaction characterized by necrosis of the epidermis and detachment of the epidermis and dermis that usually occurs as an idiosyncratic reaction to certain drugs. We report the case of a patient admitted to our Intensive Care Unit after an above-the-knee amputation who developed toxic epidermal necrolysis, possibly resulting from antibiotics therapy. Therapy included a combination of intravenous immunoglobulin with gentle early debridement of necrotic skin areas followed by wound coverage with a synthetic cover (Aquacel Ag<sup>®</sup>). This case report suggests that intensive wound management together with intravenous immunoglobulin might be beneficial in the treatment of patients with TEN.

Received: May 3, 2016

Accepted: January 10, 2017

**KEY WORDS:** toxic epidermal necrolysis, antibiotics, treatment

### INTRODUCTION

Toxic epidermal necrolysis (TEN) is a severe cutaneous hypersensitivity reaction characterized by necrosis of the epidermis and detachment of the epidermis and dermis followed by fever (1). When less than 10% of the skin is affected, the condition is called Steven-Johnson syndrome (SJS), and when affected skin covers 10%-30% of the body it is called SJS/TEN overlap. TEN is the most severe clinical manifestation of SJS that affects more than 30% of the patient's skin. Many groups of medications have been recognized as possible causes (2). Although the exact mechanism is unknown, it has been suggested that the main cause of TEN is damage to the metabolic pathway of the drug being used, which leads to accumulation of toxic drug metabolites. These metabolites may have direct toxic effects or may act as haptens that interact with host tissues (3,4). The incidence is 2-7 cases per million, and mortality rates range from approximately 20% to 60% (5,6). The Score for Toxic Epidermal

Necrolysis (SCORTEN) can be used to predict patient outcomes (7). Management of TEN requires prompt recognition and immediate withdrawal of all potential causative agents. Although there are no therapeutic guidelines regarding its management, and various treatment modalities have been suggested, such as corticosteroids, intravenous immunoglobulin therapy (IVIG), cyclosporine, cyclophosphamide, N-acetylcysteine, plasmapheresis, etc., admission to an intensive care unit (ICU) or burn center together with supportive measures and wound care are considered crucial in TEN treatment. It is known that adequate debridement of necrotic tissue with placement of wound coverage and admission to a burns or intensive care unit improves survival and reduces infection, whereas specific treatment with immunosuppressive drugs, corticosteroids, or immunoglobulin did not result improved outcomes in most studies and remains controversial (8).

As mentioned previously, no standard guidelines exist for the management of TEN, but recently published articles pointed out that combination treatment with systemic steroids and immunoglobulin as well as supportive treatment seems to have contributed to an evident prognostic improvement and remarkable recovery (9-11).

This case report highlights the importance of intensive wound care and also suggests that IVIG might be beneficial in the treatment of patients with TEN.

### CASE REPORT

A 77-year-old female was admitted to our hospital to an Internal Medicine Department with fever and severe right limb infection after transmetatarsal amputation. She had a medical history of hypertension, hyperlipidemia, diabetes mellitus type II, supraventricular and ventricular extrasystolia, and severe atherosclerosis. Further investigations showed inflammatory syndrome, anemia, uroinfection, and mild renal impairment, a consequence of fever and dehydration in the context of diabetes.

Based on the ambulatory-based antibiogram, first-line antibiotic treatment with vancomycin at 2 g/day was continued for a total of 13 days, followed by piperacillin-tazobactam 2.25 g IV q8h for the next 15 days. After that, the antibiotics were excluded from the therapy because inflammatory markers were normal and the patients had no fever. However, despite early targeted antimicrobial therapy and serial surgical debridement of the infected tissues, the

patient's general condition gradually deteriorated. She became febrile again with elevated C-reactive protein (CRP) and white blood cell count. Cultures of swabs obtained from the infected areas revealed methicillin-resistant *Staphylococcus aureus* (MRSA) and *Citrobacter freundii* which was resistant to piperacillin-tazobactam but sensitive to meropenem. The therapy with intravenous meropenem at 3 g/day and again with vancomycin at 2 g/day was started. After surgical examination and consultation, a transfemoral amputation was recommended. A preoperative assessment was performed on the patient by the consultant anesthetist. Clinical examination revealed multiple confluent macular erythema and bullous detachment of the epidermis over the face, trunk, and extremities, but predominantly on the chest and back. An otorhinolaryngologist who was consulted because of sore throat and swallowing difficulty noticed multiple painful buccal aphthous-like ulcerations. Above-knee amputation was performed 2 days later under general anesthesia. After surgery, the patient was admitted to the ICU. She was in poor general condition upon admission: febrile with a temperature of 38.5 °C, pulse between 120/140/minute and with CRP 251 mg/L. During the patient's stay in the ICU, skin lesions continued to progress; and epidermal detachment progressed over the next two days, and macular erythema and bullous skin lesions affected more than 50% of the total body surface area (TBSA) (Figure 1 and 2). Severe oral involvements also continued to progress in the form of

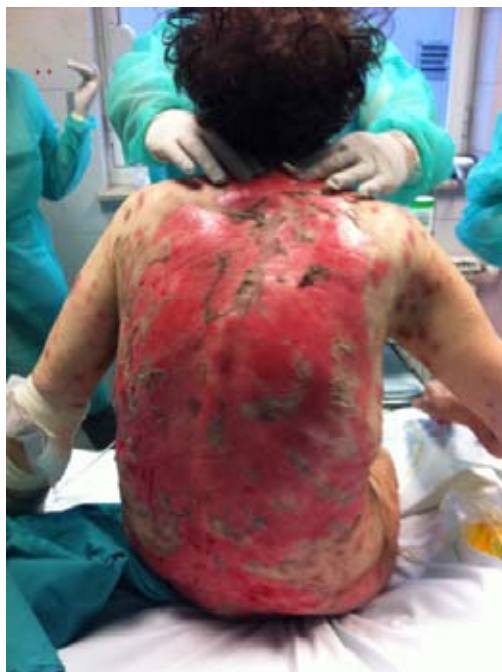

Figure 1. Peeling of the affected skin.

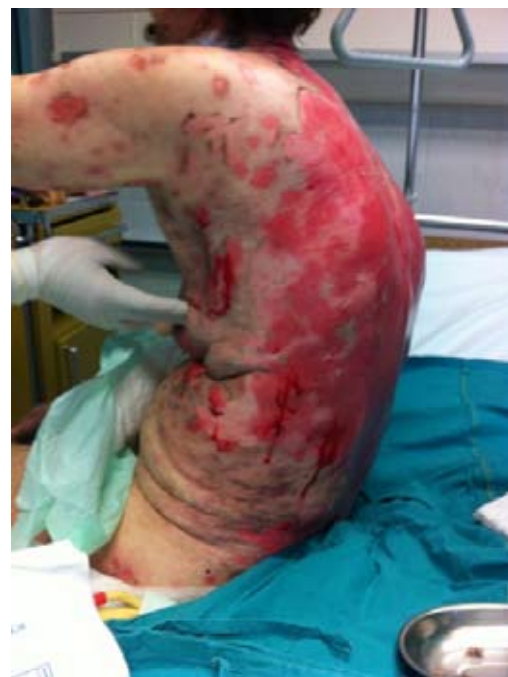
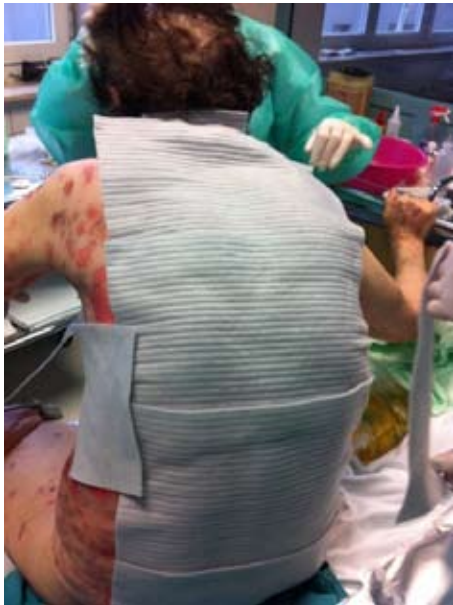
Figure 2. Peeling of the affected skin.

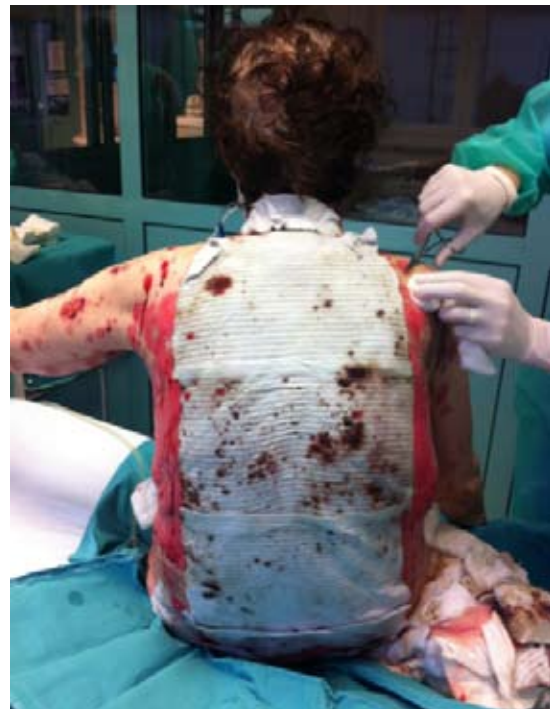

**Figure 3.** Lining placement.

painful hemorrhagic erosions and crusting over the lips, restricting her oral intake. The rapid progression of the oral erosions and desquamation on most of the patient's body surface area led us to suspect TEN as the diagnosis. Since it was assumed that the antibiotics caused TEN, all antibiotics were excluded from the therapy. Because of the severity of TEN – the SCORTEN score was 4 (Age >40, glucose >250 mg/dL, heart rate >120/min, compromised body surface >10%) indicating a 58.3% mortality rate – the patient was given intravenous immunoglobulin therapy 1 g/kg over 3 days. She also received fluid resuscitation, and the wounds were treated with Aquacell® Ag (ConvaTec) and vaseline gauzes (Figure 3 and 4). The dressings were changed periodically following cleaning with saline and gentle debridement of exfoliated epidermis (Figure 5 and 6). After 15 days of local therapy, almost full re-epithelialization was achieved (Figure 7 and 8), and the patient was generally in good condition, without active inflammatory changes. A few days later, despite improvement, she developed a sudden bradycardia that did not respond to reanimation procedures. The patients died after 18 days in the ICU from a massive heart attack, according to autopsy reports.

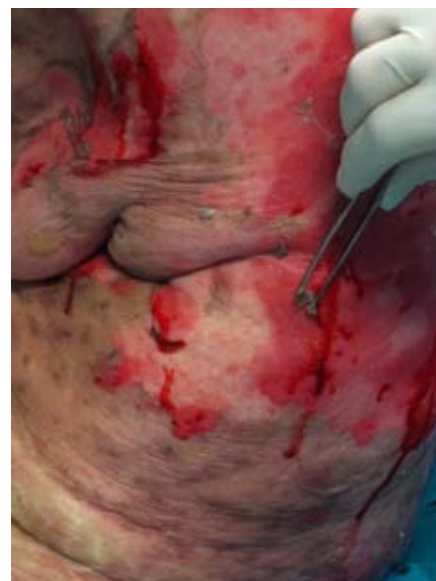### DISCUSSION

TEN is a severe life-threatening pathological syndrome with a high mortality rate. Half of the deaths occur due to the secondary infection and subsequent sepsis and multi-organ system failure. As mentioned above, the pathogenesis of TEN is not fully understood but is believed to be an immune-related cyto-

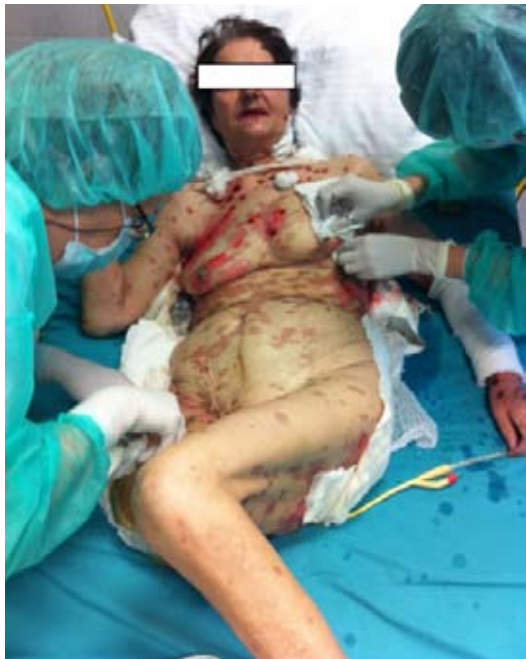

**Figure 4.** Lining placement.

toxic reaction against the offending drug or its metabolites. Drugs can stimulate the immune system by binding directly and reversibly to immune receptors. The prevalence of antibiotics being responsible for TEN ranges from 29% to 42% (12). Almost all antibiotics have been implicated, but beta-lactam and sulfonamide are most commonly associated with TEN, and TEN usually develops within the first week of antibiotic therapy. In our case, TEN was diagnosed based on the clinical picture, and drugs we most suspected as the cause were antibiotics, due to the direct relation



**Figure 5.** Removal of dead skin.

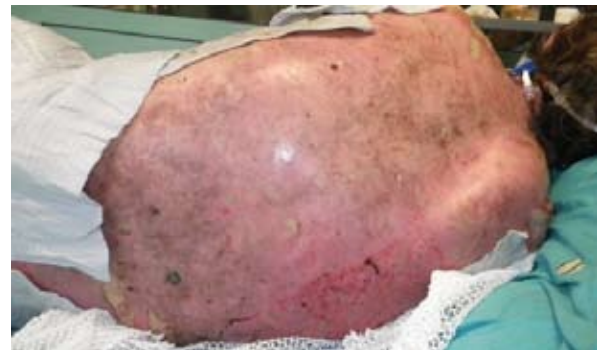


**Figure 6.** Removal of dead skin.

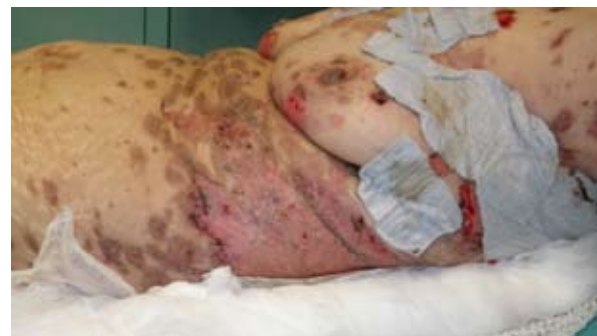between the onset of the disease and the administration of an antibiotic. Our patient received antibiotics three days before the full clinical picture was evident. However, since the patient was receiving multiple antibiotics, it was difficult to determine which antibiotic was causing the skin reaction. An improvement in the general condition of our patient after the withdrawal of antibiotics may provide indirect evidence for a causative role of antibiotics as a potential agent for TEN in our case.

At the present time there is no uniform therapeutic strategy for TEN, but recommendations are mostly conservative, so based on previous work and suggested recommendations we chose to treat the patient with the combination of intravenous immunoglobulin and regular and meticulous wound care. It appears that aggressive debridement should be restricted unless absolutely necessary. For regular wound care we used Aquacel Ag<sup>®</sup> – a primary wound dressing containing 1.2% silver in an ionic form distributed throughout the entire hydrofiber material. It is well known that silver ions possess potent broad-spectrum antibacterial properties. The use of Aquacel Ag<sup>®</sup> in the local treatment of the patient resulted in faster epithelization of the skin surface and decreased fluid loss through skin layers.

Despite controversy about the benefit on the use of IVIG, rapid progression of the skin lesions resulted in our ICU team's decision to treat the patient with IVIG. An objective response to IVIG infusion was observed within 48 h, and reepithelization was almost



**Figure 7.** Re-epithelialization



**Figure 8.** Re-epithelialization

fully achieved after 15 days of combination of local therapy and IVIG.

The action mechanism of IVIG is complex and involves several mechanisms. One of proposed mechanisms involves the inhibition of keratinocyte death. Apoptotic keratinocyte cell death leads to separation of the epidermis from the dermis, with subsequent desquamation of skin. The rationale for using IVIG in patients with TEN is to block keratinocyte apoptosis. Namely, a significant increase in immunoglobulin G (IgG) concentration in the serum, blister fluid, and epidermis was found in patients being treated with IVIG. Elevated levels of IgG were found in clinically affected and unaffected skin, which means that IVIG has both systemic and local effects (13).

## CONCLUSION

Our case report shows that antibiotics are capable of inducing fatal adverse effects such as TEN and suggests that it might be beneficial to use a combination of Aquacel Ag<sup>®</sup> and IVIG in the treatment of patients with TEN. Use of Aquacel Ag<sup>®</sup> helps rapid re-epithelization and prevents wound infection.

## Consent

Verbal informed consent was obtained from the patient for the publication of this case report and the accompanying images.

## References:

1. Harr T, French LE. Toxic epidermal necrolysis and Steven-Johnson syndrome. *Orphanet J Rare Dis* 2010;5:39-50.
2. Bastuji-Garin S, Rzany B, Stern RS, Shear NH, Naldi L, Roujeau JC. Clinical classification of cases of toxic epidermal necrolysis, Stenes-Johnson syndrome, and erythema multiforme. *Arch Dermol* 1993;129:92-6.
3. Brambilla G, Brucato F, Angrisano A, Palmieri G. Treatment of toxic epiderma necrolysis (TEN). *Ann Burns Fire Disast* 2002;15:17-21.
4. Frisch PO, Ruiz-Maldonado R. Erythema multiforme, Stevens-Johnson syndrome and toxic epidermal necrolysis. In: Freedberg IM, Eisen AZ, Wolff K, Austen KF, Goldsmith LA, Katz SI, eds. *Fitzpatrick's dermatology in general medicine*. 6th ed. New York: McGraw-Hill; 2003. pp. 543-57.
5. Rzany B, Mockenhaupt M, Baur S, Schröder W, Stocker U, Mueller J, *et al.* Epidemiology of erythema exsudativum multiforme majus, Stevens-Johnson syndrome, and toxic epidermal necrolysis in Germany (1990-1992): structure and results of a population-based registry. *J Clin Epidemiol* 1996;49:769-73.
6. Sekula P, Dunant A, Mockenhaupt M, Naldi L, Bouwes Bavinck JN, Halevy S, *et al.* Comprehensive survival analysis of a cohort of patients with Stevens-Johnson syndrome and toxic epidermal necrolysis. *J Invest Dermatol* 2013;133:1197-204.
7. Bastuji-Garin S, Fouchard N, Bertocchi M, Roujeau JC, Revuz J, Wolkenstein P. SCORTEN: a severity-of-illness score for toxic epidermal necrolysis. *J Invest Dermatol* 2000;115:149-53.
8. Stevens Johnson Syndrome and Toxic Epidermal Necrolysis (Internet). *DermNet NZ*. 2016 (cited 2016 Apr 10). Available from: <http://www.dermnetnz.org/topics/stevens-johnson-syndrome-toxic-epidermal-necrolysis/>
9. Yamane Y, Matsukura S, Watanabe Y, Yamaguchi Y, Nakamura K, Kambara T, *et al.* Retrospective analysis of Stevens-Johnson syndrome and toxic epidermal necrolysis in 87 Japanese patients - Treatment and outcome. *Allergol Int* 2016;65:74-81.
10. Huang JJ, Ma SX, Hou X, Wang Z, Zeng YD, Qin T, *et al.* Epidermal necrolysis related to AP (pemetrexed plus cisplatin) and gefitinib combination therapy in a patient with metastatic non-small cell lung cancer. *Chin J Cancer* 2015;34:94-8.
11. Jagadeesan S, Sobhanakumari K, Sadanandan SM, Ravindran S, Divakaran MV, Skaria L, *et al.* Low dose intravenous immunoglobulins and steroids in toxic epidermal necrolysis: A prospective comparative open-labelled study of 36 cases. *Indian J Dermatol Venereol Leprol* 2013;79:506-11.
12. Schöpf E, Stühmer A, Rzany B, Victor N, Zentgraf R, Kapp JF. Toxic epidermal necrolysis and Stevens-Johnson syndrome. An epidemiologic study from West Germany. *Arch Dermatol* 1991;127:839-42.
13. Paquet P, Kaveri S, Jacob E, Pirson J, Quatresooz J, Piérard GE. Skin immunoglobulin deposition following intravenous immunoglobulin therapy in toxic epidermal necrolysis. *Exp Dermatol* 2006;5:381-6.