

## *Iliopsoas Release for Internal Snapping Hip using a Minimally Open Medial Hip Approach-Case Report*

**Fernando Judas\*<sup>1</sup>, Gisela Eugénio<sup>2</sup>, Pedro Carvalho<sup>2</sup>, Marcos Carvalho<sup>3</sup>, Jorge Faísca<sup>1</sup>**

<sup>1</sup>Orthopaedic Surgeon, Department of Orthopaedics, University of Coimbra, Centro Hospitalar e Universitário de Coimbra (CHUC), Portugal

<sup>2</sup>Fellow of Rheumatology, Rheumatology Department, University of Coimbra, Centro Hospitalar e Universitário de Coimbra (CHUC), Coimbra, Portugal

<sup>3</sup>Fellow of Orthopaedics, Department of Orthopaedics, University of Coimbra, Centro Hospitalar e Universitário de Coimbra (CHUC), Coimbra, Portugal

**\*Corresponding author:** Judas F, Orthopaedic Surgeon, Department of Orthopaedics, University of Coimbra, Centro Hospitalar e Universitário de Coimbra (CHUC), Portugal, E-mail: fernandojudas@gmail.com

**Received:** February 28, 2017; **Revised:** March 18, 2017; **Published:** April 07, 2017

**Copyright:** © 2017 Judas F, et al. This is an open-access article distributed under the terms of the Creative Commons Attribution License, which permits unrestricted use, distribution, and reproduction in any medium, provided the original author and source are credited. The article has been previewed and authenticated by the Authors before sending the publication for print. The Journal, Editor and the Editorial Board are not entitled or liable to either justify or responsible for inaccurate and misleading data if any. It is the sole responsibility of the Author concerned.

**Citation:** Judas F, Eugenio G, Carvalho P, et al. Iliopsoas Release for Internal Snapping Hip using a minimally open medial hip approach - Case Report. *Int J Gen Med Surg* 2017; 1: 101.

### Abstract

*Internal snapping hip is a recognized cause of hip pain caused by recurrent subluxation of the iliopsoas tendon. When conservative treatment fails, surgical release of the iliopsoas tendon may be indicated using an arthroscopic or open hip approach. Results have been better with arthroscopic release. We report a case of a 32-year-old active female with a painful internal snapping hip. The right hip extension from a flexed position produced a strong and audible snap. A tenotomy of the iliopsoas in combination with a resection of the lesser trochanter was performed, using a limited medial hip approach different than the one described by Ludloff or Ferguson. The pain and snapping phenomenon were solved; however, a slight heterotopic ossification, as well as a weakness in the flexion of the hip was noted after the procedure, with no functional limitation. The minimally invasive medial hip approach appears to be a simple, reproducible and successful operation for the treatment of an internal snapping hip caused by the iliopsoas tendon, namely in orthopaedics departments with limited experience in hip arthroscopic approach, but it is not superior to arthroscopic release.*

**Keywords:** *Internal snapping hip, Iliopsoas tendon, Minimally invasive surgery*

### Introduction

The internal and external snapping hip syndromes usually affect women between 15 and 40 years and ballet dancers. Snapping hip syndrome is defined by recurrent clicks or

*Judas F, et al. Int J Gen Med Surg*

snaps during active motion of the hip. Occasional painless snaps may be felt by patients with normal hips which, in turn, should not be regarded as pathologic. Internal snapping hip syndrome ("internal coxa

*saltans*") is caused by iliopsoas tendon snapping over the iliopectineal eminence or the femoral head [1,2].

The snapping phenomenon, which is always voluntary and reproducible, is frequently heard. This audible snap may be accentuated by the abduction and external rotation when flexing the hip, and/or by adducting and internally rotating while extending the hip [3]. It has been documented that more than half of patients with internal snapping hip syndrome have intra-articular hip pathology [4].

The diagnosis is usually based on history and clinical examination findings. The first-line treatment for iliopsoas disorders is typically conservative, including activity modification, physical therapy, nonsteroidal anti-inflammatory drugs (NSAIDs), and corticosteroid injections. After failure of conservative treatment, surgical release of the iliopsoas tendon may be indicated using an arthroscopic or open hip approach [5].

This report aimed to describe a case of painful internal snapping hip syndrome treated by iliopsoas release, using a minimally invasive medial hip approach.

## Clinical Report

A 32-year-old female, domestic worker, presented with a 3-year history of painful snapping of the right hip. Otherwise, her medical history was unremarkable. Intense physical therapy and NSAIDs were prescribed, without apparent improvement. Her body mass index was 27.2 Kg/m<sup>2</sup>, and the remaining physical examination confirmed a painful internal snapping hip probably caused by the iliopsoas tendon, discarding a possible intra-articular pathology. Anterior and posterior femoroacetabular impingement tests were negative, but a strong and audible snap was reproduced when extending the hip from a flexed position of more than 90 degrees. The painful snap occurred at approximately 25° of flexion, simultaneously causing an apprehensive response from the patient. Rotation of the hip joint did not affect the result of the test. Furthermore, the presence of an ischiofemoral impingement was also admitted by hip pain and snapping sensation.

Pelvis and hip joint X-rays (anteroposterior and lateral views), were normal. Hip computerized tomography scan and magnetic resonance imaging revealed the presence of a dystrophic calcification of the soft parts adjacent to the lateral acetabular contour.

A tenotomy of the iliopsoas tendon in combination with a resection of the lesser trochanter were then performed, using a minimally open medial hip approach according Chiron et al. [6]: (1) the patient was positioned in dorsal decubitus, with the hip in flexion-abduction-external rotation, in the so-called "frog-leg" position; (2) a 6 cm medial incision was made in the groin fold, with 2 to 3 cm from the pubic tubercle which followed the tendon of the adductor longus muscle; (3) the aponeurosis of the adductor longus was incised, taking into account the femoral vascular pedicle, and the lesser trochanter was identified by blunt dissection; (4) the iliopsoas tendon was isolated and cut while the lesser trochanter was removed using bone osteotomes; (5) a drain was placed, and the wound closed (**Figure 1**, **Figure 2**).

No complications were reported in the perioperative period. A limitation on the flexion of the hip was present after surgery but improved within 10 weeks. At 3 months of surgery, the patient reported no hip pain neither snapping phenomenon. The hip radiograph only showed a discrete heterotopic ossification at the level of the removed less trochanter.

Although a slight weakness on the flexion of the hip remained, after 8 months, she was very satisfied with the result of the surgery. She was able to walk and jog with minimal discomfort in her hip.

## Discussion

Symptomatic internal snapping hip syndrome always presents with pain in the groin associated with a snapping phenomenon. Diagnosis typically relies in specific manifestations and physical examination. The snapping phenomenon cannot be documented using magnetic resonance arthrography, but some findings related to iliopsoas tendonitis or bursitis may occasionally be reported [3]. In our case the patient had a strong and audible snap in the right hip with positive iliopsoas test.

Surgical correction of snapping was considered after failure of conservative treatment.

Surgery involves either a release of the iliopsoas tendon or a lengthening of the muscle-tendon unit. The release of the iliopsoas can be performed at three different levels - at the insertion of the tendon on the lesser trochanter, from the central compartment or the hip periphery. This technique provides long-term relief from a painful internal snapping hip [7].

Early surgical techniques designed to treat painful internal *coxa saltans* were open procedures which have been associated with a high rate of complications. Better results have been demonstrated with arthroscopic release of the iliopsoas tendon [7,8]. This technique avoids complications of open surgery, and allows the treatment of concomitant intra-articular pathologies including femoroacetabular impingement and labral tears [4].

Nevertheless, the medial open hip approach described by Chiron et al. [6], is minimally invasive, safe, and provides the surgeon with a good exposure of the tendon. The risk of neurovascular complications is minimal if a blunt dissection behind the adductor longus aponeurosis is respected. This is a different approach without the pitfalls and complications of the Ludloff or Ferguson method, namely sensory nerve injuries caused by surgical dissection.

Various surgical approaches have been proposed for the open treatment of the painful internal *coxa saltans*. To our knowledge, iliopsoas release through a minimally invasive medial approach has not been sufficiently described in the orthopaedic literature. Chiron reported a series of 56 cases, with no major complications: this approach allows treatment of iliopsoas muscle lesions and resection or filling of benign tumours of the cervical region and enables intra-articular surgery (arthrolysis, resection of osteophytes or foreign bodies, labral suture) [6]. This approach can also be performed in the treatment of psoas impingement with an acetabular prosthesis,

although no clinical case has been described until now.

Given the difficulty of excluding an ischiofemoral impingement, a decompression of the ischiofemoral space by resecting the lesser trochanter was carried out. Ischiofemoral impingement has become an increasingly recognized extracapsular cause of atypical hip, deep gluteal, and groin pain. The symptoms and clinical findings are often non-specific, including the hip snapping sensation [9].

During follow-up a discrete heterotopic bone formation was found at the level of the lesser trochanter, despite prophylaxis with indomethacin 75 mg per day (**Figure 3**). This condition has been associated with the release of the iliopsoas tendon both in open and endoscopic release.

In our case, a slight limitation of hip flexion was present after surgery, although it improved within 10 weeks. Despite it has been documented that the iliopsoas tenotomy done at the lesser trochanter did not result in chronic weakness [10], the patients should be told about the inevitable weakness of hip flexion, and the need for rehabilitation as also as a period of crutch use.

The minimally invasive medial hip approach appears to be a useful operation for the treatment of an internal snapping hip caused by the iliopsoas tendon, and for the treatment of an ischiofemoral impingement. This hip approach passes between the adductor muscle bellies posteriorly and their aponeuroses anteriorly. It provides direct access to the lesser trochanter and the iliopsoas tendon. Other medial approaches require painstaking dissection of anterior or posterior obturator nerve structures, and provide inadequate visualization.

It's important to emphasize that minimally invasive medial hip approach is applicable when there is a limitation in arthroscopic experience, but it is not superior to arthroscopic release.

## Conclusion

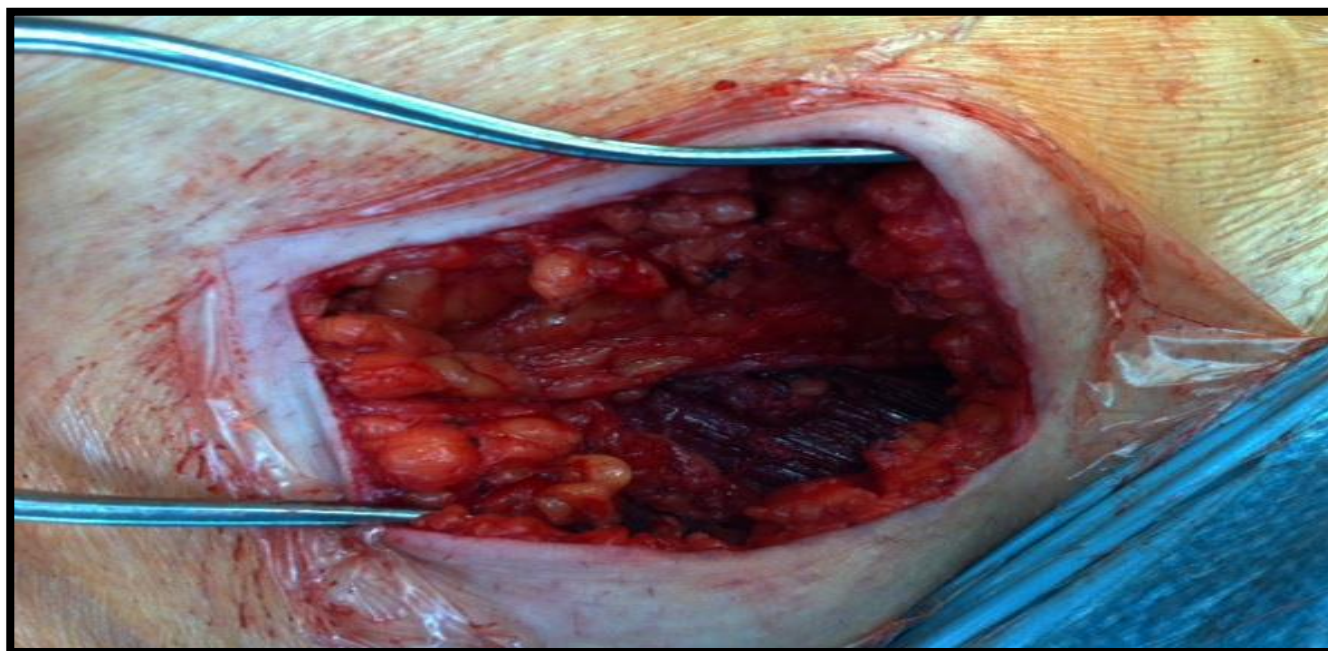
The minimally invasive medial hip approach can be regarded as an easy, reproducible, non-time-consuming, safe and successful surgical approach for the treatment of internal snapping caused by iliopsoas tendon.

## Conflict of Interest

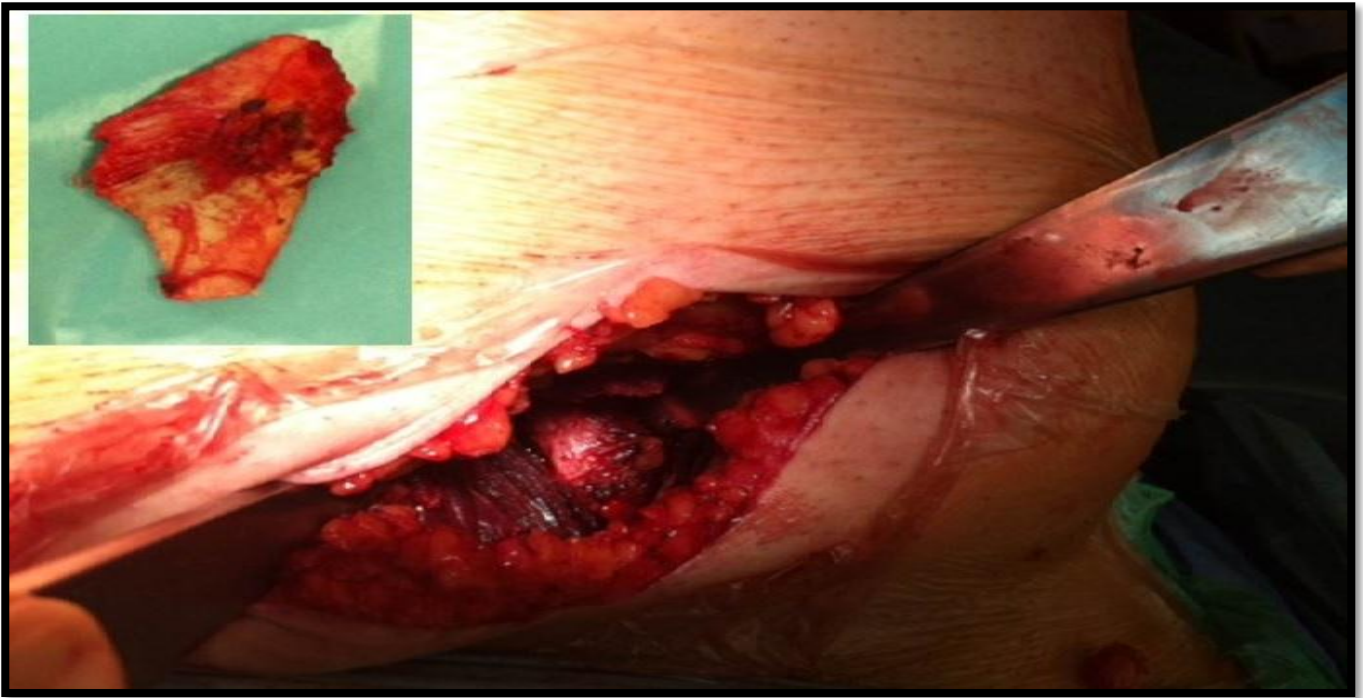
The authors declare that they have no competing interests.

## References

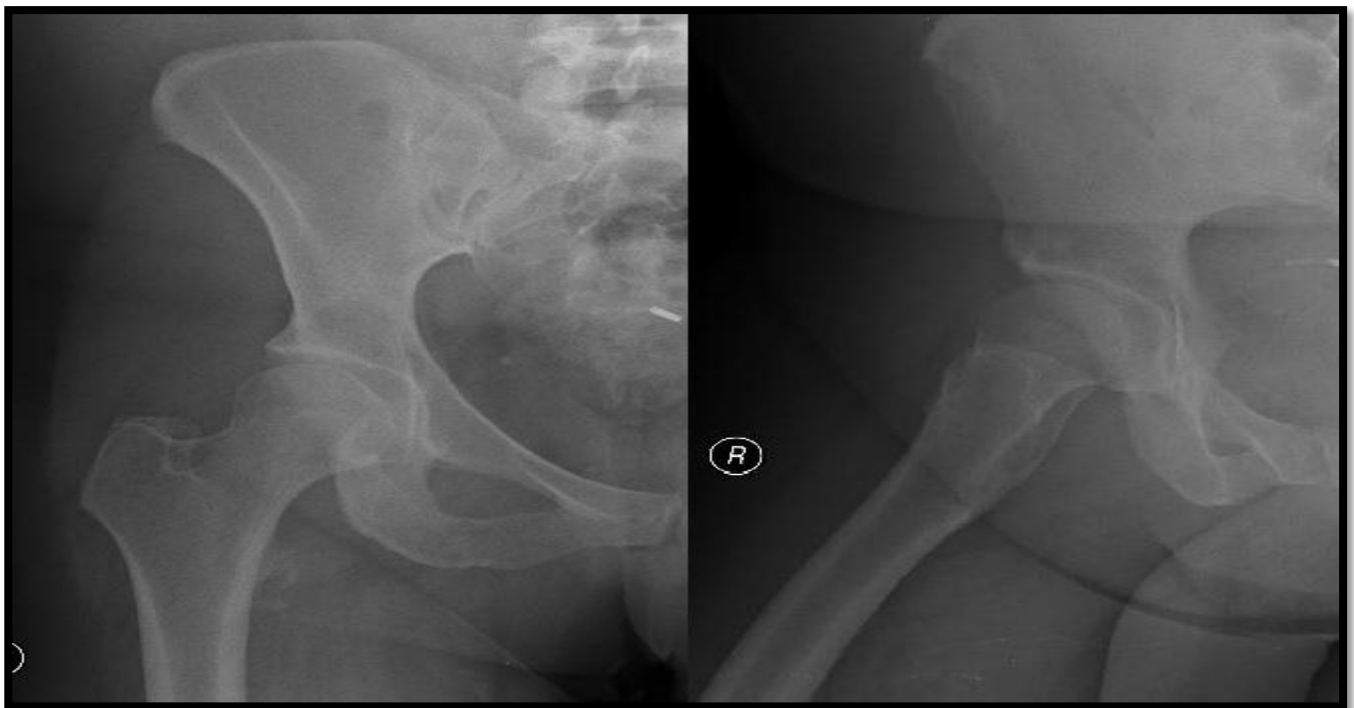
1. Ward WT, Fleisch ID, Ganz R. Anatomy of the iliocapsularis muscle: relevance to surgery of the hip. *Clin Orthop Relat Res* 2000; 374: 278-285.
2. Taher RT, Power RA. Iliopsoas tendon dysfunction as a cause of pain after total hip arthroplasty relieved by surgical release. *J Arthroplasty* 2003; 18: 387-388.
3. Ilizaliturri VM. Endoscopic iliopsoas release for internal snapping hip syndrome. *Orthopedics Today* 2011.
4. Kroger EW, Griesser MJ, Kolovich GP, et al. Efficacy of surgery for internal snapping hip. *Int J Sports Med* 2013; 34: 851-855.
5. Anderson CN. Iliopsoas: Pathology, Diagnosis, and Treatment. *Clin Sports Med*. 2016; 35: 419-433.
6. Chiron P, Murgier J, Cavaignac E, Pailhé R, Reina N. Minimally invasive medial hip approach. *Orthop Traumatol Surg Res* 2014; 100: 687-689.
7. Flanum ME, Keene JS, Blankenbaker DG, et al. Arthroscopic treatment of the painful “internal” snapping hip results of a new endoscopic technique and imaging protocol. *Am J Sports Med* 2007; 35: 770-779.
8. Polesello GC, Pereira Guimarães R, Ricioli Júnior W, et al. Possibilidades atuais da artroscopia do quadril. *Revr Bras Ortop*. 2014; 49: 103-110.
9. Howse EA, Mannava S, Tamam C, et al. Ischiofemoral space decompression through posterolateral approach: cutting block technique. *Arthrosc Tech* 3: 661-665.
10. Anderson SA, Keene JS. Results of arthroscopic iliopsoas tendon release in competitive and recreational athletes. *Am J Sports Med* 2008; 36: 2363-2371.



**Figure 1:** With the hip joint in frog's-leg position, the aponeurosis of the adductor longus muscle is incised. A slide plan between all of the adductors and the aponeurosis is easily released by blunt dissection, giving access to the lesser trochanter and psoas tendon



**Figure 2: Iliopsoas tenotomy and resection of the lesser trochanter were performed, using this minimally surgical approach**



**Figure 3: Postoperative hip radiograph showing a discrete heterotopic ossification at the level of the removed lesser trochanter**

*This manuscript was peer-reviewed*

*Mode of Review: Single-blinded*

*Editor: Dr. Shawqi Arafat*

*International Journal of General Medicine & Surgery is an open access, peer reviewed journal published by Edwiser International.*

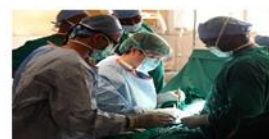*Submit your valuable manuscript at:  
[editor.ijgms@edwiserinternational.com](mailto:editor.ijgms@edwiserinternational.com)  
[submit.manuscript@edwiserinternational.com](mailto:submit.manuscript@edwiserinternational.com)*



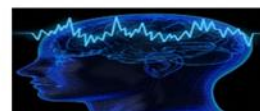**International Journal of  
Pharmaceutics & Pharmacology**



**International Journal of  
General Medicine & Surgery**



**International Journal of Trauma,  
Acute Care & Surgery**



**International Journal of Advances  
in Gynecology & Obstetrics**



**International Journal of Research  
& Clinical Trials**

