



Title	An unexpected journey of a suction catheter in a preterm neonate
Author(s)	Leung, L; Chung, PHY; Wong, KKY; Tsoi, NS; Lee, RSY
Citation	Journal of Pediatric Surgery Case Reports, 2015, v. 3 n. 9, p. 364-366
Issued Date	2015
URL	http://hdl.handle.net/10722/241731
Rights	This work is licensed under a Creative Commons Attribution-NonCommercial-NoDerivatives 4.0 International License.



An unexpected journey of a suction catheter in a preterm neonate

Ling Leung^a, Patrick Ho Yu Chung^a, Kenneth Kak Yuen Wong^{a,*}, Nai Shun Tsoi^b, Robert Shing Yan Lee^c



^a Division of Pediatric Surgery, Department of Surgery, The University of Hong Kong, Queen Mary Hospital, Pokfulam Road, Hong Kong

^b Department of Pediatrics and Adolescent Medicine, The University of Hong Kong, Queen Mary Hospital, Hong Kong

^c Department of Pediatrics and Adolescent Medicine, Pamela Youde Nethersole Eastern Hospital, Hong Kong

ARTICLE INFO

Article history:

Received 8 June 2015

Received in revised form

2 July 2015

Accepted 3 July 2015

Key words:

Foreign body

Premature infant

Endotracheal intubation

ABSTRACT

Foreign bodies are extremely rare in preterm neonates. The majority are iatrogenic. We describe a neonate of 27 weeks gestation who was found to have an 18 mm long suction catheter at the right main bronchi after resuscitation in another hospital. It was first detected by chest X-ray after endotracheal intubation. Repeat X-ray revealed the catheter moved to the stomach and migrated to the lower gastrointestinal tract in a few hours. The patient was treated conservatively and the catheter was passed out on day 14. Newborn resuscitation may result in iatrogenic foreign body in neonates. Serious complications such as respiratory compromise, perforations or abscess may occur. Early referral to a specialized tertiary center with pediatric surgical service is recommended. We hope our experience demonstrated the importance of preventing iatrogenic foreign body in clinical setting. Access to endoscopic instrumentation for foreign body removal in preterm neonates should be available at all times.

© 2015 The Authors. Published by Elsevier Inc. This is an open access article under the CC BY-NC-ND license (<http://creativecommons.org/licenses/by-nc-nd/4.0/>).

Foreign bodies are extremely rare in preterm neonates. The majority of the reported cases are iatrogenic and the foreign bodies were derived from medical devices [1–5]. Potential serious complications such as respiratory compromise, esophageal and gastrointestinal tract perforation may occur [6]. Prompt management to retrieve foreign body by endoscopic instrument or open method is required if there are signs of these complications. For small foreign body that is able to pass through the pylorus, it is possible to observe for spontaneous passage through anus. We describe an unusual journey of suction catheter that migrated from the right bronchus to the gastrointestinal tract and was eventually passed with meconium in a preterm neonate.

A dichorionic diamniotic twin two was born by emergency cesarean section for placenta abruption at 27 weeks of gestation. He had a birth weight of 1.16 kg, Apgar score was 3 at 1 min and 1 at 5 min. He developed bradycardia at birth requiring endotracheal intubation and cardiopulmonary resuscitation for 1 min. Surfactant replacement was given because of severe respiratory distress syndrome of prematurity. A close circuit suction system (Kimvent

5Fr multi-access catheter, Kimberley-Clark, Atlanta, USA) was used while patient was receiving mechanical ventilation. He was extubated to non-invasive ventilation at 18 h of life. Chest X-ray at 21 h revealed an obliquely-oriented tubular opacity over medial aspect of right lower zone (Fig. 1).

Computer tomography of thorax on day two of life showed an intraluminal elongated tubular foreign body measuring about 1.9 × 1.9 mm across and 18.0 mm in length at right bronchus (Fig. 2). Collapse was noted at the right lower lobe superior segment. Consolidative changes were noted at the left upper lobe apicoposterior segment, left lower lobe anterobasal and laterobasal segments.

The baby showed improvement in respiratory condition and was able to wean to high flow nasal cannula on day four of life. He was kept fasted and our pediatric surgical team was consulted on day six for further management. On admission, he was hemodynamically stable while on nasal cannula with FiO₂ 0.21. Abdomen was soft and slightly distended. He was kept nil by mouth and was supported by total parenteral nutrition.

Plain X-ray upon admission to our center showed the foreign body had migrated to the pyloric region and the right lower lobe was opened up. Repeat abdominal X-ray on the same day showed passage of the foreign body to the small intestine. We decided for conservative management in view of stable condition. Serial abdominal X-ray showed spontaneous passage to the large intestine (Fig. 3).

No work resembling the enclosed article has been published or is being submitted for publication elsewhere. We certify that we have each made a substantial contribution so as to qualify for authorship and that we have approved the contents.

* Corresponding author. Tel.: +852 2855 4850; fax: +852 2817 3155.

E-mail address: kkywong@hku.hk (K.K.Y. Wong).

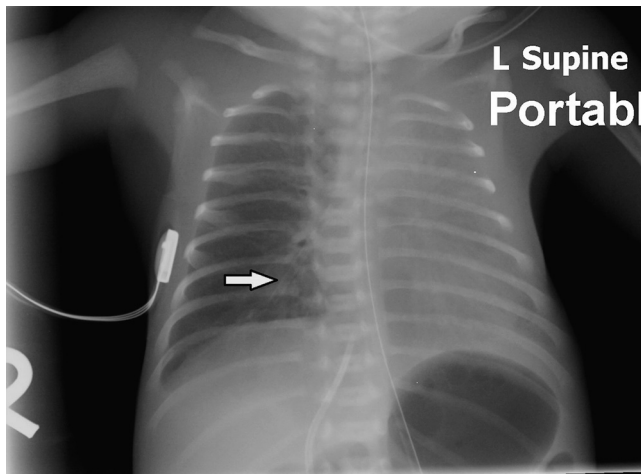


Fig. 1. Anteroposterior chest X-ray shows a foreign body at right bronchus (Arrow points to the foreign body).

He received oxygen supplement through bubble continuous positive airway pressure 5 cm H₂O (FiO₂ 0.25–0.3) for recurrent apnea. Enteral feeding was resumed 3 days after admission and was well tolerated. Total parenteral nutrition was weaned off on day fourteen of life. On the same day, he passed an 18 mm fragment of suction catheter out with meconium (Fig. 4).

1. Discussion

Foreign body in neonate is rare and most are iatrogenic [1–5]. Literature reviews reveal that the majority of foreign bodies were derived from medical devices, reported objects included laryngoscope bulb [1], sheared stylet sheath [2,4], nasal prong [3], silicone suction catheter [5]. There were only 7 cases of neonatal gastrointestinal foreign bodies reported worldwide [1–5,7,8].

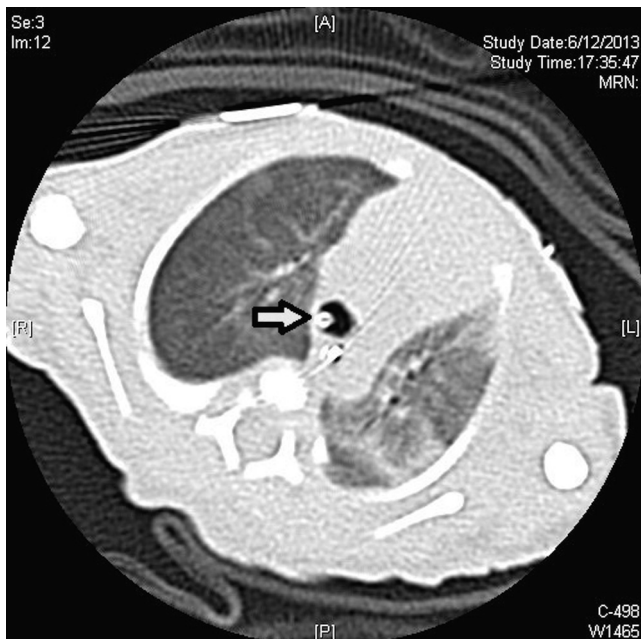


Fig. 2. Computer tomography of thorax shows the intraluminal foreign body of right bronchus (Arrow points to the foreign body).

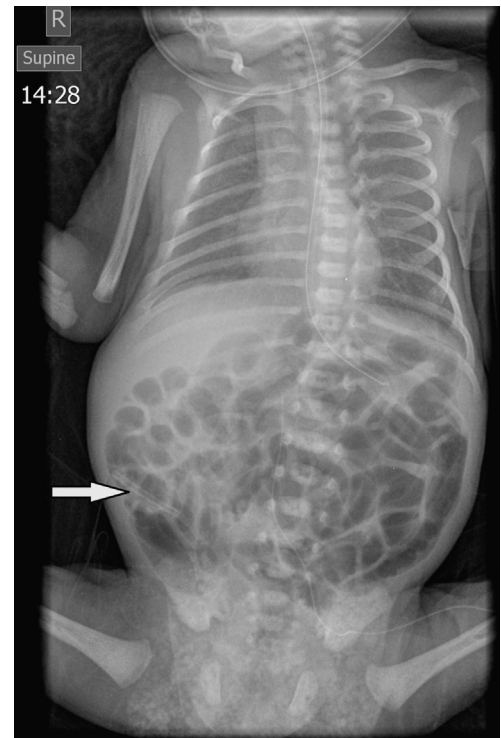


Fig. 3. Anteroposterior abdominal X-ray shows the foreign body in the large intestine (Arrow points to the foreign body).

In particular, our patient had very low birth weight, making the management even more challenging.

In our case, the foreign body recovered after it was passed in meconium was identified as an 18 mm fragment of distal end of the Kimvent suction catheter. It was customary to cut short endotracheal tube to reduce dead space for neonatal ventilation. Investigations revealed that the endotracheal tube was shortened after surfactant was delivered with the Kimvent suction catheter still in place. We postulated that when the endotracheal tube was cut, the Kimvent suction catheter in the close circuit suction system had not been completely withdrawn with the tip still inside the endotracheal tube resulting in accidental cutting off the distal end of the Kimvent suction catheter. This cut end of the Kimvent suction

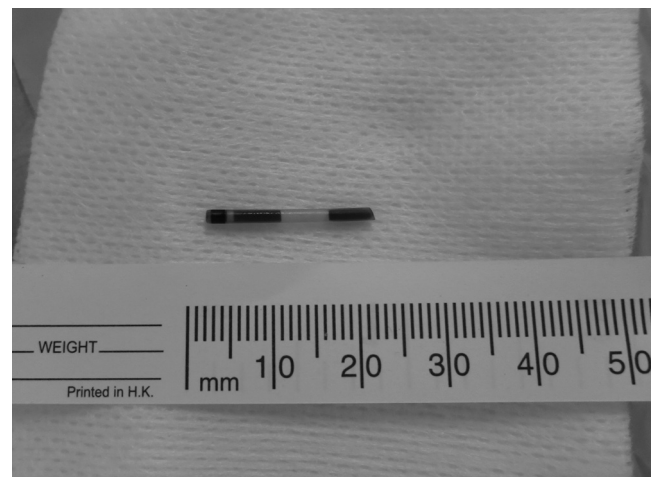


Fig. 4. An 18 mm fragment of suction catheter with meconium.

catheter then slipped into the right main bronchus. Because the accident was not identified by the medical staff, another postulation at the time of admission was that the foreign body was a broken feeding tube which might have migrated into the trachea and subsequently back to the intestinal tract because of a tracheo-laryngeal cleft. This was unlikely when we reviewed the contrast computer tomography of thorax. Our opinion was that the catheter was coughed up and then entered the esophagus by chance.

The planning of surgical retrieval largely depends on the location of the foreign body. Our patient was initially found to have an 18 mm foreign body in the right bronchus. At that time we planned for endoscopic removal using a 2.5 mm rigid bronchoscope to prevent potential serious complications such as respiratory compromise, esophageal perforations and strictures, fistulation into aorta or abscess formation. However the foreign body migrated to the stomach and small intestine shortly after transferal to our center. It has been reported most of small foreign bodies do not need any active management as about 80% of all foreign bodies pass spontaneously from gastrointestinal tract. It is estimated that only 10–20% of all gastrointestinal foreign bodies require endoscopic retrieval, whereas, only 1% requires surgical exploration [9]. The hemodynamic condition of our patient was stable all along and there was no sign of perforation or peritonitis from physical examination and imaging. Hence our patient was on expectant management and spontaneous passage of the suction catheter occurred on day fourteen of life.

2. Conclusion

We described our experience in managing a preterm neonate with iatrogenic suction catheter ingestion after resuscitation. Fortunately, our patient was spared from surgical intervention. Sequences of events led to accidental cutting of the Kimvent suction catheter. We recommend that endotracheal tube should be cut shortly after the endotracheal intubation before other procedures

are to be carried. In this case endotracheal tube should be cut before surfactant is administered. This is in line with the traditional concept of Airway Breathing Circulation Drugs in stabilization of intensive care unit patients. After surfactant is delivered, the Kimvent suction catheter should be discarded. The distal end of the Kimvent suction catheter is colorless and is difficult to inspect. We suggest that the manufacturer should consider adding on colored graduation marks at the distal end to facilitate inspection for intactness of suction catheter. Endoscopic instruments for preterm neonates should be available at all times for urgent endoscopic retrieval of foreign body.

Conflict of interest

The authors declare they have no conflicts of interest.

References

- [1] Ince Z, Tuğcu D, Coban A. An unusual complication of endotracheal intubation: ingestion of a laryngoscope bulb. *Pediatr Emerg Care* 1998 Aug;14(4):275–6.
- [2] Boyd RL, Bradfield HA, Burton EM, Carter BS. Fluoroscopy-guided retrieval of a sheared endotracheal stylet sheath from the tracheobronchial tree in a premature infant. *Pediatr Radiol* 1999;29:575–7.
- [3] Peck DJ, Tulloh RM, Madden N, Petros AJ. A wandering nasal prong—a thing of risks and problems. *Paediatr Anaesth* 1999;9(1):77–9.
- [4] Chiou HL, Diaz R, Orlino Jr E, Poulain E. Acute airway obstruction by a sheared endotracheal intubation stylet sheath in a premature infant. *J Perinatol* 2007; 27:727–9.
- [5] Mirza B, Saleem M, Sheikh A. Broken piece of silicone suction catheter in upper alimentary tract of a neonate. *APSP J Case Rep* 2010;1:8.
- [6] Nayak SR, Kirtane MV, Shah AK, Karnik PP. Foreign bodies in the cricopharyngeal region and oesophagus (a review of 226 cases). *J Postgrad Med* 1984;30:214.
- [7] Zameer M, Kanojia RP, Thapa BR, Rao K. Foreign body oesophagus in a neonate: a common occurrence at an uncommon age. *Afr J Paediatr Surg* 2010;7:114–6.
- [8] Singh R, Pandit C, Gupta D, Vajifdar H. Foreign body esophagus in a neonate: unusual age and unusual presentation. *J Anaesthesiol Clin Pharmacol* 2012 Apr; 28(2):258–60.
- [9] Al Shehri GY, Al Malki TA, Al Shehri MY, Ajao OG, Jastaniah SA, Haroon KS. Swallowed foreign body: Is interventional management always required? *Saudi J Gastroenterol* 2000;6:84–6.