



UNIVERSITÀ
DEGLI STUDI
DI PADOVA

Università degli Studi di Padova

Padua Research Archive - Institutional Repository

Effect of "wooden breast" appearance on poultry meat quality, histological traits, and lesions characterization

Original Citation:

Availability:

This version is available at: 11577/3228046 since: 2017-05-12T16:10:44Z

Publisher:

Czech Academy of Agricultural Sciences

Published version:

DOI: 10.17221/54/2016-CJAS

Terms of use:

Open Access

This article is made available under terms and conditions applicable to Open Access Guidelines, as described at <http://www.unipd.it/download/file/fid/55401> (Italian only)

(Article begins on next page)

Effect of “Wooden Breast” Appearance on Poultry Meat Quality, Histological Traits, and Lesions Characterization

ANTONELLA DALLE ZOTTE¹, GIULIA TASONIERO¹, EERO PUOLANNE²,
HERVÉ REMIGNON³, MATTIA CECCHINATO¹, ELENA CATELLI⁴, MARCO CULLERE^{1*}

¹Department of Animal Medicine, Production and Health, University of Padova, Legnaro, Italy

²Department of Food and Environmental Sciences, Faculty of Biological and Environmental Sciences, University of Helsinki, Helsinki, Finland

³University of Toulouse INPT ENSAT, UMR 1388 Genetic, Physiology and Breeding System, Castanet-Tolosan, France

⁴Department of Veterinary Medical Sciences, University of Bologna, Ozzano dell'Emilia, Italy

*Corresponding author: marco.cullere@unipd.it

ABSTRACT

Dalle Zotte A., Tasoniero G., Puolanne E., Remignon H., Cecchinato M., Catelli E., Cullere M. (2017): **Effect of “Wooden Breast” appearance on poultry meat quality, histological traits, and lesions characterization.** Czech J. Anim. Sci., 62, 51–57.

The purposes of the study were to investigate the effects of Wooden Breast (WB) myodegeneration on poultry meat quality and to give a contribution in typing lesions morphology. At a poultry meat cutting facility, 474 carcasses of a high-breast-yield hybrid chickens were inspected for WB condition, and 30 normal (N) and 30 affected (WB) breast fillets (*Pectoralis major*) were randomly selected. The WB condition represented 53.2% of the examined carcasses. Weight, cross sectional area (CSA), pH, L*, a*, b* colour values, water-holding capacity, and Warner-Bratzler shear force were determined. Samples were also visually and histologically evaluated. Affected samples were heavier, thicker, paler ($P < 0.001$), and characterized by palpatory hardness and lower water holding capacity ($P < 0.05$). Macroscopically, abnormalities were primarily localized in the cranial portion of the fillet and defined by the presence of bulges, petechiae, fluid and clear exudate, and higher pH. Microscopically, the WB condition was characterized by muscle fibres with greater CSA ($P < 0.001$) and higher giant fibres prevalence ($P < 0.01$). Data suggest a relationship between breast weight and WB condition.

Keywords: emergent myopathy; breast muscle defect; myodegeneration

An ever-increasing demand for chicken meat has enforced poultry supply chain to improve growth rate and breast meat yield of broilers, but this trend led to a substantial onset of breast muscle defects at the same time (Dalle Zotte et al. 2015).

An emergent myopathy has been described and named Wooden Breast (WB) (Sihvo et al. 2013). Distinguishing macroscopical traits of the affected *Pectoralis major* muscle are the remarkable palpatory hardness and the pale colour, as well as the

Supported by the University of Padova (Research funds Ex60% 2015, code: 60A08-7341).

The authors declare that they have no competing interests.

presence of bulges, small haemorrhages, and a slimy surface due to a fluid and clear exudate covering the hardened areas. Interestingly, also the observation of White Striping (WS) and extended areas with separated muscle bundles is often concomitant. Histologically, WB condition is a moderate or severe myodegeneration, accompanied by necrosis, inflammatory cells accumulation, and reparative responses (fibrosis). Abnormalities in cells structure and shape (internalization of nuclei, split cells appearance, and loss of polygonality) are other typical traits of tissue damage. Although the underlying causes of the disease remain obscure, through the analysis of genes expression, Mutryn et al. (2015) indicated that hypoxia, oxidative stress, increased intracellular calcium as well as the presence of fibre-type switching could be reasonably key features of WB. In addition, this myopathy demonstrates similar histological traits as WS, whose aetiology has just been explored even though not completely. Fast growth rate and ever-increasing breast meat yield reached by birds seemed to be responsible for breast muscle overstretching and capillary density lowering, with ischemia, inflammation, and reparative fibrotic response as consequence (Kuttappan et al. 2013). Selection for increased muscle size, together with muscle type, slaughter age, and energy level of the diet, is also a key factor linked to higher giant fibres (GF) incidence, phenomenon observed in turkey (Remignon et al. 2000), rabbit (Dalle Zotte et al. 2001), chicken (Miraglia et al. 2006), and swine (Schubert-Schoppmeyer et al. 2008). These cells were described as oval or rounded-shaped, with larger cross-sectional area, distributed in groups or isolated at the periphery of fascicles (Sink et al. 1986; Remignon et al. 2000) and characterized by altered energy metabolism and contraction speed (Dalle Zotte et al. 2001). In addition, according to Dalle Zotte et al. (2001), GF are associated with modification of the fibre type proportion of the muscle. In fact, despite being normally composed by white fibres (α W), rabbit *Biceps femoris* muscle presenting giant fibres was found to exhibit increased percentages and area of red fibres (β R), which were positively correlated to higher ultimate pH values. Giant cells were thought to arise from hypercontracted individual fibres (Dutson et al. 1978; Sink et al. 1986; Sosnicki 1987), to be a sign of myopathy (Sosnicki 1987) and fibres being in a degenerative, pre-necrotic stage (Cullen et al. 1979; Wegner and Ender 1990; Wilson et al. 1990). In any

case, GF were correlated with poor meat quality in pigs (Essen-Gustavsson 1995; Fiedler et al. 1999, 2004). On the basis that the outbreak of GF seemed to be the faster growth (Miraglia et al. 2006) and the selection for increased muscle size (Sosnicki et al. 1991), researching a possible difference in the prevalence of giant fibres in WB affected and normal meat samples could be of interest.

Poor information is also available about WB consequence on meat technological traits, whereas the detrimental implication of WS on these variables has already been explored.

Therefore, the present study tried to gain additional information on the quality impairment of WB affected breast, then it tried to deepen the knowledge of macroscopic typifying descriptors and of the histological traits.

MATERIAL AND METHODS

At a poultry-meat cutting facility, a total of 474 carcasses of a high-breast-yield hybrid chickens (unknown gender) were 48 h *post mortem* subjected to visual and tactile inspection for WB condition. Subsequently, 30 normal (N) and 30 WB affected breast fillets were randomly selected. WB condition was observed in 252 carcasses, which represented 53.2% of the examined carcasses.

Affected samples were visually examined for the WB descriptors, according to Sihvo et al. (2014), by filling up a dedicated form presented elsewhere (Tasoniero et al. 2016). Selected right breasts were weighed, then on their cranial and caudal ends, pH was measured in duplicate by infission with a portable pH-meter FE20 (Mettler Toledo, Switzerland), as well as colour values of lightness, redness, yellowness, chroma, and hue (L^* , a^* , b^* , C^* , and H^* , respectively) with a RM200QC colorimeter (X-Rite Co., Germany). Samples were individually vacuum-packed and kept frozen for 3 months at -20°C ; thereafter, fillets were thawed to determine the thawing losses, again vacuum-packed, and cooked in a water bath until core temperature of 74°C to determine the cooking losses. Shear force was assessed with a TA-HDi Texture Analyzer (Stable Macro System, UK) on 6 cylinder-shaped cooked meat pieces per breast (Ø 1.25 cm). Samples were obtained through the whole breast thickness; therefore, surface and deep layers were both included. Then, a Warner-Bratzler cell (100-kg load cell, 2 mm/s crosshead speed) inserted in the

doi: 10.17221/54/2016-CJAS

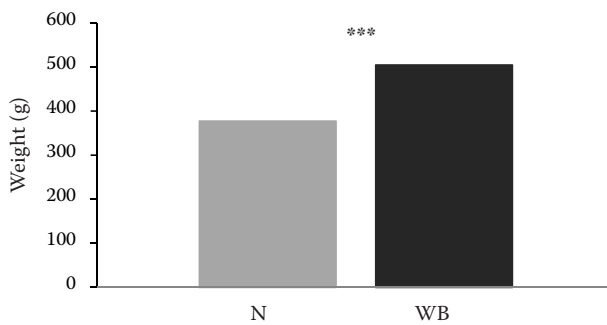


Figure 1. Breast weight of normal (N) and Wooden Breast (WB) affected birds

*** $P < 0.001$

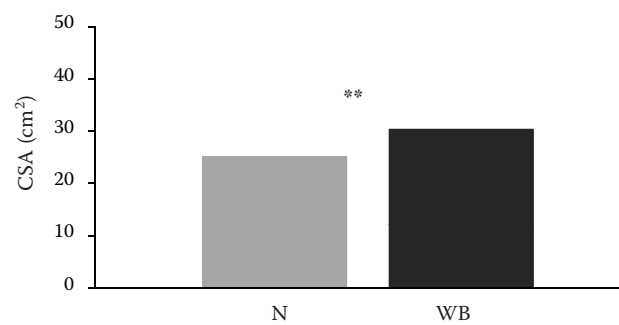


Figure 2. Breast cross sectional area (CSA) of normal (N) and Wooden Breast (WB) affected birds

** $P < 0.01$

texturometer cut samples perpendicularly to the fibres direction. The Warner-Bratzler shear force (WBSF) values of each sample represented an average of the 6 measurements. Cross sectional area (CSA) of the fillet and histological observations were performed on the left half-breasts. CSA data were obtained cutting transversely the cranial portions and photographing the views with Canon EOS 500D camera with 18–200 mm/3.5–5.6 lens; images were subsequently processed with digital image software (Carl Zeiss, Model Axiovision 4.6.3.0). Breast samples (15 N and 15 WB) were taken from the central-external part sampling both the surface and the deep layers of *Pectoralis major*, fixed in 10% formalin, processed by conventional methods and embedded in paraffin wax. Then, samples were cut at a 4- μ m thickness for hematoxylin-eosin (HE) staining (to estimate average normal fibres and giant fibres number and size) and for Masson's trichrome staining (to measure collagen and empty spaces percentages). Computerized image analysis (Buche 1990) was used to determine the fibre mean CSA (of both normal and giant fibres), the collagen and empty space area, and to count the average frequency of giant fibres per unit size of muscle section.

Breast quality traits, CSA, weight and histological data were analyzed through one-way ANOVA of the SAS software (Statistical Analysis System, Version 9.3, 2004), considering treatment (N vs WB) as independent variable. Descriptors were examined by χ^2 and z tests.

RESULTS AND DISCUSSION

Wooden Breast-affected fillets were heavier (505 vs 377 g, respectively; $P < 0.001$) and exhib-

ited greater CSA than N fillets (30.3 vs 25.1 cm², respectively; $P < 0.001$) (Figures 1 and 2); a high correlation ($r = 0.81$) between the two parameters was found (Brewer et al. 2012). At 48 h *post mortem*, WB samples were characterized by significantly higher pH and colour values and these differences were maintained after the frozen storage (Tables 1 and 2).

As demonstrated by higher pH and higher a^* and b^* values, breast cranial portions suffered more from the WB condition ($P < 0.01$); probably similarly to WS, the maximum thickness observed toward the cranial ends is responsible for overstretching and ischemia, which resulted in tissue

Table 1. Breast (*Pectoralis major*) pH and L*, a^* , b^* colour values at 48 h *post mortem*

	N ¹	WB ²	Significance	RSD ³
pH cranial	5.90	6.03	**	0.19
pH caudal	5.87	5.92	ns	0.16
L* cranial	50.9	54.6	***	3.4
L* caudal	50.5	53.8	***	3.3
a^* cranial	-1.1	-0.3	**	1.4
a^* caudal	-1.2	-0.6	ns	1.4
b^* cranial	12.9	15.9	**	3.1
b^* caudal	12.4	13.3	ns	3.6
C* cranial	13.0	16.0	**	3.2
C* caudal	12.6	13.4	ns	3.6
H° cranial	95.4	90.5	**	5.2
H° caudal	96.8	94.3	ns	7.3

L* = lightness, a^* = redness, b^* = yellowness, C* = chroma, H° = hue, N = normal, WB = Wooden Breast, RSD = residual standard deviation, ns = not significant

** $P < 0.01$, *** $P < 0.001$

damage and reparative responses (Kuttappan et al. 2013). The higher pH values observed in WB breasts than in N ones may be explained by the strong negative correlation between glycogen storage and breast muscle weight (Le Bihan-Duval et al. 2008). Therefore, a breast with greater size could exhibit a reduced glycolytic potential, resulting in higher ultimate pH. In fact, it was recently hypothesized that the high pH of WB fillets could be related to an altered glycogen utilization which would result in glycogen depletion (Soglia et al. 2016a). Differently, breast redder portions could be related to a higher myoglobin content: the fibre-type switching phenomenon, which was found to occur in WB condition, seemed to lead to a higher expression of myoglobin genes (Mutryn et al. 2015). Our results concerning yellowness index are in accordance with previous results on WS (Petracci et al. 2013) and WB (Mudalal et al. 2015): affected fillets are more yellow than non-affected ones, probably due to the severe fibrotic response. On the contrary, both the portions (cranial and caudal) were brighter in affected samples ($P < 0.001$), thus confirming the evidence of the importance of this last feature in the WB condition. Chroma (C^*) and hue (H°) followed the similar trend of redness value.

Our WB fillets also displayed a worse water holding capacity (WHC), as demonstrated by the supe-

rior cooking losses ($P < 0.01$), which contributed to the higher total losses ($P < 0.05$) observed for this group (Table 3). Such result is in accordance with recent literature data (Tijare et al. 2016). Muscles could exhibit a reduced ability to hold water because of the myodegeneration. It is likely that, as previously observed in WS condition (Petracci et al. 2014), the functional proteins content, responsible for meat WHC is lowered in favour of collagen (Dalle Zotte et al. 2014; Petracci et al. 2015). This hypothesis found confirmation in the work by Soglia et al. (2016a), which showed a higher collagen and lower protein contents in chicken breast muscles affected by WB abnormality compared to normal ones. This replacement results in a significant impairment of protein functionality and water retention of cooked meat, despite collagen proteins shorten, swell, solubilize during the cooking process and gelatinize when cooled (Palka 1999; Tornberg 2005), thus keeping an amount of water. Furthermore, WB myopathy was found to worsen the oxidative status of meat proteins and lipids which could contribute to reduced storage stability of meat and thus WHC (Soglia et al. 2016b).

Despite the results of a recent work by Soglia et al. (2016a) showed that WB chicken breasts exhibited higher hardness, gumminess, and chewiness than normal ones, shear force values of the affected cooked breasts of the present experiment did not correspond to the palpatory hardness perceived at the fresh and thawed state; these results are in accordance with those of Mudalal et al. (2015). The extensive poor cohesion and the tendency of the fibre bundles to separate, mainly at the cranial level, could have mitigated the expected hardness (Petracci and Cavani 2012; Petracci et al. 2013). In addition, toughness values could have been mitigated also because of the storage period:

Table 2. Breast (*Pectoralis major*) pH and $L^*a^*b^*$ colour values after frozen storage

	N	WB	Significance	RSD
pH cranial	5.91	6.03	***	0.12
pH caudal	5.86	5.91	ns	0.13
L^* cranial	48.5	52.3	***	3.0
L^* caudal	48.9	51.3	***	2.4
a^* cranial	-0.4	-0.7	**	1.3
a^* caudal	-1.2	-1.2	ns	1.3
b^* cranial	16.7	19.8	**	3.7
b^* caudal	13.9	15.2	ns	3.7
C^* cranial	16.7	19.9	**	3.7
C^* caudal	14.1	15.4	ns	3.6
H° cranial	92.1	88.8	**	4.6
H° caudal	96.0	96.0	ns	6.2

L^* = lightness, a^* = redness, b^* = yellowness, C^* = chroma, H° = hue, N = normal, WB = Wooden Breast, RSD = residual standard deviation, ns = not significant

** $P < 0.01$, *** $P < 0.001$

Table 3. Breast (*Pectoralis major*) weight, water holding capacity (WHC), and Warner-Bratzler shear force (WBSF)

	N	WB	Significance	RSD
Thawing losses (%)	5.4	5.0	ns	1.7
Cooking losses (%)	23.5	26.4	**	3.7
Total losses (%)	29.0	31.4	*	4.4
WBSF (N)	15.5	16.9	ns	2.8

N = normal, WB = Wooden Breast, RSD = residual standard deviation, ns = not significant

** $P < 0.01$, *** $P < 0.001$

doi: 10.17221/54/2016-CJAS

Table 4. Wooden Breast (WB) descriptors prevalence

Descriptors				Significance
Localization (%)				
Cranial	caudal	cranial + caudal	longitudinal	
56.7 ^A	3.3 ^B	23.3 ^B	16.7 ^B	***
Breast colour (%)				
Normal	pale	pink	other	
36.7 ^A	56.7 ^A	3.3 ^B	3.3 ^B	***
Breast consistency (%)				
Hard	very hard			
80.0 ^A	20.0 ^B			***
Bulgies localization (%)				
Cranial	caudal	cranial + caudal	longitudinal	
60.0 ^A	0.0 ^C	23.3 ^B	16.7 ^{BC}	***
Exudate consistency (%)				
Fluid	turbid			
36.7 ^A	6.7 ^B			**
Exudate colour (%)				
Clear	grey	yellow		
40.0 ^A	0.0 ^B	3.3 ^B		***
Hemorrhages localization (%)				
Cranial	caudal	longitudinal		
23.3 ^A	0.0 ^B	6.7 ^{AB}		**
Hemorrhages width (%)				
Pinpoint	3–5 mm	≥ 5 mm		
23.3 ^A	6.7 ^{AB}	0.0 ^B		**

^{AB}means in the same row with different superscripts differ significantly, ** $P < 0.01$, *** $P < 0.001$

the large extracellular ice crystals, formed during freezing, could have broken down myofibrils apart, thus resulting in physical structure disruption (Leygonie et al. 2012) (Table 3). Macroscopically, the descriptors used highlighted that lesions are distributed mainly in the cranial end of the fillets ($P < 0.001$) (Table 4). The presence of bulgies (in 100% of the cases) was one of the selection traits, and it was localized at the cranial level in 60% of the observations, as well as the hard palpatory consistency and the colour ranging from normal to pale. The exudate appeared with a prevalence of 43.4% and it was mainly fluid and clear ($P < 0.01$), whereas pinpoint hemorrhages were present in 30% of the cases and mostly in the upper area. On WB samples the WS condition was present in 90% of the cases, thus confirming the evidence that such myopathies often occur simultaneously (Tijare et al. 2016), and it was mainly located in the cranial side of the breast, where the muscle displayed maximum thickness.

At histological level, fibres of WB samples were identified for their larger CSA ($P < 0.001$) and for the higher incidence of giant-type fibres among them ($P < 0.01$) (Table 5). This lowered the fibres average number visualized in the field area (80 vs 105; $P < 0.001$). It is worthy to be noticed that giant-type fibres belonging to WB samples possessed CSA values that were far greater than those of the giant-type fibres of the non-affected counterparts (6070 vs 3816 μm^2 ; $P < 0.01$). The occurrence of giant-type fibres and of fibres with an increased size are indexes of abnormality in the

Table 5. Histological traits

	N	WB	Significance	RSD
Average fibres number (on total field area)	105	80	***	14.7
Fibres CSA (% total field area) (HE staining)	71.0	73.5	ns	4.5
Fibre CSA (μm^2)	2012	2750	***	332
Giant fibre CSA (μm^2)	3816	6070	**	2111
Giant fibres (% total fibres number)	1.1	2.0	**	0.8
Giant fibres area (% total field area)	2.1	3.8	**	1.6
Collagen area (% total fibres area)	16.1	20.0	ns	7.2
Collagen area (% total field area)	10.7	12.9	ns	3.4
Empty spaces (% total field area)	21.4	19.0	ns	4.5

N = normal, WB = Wooden Breast, RSD = residual standard deviation, CSA = cross sectional area, HE = hematoxylin-eosin staining, ns = not significant

** $P < 0.01$, *** $P < 0.001$

muscle architecture and are typical of the degenerative process which establishes itself in breast muscle of fast growing and higher yield birds (Petracchi et al. 2013). A microscopic analysis revealed that they are hyper-contracted fibres with a sign of structural disintegration; in these cells, organelles important for cell integrity and functionality are damaged, resulting in an impaired adenosine triphosphate production (Schubert-Schoppmeyer et al. 2008). Contrary to the expectations, but likely due to the limited sampling size, in the present study the pathological condition did not entail an enhancement concerning collagen percentages, and only numerically higher values were observed. Nevertheless, it remains undeniable that collagen proliferation is a typifying characteristic (Sihvo et al. 2013).

CONCLUSION

Wooden Breast myodegeneration worsens meat quality traits and the visual appearance of the affected breasts through the presence of characterizing lesions. Despite the studies that have been conducted until now, many aspects on WB aetiology remain unclear. Considering the analogies with WS condition, high body weight and superior breast yield reached by birds within a short period of time could contribute to the myopathy. However, the pathological mechanisms at molecular level and the implication of the genetic component in the development of WB remain obscure.

Acknowledgements. Authors thank Jasmina Bradanović, Nicole Pontarin, and Andrea Quartesan for their technical support.

REFERENCES

- Brewer V.B., Kuttappan V.A., Emmert J.L., Meullenet J.F., Owens C.M. (2012): Big-bird programs: effect of strain, sex and debone time on meat quality of broilers. *Poultry Science*, 91, 248–254.
- Buche P. (1990): RACINE: a multi-image analysis system of serial sections. Application to the characterization of muscle fibres. Ph.D. Thesis. France, Rennes: Université Rennes I. (in French)
- Cullen M.J., Appleyard S., Bindoff L. (1979): Morphologic aspects of muscle breakdown and lysosomal activation. *Annals of the New York Academy of Sciences*, 317, 440–464.
- Dalle Zotte A., Remignon H., Ouhayoun J. (2001): Effect of some biological and zootechnical factors on appearance of giant fibres in the rabbit. Consequences on muscle fibre type, morphology and meat quality. *World Rabbit Science*, 9, 1–7.
- Dalle Zotte A., Cecchinato M., Quartesan A., Bradanovic J., Tasoniero G., Puolanne E. (2014): How does “Wooden Breast” myodegeneration affect poultry meat quality? *Archivos Latinoamericanos de Produccion Animal*, 22, 476–479.
- Dalle Zotte A., Tasoniero G., Russo E., Longoni C., Cecchinato M. (2015): Impact of coccidiosis control program and feeding plan on white striping prevalence and severity degree on broiler breast fillets evaluated at three growing ages. *Poultry Science*, 94, 2114–2123.
- Dutson T.R., Merkel R.A., Pearson A.M., Gann G.L. (1978): Structural characteristics of porcine skeletal muscle giant myofibers as observed by light and electron microscopy. *Journal of Animal Science*, 46, 1212–1220.
- Essen-Gustavsson B. (1995): Effects of physical stress on muscle fibre characteristics in pigs – relation to meat quality. In: Proc. 2nd Dummerstorf Muscle-workshop Muscle Growth and Meat Quality, Rostock, Germany, 65–69.
- Fiedler I., Ender K., Wicke M., Maak S., Lengerken G., Meyer W. (1999): Structural and functional characteristics of muscle fibres in pigs with different malignant hyperthermia susceptibility (MHS) and different meat quality. *Meat Science*, 53, 9–15.
- Fiedler I., Dietl G., Rehfeldt C., Wegner J., Ender K. (2004): Muscle fibre traits as additional selection criteria for muscle growth and meat quality in pigs – results of a simulated selection. *Journal of Animal Breeding and Genetics*, 121, 331–344.
- Kuttappan V.A., Shivaprasad H.L., Shaw D.P., Valentine B.A., Hargis B.M., Clark F.D., McKee S.R., Owens C.M. (2013): Pathological changes associated with white striping in broiler breast muscles. *Poultry Science*, 92, 331–338.
- Le Bihan-Duval E., Debut M., Berri C.M., Sellier N., Sante-Lhoutellier V., Jégo Y., Beaumont C. (2008): Chicken meat quality: genetic variability and relationship with growth and muscle characteristics. *BMC Genetics*, 9: 53.
- Leygonie C., Britz T.J., Hoffman L.C. (2012): Impact of freezing and thawing on the quality of meat: review. *Meat Science*, 91, 93–98.
- Miraglia D., Mammoli R., Branciarri R., Ranucci D., Cenci Goga B.T. (2006): Characterization of muscle fibre type and evaluation of the presence of giant fibres in two meat chicken hybrids. *Veterinary Research Communications*, 30, 357–360.
- Mudalal S., Lorenzi M., Soglia F., Cavani C., Petracchi M. (2015): Implications of white striping and wooden breast

doi: 10.17221/54/2016-CJAS

- abnormalities on quality traits of raw and marinated chicken meat. *Animal*, 9, 728–734.
- Mutryn M.F., Brannick E.M., Fu W., Lee W.R., Abasht B. (2015): Characterization of a novel chicken muscle disorder through differential gene expression and pathway analysis using RNA-sequencing. *BMC Genomics*, 16: 399.
- Palka K. (1999): Changes in intramuscular connective tissue and collagen solubility of bovine m. semitendinosus during retorting. *Meat Science*, 53, 189–194.
- Petracci M., Cavani C. (2012): Muscle growth and poultry meat quality issues. *Nutrients*, 4, 1–12.
- Petracci M., Mudalal S., Bonfiglio A., Cavani C. (2013): Occurrence of white striping under commercial conditions and its impact on breast meat quality in broiler chickens. *Poultry Science*, 92, 1670–1675.
- Petracci M., Mudalal S., Babini E., Cavani C. (2014): Effect of white striping on chemical composition and nutritional value of chicken breast meat. *Italian Journal of Animal Science*, 13, 179–183.
- Petracci M., Soglia F., Sirri F., Zambonelli P., Davoli R., Cavani C. (2015): Broiler Pectoralis major muscle affected by emerging abnormalities: composition and technological traits. *Italian Journal of Animal Science*, 14 (Suppl. 1), 59.
- Remignon H., Zanusso J., Albert G., Babile R. (2000): Occurrence of giant myofibres according to muscle type, pre- or post-rigor state and genetic background in turkeys. *Meat Science*, 56, 337–343.
- Schubert-Schoppmeyer A., Fiedler I., Nurnberg G., Jonas L., Ender K., Maak S., Rehfeldt C. (2008): Simulation of giant fibre development in biopsy samples from pig longissimus muscle. *Meat Science*, 80, 1297–1303.
- Sihvo H.K., Immonen K., Puolanne E. (2013): Myodegeneration with fibrosis and regeneration in the pectoralis major muscle of broilers. *Veterinary Pathology*, 51, 619–623.
- Sink J.D., Mann O.M., Turgut H. (1986): Characterization of the giant myofibre in bovine skeletal muscle. *Experimental Cell Biology*, 54, 1–7.
- Soglia F., Mudalal S., Babini E., Di Nunzio M., Mazzoni M., Sirri F., Cavani C., Petracci M. (2016a): Histology, composition, and quality traits of chicken Pectoralis major muscle affected by wooden breast abnormality. *Poultry Science*, 95, 651–659.
- Soglia F., Laghi L., Canonico L., Cavani C., Petracci M. (2016b): Functional property issues in boiler breast meat related to emerging muscle abnormalities. *Food Research International*, 89, 1071–1076.
- Sosnicki A. (1987): Histopathological observation of stress myopathy in *M. longissimus* in the pig and relationships with meat quality, fattening and slaughter traits. *Journal of Animal Science*, 65, 584–596.
- Sosnicki A.A., Cassens R.G., Vimini R.J., Greaser M.L. (1991): Histopathological and ultrastructural alterations of turkey skeletal muscle. *Poultry Science*, 70, 349–357.
- Tasoniero G., Cullere M., Cecchinato M., Puolanne E., Dalle Zotte A. (2016): Technological quality, mineral profile and sensory attributes of broiler chicken breasts affected by White Striping and Wooden Breast myopathies. *Poultry Science*, 95, 2707–2714.
- Tijare V.V., Yang F.L., Kuttapan V.A., Alvarado C.Z., Coon C.N., Owens C.M. (2016): Meat quality of broiler breast fillets with white striping and woody breast muscle myopathies. *Poultry Science*, 95, 2167–2173.
- Tornberg E. (2005): Effects of heat on meat proteins – implications on structure and quality of meat products. *Meat Science*, 70, 493–508.
- Wegner J., Ender K. (1990): Microstructural bases for the growth of muscle and fatty tissue and their relationship with carcass lean and quality. *Fleischwirtschaft*, 70, 337–340.
- Wilson W.B., Nieberg P.S., Buhr R.J., Kelly B.J., Shultz F.T. (1990): Turkey muscle growth and focal myopathy. *Poultry Science*, 69, 1553–1562.

Received: 2016–06–10

Accepted after corrections: 2016–10–06