



THE AGA KHAN UNIVERSITY

eCommons@AKU

Department of Surgery

Department of Surgery

January 2014

Conversion of cardiac bypass into an extracorporeal membrane oxygenation circuit: a case from Pakistan

Riffat Rasheed
Aga Khan University

Ijaz Hidayat
Aga Khan University

Muneer Amanullah
Aga Khan University, muneer.amanullah@aku.edu

Babar Hasan
Aga Khan University, babar.hasan@aku.edu

Follow this and additional works at: https://ecommons.aku.edu/pakistan_fhs_mc_surg_surg

 Part of the [Surgery Commons](#)

Recommended Citation

Rasheed, R., Hidayat, I., Amanullah, M., Hasan, B. (2014). Conversion of cardiac bypass into an extracorporeal membrane oxygenation circuit: a case from Pakistan. *Journal of Pakistan Medical Association*, 64(5), 589-592.

Available at: https://ecommons.aku.edu/pakistan_fhs_mc_surg_surg/653

Conversion of cardiac bypass into an extracorporeal membrane oxygenation circuit: a case from Pakistan

Riffat Rasheed,¹ Ijaz Hidayat,² Muneer Amanullah,³ Babar Sultan Hasan⁴

Abstract

A 35 days old neonate with d-loop transposition of great arteries, underwent an arterial switch operation following which he developed hypotension attributed to left ventricular failure. During cardiopulmonary resuscitation decision was made to place him on cardiac bypass again. Due to limited resources and unavailability of a specialized extracorporeal membrane oxygenator machine, the CPB was modified and converted an ECMO. The neonate was successfully decannulated after 72 hours and discharged home after 3 weeks of the operation without any sequel. ECMO is a viable option in developing countries and may help in improving the outcome especially in neonatal congenital heart disease.

Keywords: ECMO, Paediatrics, Developing country.

Introduction

The use of Extracorporeal membrane oxygenation (ECMO) in reversible cardiac or respiratory failure and protracted cardiopulmonary resuscitation (CPR) refractory to conventional intensive care measures is well documented.¹⁻⁴ ECMO also serve as a bridge for heart transplantation in developed countries.^{5,6} However, its usage in developing countries is still extremely limited due to high cost, equipment unavailability and lack of trained staff.⁷ We report here a case of ECMO use, at a tertiary care hospital in Pakistan.

Case Report

The case of a neonate born at full term by normal vaginal delivery and to consanguineous parents with no family history of congenital heart disease is presented.

At 10th day of life our patient was diagnosed with d-loop transposition of great arteries (d-loop TGA) and underwent emergent balloon atrial septostomy at The

Aga Khan University Hospital, Karachi, Pakistan. He was electively admitted at 33 days of age for an arterial switch operation (ASO). Pre-operative echocardiogram showed appropriate left ventricular (LV) mass and normal biventricular function. ASO was performed in September 2012 with no intra-operative issue. Total bypass time was 165 minutes with an aortic cross clamp time of 75 minutes. After coming off the cardiac bypass (CPB), he developed hypotension which was responsive to fluid and inotropes. An epicardial echocardiogram demonstrated a LV ejection fraction (LVEF) of 40%. He was shifted to cardiac intensive care unit (CICU) with an open chest (a usual practice in our institute) on a high inotropic score (IS) of 20 comprising of epinephrine (E) of 0.12 mcg/kg/min, norepinephrine (NE) 0.05 mcg/kg/min and milrinone (M) of 0.3mcg/kg/min). During first hour of transfer, he developed bradycardia, hypotension, increased left atrial pressure (LAP) of 13 mmHg with increased chest drainage output. Immediately cardiopulmonary resuscitation (CPR) was started, IS increased to 50 (E: 0.3 mcg/kg/min, NE 0.2 mcg/kg/min). He was transferred back to operating room with active CPR. After approximately 45 minutes of CPR, the neonate was placed back on the CPB machine through right internal jugular and carotid artery cannulation (12 F and 10 F cannula respectively). LV dysfunction due to unprepared myocardium was thought to be the cause of this acute de-compensation. It was felt that the best chance the neonate had was to be left on cardiopulmonary support for at least 48-72 hours to give the LV some rest and recovery post-surgery. At this time, plan was made to convert the CPB machine to an extracorporeal membrane oxygenator (ECMO) circuit and move the neonate to the CICU. Conventional bypass machine was transformed into a modified ECMO circuit after removing arterial filter and addition of a bridge in arterial-venous line. The paediatric cardiectomy reservoir was used as the pre-oxygenator bladder, a hollow fiber oxygenator (MEDOS HILITE 1000, GISH biomedical INC. California, USA) with a built in heat exchanger (HCU 20) was used as the membrane oxygenator (MO) (Figure-1 and 2). The air-mixer blender was attached to the MO as a source of sweep gas. A single roller pump (COBE Cardiovascular Inc. Colorado, USA) was used. Silicone

¹Pediatric Intensive Care, Department of Pediatric and Child Health, ²Department of Nursing, ³Department of Surgery, Section of Cardiothoracic Surgery, ⁴Pediatric Cardiology, Department of Pediatrics and Child Health, Aga Khan University, Karachi.

Correspondence: Babar Sultan Hasan. Email: babar.hasan@aku.edu

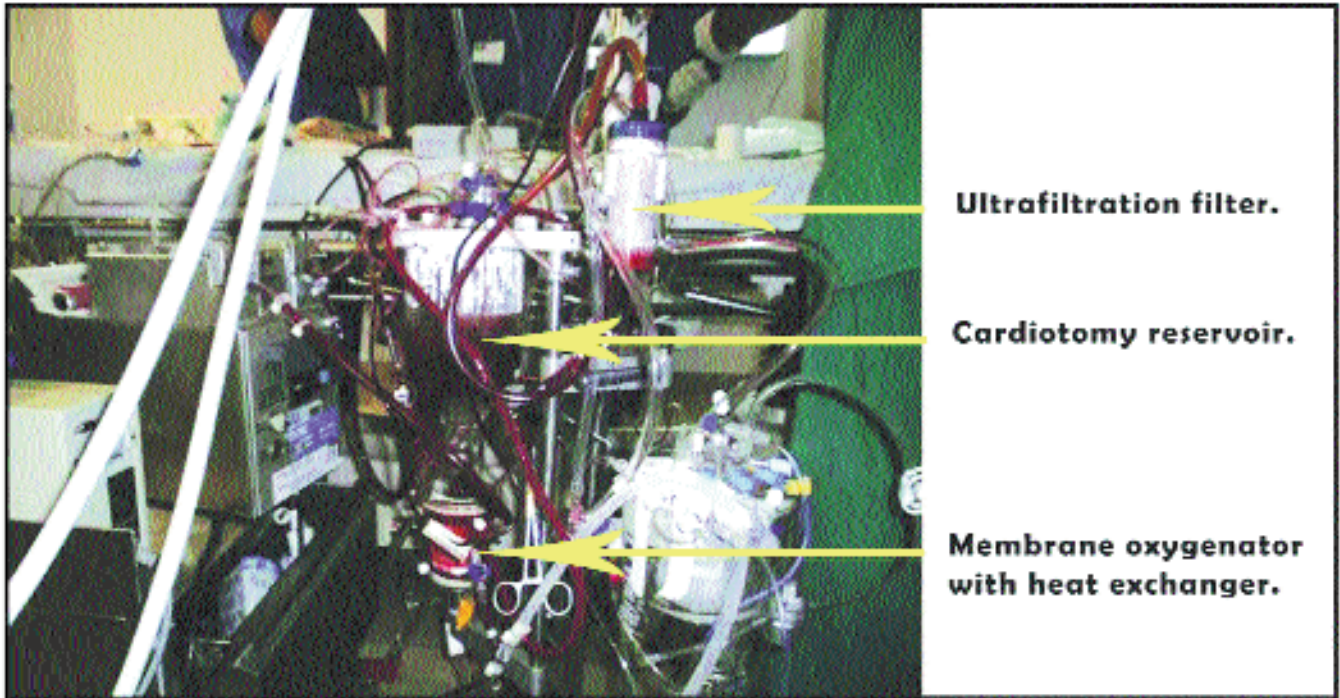


Figure-1: Portion of ECMO circuit showing the cardiotomy reservoir (used as a substitute for bladder), membrane oxygenator with built in heat exchanger and ultrafiltration filter.

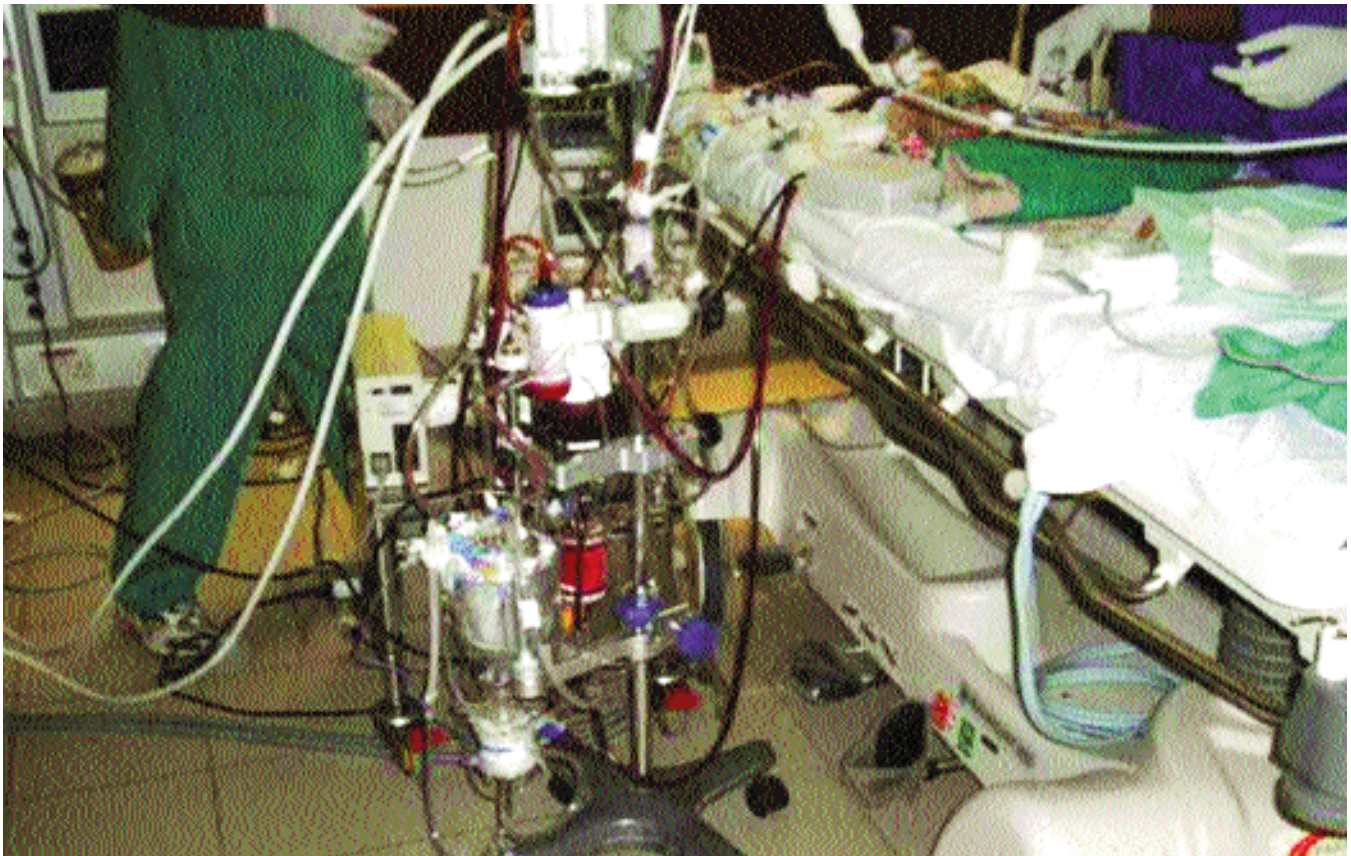

Figure-2: Complete ECMO circuit.

tubes were used for the "race course" portion of the circuit whilst regular polythene tubing completed the rest of the circuit. DLP (Medtronic's, Minneapolis, USA) pressure boxes were used to determine pre and post membrane pressures. The pre and post-membrane pressures were trended and monitored for any increase in pre-membrane pressures (>150mmHg) or difference in the pre/post membrane pressures (>50mmHg) to determine the integrity of the MO. Change in post-membrane partial pressure of oxygen at a constant sweep speed was also trended every 8 hours as another check for MO integrity. Another crystalloid primed circuit was kept at the bedside for emergent replacement if needed. Ultrafiltration was performed using a filter placed within the circuit. This venoarterial ECMO set was used to flow at 150 ml/kg to maintain a mean non-pulsatile blood pressure of 45-55 mmHg. Mean LAP of <8mmHg and a decompressed LV cavity on echocardiogram was used to determine effectiveness drainage. Activated clotting time (ACT) was used to assess the effect of heparin. Due to a cardiac reservoir instead of a bladder, the pre-reservoir ACT was kept at 300 IU. Patient ACT (drawn from the patient's arterial line) was kept at 180-200 IU and heparin was titrated based on this value. A difference of 100 IU was usually observed between these 2 values depicting constant heparin consumption by the cardiectomy reservoir. Heparin boluses were given in the ECMO venous line (pre-reservoir) to maintain the above mentioned values. Packed red blood cells were given to maintain haematocrit at 35-40%, platelets were maintained at >100,000, and cryoprecipitate kept the fibrinogen at >2gm/dl. For the total ECMO duration, a total of 8 units of packed red blood cells, 1 unit whole blood, 14 units cryoprecipitate, 8 units of platelets and 6 units of fresh frozen plasma were transfused. During the course of ECMO, pulmonary rest ventilation strategy was adopted with an intermittent ventilator rate of 5 breath/sec, positive end expiratory pressure of 10mmHg, Tidal volume of 4ml/kg and inhaled oxygen fraction of 30%. Inspiratory holds were performed every 8 hours for alveoli recruitment. One nurse, a perfusionist and physician team took care of the patient round the clock. Effective left atrial decompression was observed on echocardiogram and the need to create an inter-atrial communication for left atrial decompression was deferred. No circuit or patient related issues were encountered for the first 60 hours. After which increased chest drainage with coagulopathy and bleeding started and required several cryoprecipitate and platelet transfusions. By this time, pulsatility was observed and the ECMO flow was already down to idle value of 50ml/kg. He was taken back to the operation room where he was successfully decannulated

after 67 hours of being on ECMO. This was the 3rd post-operative day. His head ultrasounds performed immediately after cannulation and decannulation were normal. The chest of the patient was closed on the 6th post-operative day. LVEF improved to 66% at time of chest closure. He was extubated on the 10th and then discharged on 28th post-operative day without any sequel.

Discussion

Use and effectiveness of ECMO in post-operative congenital heart disease patients is well established in the developed countries.^{1,2} The extracorporeal life support organization (ELSO) in 2006 reported that among those post-operative congenital heart disease paediatric patients who were placed on ECMO, 60% were successfully weaned off and 44% were eventually discharged from the hospital.⁸ Improved outcome with the implication of this life saving modality mandates its usage in any cardiac intensive care unit. Countries with middle income economies i.e. India, Egypt, and South Africa have described ECMO use,⁷ but to the best of our knowledge, this is the first report of ECMO use from Pakistan. We demonstrated that in the absence of a complete ECMO set up, with some modifications a CPB machine can be converted and used as an ECMO. To decrease the chance of circuit thrombosis, the arterial air filter was removed and a bridge created between the venous and arterial portion of the circuit. Unavailability of a bladder and use of the cardiac reservoir as a substitute required running higher pre-reservoir ACTs and did eventually pose issues with bleeding at the 60th hour of ECMO run. Titrating ACTs based on patient's blood sample rather than from circuit may be a solution to overcome this issue. Hollow fiber MO may not be designed to work for long CPB runs. Given the unpredictability of such a MO, we used pre and post membrane pressures and post membrane PaO₂ as checks for MO integrity. Another crystalloid primed circuit was kept at the bedside for emergent replacement if needed.

Though we demonstrate use of ECMO, we do advocate cautious and appropriate use in a low-income setting like Pakistan. ECMO is a labour-intensive and expensive modality with an estimated total hospital cost of \$20,000 to \$90,000 per patient in developed countries.¹ Our patient survived after ECMO institution of 67 hours with total length of hospital stay of 25 days. Total cost of ECMO institution was 98,408,1 Pakistani rupees or \$9840 whereas total cost of stay was over 3 million Pakistani rupees. The personal support required was substantial with approximately 800 person-hours instituted for the care of this patient.

Conclusion

This successful experience of ECMO use from a low-income country with limited resources and unavailability of advanced equipment is hopeful and provides an option in reversible cardiorespiratory compromise refractory to standard ICU therapy. Such a modality should be used in highly selective cases where reversibility is anticipated.

Acknowledgements

We thank Dr. Mehnaz Atiq, Dr. Asif Hasan and William Watson from Newcastle, UK for their technical assistance in the case.

References

1. Ayad O, Dietrich A, Mihalov L. Extracorporeal Membrane Oxygenation. *Emerg Med Clin N Am* 2008; 26: 953-9.
 2. Ailawadi G, Zacour R. Cardiopulmonary Bypass/ Extracorporeal Membrane Oxygenation/ Left Heart Bypass: Indications, Techniques and Complications. *Surg Clin N Am* 2009; 89: 781-96.
 3. Vidmar I, Primožic J, Kalan G, Grosek S. Extracorporeal Membrane Oxygenation (ECMO) in neonates and children experiences of a multidisciplinary pediatric intensive care unit. *Signa Vitae* 2008; 3 Suppl 1: 17-21.
 4. Alsoufi B, Al-Radi OO, Nazer RI, Gruenwald C, Foreman C, Williams WG, et al. Survival outcomes after rescue extrapulmonary cardiopulmonary resuscitation in pediatric patients with refractory cardiac arrest. *J Thorac Cardiovasc Surg* 2007; 134: 952-9.
 5. Duncan BW. Mechanical circulatory support in children: extracorporeal membrane oxygenation and ventricular assist devices. *Expert Rev Med Devices* 2005; 2: 239-41.
 6. Blume ED, Naftel DC, Bastardi HJ, Duncan BW, Kirklin JK, Webber SA. Outcomes of children bridged to heart transplantation with ventricular assist devices. A multi-institutional study. *Circulation* 2006; 113: 2313-9.
 7. Smith J, Kirsten GF. Persistent pulmonary hypertension of the neonate in a developing country--does extracorporeal membrane oxygenation have a role to play? *S Afr Med J* 1993; 83: 742-5.
 8. Chan T, Thiagarajan Rr, Frank D, Bratton SL. Survival after extrapulmonary cardiopulmonary resuscitation in infants and children with heart disease. *Thorac Cardiovasc Surg* 2008; 136: 984-92.
-