



THE AGA KHAN UNIVERSITY

eCommons@AKU

Section of Cardiothoracic Surgery

Department of Surgery

January 2012

Subclavian steal syndrome secondary to subclavian artery thrombosis in a patient with homocysteinemia and its successful treatment

Marium Muzaffar

Hashim Muhammed Hanif

Saulat H. Fatimi

Aga Khan University, saulat.fatimi@aku.edu

M. Tariq

Aga Khan University, muhammed.tariq@aku.edu

Follow this and additional works at: https://ecommons.aku.edu/pakistan_fhs_mc_surg_cardiothoracic



Part of the [Cardiology Commons](#)

Recommended Citation

Muzaffar, M., Hanif, H., Fatimi, S., Tariq, M. (2012). Subclavian steal syndrome secondary to subclavian artery thrombosis in a patient with homocysteinemia and its successful treatment. *Journal of Pakistan Medical Association*, 62(10), 1118-1120.

Available at: https://ecommons.aku.edu/pakistan_fhs_mc_surg_cardiothoracic/50

Subclavian steal syndrome secondary to Subclavian Artery Thrombosis in a patient with Homocysteinemia and its successful treatment

Marium Muzaffar,¹ Saulat Hasnain Fatimi,² Muhammad Tariq,³ Hashim Muhammed Hanif⁴

Medical College,^{1,4} Department of Surgery, Division of Cardiothoracic Surgery,² Department of Medicine,³ Aga Khan University, Karachi, Pakistan.

Corresponding Author: Hashim Muhammed Hanif. Email: hashimhanif@gmail.com

Abstract

Subclavian steal syndrome (SSS) is a rare condition. It results from subclavian artery (SA) stenosis proximal to the origin of the vertebral artery. It is characterized by cerebral ischaemia with associated symptoms of vertebrobasilar hypoperfusion and/or symptoms of brainstem or arm ischaemia. We describe a case of a 35 year old male who presented with persistent vertigo for two months, blue discoloration and pain in the left fingers for two weeks. A diagnosis of SSS was made and patient was treated with a gortex graft from the arch of the aorta to the second portion of the left subclavian artery. Treatment is aimed at restoring permanent antegrade blood flow to the affected vertebral artery. This abolishes vertebral basilar symptoms and other manifestations of SSS. Several modalities exist, however surgical correction is the treatment of choice.

Keywords: Subclavian Steal Syndrome, Homocysteinemia.

Introduction

Subclavian Steal Syndrome (SSS) is a condition that results from subclavian artery stenosis proximal to the origin of the vertebral artery. The blockage causes the reversal of the normal direction of blood flow in the vertebral artery which is termed the "steal", because it steals blood from the cerebral circulation. Blood is drawn from the contralateral vertebral, basilar or carotid artery regions into the low-pressure ipsilateral upper limb vessels. SSS is a rare disease and is mostly seen in ages above 60 in men.^{1,2} Atherosclerotic plaques in the subclavian artery are rare and patients are usually asymptomatic; hence the condition presents late.³ This syndrome exists as an important consideration in the differential diagnosis of cerebral and brachial ischaemia. We discuss a case of a 35 year old male who presented to us with upper limb ischaemia.

Case Presentation

A 35 years old male, known case of hypertension, presented with continuing vertigo and symptoms of imbalance for two months duration, blue discoloration and

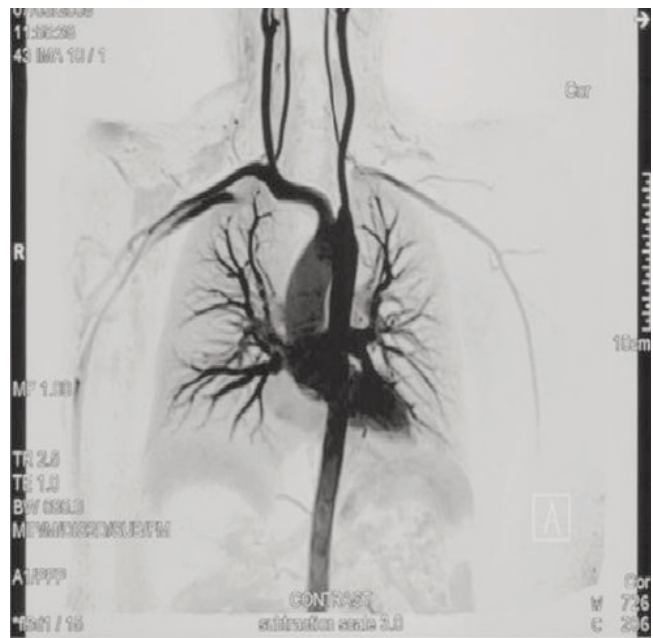

Figure-1: Angiography showing complete left Subclavian stenosis and its refilling via the basilar artery.

pain in the fingers of left hand for two weeks. There was no history of fever but patient gave history of right CVA secondary to right posterior inferior cerebellar artery territory infarct two years ago with some residual weakness of the left upper extremity. On examination, his vital signs were normal and he was found to be alert and oriented with 3/5 power in the left upper extremity and the rest normal on neurological examination. However there was no palpable left radial or brachial pulse and there was obvious cyanosis of the fingers of the left hand. Magnetic Resonance Angiogram (MRA) of the aortic arch and its vessels showed complete occlusion of the left subclavian artery at its takeoff from the aorta and its reconstruction via left vertebral artery (Figure-1). A diagnosis of left subclavian steal syndrome was made. Further investigations were done to determine cause of this spontaneous occlusion. Workup for previous stroke revealed normal protein C and S and antithrombin iii

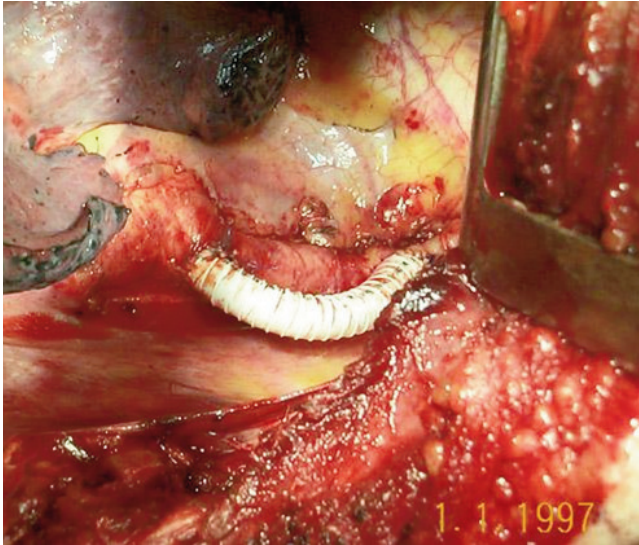


Figure-2: Gortex graft.

levels but high homocysteine levels in the blood.

Patient was taken to the OR and via left posterolateral thoracotomy, the subclavian artery was exposed. Histopathology of the web revealed fibrinous material with inflammatory cells and red blood cells. There was no evidence of malignancy. The subclavian artery was then bypassed with 6 mm ringed gortex graft from the arch of the aorta to the second portion of the left subclavian artery (Figure-2). Post-operatively patient had complete resolution of vertigo symptoms, cyanosis of the left hand and had a good radial pulse. He was put on aspirin and warfarin to keep his INR around 3 - 4.5. He was discharged home in one week. A three month follow-up revealed the patient to be asymptomatic and doing well.

Discussion

SSS is characterized by cerebral ischaemia with associated symptoms of vertebrobasilar hypoperfusion and/or symptoms of brainstem or arm ischaemia. Symptoms ensue when blood is drawn from the contralateral vertebral artery into the low pressure ipsilateral upper limb vessels, thereby rendering a decrease in the flow in the basilar artery.

Symptoms include those of carotid artery ischaemia; hemianaesthesia, hemi/monoparesis, head ache, dysphagia, visual field disturbance and confusion, and of vertebrobasilar ischaemia; dizziness/vertigo/light headedness, drop attacks/fainting spells, diplopia, dysarthria, dysphagia, ataxia, nausea, numbness and nystagmus.³ SSS is reported to occur in approximately 6% of patients with asymptomatic cervical bruits.⁴ It is slightly more common in men than women with the average age of patients being 61 yrs and 59 yrs respectively.^{5,6}

Risk factors include atherosclerosis, smoking (78% to 100% cases) and concomitant coronary artery disease (27% to 65% of cases).⁵ As there is extensive collateral circulation from the vertebral artery and around the shoulder, symptoms of arm ischaemia seldom develop from proximal subclavian artery occlusive disease alone. It has been found that 88% of proximal subclavian artery occlusions present with CNS symptoms and only 40% of such patients have intermittent claudication of the arm.⁷ However, those patients with distal subclavian occlusions present predominantly with intermittent claudication of the arm.⁸ Arm symptoms include ischaemic pain at rest, ulcers, muscle fatigue, and digital necrosis.

Coagulopathy is a well known risk factor from thrombosis generally anywhere in the body, however its affecting the subclavian artery is a rare occurrence. Treatment is aimed at restoring permanent ante grade blood flow to the affected vertebral artery and thus abolishing vertebrobasilar and subclavian symptoms of SSS.

Subclavian steal syndrome is often found in patient with concomitant cardiovascular diseases including lower-extremity peripheral artery disease and coronary artery disease. Secondary prevention and cardiovascular risk factor modification is the mainstay of treatment of subclavian stenosis and subclavian steal syndrome.^{4,8-10} These interventions include blood pressure control, cholesterol modification, glycaemic control in diabetic patients, smoking cessation, lifestyle modifications, and antithrombotic/ antiplatelet therapy. In symptomatic patients, treatment options include angioplasty, endarterectomy and patch aortosubclavian artery bypass or carotid-subclavian artery bypass surgery. Extrathoracic approach is the most popular surgical approach with overall patency rate of 95%, 86% and 73% in one, three and five years followup, respectively.¹¹ Although no randomized trials available, retrospective observational studies have shown equal effectiveness but fewer complication rates with angioplasty and/or stenting.¹² De Vries et al. in a retrospective observational study in 110 patients have shown more than 90% initial success rate with subclavian angioplasty with or without stenting.¹³ In this study, significant restenosis, more than 70% was observed in 7% at a median followup of 23 months.

In summary, subclavian steal syndrome is blood flow reversal in vertebral arteries usually caused by severe stenosis of the subclavian artery or innominate artery. The clinical presentation of subclavian steal syndrome is variable, ranging from asymptomatic to cerebrovascular ischaemia to arm pain. Subclavian stenosis is an independent risk factor for overall and cardiovascular mortality. Subclavian stenosis can be readily recognized by duplex ultrasound performed in experienced centers and

with a protocol that includes imaging of the proximal subclavian arteries.

Consent:

Written informed consent was obtained from the patient for publication of this case report and accompanying images. A copy of the written consent is available for review by the Editor-in-Chief of this journal.

Reference

1. Smith JM, Koury HI, Hafner CD, Welling RE. Subclavian steal syndrome. A review of 59 consecutive cases. *J Cardiovasc Surg (Torino)* 1994; 35: 11-4.
 2. Delaney CP, Couse NF, Mehigan D, Keaveny TV. Investigation and management of subclavian steal syndrome. *Br J Surg [Review]* 1994; 81: 1093-5.
 3. Pollard H, Rigby S, Moritz G, Lau C. SUBCLAVIAN STEAL SYNDROME: A Review. *Australas Chiropr Osteopathy* 1998; 7: 20-8.
 4. Fields WS, Lemak NA. Joint Study of extracranial arterial occlusion. VII. Subclavian steal--a review of 168 cases. *Jama* 1972; 222: 1139-43.
 5. Lacey KO. Subclavian steal syndrome: a review. *J Vasc Nurs [Review]* 1996; 14: 1-7.
 6. Welling RE, Cranley JJ, Krause RJ, Hafner CD. Obliterative arterial disease of the upper extremity. *Arch Surg* 1981; 116: 1593-6.
 7. Zimmerman NB. Occlusive vascular disorders of the upper extremity. *Hand Clin [Review]* 1993; 9: 139-50.
 8. Marques KM, Ernst SM, Mast EG, Bal ET, Suttorp MJ, Plokker HW. Percutaneous transluminal angioplasty of the left subclavian artery to prevent or treat the coronary-subclavian steal syndrome. *Am J Cardiol* 1996; 78: 687-90.
 9. Breall JA, Kim D, Baim DS, Skillman JJ, Grossman W. Coronary-subclavian steal: an unusual cause of angina pectoris after successful internal mammary-coronary artery bypass grafting. *Cathet Cardiovasc Diagn [Case Reports]* 1991; 24: 274-6.
 10. Nguyen NH, Reeves F, Therasse E, Latour Y, Genest J, Jr. Percutaneous transluminal angioplasty in coronary-internal thoracic-subclavian steal syndrome. *Can J Cardiol [Case Reports Research Support, Non-U.S. Gov't Review]* 1997; 13: 285-9.
 11. Salam TA, Lumsden AB, Smith RB, 3rd. Subclavian artery revascularization: a decade of experience with extrathoracic bypass procedures. *J Surg Res* 1994; 56: 387-92.
 12. Hadjipetrou P, Cox S, Piemonte T, Eisenhauer A. Percutaneous revascularization of atherosclerotic obstruction of aortic arch vessels. *J Am Coll Cardiol [Comparative Study]* 1999; 33: 1238-45.
 13. De Vries JP, Jager LC, Van den Berg JC, Overtom TT, Ackerstaff RG, Van de Pavoordt ED, et al. Durability of percutaneous transluminal angioplasty for obstructive lesions of proximal subclavian artery: long-term results. *J Vasc Surg* 2005; 41: 19-23.
-