



THE AGA KHAN UNIVERSITY

eCommons@AKU

Department of Emergency Medicine

Medical College, Pakistan

March 2015

Nail as a foreign body in a neonate, an unusual presentation at an unusual age

Sayyeda Ghazala Irfan Kazi
Aga Khan University

Muhammad Irfan Habib
Aga Khan University

Badar Afzal
Aga Khan University

Irum Qamar Khan
Aga Khan University

Emaduddin Siddiqui
emaduddin.siddiqui@aku.edu, emaduddin.siddiqui@aku.edu

See next page for additional authors

Follow this and additional works at: https://ecommons.aku.edu/pakistan_fhs_mc_emerg_med



Part of the [Pediatrics Commons](#)

Recommended Citation

Kazi, S. I., Habib, M., Afzal, B., Khan, I. Q., Siddiqui, E., Aftab, M. (2015). Nail as a foreign body in a neonate, an unusual presentation at an unusual age. *Journal of Pakistan Medical Association*, 65(3), 315-316.

Available at: https://ecommons.aku.edu/pakistan_fhs_mc_emerg_med/135

Authors

Sayyeda Ghazala Irfan Kazi, Muhammad Irfan Habib, Badar Afzal, Irum Qamar Khan, Emaduddin Siddiqui, and Maryam Aftab

Nail as a foreign body in a neonate, an unusual presentation at an unusual age

Sayyeda Ghazala Irfan Kazi, Muhammad Irfan Habib, Badar Afzal, Irum Qamar Khan, Emaduddin Siddiqui, Maryam Aftab

Abstract

Children are prone to ingest substances due to their exploratory nature and tendency to put everything in the mouth. Commonly ingested foreign bodies are coins, batteries and buttons. Foreign body ingestion in neonates is a very rare presentation and always needs important consideration as it can be a part of child abuse and can lead to serious life threatening consequences.

Keywords: Neonates, Foreign body ingestion.

Introduction

Ingestion of foreign body (FB) is a common presentation in the paediatric emergency department. It is more prevalent in children due to their curious nature and preference to oral explorations.¹ Toddlers have a susceptibility to keep everything in the mouth and hence are the most exposed group to such misfortunes.² Eighty percent of all FB ingestions occur in children. The peak incidence is between the ages of 6 months and 3 years.³ The most common FBs ingested by young children are coins. Among all of the FBs that come for medical consideration, 80-90% pass through the gastrointestinal tract without causing any obstruction, 10-20% require endoscopic elimination, and only about 1% require surgical intervention.⁴ Diagnosis becomes easy when parents give a history of FB aspiration. X-ray neck, AP and lateral view, is most commonly done for diagnosis.⁵ Oesophageal FB can damage the oesophagus and may lead to perforations and strictures and may erode the vital structures around including trachea and aorta.⁶ Ingestion of FB is extremely rare in neonates with only a few reported cases in literature.¹ FB ingestion is commonly seen in a scenario where the elder sibling introduced FB into the mouth of young one while playing or it may be a homicidal attempt on an unwanted child.⁷

Case Report

A male neonate age seven days was brought to our emergency department with insertion of nail in his pharynx by his 3years old elder brother. According to the mother, her older child who was 3 years old, informed her

.....
Department of Emergency Medicine, Aga Khan University Hospital, Karachi.

Correspondence: Sayyeda Ghazala Irfan Kazi. Email: ghazala.kazi@aku.edu

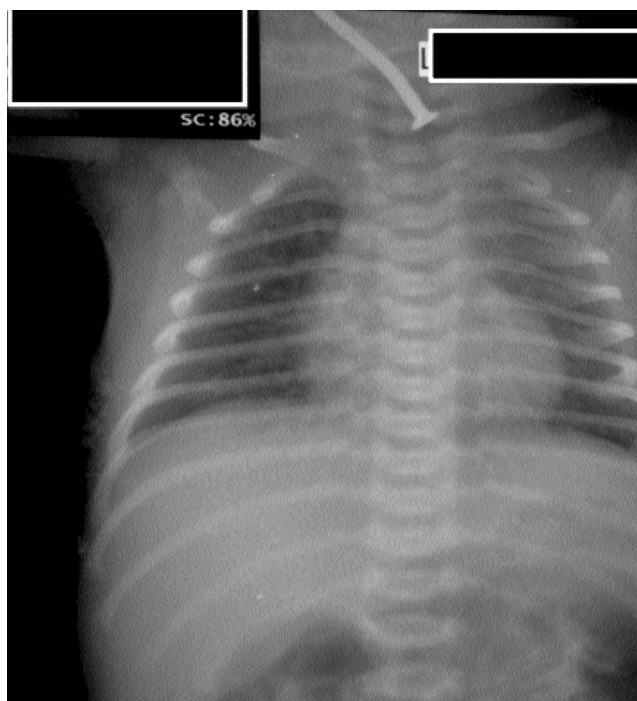


Figure-1: Plain radiograph showing nail in the neck.

that he put a metallic nail in the mouth of his youngest brother because he was crying excessively and he wanted to keep him quiet. Initially the child was taken to a private hospital where his X- ray neck, chest and upper abdomen was done which showed a nail of about 2 inches in the upper part of the neck (Figure-1). After X- ray the child was referred to our hospital for removal of nail. On arrival, the child was irritable but he was vitally stable with no signs of respiratory distress. Mother complained that he is not taking feeds since then. General physical examination as well as systemic examination was unremarkable. In emergency department, child was immediately taken to the resuscitation room. As it was revealed on X- ray that it was impacted in the pharynx, immediate laryngoscopy was done to visualize it in the hypopharynx. It was clearly visible on direct laryngoscopy and was immediately taken out with the help of an artery forcep without any bleeding. (Figure-2) The size of the nail was 2 inches (5cm). The procedure was done without anaesthesia. The child then kept in emergency for 6 hours, took his feed

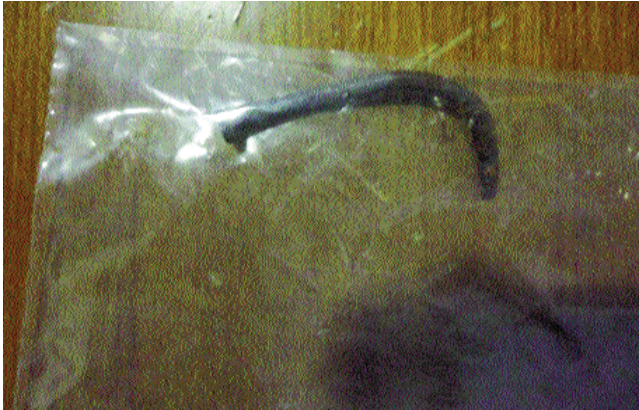

Figure-2: Nail after removal.

comfortably and then was discharged home.

Discussion

Foreign body ingestion is a common presentation in the paediatric population; however its occurrence in neonates is very rare with only few reported cases.⁸ Negligence or homicidal attempt for an unwanted child may also be a reason. Common sites for FB obstruction within the oesophagus are cricopharyngeal area, middle one-third of the oesophagus (at aortic arch) and lower esophageal sphincter (above the diaphragm).⁹ The presentation of oesophageal foreign bodies may have typical manifestations like feeding difficulty, drooling and vomiting with or without respiratory manifestation like cough, respiratory distress, and stridor. Respiratory distress is the commonest presentation of a FB especially in oesophagus in neonates, however, in our case there was no respiratory symptom. The respiratory manifestations are mainly due to compression, collapse or erosion of trachea. Various other complications include erosion of aorta that may lead to life threatening haemorrhage, oesophageal perforation and abscess formation.¹⁰ Proper history and visualization of foreign body on radiograph of the chest helps in confirming the diagnosis. Diagnosis is easier if a family member provides a leading history, as in our case. In case of negative

radiographs and strong suspicion of foreign body, endoscopy is a preferred way to retrieve radiolucent FBs. CT scan and MRI imaging has been used to recognize the radiolucent FBs,¹¹ however endoscopic removal is a preferred method for oesophageal FBs especially in neonates. In cases of large and impacted FB, open surgery by cervical exploration is preferred over endoscopic removal.

Conclusion

Neonatal FB though rare but can lead to serious life threatening events if remain undiagnosed. Counseling of parents and caretakers should be the first step in preventing this to happen and should take adequate precautions in the presence of toddler siblings, these mishaps may be dangerous and can lead to serious consequences.

References

1. Tansneem Z, Khan MA, Uddin N. Esophageal foreign body in neonate. *J Pak Med Assoc* 2004; 54:159-61.
2. Yalçın S, Karnak I, Ciftci AO, Senocak ME, Tanyel FC, Büyükpamukçu N. Foreign body ingestion in children: An analysis of pediatric surgical practice. *Pediatr Surg Int* 2007; 23: 755-61
3. Dahshan A. Management of ingested foreign bodies in children. *J Okla State Med Assoc* 2001; 94: 183-6.
4. Wahebeh G, Wyllie R, Kay M. Foreign Body ingestion in infants and children, location. *Clin Pediatr* 2002; 41: 633-40.
5. Singh R, Pandit C, Gupta D, Vajifdar H. Foreign body esophagus in a neonate: Unusual age and unusual presentation. *J Anaesthesiol Clin Pharmacol* 2012; 28: 258-60.
6. Jiraki K. Aortoesophageal conduit due to a foreign body. *Am J Forensic Med Pathol* 1996; 17: 347-8.
7. Zameer M, Kanojia RP, Thapa BR, Rao KL. Foreign body oesophagus: A common occurrence at an uncommon age. *Afr J Pediatr Surg* 2010; 7: 114-6.
8. Pujar V, Joshi S, Dhaded S. Unusual Cause of Esophageal Obstruction in a Neonate Presenting as Esophageal Atresia. *J Neonatal Surg North Am* 2013; 2: 47.
9. Singh B, Bhagat S, Kataria G, Kaur G, Singh R. Unusual Esophageal Twin Foreign Body (Glass Marble) in a Neonate. *J Health Allied Sci* 2013; 12: 21.
10. Singh H, Dhingra B, Yadav D, Aggarwal V. Esophageal Foreign Body in a Neonate: An Unusual Age of Presentation. *J Nepal Paediatr Soc* 2012; 32: 79-80.
11. Opananon S, Akaraviputh T, Methasate A, Sirikun J, Laohapensang M. Endoscopic management of foreign body in the upper gastrointestinal tract: A tertiary care center experience. *J Med Assoc Thai* 2009; 92: 17-21.