



THE AGA KHAN UNIVERSITY

eCommons@AKU

Department of Emergency Medicine

Medical College, Pakistan

January 1997

# Special maneuver for removal of an impacted bronchial foreign body at thoracotomy

SH Khan

Asad Mian

Aga Khan University, [asad.mian@aku.edu](mailto:asad.mian@aku.edu)

Q Khan

N Khan

Follow this and additional works at: [https://ecommons.aku.edu/pakistan\\_fhs\\_mc\\_emerg\\_med](https://ecommons.aku.edu/pakistan_fhs_mc_emerg_med)



Part of the [Emergency Medicine Commons](#)

## Recommended Citation

Khan, S., Mian, A., Khan, Q., Khan, N. (1997). Special maneuver for removal of an impacted bronchial foreign body at thoracotomy. *Journal of College of Physicians and Surgeons Pakistan*, 7(3), 133-135.

**Available at:** [https://ecommons.aku.edu/pakistan\\_fhs\\_mc\\_emerg\\_med/127](https://ecommons.aku.edu/pakistan_fhs_mc_emerg_med/127)

# SPECIAL MANEUVER FOR REMOVAL OF AN IMPACTED BRONCHIAL FOREIGN BODY AT THORACOTOMY

Saima H Khan, Asad I Mian, Qaisar M Khan and Naeem-uz-Zafar Khan\*

**ABSTRACT:** Tracheobronchial foreign body aspiration is a common, but often unobserved event in children. A delay in diagnosis can lead to difficulty in removal of the aspirated object. The present case report highlights a special intraoperative maneuver at thoracotomy that was adopted to remove an impacted foreign body that could not be removed at bronchoscopy.

**KEY WORDS:** Foreign bodies Thoracotomy Bronchiectasis

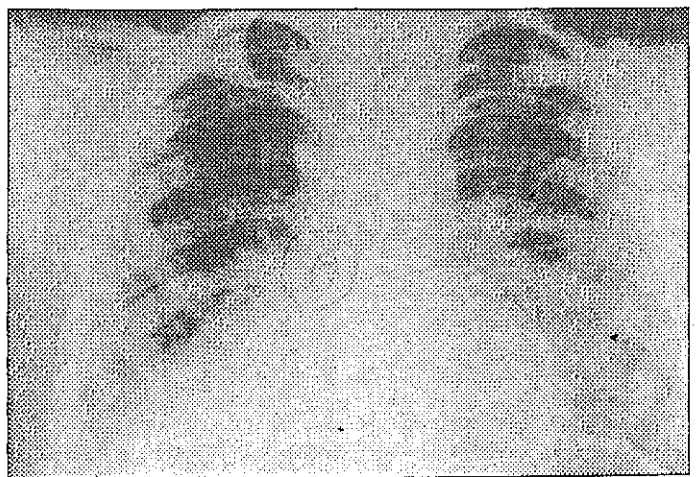
## INTRODUCTION

Aspirated objects in the airway of children still remains a significant cause of morbidity and mortality<sup>1,3</sup>. Diagnosis can be made on the basis of a history of foreign body aspiration, radiographic signs, and confirmed on bronchoscopy<sup>2,3</sup>. With the development of modern endoscopic techniques and controlled anaesthesia, most foreign bodies can be removed safely with a bronchoscope<sup>1,4</sup>. Open surgery for removal of a foreign body and an irreversibly damaged lung (bronchiectasis, lung abscess, etc.) is rarely needed<sup>1</sup>. In the past 4 years, only in 2 cases, including the present case report, thoracotomy had to be undertaken for removal of foreign body.

## CASE REPORT

A six year old boy was admitted with a week long history of high grade fever, dyspnea and cough with purulent sputum. On further inquiry, it was revealed that these symptoms had been present intermittently over the past seven months. There was no definite history of foreign body aspiration or contact with any tuberculous case. Investigations done elsewhere included an ESR of 40, and several chest radiographs, all of which showed a localized opacity in the lower lobe of the right lung. The child had initially received treatment for pneumonia, but around five months prior to presentation, anti-tuberculous therapy was also started. On examination, the child was anaemic, febrile and tachypnoic. Breath sounds were diminished in the right lower zone of chest. A chest radiograph revealed a rectangular radiodense shadow in the right lower segment with collapse of affected lobe (Fig. 1). Previous radiographs taken elsewhere had a similar shadow as mentioned above that went unnoticed. Patient was put on intravenous antibiotics and chest physiotherapy was started. Two days later bronchoscopy under fluoroscopic control was performed. The foreign body appeared to be a cup-shaped object that could not be negotiated proximally. In addition,

cavitation had developed which permitted the object to be displaced distally. Because of the unsuccessful bronchoscopic attempt at removal of the foreign body, a thoracotomy had to be performed two days later. On opening the thoracic cavity, the medial basal segment of the right lung was found to be collapsed, with cavitation, and contained a large amount of pus; this segment was resected. On searching for the foreign body, which was impacted in more proximal bronchus we realized that localization of its exact position by palpation was difficult owing to the marked enlargement of the surrounding pulmonary hilar lymph nodes. In order to localize the object and subsequently remove it, we decided to complement the thoracotomy with intraoperative bronchoscopy. With the patient still in the left lateral position, and continued general anaesthesia, the endotracheal tube was replaced by a bronchoscope. Through this a foreign body extracting forcep was introduced, thus pushing the foreign body distally. In this manner localization at the hilum was made possible (Fig. 2). As the bronchus supplying medial basal segment was already closed while resecting that segment, a bronchotomy was made in lower tube bronchus and the object was extracted. Bronchotomy was closed with prolene. An under water seal drainage was placed and the thoracotomy incision

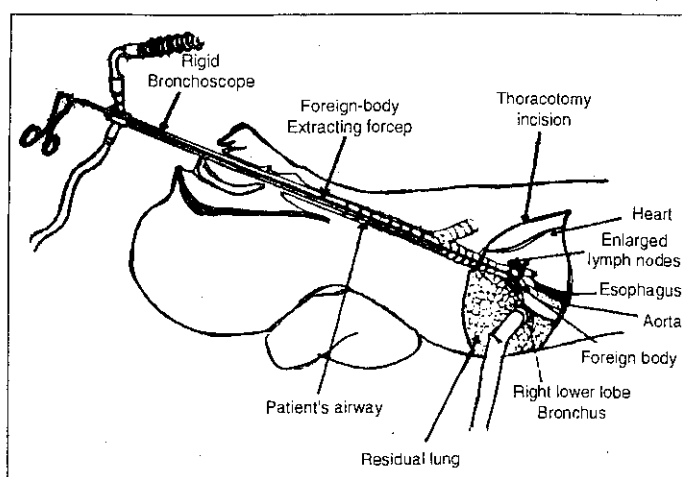


**Figure 1** Chest radiograph (at admission) showing a radio-opaque foreign body in the right lower lobe segment and a collapsed and fibrosed lower lobe.

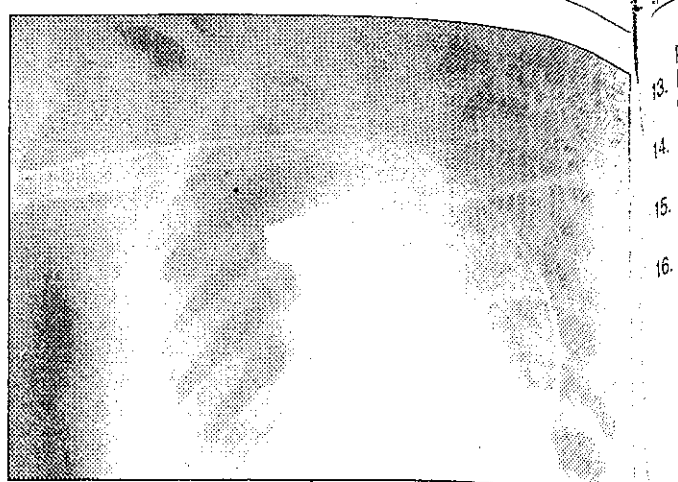
\*The Aga Khan University Hospital, Karachi, Pakistan.

\*Department of Pediatric Surgery, Pakistan Institute of Medical Sciences, Islamabad, Pakistan.

Received October 7, 1996; accepted May 14, 1997



**Figure 2** Diagrammatic showing the foreign-body extracting forcep being used to push the object distally.



**Figure 3** Post operative chest radiograph of the patient showing satisfactory lung expansion.

closed. The foreign body was a cup shaped metallic object of unknown origin. Postoperative progress was satisfactory with rapid expansion of residual lung (Fig. 3). The patient was allowed to go home a week later.

## DISCUSSION

Foreign body aspiration is a common problem with 80% of all aspirations occurring in children<sup>2,5,7</sup>. Most occur between the ages of six months and four years<sup>2</sup>. It accounts for as many as 500 to 3000 deaths per year in the United States alone<sup>2</sup>. While obstruction of the larger airways produce dramatic symptoms, that of the smaller airways often go unnoticed by parents, or the history may be omitted or forgotten<sup>8-10</sup>. This, coupled with low index of suspicion of medical personnel, leads to a delay in diagnosis resulting in complications. Aspirated objects tend to get lodged into the dependant bronchi where they trigger an inflammatory response. This produces a vicious cycle of obstruction and further inflammation culminating in atelectasis and subsequent pneumonia<sup>4</sup>, as seen in our patient. Reports exist of patients being treated for as long as twenty years for asthma when actually a foreign body was present<sup>11</sup>.

Early diagnosis and prompt treatment is mandatory for the prevention of serious complications. Radiographic findings are nonspecific, except for presence of radio-opaque foreign body. Diagnostic bronchoscopy is therefore warranted in a child with a long history of paroxysms of coughing or recurrent pneumonia<sup>12</sup> but the facilities of bronchoscopy are available in only a few places in our country<sup>13</sup>.

The success rate for removal of foreign body by endoscopy has reached 95% to 99%, with the modern techniques of fluoroscopy and anaesthesia<sup>14,16</sup>. An early diagnosis and fewer complications also ensure this. Thoracotomy for foreign body removal has been reported in 1% to 2% of patients by most authors<sup>7,12,17,18</sup>, but one series reported a rate as high as 8%<sup>1</sup>. In the special maneuver that we used, thoracotomy was combined with an intraoperative bronchoscopy. This technique helped in localizing a foreign body, which on thoracotomy alone was difficult to distinguish from the surrounding hilar structures. A thorough literature search did not reveal a similar approach.

The difficulties encountered during the procedure, and thoracotomies in general, highlight the need for early diag-

nosis of a possible foreign body aspiration. Education of parents, child-care providers and medical personnel can reduce the sequelae of a late diagnosis<sup>1,13</sup>. Physicians should remain aware of the possibility of the presence of foreign body in children with indolent pulmonary symptoms despite adequate treatment, and especially not miss the radioopaque ones.

## REFERENCES

1. Thompson GP, Utz JP, McDougall DC. Pediatric tracheobronchial foreign bodies: a case report. *Minn Med* 1990; 76: 19-21.
2. Calhoun JH, Grover FL, Chap. 17 Tracheobronchial aspiration. In: Webb WR, Besson A (eds). *Thoracic surgery. Surgical management of chest injuries*. St. Louis, Mosby Year Book, Inc.; vol 7: 142-50, 1991
3. Healy GB: Chap. 15 Aerodigestive tract foreign bodies. In: Fallis JC, Filler RM, Lemoine G. *Pediatric thoracic surgery*. New York, Elsevier Science Publishing Company, Inc 1991; 192-200.
4. Hamilton AH, Carswell F, Wisheart JD. The Bristol Children's Hospital experience of tracheobronchial foreign bodies 1977-87. *Bristol Med Chir J* 1989; 104: 72-4.
5. Welch KJ, Ravitch MM. *Pediatric Surgery* 4th. Ed 619, 1985
6. Fink JA, Klein RL. Complications of Heimlich maneuver. *J Pediatr Surg* 1989; 24: 486-7.
7. Moazam F, Talbert JL, Rodgers BM. Foreign bodies in the pediatric tracheobronchial tree. *Clin Pediatr* 1983; 148.
8. Blazer S, Naveh Y, Friedman A. Foreign body in the airway. A review of 200 cases. *Am J Dis Child* 1980; 134: 68-71.
9. Tareen DC Jr, Falterman KW, Arensman RM. Complications of the fogarty catheter technique for removal of endotracheal foreign bodies. *J Pediatr Surg* 1989; 24: 613-5.
10. Robert E. Spelunking in the pediatric airway: Exploration with a flexible fibreoptic bronchoscope. *Ped Clin North Am* 1984; 3:
11. Denny MK, Berkas EM, Snider TH, Nedwicki EG. Foreign body bronchiectasis. *Dis Chest* 1968; 53: 613-6.
12. Puhakka H, Svedstrom E, Kero P, Valli P, Iisalo E. Tracheobronchial foreign bodies. A persistent problem in

- pediatric patients. *Am J Disc Child* 1989; 143: 543-5.
3. Khan MN, Abbasi Z, Khan SA. Tracheobronchial foreign bodies in children. *J Surg* 1991; 2: 52-5.
4. Weissberg D, Schwartz I. Foreign bodies in the tracheobronchial tree [see comments]. *Chest* 1987; 91: 730-3.
5. Kosloske AM. Bronchoscopic extraction of aspirated foreign bodies in children. *Am J Disc Child* 1982; 96: 924-7.
16. Mantel K, Butenandt I. Tracheobronchial foreign body aspiration in childhood: A report on 224 cases. *Eur J Pediatr* 1986; 145: 211-6.
17. Newman, G.E.; Effman, E.L.; Putman, C.E.: Pulmonary aspiration complexes in adults. In: Keats, T.E. (ed.): *Current problems in diagnostic radiology*. Chicago, Year Book Medical Publishers, Inc. 1982.
18. Cotton E, Yasuda K. Foreign body aspiration. *Pediatr Clin North Am* 1984; 31: 937-41.