



THE AGA KHAN UNIVERSITY

eCommons@AKU

Department of Emergency Medicine

Medical College, Pakistan

January 1997

Late onset oesophageal perforation due to gunshot injury of chest: successful non-operative management in a young child

Asad Mian

Aga Khan University, asad.mian@aku.edu

Saima H. Khan

Naeem -uz-Zafar Khan

Follow this and additional works at: http://ecommons.aku.edu/pakistan_fhs_mc_emerg_med



Part of the [Emergency Medicine Commons](#)

Recommended Citation

Mian, A., Khan, S. H., Khan, N. (1997). Late onset oesophageal perforation due to gunshot injury of chest: successful non-operative management in a young child. *Journal of Surgery Pakistan*, 2(1), 17-20.

Available at: http://ecommons.aku.edu/pakistan_fhs_mc_emerg_med/126

LATE ONSET ESOPHAGEAL PERFORATION DUE TO GUNSHOT INJURY OF CHEST: SUCCESSFUL NONOPERATIVE MANAGEMENT IN A YOUNG CHILD.

A Case Report

ASAD I. MIAN*, SAIMA H. KHAN*, M. NAEEM-UZ-ZAFAR KHAN**

ABSTRACT:

Penetrating firearm injuries of the chest have become commonplace in children living in violent urban areas. Esophageal perforation may present as a late manifestation of paediatric thoracic trauma due to gunshot injury. Opinion varies as to the surgical or nonsurgical management of such a patient. The authors report a case of a 12-year-old girl who presented with a similar dilemma and her successful conservative management, that they opted for, is discussed.

KEYWORDS: *Esophageal perforation, firearm injuries, penetrating thoracic trauma.*

INTRODUCTION

Penetrating thoracic trauma by high-velocity projectile accounts for 10% to 15%^{1,2} of childhood firearm injuries, and is on the rise.^{3,4} It is the commonest cause of thoracic injury in children 12-years of age or older.⁵ The lesions are diverse and may involve any intrathoracic structure.⁶ Perforation of the esophagus, due to firearm, is the most severe complication of esophageal injury and a life-threatening condition that requires prompt diagnosis and treatment.^{3,7} Unfortunately, damage to the esophagus due to intrathoracic trauma is often overlooked during the initial examination, or is not immediately apparent because of delay in presentation.⁸ Management of cases of delayed onset esophageal perforation remains controversial.^{7,19}

Herein we describe the case of a child who developed late onset esophageal perforation due to firearm injury of the chest. Her successful nonoperative management is reported and discussed as described in literature.

CASE REPORT:

A twelve-year-old girl presented 24 hours after sus-

taining a bullet injury of the chest. The injury had led to profuse bleeding from her right shoulder. The girl developed progressive difficulty in breathing and cyanosis. Bleeding was curtailed by pressure bandage until her arrival to the ER, where she was found to be in severe pain and obvious respiratory distress. She had heart rate of 120/min., respiratory rate of 30/min., and blood pressure of 90/60 mm of Hg. She had a 1cm. x 1cm. wound of entry along the posterior axillary fold on the left axilla, and the wound of exit was 5cm x 3cm along the right suprascapular region. Left side of the chest had decreased expansion and absent breath sounds. A chest radiograph showed an air-fluid level on the left and a needle thoracentesis was diagnostic for a hemopneumothorax. Immediate chest intubation was done and hemorrhagic fluid drained.

In the intensive care unit broad-spectrum intravenous antibiotics (a third generation cephalosporin, an aminoglycoside and metronidazole) were prescribed, and oral intake was allowed. The chest tube was removed after four days but subsequently the child developed a continuous high grade fever. Blood counts showed a persistent leucocytosis with neutrophilia. On the fifth day of admission, thick pus and saliva started oozing from the wound of exit, followed two days later by frank discharge of foul smelling food material from the same site. This was the first clinical indication of a delayed presentation of esophageal

All correspondence to:
M. Naeem-uz-Zafar Khan, Department of Paediatric Surgery, The Children's Hospital, P.I.M.S., Islamabad, Pakistan.

perforation, secondary to the transmediastinal trajectory of a projectile. A gastrografin (radiographic contrast) study under fluoroscopic control on the eighth post-traumatic day, confirmed the presence of a perforation of the thoracic esophagus at the level of the third thoracic vertebra. There was leakage of contrast that communicated with the skin through the wound of exit. Surprisingly, on the left side of the chest, leakage of contrast extends down to the level of the left dome of the diaphragm (Fig.1).

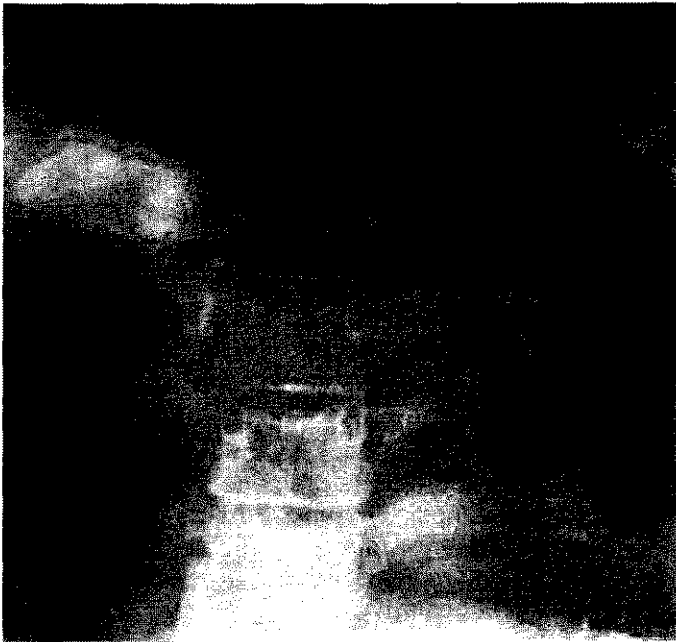

Figure 1. Gastrografin contrast study performed eight days subsequent to thoracic gunshot injury confirmed esophageal perforation; leakage of contrast can be seen on both sides of the thorax (arrows).

The patient was put on nasogastric feeding in prop-up position, with a high caloric intake. Continuous suction at the wound of exit and toilet of the wound of entry was initiated, alongwith continuous pharyngeal suction and chest physiotherapy; intravenous antibiotic were continued. On the fourteenth post-trauma day, once again the left side of the chest showed diminished ventilation. A chest radiograph and a subsequent thoracentesis revealed a left-side empyema thorax, which was drained by a wide thoracostomy tube with an underwater seal. With the chest tube in place and continued drainage of the purulent fluid, and subsequent chest radiographs showed progressive improvement.

Conservative management of our patient helped put her on the path of steady recovery. Her Pyrexia settled and her thorax cleared. Chest tube was removed and subsequent chest radiograph showed clear lung fields. Repeat gastrografin contrast studies over subsequent weeks showed progressive reduction of the fistulous tracts (Fig. 2A & B).

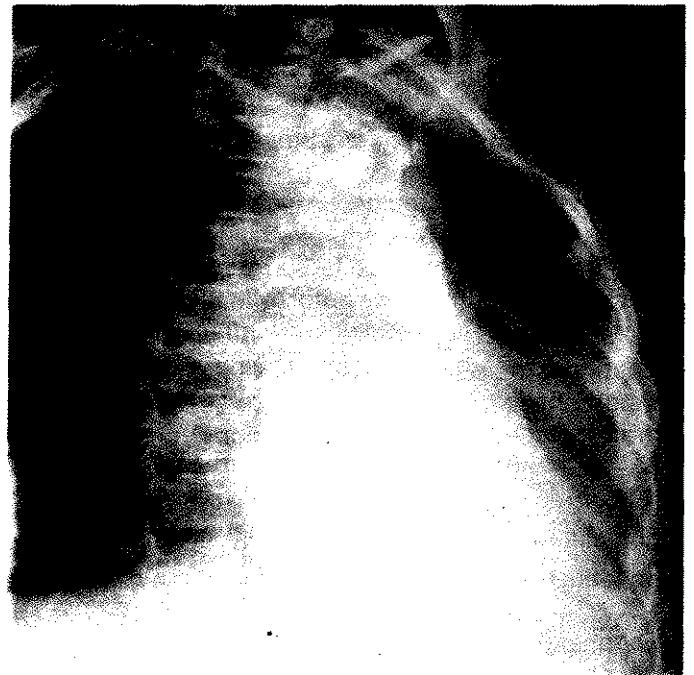


Figure 2A

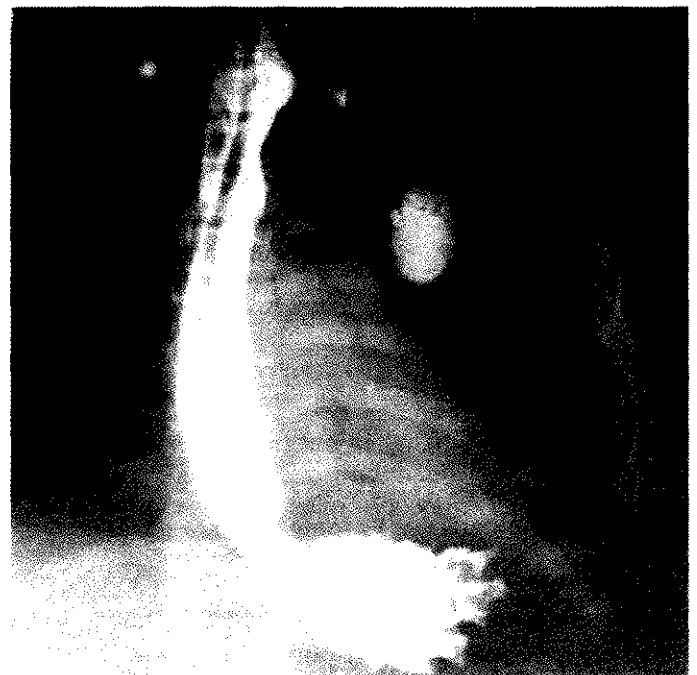

Figure 2B. Repeat gastrografin studies over the subsequent weeks showing progressive decrease in the sizes of the fistulous tracts. These were performed on the fifteenth (A) and the thirtieth (B) post-trauma days, respectively.

DISCUSSION:

Whenever a penetrating wound to the chest has crossed the midline, one actively needs to exclude injury to the mediastinal structures, such as the heart, aortic arch, bronchial tree, and the esophagus, even though injury to such structures may not be immedi-

ately clinically apparent.^{8,9} Esophageal perforations occur most commonly as an iatrogenic complication (75% to 77%),^{3,10,11} with chest trauma accounting for only 2% to 10%^{1,3,10,12,13} of all esophageal injuries. The esophagus is infrequently the site of isolated trauma because of its protected position and small diameter. The seriousness of perforation is heightened by the fact that the esophagus is surrounded by loose connective tissue that does not effectively prevent dissemination of infection and inflammation; without treatment the outcome usually is fatal.⁷ However, most reports have been based on adult series with few children included. Thus the conclusions regarding etiology, treatment and outcome may differ and may not be directly applicable to the paediatric patient.⁷ Few guidelines are available which facilitate treatment of patients with noniatrogenic injuries of the esophagus.¹⁴

Esophageal perforations due to penetrating trauma of the chest may lead to a linear tear in the esophagus allowing leakage into the mediastinum, producing mediastinitis, and immediate or delayed rupture into the pleural space, producing empyema.¹⁵ These two complications were late manifestations in our patient. There are distinct clinical patterns of presentation, depending on the level of esophageal perforation. At least 75% of patients with perforation have dysphagia and excruciating pain on swallowing.¹⁵ In the older child, severe pleuritic pain or substernal pain are the hallmarks of perforation. Fever may often be quite high and a rapid, toxic progression to shock may occur in patients of any age, but seems to be commoner in older children with free pleural involvement. However, esophageal perforations may occasionally present in an obscure fashion, as in our patient, without the dramatic explosion described above. In such instances, the diagnosis may be missed for many days or weeks.¹⁰ Late sequelae are rare because patients do not survive the initial trauma or because the injury is recognized early and treated appropriately.¹⁶ In our patient a fistula between the esophagus and skin via the wound of exit was a late sequela because of unrecognized trauma to the esophagus.

Early diagnosis of esophageal perforation is suspected clinically and confirmed radiologically.¹⁵ The results of plain radiographs of the chest and neck will suggest the diagnosis in the majority of cases.⁷ Characteristic findings are subcutaneous emphysema, pneumomediastinum, pleural effusion and/or pneumothorax, which were absent in our patient. It is noteworthy that upper thoracic perforations, as in our case, present with left-sided effusion, while lower thoracic perforations have

right-sided signs. This is contrary to previous findings.⁷ Anatomically the left pleura is closely related to the esophagus in the superior mediastinum, whereas the right pleura is in intimate contact with the distal two-thirds of the esophagus, except where it is crossed by the azygos vein. This most likely accounts for the pattern of presentation. Plain radiographs should be followed by water-soluble (e.g. gastrografin; diatrizoate meglumine) study to accurately delineate the pathology. If contrast study findings are negative in a case of suspected perforation, a dilute barium study should be performed.^{11,17} Esophagoscopy offers no diagnostic advantages and may in fact enlarge the perforation, complicating subsequent repair.¹⁵

The most appropriate therapy for esophageal perforation depends on the site of perforation, the interval between the perforation and its recognition, and the systemic response to injury.¹⁰ In the past authors discouraged conservative (i.e. nonoperative) management that was proposed by Mengoly and Klassen in 1965.¹⁰ The "drain and hope" regimen was thought to be a disappointment and hence a more aggressive approach was advocated. They suggested that primary suture with appropriate drainage should be attempted in early diagnosis (within 24 hours of perforation); for late cases only drainage should be performed. However in recent years varying accounts of management and prognosis have been reported for late recognized perforation. Some current studies reveal that despite a high incidence of associated complications, survival following esophageal perforations is high and the impact of delayed diagnosis is decreasing.^{12,14} On the other hand, others still report high morbidity and mortality due to delayed diagnosis and continue to advocate a surgical approach.¹⁸

Literature review revealed controversial management options for cases in which the delay in diagnosis exceeds 24 hours.^{7,19} In our patient, the perforation was a delayed manifestation of firearm injury. We opted for a conservative approach. Our management is in contrast to protocols for adults, for whom the gold standard remains early aggressive surgical therapy, aiming for primary closure of the defect.^{7,19,21} We conclude that with appropriate conservative management, a good outcome can be expected with a traumatic esophageal perforation presenting late.

REFERENCES:

1. Nance, M.L. Sing R.F., Reilly P.M., et al: Thoracic gunshot wounds in children under 17 years of age. *J Pediatr Surg.* 1996, 31(7):931-35.

2. Nance M.L., Templeton J.M., O'Neill J.A.: Socioeconomic impact of gunshot wounds in an urban pediatric population. *J Pediatr Surg.* 1994, 29:39-43.
3. Postlethwait R.W.: *Surgery of the esophagus.* New York, Appleton-Century-Crofts, 1979.
4. Zavoski R.W., Lapidus G.D., et al: A population-based study of severe firearm injury among children and youth. *Pediatrics.* 1995, 96(2 Pt 1):278-82.
5. Meller J.L., Little A.G., Shermata D.W.: Thoracic trauma in children. *Pediatrics.* 1984, 74:813.
6. Reinberg O., Genton N., Lacheretz M.: Particularities of thoracic trauma in children. In: Webb W.R., Besson A. (eds.): *Thoracic surgery: Surgical management of chest injuries* (chapter 34). St. Louis, Mosby-Year Book, 1991, 7:340.
7. Panieri E., Millar A.J.W., et al: Iatrogenic esophageal perforations in children: Patterns of injury, presentation, management, and outcome. *J Pediatr Surg.* 1996, 31(7):890-95.
8. Haller J.A. Thoracic injuries. In: Welch K.J., Randolph J.G., Ravitch MM, et al: *Pediatric surgery.* Chicago, Year Book Medical Publishers, Inc. (chap 17); 1986, 143-53.
9. Falcon O. Knott C., Elkins R.C. Gunshot wounds traversing the mediastinum: Guidelines for evaluation and management. *J Okla State Med Assoc.* 87(4): 1994, 174-7.
10. Popovici, Z.: Esophageal injuries. In: Webb, W.R.; Besson, A. (eds.): *Thoracic surgery: Surgical management of chest injuries* (chap 45). St. Louis, Mosby-Year Book. 1991, 7:443-66.
11. Sawyer R., Phillips C., Vakil N. Short and long-term outcome of esophageal perforations. *Gastrointest endosc.* 1995, 41(2):130-4.
12. Reefder L.B., DeFilippi V.J., Ferguson MK.: Current results of therapy for esophageal perforations. *Am J Surg.* 1996, 169(6):615-7.
13. Besson A., Savary M.: Trauma of the esophagus. In: Besson A., Saegesser R. (eds.): *SA colour atlas of chest trauma and associated injuries* (chap. 11) London, Wolfe Medical Publications, Ltd. (2): 1983, 251-316.
14. Weimam D.S., Walker W.A., Brosnan K.M.: Noniatrogenic esophageal trauma. *Ann Thorac Surg.* 1995, 59(4):845-9.
15. Weber T.R.: Esophageal rupture and perforation. In: Welch K.J., Randolph J.G., Ravitch M.M.; et al: *Pediatric Surgery* (chap 73) Chicago, Year Book Medical Publishers, Inc.: 1986, 725-27.
16. Deslauriers J., Desaulniers D., Pomerleau S.: Late sequelae of thoracic injury. In: Webb W.R., Besson A. (eds.): *Thoracic surgery: Surgical management of chest injuries* (chap. 48) St. Louis, Mosby-Year Book, Inc.; vol 7: 1991, 513-35.
17. James A.E., Montaly R.J., Chafee V., et al: Barium or gastrografin: which contrast media for diagnosis of esophageal tears? *Gastroenterology*, 1975, 68:1103.
18. Andrade A.R. T-tube intubation in the management of late traumatic esophageal perforations: Case report. *J Trauma.* 1994, 37(1):131-2.
19. White R.K., Morris D.M. Diagnosis and management of esophageal perforations. *Am Surg.* 1992, 8:112-19.
20. Santos G.H., Frater R.W.M. Transesophageal irrigation for the treatment of mediastinitis produced by esophageal rupture. *J Thorac Cardiovasc Surg.* 1986, 91:57-62.
21. Flynn A.E., Verrier E.D., Way L.W., et al: Esophageal perforations. *Arch Surg.* 1989, 124-1211-14.

RECEIVED
BY THE
LIBRARY
JAN 15 1997