



THE AGA KHAN UNIVERSITY

eCommons@AKU

---

Department of Surgery

Department of Surgery

---

June 2015

# Diagnosis of second mesiobuccal canal in maxillary first molars among patients visiting a tertiary care hospital.

Muhammad Hasan Hameed  
*Aga Khan University*, [muhammad.hasan@aku.edu](mailto:muhammad.hasan@aku.edu)

Farhan Raza Khan  
*Aga Khan University*, [farhan.raza@aku.edu](mailto:farhan.raza@aku.edu)

Follow this and additional works at: [http://ecommons.aku.edu/pakistan\\_fhs\\_mc\\_surg\\_surg](http://ecommons.aku.edu/pakistan_fhs_mc_surg_surg)

 Part of the [Dentistry Commons](#), and the [Surgery Commons](#)

---

## Recommended Citation

Hameed, M. H., Khan, F. R. (2015). Diagnosis of second mesiobuccal canal in maxillary first molars among patients visiting a tertiary care hospital. *Int J Biomed Sci*, 11(2), 107-108.

**Available at:** [http://ecommons.aku.edu/pakistan\\_fhs\\_mc\\_surg\\_surg/618](http://ecommons.aku.edu/pakistan_fhs_mc_surg_surg/618)

# Diagnosis of Second Mesiobuccal Canal in Maxillary First Molars among Patients Visiting a Tertiary Care Hospital

Muhammad Hasan<sup>1</sup>, Farhan Raza Khan<sup>2</sup>

<sup>1</sup>Instructor, Dental Section, Department of Surgery, The Aga Khan University Hospital, Karachi, Pakistan;

<sup>2</sup>Assistant Professor, Dental Section, Department of Surgery, The Aga Khan University Hospital, Stadium Road, Karachi, Pakistan

The mesiobuccal root of the maxillary first molar has generated more research and clinical investigation than any other root. An inability to detect and treat a second mesiobuccal canal (MB2) is a reason for endodontic failure in maxillary first molars (1). Modifications in endodontic access and detection techniques, along with advancements in illumination and magnification technology, have aided in the location and treatment of the second mesiobuccal canal of maxillary first molars (2). Studies have shown an incidence of MB2 in maxillary first molars to be 63% (3).

The objective of our study was to determine the frequency of the second mesiobuccal canal in the permanent maxillary first molars with magnification loupes ( $\times 4.0$ ). This study was conducted in the dental section of the Aga Khan University Hospital located in Karachi, Pakistan. In this cross sectional study, a total of 53 teeth were assessed clinically using magnification loupes for MB2 canal in mesiobuccal root of first maxillary molars. Detection of MB2 canal was done through a clinical access cavity preparation with magnification ( $\times 4.0$ ) with controlled pulp chamber floor troughing. Before recruiting patients, this study was approved by the Institution's Ethical Review Committee. (Ref: 1567-Sur-ERC-2010).

We were able to detect MB2 in 27 out of 53 (50.9%) of maxillary first molars. It was found that males tend to have a higher proportion of MB2 canals up to 31% as compared to females in whom the MB2 could be identified only 19% of the time.

Weine FS *et al.* were the first to report that clinician's inability to locate and fill the second mesiobuccal canal can result in an endodontic failure in maxillary molars (4). This may be attributed to the anatomical diversity in MB2 canal system which invariably originates within the sub-pulpal groove connecting the two main canals, making its detection challenging (5).

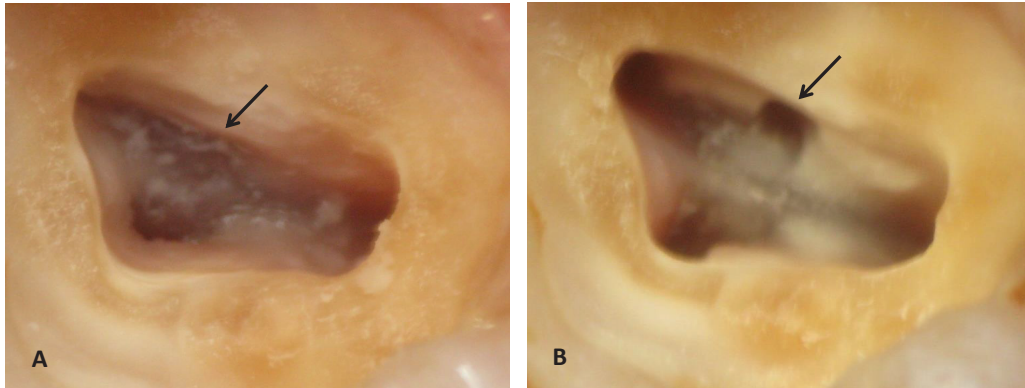
Within the limitations of our study, we conclude that the use of the magnification loupes ( $\times 4.0$ ) enhanced the detection (50.9%) of the MB2 canals in the maxillary first molars. In addition, the prudent clinician is suggested to employ the canal-search strategies such as chamber floor troughing, assessment of radiographic width of the mesiobuccal root, CEJ perimeter, tooth angulation, cusp tip-pulp floor distance (CPFD), and the laws of orifice location to successfully locate the second mesiobuccal canal system to improve the outcome of endodontic treatment (Figure 1). (*Int J Biomed Sci* 2015; 11 (2): 107-108)

**Keywords:** Mesiobuccal canal; maxillary first molar; magnification

---

**Corresponding author:** Dr. Muhammad Hasan, Instructor, Dental Section, Department of Surgery, The Aga Khan University Hospital, Stadium Road, Karachi, Pakistan. Tel: +92 333 383 1183. E-mail: hasan82@msn.com.

**Copyright:** © 2015 Muhammad Hasan *et al.* This is an open-access article distributed under the terms of the Creative Commons Attribution License (<http://creativecommons.org/licenses/by/2.5/>), which permits unrestricted use, distribution, and reproduction in any medium, provided the original author and source are credited.



**Figure 1.** Clinical case demonstrating initial access opening and identification of the developmental groove between the palatal and primary mesiobuccal canals [black arrow] [A], Controlled chamber floor troughing lead to revelation of the second mesiobuccal canal [black arrow] [B].

## REFERENCES

1. Wolcott J, Ishley D, Kennedy W, Johnson S, *et al.* A 5 yr clinical investigation of second mesiobuccal canals in endodontically treated and retreated maxillary molars. *J. Endod.* 2005; 31: 262–264.
2. Weller RN, Hartwell GR. The impact of improved access and searching techniques of detection of the mesiolingual canal in maxillary molars. *J. Endod.* 1989; 15: 82-83.
3. Hartwell GR, Bellizzi R. Clinical investigation of *in vivo* Endodontically treated mandibular and maxillary molars. *J. Endodon.* 1982; 8: 555–557.
4. Weine FS, Healey HJ, Gerstein H, Evanson L. Canal configuration in the mesiobuccal root of the maxillary first molar and its endodontic significance. *Oral. Surg. Oral. Med. Oral. Pathol.* 1969; 28: 419–425.
5. Gulabivala K, Aung TH, Alavi A, *et al.* Root and canal morphology of Burmese mandibular molars. *Int. Endod. J.* 2001; 34: 359–370.