



THE AGA KHAN UNIVERSITY

eCommons@AKU

Department of Surgery

Department of Surgery

September 2015

Laser treatment of laryngeal papillomatosis in a young child: anaesthetic and surgical management

Faisal Shamim

Aga Khan University, faisal.shamim@aku.edu

Durriya Raza

Aga Khan University

Mubasher Ikram

Aga Khan University, mubasher.ikram@aku.edu

Follow this and additional works at: http://ecommons.aku.edu/pakistan_fhs_mc_surg_surg

 Part of the [Otolaryngology Commons](#), and the [Surgery Commons](#)

Recommended Citation

Shamim, F., Raza, D., Ikram, M. (2015). Laser treatment of laryngeal papillomatosis in a young child: anaesthetic and surgical management. *JCPSP: J Coll Physicians Surg Pak*, 25(9), 698-699.

Available at: http://ecommons.aku.edu/pakistan_fhs_mc_surg_surg/608

LASER Treatment of Laryngeal Papillomatosis in a Young Child: Anaesthetic and Surgical Management

Faisal Shamim¹, Durriya Raza¹ and Mubasher Ikram²

ABSTRACT

The authors report the case of a 4-year boy who required anaesthetic and surgical care during LASER excision of laryngeal papillomatosis. He presented with hoarseness and stridor and underwent emergency tracheostomy after confirmation of laryngeal papillomas on CT scan. He required LASER treatment under general anaesthesia with a requirement of paediatric LASER-safe endotracheal tube but unfortunately, this was not available in the country. Balanced anaesthesia technique using inhalational anaesthetic, muscle relaxant and narcotic is used with modifications. After three successful surgical sessions, the airway became patent and tracheostomy was de-cannulated. The perioperative issues surrounding this process are discussed including anaesthetic induction in the patient with a compromised airway, maintenance anaesthetic techniques, methods used for ventilation during LASER surgery of the upper airway, surgical implications and hazards of LASER to the operating room personnel.

Key Words: Anaesthesia. LASER. LASER-Flex ETT. Laryngeal papillomatosis.

INTRODUCTION

Human Papilloma Virus (HPV) type 6 or 11 is most common causative organism for benign epithelial tumours of upper respiratory tract termed as papilloma.¹ Both adults and children can have this problem and may present with wheezing, hoarseness, or stridor. The goals of treatment are debulking, improvement of the voice and remission of papillomas.² Paediatric patients require multiple treatments, most commonly with the CO₂ LASER.

Anaesthesia for LASER surgery in children presents some unique challenges to the anaesthesiologist² with potentially difficult airway to contend with and any concomitant problems child may have; moreover, the apparatus being used can cause harm if proper precautions are not taken.

The purpose of reporting this case is to create awareness and disperse information to our local population about availability of LASER surgery in ENT and head and neck cancer patients.

CASE REPORT

A 4-year male child presented to emergency department with complaints of hoarseness of voice for 2 years, dyspnea for 1 week and cyanotic spells since last night. The vital sign on admission were HR 140/minute, blood pressure of 122/90 mmHg, and O₂ saturation 95% on

room air with respiratory rate of 38/minute. On examination, subcostal recessions were present. Decreased bilateral air entry and wheeze with tracheal tug was found on chest auscultation. CT scan head and neck showed laryngeal stenosis due to presence of papillomas on left vocal cord (Figure 1).

He was rushed to the operating room for emergency tracheostomy and Direct Laryngoscopy (DL) ± biopsy. The findings of CT scan were confirmed for the presence of papillomas and then patient was shifted to the Paediatric Intensive Care Unit (PICU) and discharged afterwards.

LASER assisted excision of laryngeal papillomas was planned as best treatment option. The authors were using exclusive LASER resistant endotracheal tubes (Mallinckrodt LASER-Flex Tube) and only adult size was available in the country. A comprehensive search for

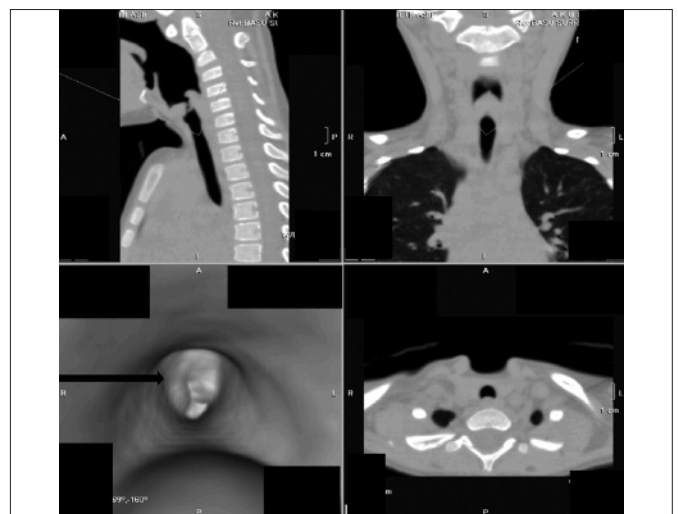


Figure 1: CT scan showing laryngeal stenosis due to presence of papilloma.

Department of Anaesthesiology¹ / Surgery², The Aga Khan University, Stadium Road, Karachi.

Correspondence: Dr. Faisal Shamim, C-16, Ali Apartment, Block-3, Gulshan-e-Iqbal, Karachi.

E-mail: faisal.shamim@aku.edu

Received: April 15, 2014; Accepted: November 01, 2014.



Figure 2: Paediatric LASER - flex endotracheal tube size 3.

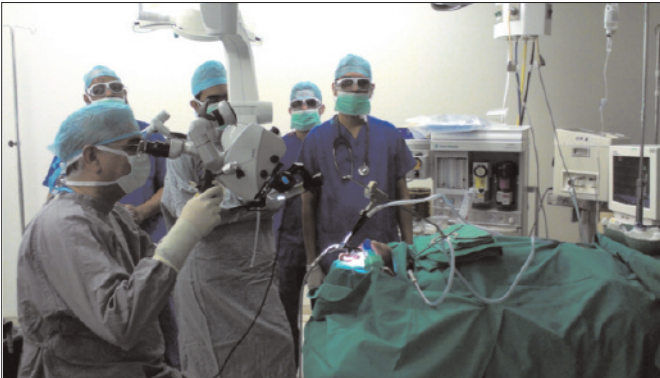

Figure 3: Conducting a LASER ENT case with safety precautions like goggles.

vendors was made at that time to import paediatric LASER flex tube and non-availability of the tube delayed the procedure for about 6 - 8 weeks. Family was counseled about anticipated number of surgical procedures, importance of specialized endotracheal tube for this surgery and complications, so the patient was discharged with tracheostomy tube in place.

After availability of only one paediatric LASER-flex tube, size 3 (Figure 2), the patient was re-admitted. Plan was discussed with family and an ICU bed was arranged. All necessary equipment for airway management including manual jet ventilator (Sander's injector) and resuscitation drugs were made available in the operating room. The mandatory precautions to conduct a LASER ENT case (goggles, 50 ml syringes filled with water, wet swabs on patient face etc.) were taken into account (Figure 3). After inhalational induction with sevoflurane in oxygen and air, LASER flex tube was inserted through the tracheostomy. Fentanyl in titrating doses (10 µg) was used to minimize procedural reflex response. During the procedure, the FIO₂ was kept at 30% and nitrous oxide was avoided. The problems encountered during procedure were movement of ETT in and out as there is very short distance between tracheostomy site and carina and airway resistance because of tube size. To overcome hypoventilation, muscle relaxant atracurium 0.5 mg/kg and high respiratory rate with pressure control mode ventilation (PCV) was used. The laryngeal papillomas, which were involving both the true and false vocal cords with subglottic extension were successfully

excised with CO₂ LASER. As it was already planned to do subsequent airway endoscopy and de-cannulation of tracheostomy at a later stage, the patient was shifted to the post anaesthesia care unit with tracheostomy.

At second stage, 1 month later, laryngeal endoscopy revealed some disease on left vocal cords so again CO₂ LASER assisted excision was done. There was no problems encountered during anaesthetic management and the procedure went uneventfully. Patient remained stable postoperatively and was discharged with tracheostomy in place. Subsequently, after 4 weeks he was scheduled for de-cannulation of tracheostomy. After inhalational induction with sevoflurane, the endoscopy showed a patent airway and the tracheostomy tube was successfully removed. The patient was kept in the theatre to observe any signs of airway obstruction. He remained stable, maintaining oxygen saturation and thus was shifted to the post anaesthesia care unit and subsequently discharged home. The patient comes for regular follow-up in the ENT clinic for fiber optic laryngoscopy and is disease-free for the last 6 months.

DISCUSSION

Anaesthetic implications in LASER surgery with special emphasis on airway management and ventilation techniques, safety principles and precautions and the limited resources of specialized equipment need to be considered for these procedures.

LASER is an acronym for Light Amplification by Stimulated Emission of Radiation that has a single wavelength, is coherent and collimated.² The clinical applications of CO₂ LASER surgery in ENT is broadly divided into oral, nasal and laryngeal indications. The laryngeal procedures are at greater risk of developing airway fire. The rapid advancement of this technology in ENT surgery has been accompanied by complications like fire hazards, making it imperative that anaesthesiologist as well as ENT surgeons understand the potential threat to their patients and themselves and be prepared to respond properly. CO₂ LASER surgery in ENT is one of those surgical procedures in which the surgical risk is minimal while the anaesthetic risk is great.³

Anaesthesia for LASER surgery of the airway presents the anaesthetist with a number of problems like shared airway, circulatory changes associated with laryngoscopy, postoperative laryngospasm and edema, operating room pollution and LASER safety precautions.³ The choice of anaesthetic technique directly influences the ability of the surgeon to perform a LASER resection, and the choice of LASER technique determines the kind of anaesthetic that can be safely used. A favorable outcome, therefore, presupposes a high level of communication and cooperation between anaesthesiologist and surgeon. So, the three main

anaesthetic techniques which are currently available to avoid the fire hazards associated with the use of conventional endotracheal tubes during LASER surgery of the airway are no tube in the airway, protection of the external surface of a conventional tube, or use of a LASER resistant tube. The technique of ventilation during non-intubation techniques are apneic oxygenation, spontaneous ventilation and jet ventilation.⁴ The ideal way of doing these cases is with LASER resistant ETT such as Mallinckrodt™ LASER flex tube.⁵ Unfortunately, in resource-limited areas, these tubes are not available and are also very expensive but it is one of the safety precautions in preventing airway fire.

The risk and dangers associated with LASER use in operating room are atmospheric contamination LASER plume, misdirection of LASER energy, gas embolism, energy transfer to an inappropriate location and fire and explosion. There are various measures that can be taken to prevent injury from LASER radiation. These include engineering controls, administrative controls, personal protective equipment and warning signs. Every institution using LASERs should have a LASER safety committee with a LASER safety officer, anaesthesiologists, operation room nurses, hospital administrator(s) and a biomedical engineer looking into the education and training of all the staff.⁶ In the event of airway fire, an immediate and planned response from operating room personnel is required. The airway fire protocol⁷ is highly desirable in this case and acts accordingly. These steps are removal of the fire source,

stop ventilation, disconnect oxygen source and flood the airway with water (ready in multiple 50 cc syringes), remove the burned ETT, examine the airway, mask ventilate the patient and re-intubate. Further management includes survey the extent of injury with flexible bronchoscope, monitor the patient for 24 hours, administer steroid to reduce inflammation and edema, provide antibiotics and ventilatory support if indicated, severe damage may need low tracheostomy.

REFERENCES

1. Tripi PA, Kandil ES, Arnold JE. Anaesthetic management for LASER excision of recurrent respiratory papillomatosis in a third trimester parturient. *J Clin Anesth* 2005; **17**:610-3.
2. Rietz CS, Tobias JD. Anaesthetic management of children with recurrent, viral laryngeal papillomatosis: a case report. *AANA J* 1996; **64**:362-8.
3. Afroza S, Bhuyan AH, Zahurul Huq Z, Hossain T, Aziz L. Anaesthetic complications in CO₂ LASER in ENT surgery. *Bangladesh J Otorhinolaryngol* 2008; **14**:30-5.
4. Biro P. Jet ventilation for surgical interventions in the upper airway. *Anesthesiol Clin* 2010; **28**:397-409.
5. Best C. Anaesthesia for LASER surgery of the airway in children. *Paediatr Anaesth* 2009; **19**:155-65.
6. Dhar P, Malik A. Anaesthesia for LASER surgery in ENT and the various ventilatory techniques. *Trends Anaesth Crit Care* 2011; **1**:60-6.
7. David S, Robert G. LASER surgery and fire hazards in ear, nose and throat surgeries. *Anesthesiol Clin* 2010; **28**: 485-96.

