



THE AGA KHAN UNIVERSITY

eCommons@AKU

Department of Surgery

Department of Surgery

March 2016

Aneurysm in the anterior inferior cerebellar artery-posterior inferior cerebellar artery variant: case report and review of literature

Saad Akhtar
Aga Khan University

Abdul Azeem
Aga Khan University

, Aamna Jiwani
Aga Khan University

Gohar Javed
Aga Khan University, gohar.javed@aku.edu

Follow this and additional works at: http://ecommons.aku.edu/pakistan_fhs_mc_surg_surg

 Part of the [Surgery Commons](#)

Recommended Citation

Akhtar, S., Azeem, A., Jiwani, ,, Javed, G. (2016). Aneurysm in the anterior inferior cerebellar artery-posterior inferior cerebellar artery variant: case report and review of literature. *Int J Surg Case Rep*, 22(3), 23-27.

Available at: http://ecommons.aku.edu/pakistan_fhs_mc_surg_surg/579



Contents lists available at ScienceDirect

International Journal of Surgery Case Reports

journal homepage: www.casereports.com

Aneurysm in the anterior inferior cerebellar artery-posterior inferior cerebellar artery variant: Case report and review of literature

Saad Akhtar^a, Abdul Azeem^b, Amyna Jiwani^c, Gohar Javed^{d,*}^a Section of Neurosurgery, Department of Surgery, Aga Khan University Hospital, Karachi, Pakistan^b Medical College, The Aga Khan University, Karachi, Pakistan^c Section of General Surgery, Department of Surgery, Aga Khan University Hospital, Karachi, Pakistan^d Section of Neurosurgery, Department of Surgery, Aga Khan University Hospital, Karachi, Pakistan

ARTICLE INFO

Article history:

Received 8 November 2015

Received in revised form 6 March 2016

Accepted 7 March 2016

Available online 10 March 2016

Keywords:

AICA-PICA variant

Aneurysm

Case report

ABSTRACT

INTRODUCTION: There are variations in the anatomy of the vertebrobasilar system amongst which the Anterior Inferior Cerebellar Artery-Posterior Inferior Cerebellar Artery (AICA-PICA) variant is thought to have a prevalence of 20–24% (based on retrospective studies). Despite this, aneurysms of the AICA-PICA variant are rare. We present a case of an AICA-PICA aneurysm and discuss its presentation and management, along with a review of literature.

PRESENTATION OF CASE: We describe the case of a 35 year old female who presented with signs of meningismus. On the basis of radiological imaging it was initially misdiagnosed as a thrombosed arteriovenous malformation (AVM). The patient was eventually discharged with a plan of interval imaging and interventional radiology (if required). The patient presented again with similar signs and symptoms. Re-evaluation of imaging revealed an aneurysm of the AICA-PICA variant which was managed surgically.

DISCUSSION: Aneurysms of the AICA-PICA variant are rare. The radiological features and surgical management represent a unique clinical entity and are discussed below.

CONCLUSION: The prevalence of the AICA-PICA variant might be high but aneurysms in this vessel are rare. The scant knowledge available on this subject makes it a diagnostic difficulty.

© 2016 The Authors. Published by Elsevier Ltd. on behalf of IJS Publishing Group Ltd. This is an open access article under the CC BY-NC-ND license (<http://creativecommons.org/licenses/by-nc-nd/4.0/>).

1. Introduction

Aneurysms of posterior circulation account for only 10–15% of all intracranial aneurysms and amongst these aneurysms, AICA aneurysms account for only 1–2% [1]. AICA aneurysms can be associated with arteriovenous malformation (AVM) and cerebello-pontine tumours [1–3]. However, aneurysms of the AICA-PICA variant are exceedingly rare. Only 5 cases of such aneurysms that were surgical managed have been reported in literature.

In this case report, we described a patient who presented with an AICA-PICA aneurysm which was initially misdiagnosed as a thrombosed AVM. We also discussed the presentation, radiological findings and surgical management of such aneurysms. Pertinent literature was also reviewed.

2. Presentation of case

A 35 year old female, with no known co-morbid conditions, presented with complaints of severe headache followed by altered sensorium for 2 days. On examination, she had a Glasgow Coma Score (GCS) of 9/15 (E2 V2 M5), bilateral gross papilledema and down going plantars. No focal neurological deficit was seen. CT-scan revealed bilaterally dilated lateral ventricles and cerebellar haemorrhage. While cerebral angiogram showed focal dilation of the meningeal branch of the right vertebral artery. This was thought to be secondary to the presence of a thrombosed AVM and was the possible source of the haemorrhage [Figs. 1 and 2]. External Ventricular Drain (EVD) was placed due to hydrocephalus which was caused by intraventricular haemorrhage, secondary to sub-arachnoid haemorrhage. This resulted in gradual improvement in her GCS. After clearance of CSF, she was given an EVD challenge. This refers to closing the EVD for 24 h along with monitoring the patient's neurological response and intracranial pressure (ICP). A CT-scan is repeated after 24 h have elapsed. If after 24 h, no deterioration is seen in the patient's neurological response and the CT-scan does not show a further increase in hydrocephalus, the patient is deemed drain independent and the EVD is removed. The patient is deemed drain dependent if there is an increase in ICP after 24 h,

* Corresponding author.

E-mail addresses: saad.akhtar@aku.edu (S. Akhtar), abdulazeem22@hotmail.com (A. Azeem), amyna.jiwani@gmail.com (A. Jiwani), gohar.javed@aku.edu (G. Javed).

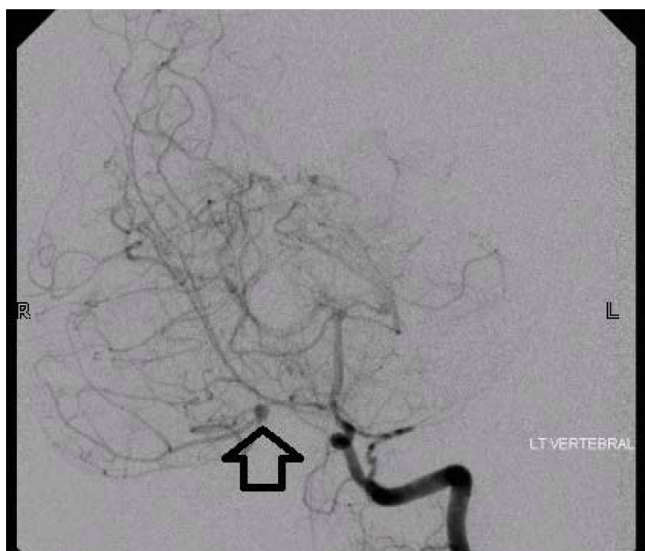


Fig. 1. Catheter based angiography showed a 3 mm aneurysm from the branch of the PICA, located almost in the midline near the vermis (pointed by the arrow).

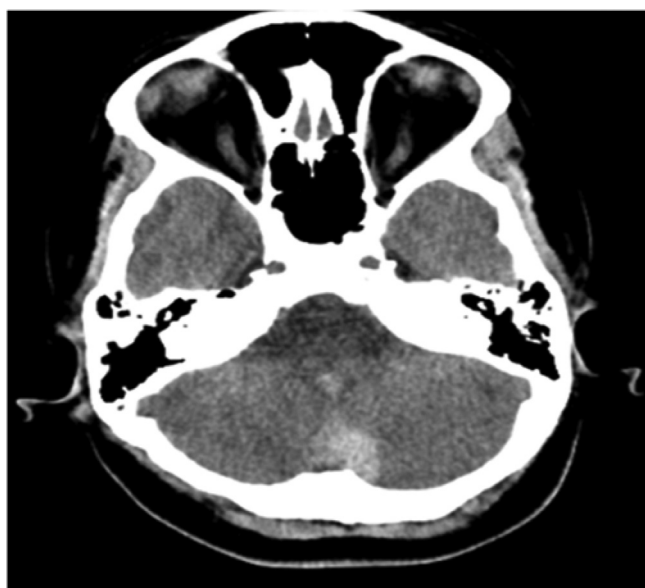

Fig. 2. CT scan (axial view) shows cerebellar bleed predominantly in the region of the cerebellar vermis.

deterioration at opening or closing the EVD, or an increase in hydrocephalus on CT-scan. A shunt is placed when feasible. The patient tolerated the challenge and hence EVD was removed. The patient was discharged on the 14th day of admission with a plan of interval imaging and interventional radiology if required.

However, on the 10th day of her discharge, the patient was readmitted for headache, neck pain and vomiting for the past 6 h. On examination, her GCS was 15/15 (E4 V5 M6). CT-scan showed haemorrhage in the fourth ventricle and hydrocephalus. Her cerebral angiogram was repeated which showed a 3 mm aneurysm in the anterior inferior cerebellar artery (AICA) along with the absence of posterior inferior cerebellar arteries (PICA) bilaterally [Figs. 3–4]. This aneurysm was the source of the bleeding. This was co-related with Fig. 1. Relevant pre-operative work-up showed anaemia with haemoglobin and haematocrit levels of 9.4 g/dl and 29% respectively. Additionally, her serum pH was 7.55 with partial pressures of oxygen and carbon dioxide at 317.50 mmHg and 26.40 mmHg

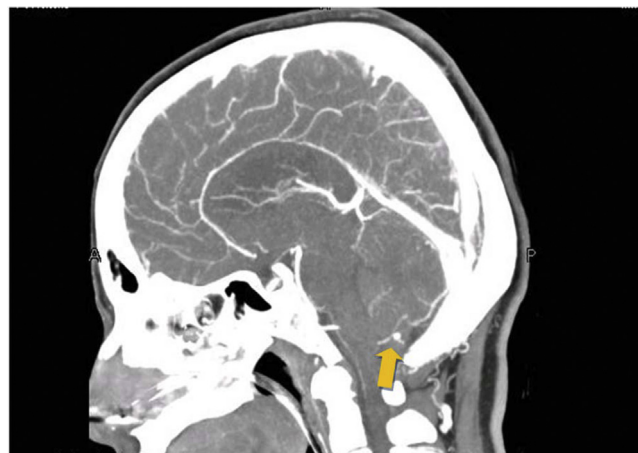

Fig. 3. Sagittal view on CT scan: Presence of suspected aneurysm. Orange arrow points to the aneurysm.

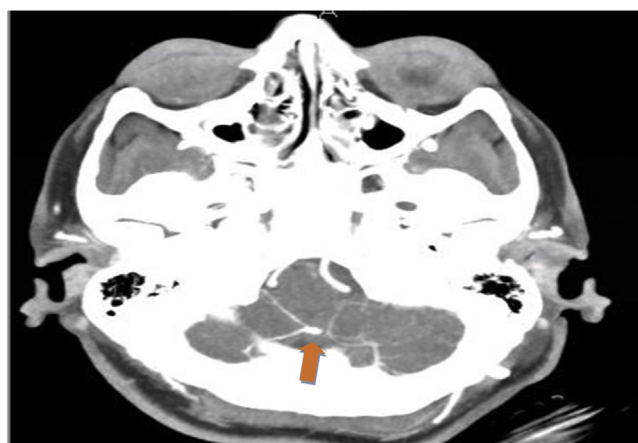


Fig. 4. CT scan (axial) showing the aneurysm. It is located almost in the midline. Orange arrow points to the region of the aneurysm.

respectively. Coagulation and electrolyte studies along with serum creatinine and blood urea nitrogen revealed no abnormalities. She underwent sub-occipital craniotomy and excision of the aneurysm.

Intra-operative findings included a fusiform thrombosed aneurysm at the bifurcation of the AICA on the right side, within the AICA-PICA complex. The aneurysm was excised with cautery, haemostasis was secured and an EVD was placed. This was done to ensure complete resolution of hydrocephalus. Her angiogram was repeated which showed complete excision of the aneurysm [Fig. 5]. The patient did not develop any new neurological deficit. The post-operative course was unremarkable and the patient was discharged once the EVD had been removed.

The patient was followed up one week later. Her GCS was 15/15 and there were no active issues.

3. Discussion

There are considerable variations in the anatomy of the verte-brobasilar system. The most common variation is agenesis of the right PICA followed by agenesis of the left PICA as reported in literature [4]. An inverse relationship between the sizes of the AICA and PICA is thought to exist [5]. Agenesis of the PICA leads to a well-developed AICA so that it can supply the areas that would have been perfused by the absent vessels. This is known as the “AICA-PICA variant” with an overall prevalence rate of 20–24% as reported in literature [5]. This prevalence is derived from reviewing vertebral

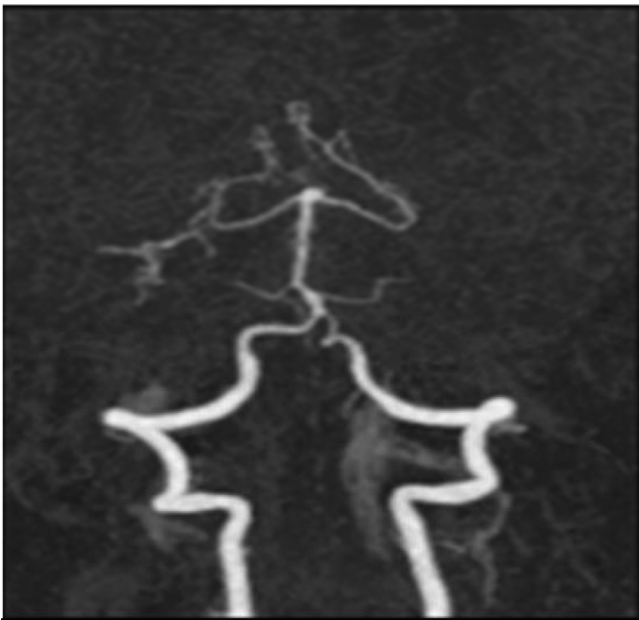


Fig. 5. CT angiogram (post-operative) shows absence of any aneurysm in posterior circulation.

angiograms of 200 patients as seen in the study by Takahashi et al. and 100 normal angiograms as seen in the study by Margolis and Newton [6]. While both studies report a comparable prevalence, extrapolating this prevalence to the general population may not be statistically accurate. Regardless of the prevalence, the rarity of AICA aneurysms, as discussed earlier, could explain the presence of only 5 cases on the surgical removal of such an aneurysm.

As far as aneurysms of the AICA-PICA variant are concerned, the exact cause is not known. The aneurysms may develop due to increased blood flow in the variant or a vascular injury such as a dissection [9]. Saccular and fusiform types of aneurysms of the AICA-PICA variant were seen in our literature review. These terms refer to the morphological features of these aneurysms [10]. As with any other cerebral aneurysm, the complication would include rupture of the aneurysm.

As seen in Table 1, there is a female predominance amongst cases of an aneurysm of the AICA-PICA variant managed surgically. However, the minute number of cases available make it difficult to derive a statistical conclusion so gender cannot be considered a risk factor for the development of these aneurysms [5,9,11,12].

In the report by Suh et al. 5 cases of aneurysms of the AICA-PICA variant were managed non-surgically via Endovascular Treatment (EVT). This study reports the presence of such an aneurysm in a male patient although a female predominance is still seen. The predominant presentation was that of subarachnoid haemorrhage as seen in 3 out of 5 patients. In two patients, the aneurysm was discovered incidentally [13].

Before EVT, surgery was the main treatment modality for intracerebral aneurysms. With the increasing advances in technology, a greater number of aneurysms can be managed via EVT today. However, aneurysms that are large (>10 mm), giant (>25 mm) or fusiform in morphology are associated with higher morbidity, mortality and recurrence rate when managed by EVT [14–16]. EVT also requires the administration of a dual anti-platelet regimen which may not be tolerated by all patients [15]. Moreover, ruptured aneurysms with compressive hematomas are indications for surgery too [14].

Amongst cases managed surgically, the most common presenting features included headaches of sudden onset and vomiting as summarised in Table 1 [5,9,11,12,17]. The only exception is a case

reported by Ooigawa, et al [17]. The authors reported a case with a giant thrombosed aneurysm in the right AICA-PICA variant. The presenting features included progressive right-sided facial sensory disturbance, hemidysesthesia in the left extremities and hearing loss in the right ear for a few years [17]. However, based on the review of literature, it can be concluded that the most common presentation is acute in nature. This is also seen in our case.

Radiological imaging is an important prerequisite in the diagnosis of such aneurysms. On CT- scan, subarachnoid and intraventricular haemorrhages were seen in almost all cases [5,9,11,12]. The only exception being the case reported by Ooigawa et al.

Vertebral angiography and cerebral angiography are also important diagnostic modalities in such cases. The aneurysm was seen in the distal segment of the left AICA-PICA variant on vertebral angiography as reported by Kojima et al [12]. Baskaya et al. reported another case where cerebral angiography revealed a saccular aneurysm in the cortical segment of the AICA-PICA complex, on the left [5]. The two most recent cases of aneurysms in the AICA-PICA variant have been reported by C. V. Gopalakrishnan et al. The first case showed the presence of a saccular aneurysm in the telovelotonsillar region of the AICA-PICA variant on the right [9]. While the second case showed an aneurysm in the tonsilomedullary segment of the AICA-PICA variant on the left [9].

The only notable exception includes the case reported by Ooigawa H, et al. The authors reported the presence of a 3 cm mass lesion at the right cerebello-pontine angle on MRI [17]. This was initially thought to be a vestibular schwannoma [17]. However, digital subtraction angiography showed the presence of a partially thrombosed aneurysm in the distal region of the AICA-PICA variant [17].

As seen in the case description above, the radiological findings in our case were similar to those reported in literature. Cerebellar and intra-ventricular haemorrhages were seen on CT-scan. On angiography, a 3 mm aneurysm in the AICA-PICA variant was seen on the right. Only Baskaya et al. and Gopalakrishnan et al. (in 1 case) have described the aneurysms as saccular aneurysms. This has not been mentioned in other cases as seen in Table 1. The aneurysm seen in our case was a fusiform aneurysm. This is different from other aneurysms reported in literature.

Surgical management of such aneurysms remains a challenge. Bilateral suboccipital craniectomy was performed and the aneurysm was clipped via a midline suboccipital approach in the case reported by Kojima et al [12]. While a midline suboccipital craniotomy was performed and the saccular aneurysm in the cortical region of the AICA-PICA complex was clipped via transcerebellar dissection in the case reported by Baskaya et al [5].

In the series of two cases reported by Gopalakrishnan et al., a midline suboccipital craniectomy was performed in the first case and the saccular aneurysm was clipped via a telovelotonsillar approach (after freeing it from adhesions to the inferior medullary velum) [9]. This was similar to the approach used in the other reported cases. However, in the second case, a lateral suboccipital craniectomy was performed and the aneurysm was successfully clipped [9]. This was different from other cases reported in literature. The authors deemed this was necessary due to the lateral location of the aneurysm [9].

In conclusion, the surgical management in all such cases included clipping. The only exception reported in literature includes the case described by Ooigawa et al. Thrombectomy was performed after endovascular trapping of the aneurysm [17]. The authors chose such a plan of management in order to avoid any new neurological deficit since MRI had also revealed a cerebellar infarction in the distal region supplied by the AICA-PICA variant [17]. The location of aneurysm (on the lateral wall of the pons) was also a contributing factor [17].

Table 1

(Legend: Y = Years, F = Female, CA = cerebral angiography, VA = vertebral angiography, DSA = digital subtraction angiography).

Year	Author	Age	Sex	Presenting features	Findings on radiological imaging	Treatment option	Outcome
1996	Kojima et al. (case in Japanese)	67y	F	Case reported in Japanese. Cannot be fully ascertained.	Case reported in Japanese. Cannot be fully ascertained.	Case reported in Japanese. Cannot be fully ascertained.	Case reported in Japanese. Cannot be fully ascertained.
1999	Ebara et al. (case in Japanese)	62y	F	Sudden onset of: 1. Severe headache 2. Nuchalgia	CT: 1. Subarachnoid haemorrhage in ambient cistern 2. Blood clots in 3 rd , 4 th ventricle VA: 1. Left distal AICA-PICA aneurysm	Clipping via median suboccipital approach	Post-operative course was unremarkable
2006	Baskaya et al.	44y	F	Sudden onset of: 1. severe headache and vomiting	CT: 1. Subarachnoid and intraventricular haemorrhage. CA: 1. saccular aneurysm in right PICA 2. saccular aneurysm in AICA-PICA variant on left	Clipping of both aneurysms after bilateral suboccipital craniotomy	Post-operatively: 1. Presence of fusiform aneurysm in right distal PICA detected. 2. Communicating hydrocephalus and lower cranial nerve paresis 3 years later: 1. Left cerebellar dysmetria and ataxia.
2009	Gopalakrishnan et al.	68y	F	Case 1: Sudden onset of: 1. Headache and vomiting followed by altered sensorium	CT: Intraventricular haemorrhage and hydrocephalus CA: 1. Saccular aneurysm in AICA-PICA variant on the right	Clipping via telovelotonsillar approach	1. Hemodynamic instability and irregular respiration 2. Fulminant meningitis 3. Eventually, vegetative state.
2009	Gopalakrishnan et al.	63y	F	Case 2: Sudden onset of: 1. Severe headache and vomiting	CT: 1. Subarachnoid haemorrhage 2. Haemorrhage in 4th ventricle CA 1. 6 mm aneurysm in AICA-PICA variant on the left	Clipping after lateral suboccipital craniectomy	Post-operative course was unremarkable
2015	Ooigawa H, et al.	42y	M	1. Right facial sensory disturbance, and hemidysesthesia in the left extremities 2. Hearing loss for a few years	MRI: 1. 3 cm mass lesion at CP angle on the right. 2. Ipsilateral cerebellar infarct DSA: 1. Partially thrombosed aneurysm in distal AICA-PICA on the right	Endovascular trapping of aneurysm followed by surgical thrombectomy using lateral suboccipital craniotomy.	Post-operative course and follow up were unremarkable
2015	Our case	35y	F	Headache, neck pain and vomiting for the past 6 hours	CT: 1. Haemorrhage in the fourth ventricle) and hydrocephalus CA: 1. 3 mm aneurysm in the anterior inferior cerebellar artery (AICA) 2. Absence of posterior inferior cerebellar arteries (PICA) bilaterally	Sub-occipital craniotomy and excision of aneurysm	Post-operative course and follow-up were unremarkable.

However, in our case, the aneurysm was excised after suboccipital craniotomy. This was done due to the size of the aneurysm (3 mm). An aneurysm of such a size was considered to pose difficulty in clipping. This plan of management is different from other cases reported in literature.

The post-operative course and follow-up were unremarkable in most cases. The exceptions included the cases reported by Baskaya et al. and Gopalakrishnan as mentioned in Table 1. The first case described by Gopalakrishnan et al. eventually ended in a vegetative state after surgery [9]. The authors felt this was due to medullary ischemia secondary to retrograde perforator spasm. This is based on their observation of perforators to the brainstem from the distal part of the AICA-PICA variant [9]. This is in contrast to Baskaya et al. where the authors believe there is no contribution to supply of the brainstem from the telovelotonsillar and cortical regions of the variant [5]. However, if perforators are seen preoperatively, these perforators need to be preserved as damaging them can lead to major neurological deficit as seen in the case described by Gopalakrishnan et al [9]. No perforators were seen on any angiograms in our patient.

4. Conclusion

In conclusion, despite the relative prevalence of the AICA-PICA variant, aneurysms in the AICA-PICA variant are rare. Careful evaluation is needed to come to an accurate diagnosis. All this contributes towards devising a suitable plan for the management of such aneurysms.

Conflict of interest

The authors would explicitly state that there are no conflicts of interest and have nothing to declare.

Funding

There were no sources of funding

Ethical approval

This is a case report. Hence it does not require a review from the ethics committee.

Author contribution

Dr. Saad Akhtar = writing the paper, Abdul Azeem = writing the paper, review of literature, Dr. Amyna Jiwani = writing the paper, Dr. Gohar Javed = writing the paper, proof reading, corrections and corresponding author.

Consent

Written informed consent was obtained from the patient for publication of this case report and accompanying images. A copy of the written consent is available for review by the Editor-in-Chief of this journal on request.

Guarantor

Dr. Saad Akhtar.

References

- [1] T. Menovsky, J. Andre Grotenhuis, R.H. Bartels, Aneurysm of the anterior inferior cerebellar artery (AICA) associated with high-flow lesion: report of two cases and review of literature, *J. Clin. Neurosci.* 9 (2002) 207–211.
- [2] A. Sarkar, M.J. Link, Distal anterior inferior cerebellar artery aneurysm masquerading as a cerebellopontine angle tumor: case report and review of literature, *Skull Base* 14 (2004) 101–106.
- [3] H. Tokimura, T. Ishigami, H. Yamahata, H. Yonezawa, S. Yokoyama, A. Haruzono, et al., Clinical presentation and treatment of distal anterior inferior cerebellar artery aneurysms, *Neurosurg. Rev.* 35 (2012) 497–503.
- [4] V. Akgun, B. Battal, Y. Bozkurt, O. Oz, S. Hamcan, S. Sari, et al., Normal anatomical features and variations of the vertebrobasilar circulation and its branches: an analysis with 64-detector row CT and 3T MR angiographies, *Sci. World J.* (2013) 2013.
- [5] M.K. Baskaya, E. Coscarella, A. Jea, J.J. Morcos, Aneurysm of the anterior inferior cerebellar artery-posterior inferior cerebellar artery variant: case report with anatomical description in the cadaver, *Neurosurgery* (2006) 2006.
- [6] M.K. Baskaya, E. Coscarella, A. Jea, J.J. Morcos, Aneurysm of the anterior inferior cerebellar artery-posterior inferior cerebellar artery variant: case report with anatomical description in the cadaver, *Neurosurgery* 58 (2006) E388 (discussion E.).
- [9] C.V. Gopalakrishnan, G. Menon, S. Nair, Aneurysm of the anterior inferior cerebellar artery-posterior inferior cerebellar artery variant: two case reports and review of literature, *Br. J. Neurosurg.* 23 (2009) 554–556.
- [10] H.C. Echiverri, F.A. Rubino, S.R. Gupta, M. Gujrati, Fusiform aneurysm of the vertebrobasilar arterial system, *Stroke: J. Cereb. Circ.* 20 (1989) 1741–1747.
- [11] M. Ebara, T. Tanaka, S. Sawauchi, S. Morooka, K. Yuhki, T. Abe, A ruptured aneurysm of the anterior and posterior inferior cerebellar artery: a case report, *No Shinkei Geka* 27 (1999) 1013–1017.
- [12] A. Kojima, T. Nakamura, H. Takayama, S. Harada, Y. Takamiya, A case of de novo aneurysm of the distal posterior inferior cerebellar artery with intraventricular hemorrhage, *No Shinkei Geka* 24 (1996) 469–473.
- [13] S.H. Suh, D.J. Kim, D.I. Kim, B.M. Kim, T.S. Chung, C.K. Hong, et al., Management of anterior inferior cerebellar artery aneurysms: endovascular treatment and clinical outcome, *AJNR Am. J. Neuroradiol.* 32 (2011) 159–164.
- [14] R. Anxionnat, R. Tonnelet, A.L. Derelle, L. Liao, C. Barbier, S. Bracard, Endovascular treatment of ruptured intracranial aneurysms: indications, techniques and results, *Diagn. Intervent. Imaging* 96 (2015) 667–675.
- [15] M.Y. Kalani, W. Ramey, F.C. Albuquerque, C.G. McDougall, P. Nakaji, J.M. Zabramski, et al., Revascularization and aneurysm surgery: techniques, indications, and outcomes in the endovascular era, *Neurosurgery* 74 (2014) 482–497 (discussion 97–8).
- [16] O. Petr, W. Brinjikji, C. Thome, G. Lanzino, Safety and efficacy of microsurgical treatment of previously coiled aneurysms: a systematic review and meta-analysis, *Acta Neurochir. (Wien)* 157 (2015) 1623–1632.
- [17] H. Ooigawa, E. Morikawa, S. Ishihara, T. Ogura, R. Takeda, H. Kurita, Partially thrombosed giant aneurysm arising from a distal anterior inferior cerebellar artery-posterior inferior cerebellar artery variant: a case report, *Interdiscip. Neurosurg.: Adv. Tech. Case Manage.* 2 (2016) 123–125.

Open Access

This article is published Open Access at [sciencedirect.com](https://www.sciencedirect.com). It is distributed under the [IJSCR Supplemental terms and conditions](#), which permits unrestricted non commercial use, distribution, and reproduction in any medium, provided the original authors and source are credited.