



THE AGA KHAN UNIVERSITY

eCommons@AKU

---

Department of Surgery

Department of Surgery

---

June 2016

# Unusual case of non-resolving necrotizing pneumonia: a last resort measure for cure.

Naseem Salahuddin

*Aga Khan University*, [naseem.salahuddin@aku.edu](mailto:naseem.salahuddin@aku.edu)

Naila Baig Ansari

*Aga Khan University*

Saulat H. Fatimi

*Aga Khan University*, [saulat.fatimi@aku.edu](mailto:saulat.fatimi@aku.edu)

Follow this and additional works at: [http://ecommons.aku.edu/pakistan\\_fhs\\_mc\\_surg\\_surg](http://ecommons.aku.edu/pakistan_fhs_mc_surg_surg)

 Part of the [Surgery Commons](#)

---

## Recommended Citation

Salahuddin, N., Ansari, N., Fatimi, S. (2016). Unusual case of non-resolving necrotizing pneumonia: a last resort measure for cure.. *JPMA: Journal of the Pakistan Medical Association*, 66(6), 754-756.

**Available at:** [http://ecommons.aku.edu/pakistan\\_fhs\\_mc\\_surg\\_surg/566](http://ecommons.aku.edu/pakistan_fhs_mc_surg_surg/566)

## Unusual case of non-resolving necrotizing pneumonia: A last resort measure for cure

Naseem Salahuddin,<sup>1</sup> Naila Baig-Ansari,<sup>2</sup> Saulat Hasnain Fatimi<sup>3</sup>

### Abstract

To our knowledge, this is an unusual case of a community-acquired pneumonia (CAP) with sepsis secondary to *Streptococcus pneumoniae* that required lung resection for a non-resolving consolidation. A 74 year old previously healthy woman, presented with acute fever, chills and pleuritic chest pain in Emergency Department (ED). A diagnosis of CAP was established with a Pneumonia Severity Index CURB-65 score of 5/5. In the ER, she was promptly and appropriately managed with antibiotics and aggressive supportive therapy. She remained on ten days of intravenous antibiotics. However, 48 hours post antibiotic course, she returned to ER with fever and signs of sepsis. Despite timely and appropriate management, the consolidated lobe remained the focus of sepsis for over four weeks. The patient recovered after the offending lobe was resected. Histopathology of the lung tissue revealed acute and chronic inflammation. However, no malignancy, bacterial infection or broncho-pleural fistula was found. Eighteen months post-surgery, the patient remains well.

**Keywords:** Necrotizing pneumonia, Nonresolving pneumonia, Community-acquired pneumonia, *Strep pneumoniae*, Lung resection.

### Introduction

Community-acquired pneumonia (CAP) is an important cause of morbidity and mortality, and remains one of the most common reasons for hospitalization among the elderly. Prompt initiation of appropriate antibiotic therapy prior to the availability of culture results potentially benefits prognosis. In patients with severe respiratory distress, sepsis or septic shock, mortality rates range from 23% to 50% depending upon the presence of shock, accuracy of processes of care, and type of underlying disease.<sup>1</sup> *Streptococcus pneumoniae* is the most common

pathogen of acute CAP<sup>2,3</sup> and accounts for most cases of slowly resolving pneumonia. The majority of previously healthy hospitalized patients with severe CAP responded satisfactorily to prompt initiation of appropriate antibiotic therapy; however, it is estimated that 10% of hospitalized CAP patients have slowly resolving or nonresolving disease.<sup>4</sup>

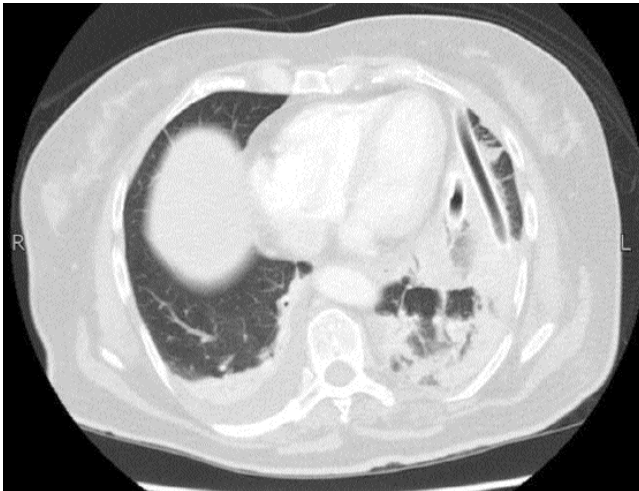
### Case Report

**History:** A 74 year old woman who was previously healthy with no history of hypertension or diabetes, was a non-smoker, and had never received pneumococcal vaccine presented with acute fever over 48 hours, chills and left pleuritic chest pain. In the Emergency Department at the Aga Khan University Hospital, Karachi in December 2013, she was ill appearing and slow in responding to questions. The temperature was 39°C, respiratory rate was 36 per minute, blood pressure 110/60 mm Hg and oxygen saturation was 95% on room air. The left posterior chest was dull to percussion, and auscultation of the chest revealed bronchial breath sounds in the left base. Her chest radiograph showed a consolidated left lower lobe. As she had no history of significant infections in the past and no risk for HIV, it was not deemed necessary to evaluate her for immune deficiency. Relevant lab tests were: haemoglobin 13.2 gm/dl, white blood cell count 17,100/mm<sup>3</sup> with 92% polymorphonuclear leukocytes, CRP 16.8 mg/l. and blood urea 45 mg%. A diagnosis of CAP with sepsis was established, and Pneumonia Severity Index CURB-65 score was 5/5. Within two hours of arrival she was given ceftriaxone 2 grams intravenously and 500 mg clarithromycin orally. After prompt resuscitation with fluid, oxygen and vasopressors she improved clinically over the next 48 hours. White blood cell count and CRP also improved subsequently.

Blood cultures grew *Strep pneumoniae*, with MIC to ceftriaxone 0.06 µg/ml. Serotyping for *S pneumoniae* could not be performed. She remained in the hospital for 7 days receiving intravenous antibiotics, which were continued for an additional 3 days as outpatient. While at home, she remained afebrile but complained of pleuritic chest pain. Before discharge ultrasound was not

.....  
<sup>1</sup>Department of Medicine, The Aga Khan University Hospital, Department of Infectious Diseases, The Indus Hospital, Karachi, <sup>2</sup>Department of Epidemiology, The Indus Hospital Research Center, Karachi, <sup>3</sup>Section of Cardiothoracic Surgery, Department of Surgery, The Aga Khan University Hospital, Karachi, Pakistan.

**Correspondence:** Naseem Salahuddin. Email: naseems101@gmail.com



**Figure:** Computerized tomography without contrast shows moderate pleural effusion with underlying collapse/consolidation with air bronchogram. Parapneumonic nodules are seen in the left lower lobe.

considered to be necessary. A day after stopping the antibiotics, she returned to the Emergency Department with a temperature of 39.4°C along with signs of sepsis. High resolution CT scan of the chest (Figure) revealed small effusion in the left chest with collapse and air bronchogram, and pools of abscesses. Broad spectrum antibiotics were started empirically, but her clinical condition continued to worsen. Blood cultures remained negative.

Removal of the abscess pool under ultrasound guidance was attempted, but failed to resolve the infection. After two weeks of continuing pain and fever, a decision was made to do a left sided decortication through Video Assisted Thoracoscopy (VATS). Thick fibrinous empyema was found which was evacuated. The left lung expanded well except for the left lower lobe basilar segments, which had consolidation. Two chest tubes were inserted and placed on under-water suction. Despite the procedure the patient's clinical condition and fever patterns remained unchanged.

Her illness was now into the fourth week and her clinical condition continued to worsen with high fever with chills and intense chest pain, along with rising white blood cell count and CRP. Urine and blood cultures revealed no growth; brain MRI and echocardiogram were done to rule out possibilities of other occult infection and were normal. Chest CT scans showed unchanged consolidation and minimal effusion. A re-look thoracotomy was performed. There was minimal fluid in the pleural cavity but the entire left lower lobe was studded with micro-

abscesses and pus. The left upper lobe was completely normal. Intra-operative consultation was done between the treating physicians and thoracic surgeon, and an unorthodox decision was taken to remove the offending left lower lobe of the lung. Complete left lower lobectomy was performed. There were no intra-operative complications and the patient was transferred to the recovery room in stable condition. Grossly, the lung tissue was necrotic and had multiple small abscesses involving the entire parenchyma. Microscopic examination of the removed lung showed areas of fibrinous and organizing pneumonia and abscesses palisaded by epithelioid histiocytes and giant cells. There were no granulomas or malignancy and no bronchopleural fistula. Culture for bacteria, mycobacterium tuberculosis and fungus were negative.

Post-operatively, her course of recovery was unremarkable and she was discharged one week later. Eighteen months later, the patient remains well and has resumed her normal activities.

## Discussion

CAP is one of the most common reasons for hospitalization among the elderly, and represents a major cause of morbidity and mortality. It is most commonly caused by *Streptococcus pneumoniae* and may result in empyema.<sup>2</sup> Positive blood cultures and drug sensitivity are helpful in narrowing antibiotic selection. Administration of antimicrobial agents within two hours of arrival determines patient survival. In an average case, 3-7 days of treatment is acceptable, but may be extended by a few days in a sick patient.<sup>5</sup> Our patient received a susceptible antibiotic within one hour in appropriate dosage for ten days.

Chest X-ray improvement of lung consolidation generally takes several weeks after resolution of clinical symptoms. However, non-resolution with continuing clinical symptoms warrants investigation. Our patient was found to have empyema, which is uncommon following *S. pneumoniae* pneumonia, and is also unrelated to positive blood culture or duration of antibiotic therapy.

In a large series of patients with necrotizing pneumonia, type 3 pneumococcus strains was the single most common serotype implicated in necrosis in children and adults.<sup>6</sup> Since serotyping is not routinely done in our hospital, we have no data on the patient's serotype.

VATS is a safe and effective method for diagnosis and treatment of post pneumonic empyema.<sup>7</sup> Our patient did not benefit from decortication and chest drainage, and a bold decision was ultimately taken to surgically excise the

affected lobe, following which her clinical condition improved. In most case series of non-resolving pneumonias the underlying diagnosis is malignancy, tuberculosis, fungal infections or Bronchiolitis obliterans and organizing pneumonia(BOOP).<sup>8,9</sup> No underlying pathology was seen in our patient. Histopathology showed acute inflammation with patchy areas of organizing pneumonia.

### Conclusion

This is an unusual case of *S. pneumoniae* CAP complicated by empyema that did not respond to broad spectrum antibiotics, drainage and decortication. Sepsis ultimately resolved with removal of the affected lobe. There was no underlying malignancy or chronic lung parenchymal infection. Despite her age and severity of illness, this patient survived probably because of her previous good health, no co-morbid and being a non smoker.

### Acknowledgements

Zara Ansari for editing the final copy.

**Disclosure:** The article or part of the article has not been published in any other journal.

**Conflict of Interest:** None.

**Financial Support:** None.

### References

1. Rodriguez A, Lisboa T, Blot S, Martin-Loeches I, Solé-Violan J, De Mendoza D, et al. Mortality in ICU patients with bacterial community-acquired pneumonia: when antibiotics are not enough. *Inten Care Med.* 2009;35:430-8.
2. Cardinal-Fernández P, García Gabarrot G, Echeverría P, Zum G, Hurtado J, Rieppi G. Clinical and microbiological aspects of acute community-acquired pneumonia due to *Streptococcus pneumoniae*. *Rev Clin Esp (Barc).* 2013; 213:88-96.
3. Sialer S, Liapikou A, Torres A. What is the best approach to the nonresponding patient with community-acquired pneumonia? *Infect Dis Clin North Am.* 2013; 27:189-203.
4. Weyers CM, Leeper KV. Nonresolving pneumonia. *Clin Chest Med.* 2005; 26:143-58.
5. Jenkins TC, Sakai J, Knepper BC, Swartwood CJ, Haukoos JS, Long JA, et al. Risk factors for drug-resistant *Streptococcus pneumoniae* and antibiotic prescribing practices in outpatient community-acquired pneumonia. *Acad Emerg Med.* 2012; 19:703-6.
6. Pande A, Nasir S, Rueda AM, Matejowsky R, Ramos J, Doshi S, et al. The incidence of necrotizing changes in adults with pneumococcal pneumonia. *Clin Infect Dis.* 2012; 54:10-6.
7. Tiitto L, Heiskanen U, Bloigu R, Pääkkö P, Kinnula V, Kaarteenaho-Wiik R Thoracoscopic lung biopsy is a safe procedure in diagnosing usual interstitial pneumonia. *Chest.* 2005; 128:2375-80.
8. Jayaprakash B, Varkey V, Anithakumari K. Etiology and clinical outcome of non-resolving pneumonia in a tertiary care centre. *J Assoc Physicians India.* 2012;60:98-101.
9. Pacheco A, Fogué L. [Bronchiolitis obliterans and organized pneumonia: 2 clinical-histological entities of the pulmonary acinus]. *Arch Bronconeumol.* 1995; 31:429-30.