



THE AGA KHAN UNIVERSITY

eCommons@AKU

Department of Surgery

Department of Surgery

October 2016

Cervical mediastinoscopy in the diagnosis of lymphadenopathy in South Asia.

Sulaiman B Hasan

Aga Khan University

Fazal Wahab Khan

Aga Khan University

Shiraz Hashmi

Aga Khan University, shiraz.hashmi@aku.edu

Ahsan Ehtesham

Aga Khan University

Rizwana Ahmed Magsi

Aga Khan University

See next page for additional authors

Follow this and additional works at: http://ecommons.aku.edu/pakistan_fhs_mc_surg_surg



Part of the [Surgery Commons](#)

Recommended Citation

Hasan, S., Khan, F. W., Hashmi, S., Ehtesham, A., Magsi, R., Shahabuddin, S. (2016). Cervical mediastinoscopy in the diagnosis of lymphadenopathy in South Asia.. *JPMA: Journal of Pakistan Medical Association*, 66(10), S16-S18.

Available at: http://ecommons.aku.edu/pakistan_fhs_mc_surg_surg/549

Authors

Sulaiman B Hasan, Fazal Wahab Khan, Shiraz Hashmi, Ahsan Ehtesham, Rizwana Ahmed Magsi, and Syed Shahabuddin

SHORT REPORT

Cervical mediastinoscopy in the diagnosis of lymphadenopathy in South Asia

Sulaiman Bashir Hasan,¹ Fazal Wahab Khan,² Shiraz Hashmi,³ Ahsan Ehtesham,⁴ Rizwana Ahmed Magsi,⁵ Syed Shahabuddin⁶

Abstract

We planned to determine the clinical utility and safety of mediastinoscopy in the pathologic diagnosis of mediastinal lymphadenopathy and to determine disease patterns in a tertiary care setting in Karachi. The retrospective review comprised record of patients who underwent mediastinoscopy over 25 years between July, 1990 and August, 2015. Of the 122 patients, records were complete for 88(72%). Mean age was 42.5±12.9 years and 55(62.5%) were male. Overall, 60(68.2%) patients had benign inflammatory diseases; 25 (28.4%) had lymphoma or lung cancer which was accurately staged; 26(29.5%) had tuberculosis; 13(14.8%) sarcoidosis; and 11 (12.5%) had concomitant tuberculosis and sarcoidosis. No mortality or significant morbidity was recorded. Mediastinoscopy was useful in staging bronchogenic carcinoma and influenced the management in this series. It was found to be accurate in the diagnosis of other malignant as well as benign mediastinal pathologies, all of which were treatable.

Keywords: Cervical mediastinoscopy, Lymphadenopathy, Inflammatory diseases, Malignant diseases.

Introduction

Cervical mediastinoscopy is a minimally invasive surgical procedure for the biopsy of mediastinal lymph nodes for diagnosis¹ and for staging of known lung cancer.² It involves insertion of a mediastinoscope into the mediastinum through a cervical incision under anaesthesia. Biopsies of up to seven mediastinal lymph node stations can be obtained on both sides of the midline: 2, 4, 7 and 10 (Figure).

Accurate staging determines management of lung cancer³ and predicts outcomes. Non-invasive tests for identifying tumour metastases include chest X-ray, computed tomography (CT) scanning and positron emission tomography (PET) scanning. The latter has reduced the need for mediastinoscopy in lung cancer.¹

.....
^{1-3,6}Section of Cardiothoracic Surgery, Department of Surgery, Aga Khan University Hospital, ^{4,5}Medical Student, DUHS, Karachi.

Correspondence: Sulaiman Bashir Hasan. Email: sulaiman.hasan@aku.edu

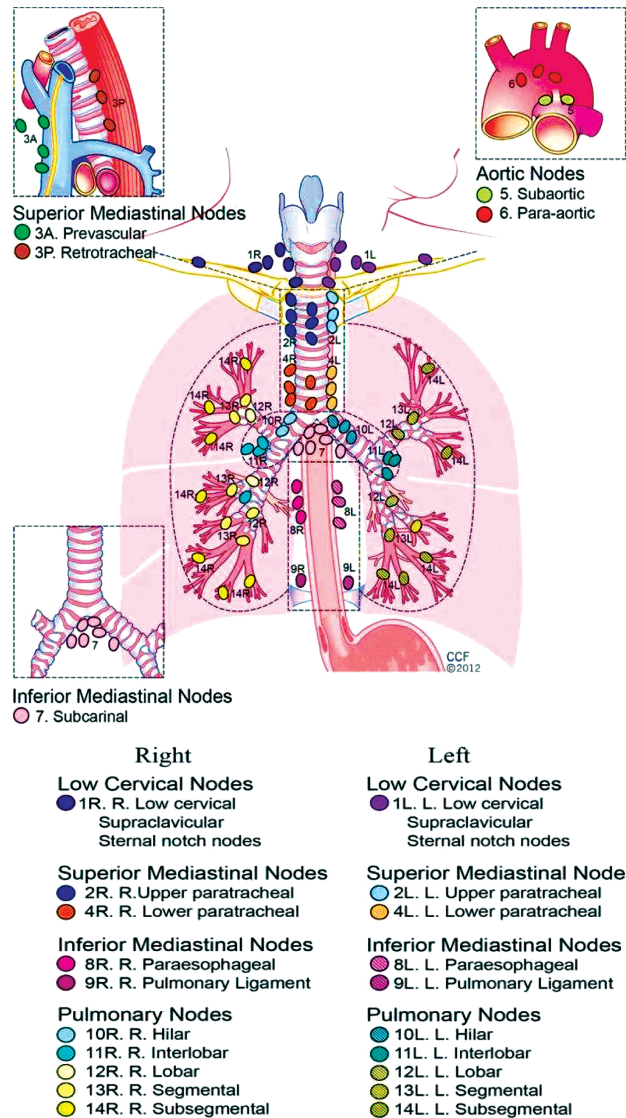


Figure: The International Association for the Study of Lung Cancer (IASLC) lymph node map.

Patients and Methods

The retrospective study was conducted at Aga Khan University Hospital (AKUH), Karachi, and comprised records of patients who underwent mediastinoscopy between July, 1990 and August, 2015. Ethical approval was obtained from the institutional review committee.

Analysis was performed on SPSS 20. Frequencies and percentages for categorical variables were calculated. Mean and standard deviation for normally distributed continuous variables and the median and interquartile range (IQR) for skewed variables were computed. Chi square was used to observe group differences. $P < 0.05$ was statistically significant.

Results

Of the 122 patients who had undergone mediastinoscopy, 88(72%) cases had complete records available and comprised the study sample. Mean age was 42.5 ± 12.9 years and 55(62.5%) were male. Median length of stay was 1 day (IQR: 1-16). Symptoms included fever, cough, dyspnoea, chest pain and hoarseness. In 21 (23.8%) patients there was no symptom. Moreover, 60(69%) biopsies were taken from nodal station 2,

49(55.7%) from station 4, 37(42.0%) from station 7, and 3(3.4%) from station 10. Overall, 60(68.2%) patients had benign inflammatory diseases; 25 (28.4%) had lymphoma or lung cancer which was accurately staged; 26(29.5%) had tuberculosis (TB); 13(14.8%) sarcoidosis; and 11 (12.5%) had concomitant TB and sarcoidosis. On frozen section, 3(3.4%) cases were read as benign but were found to be malignant on permanent sections. Among the 25(28%) malignant cases, 21(84%) had bronchogenic carcinoma (Table).

There was no mortality, serious complications or transfusion.

Conclusion

Mediastinoscopy allows accurate information from biopsies of lymph nodes. In our series, the majority (68.2%) showed non-malignant granulomatous diseases, predominantly TB 29.5%, sarcoidosis 14.8%, and concurrent sarcoidosis and TB 12.5%. In the West, 83% are diagnosed with malignancy, of which 81% have lung cancer.² TB is now uncommon in the West. Pakistan ranks 6th in the estimated global TB burden list, with an incidence of 181/100000, and prevalence 359/100000.⁴

Sarcoidosis is a diagnostic challenge in countries where TB is endemic.⁵ The estimated prevalence of sarcoidosis in this series was 27%, which seems higher than the West (12%).² A series from India reports 18%.¹ In our study, the prevalence of bronchogenic carcinoma was 24% and lymphoma 4.5%. Eight (33.3%) of these had N0 and N1 disease and underwent resection of the primary tumours. Thirteen (61.9%) were diagnosed with N2 or N3 disease and were spared a resection. It is probably best to do mediastinoscopy separately in an outpatient setting to allow for reports of the more accurate permanent sections.

Compared to the West, a very low proportion of procedures were performed for staging of bronchogenic carcinoma. The sensitivity and specificity of PET/CT for lung cancer staging is lower than mediastinoscopy.⁶ PET-negative nodes do have 10-15% incidence of containing metastatic disease and biopsy should be considered when the primary tumour is locally advanced or an extended resection seems likely to be required for cure. In Pakistan, the reliability of PET/CT may be lower due to TB being endemic, likely increasing false positive rates. Positive PET/CT may require histological confirmation.⁷ Moreover, on CT, enlarged nodes may be inflammatory whereas normal-sized lymph nodes may contain malignancy.⁸ Two patients had chemotherapy for lymphoma and had PET-positive mediastinal lymph

Table: Demographic and clinical characteristics of patients.

Variables	n=88
Age in Years	
-Mean (\pm SD)	42.5 (\pm 12.9)
-Median (Min-Max)	44.5 (13-67)
Gender	
-Male	55 (62.5)
-Female	33 (37.5)
Hospital Stay Days	
-Mean (\pm SD)	2.7 (\pm 3.1)
-Median (Min-Max)	1 (1-16)
Symptoms*	
-Fever	30 (34.1)
-Dry to productive cough	22 (25.0)
-Dyspnea	16 (18.2)
-Chest pain	9 (10.2)
-Hoarseness of voice	5 (5.7)
-No symptoms	21 (23.8)
Clinical Findings	
Mediastinal lymphadenopathy or mass	58 (65.9)
Known case of carcinoma/lymphoma	23 (26.1)
Suspected Sarcoidosis	3 (3.4)
Suspected TB	3 (3.4)
Suspected cases of TB and Sarcoidosis	1 (1.1)
Histopathological Diagnosis	
Bronchogenic Carcinoma	21 (23.8)
Non-Hodgkin's Lymphoma	2 (2.3)
Hodgkin's lymphoma	2 (2.3)
Tuberculosis (TB)	26 (29.5)
Sarcoidosis	13 (14.8)
Concurrent TB and Sarcoidosis	11 (12.5)
Benign reactive changes	7 (8.0)
Anthraxis or others	3 (3.4)
Unspecified	3 (3.4)

*More than one symptoms may be present in same patient.
SD: Standard Deviation.

nodes on follow-up. Biopsies revealed granulomatous inflammation compatible with TB for which they were treated. An assumption of recurrent lymphoma would have led to further chemotherapy, with potentially disastrous consequences.

Endobronchial ultrasound-transbronchial needle aspiration (EBUS-TBNA) biopsy has reduced the need for mediastinoscopy in lung cancer. These needle biopsies are less effective in cases of lymphoma and granulomas as they only provide cytology. The accuracy of mediastinal lymph node biopsies by EBUS-TBNA for TB is 50%, sarcoidosis 60%, but for lung cancer, it is 93%.⁹

Mediastinoscopy has advantage over video-assisted thoracoscopic surgery (VATs) in the ability to biopsy both sides, avoidance of double lumen endotracheal tubes, chest tubes and hospitalisation. Complication rates are minimal. Bleeding from vascular injuries like innominate and pulmonary arteries and azygos vein, recurrent laryngeal nerve injury, pneumothorax, tracheal or oesophageal injury, pericardial puncture and wound infection have rarely been reported.¹⁰

Mediastinoscopy is a safe procedure with minimal morbidity and hospital stay. It is accurate in the staging bronchogenic carcinoma as well as in the diagnosis of other benign and malignant mediastinal pathologies. For lung cancer staging, mediastinoscopy can often be replaced by PET scanning and EBUS-TBNA. It still has distinct advantage over these modalities in inflammatory disease and lymphoma.

Acknowledgements

We are grateful to the staff of institutional Health Information Management System (HIMS) and research for facilitating the data retrieval process.

References

1. Chauhan A, Kapoor S, Ganguly M, Nath P. Cervical mediastinoscopy: re-evaluation of an old technique in era of new imaging technology. *Indian J Chest Dis Allied Sci* 2012; 54: 169-73.
2. Hammoud ZT, Anderson RC, Meyers BF, Guthrie TJ, Roper CL, Cooper JD, et al., The current role of mediastinoscopy in the evaluation of thoracic disease. *J Thorac Cardiovasc Surg* 1999; 118: 894-9.
3. Mountain CF. Staging classification of lung cancer: a critical evaluation. *Clin Chest Med* 2002; 23: 103-21.
4. Hasan Z, Tanveer M, Kanji A, Hasan Q, Ghebremichael S, Hasan R. Spoligotyping of *Mycobacterium tuberculosis* isolates from Pakistan reveals predominance of Central Asian Strain 1 and Beijing isolates. *J Clin Microbiol* 2006. 44:1763-8.
5. Hameed H, Mahmood S, Javaid M. Five years experience of Sarcoidosis at a tertiary care centre in Pakistan. *J Pak Med Assoc* 2010; 60: 293-6.
6. Gelberg J, Grondin S, Tremblay A. Mediastinal staging for lung cancer. *Can Respir J* 2014; 21: 159-61.
7. Liam CK, Andarini S, Lee P, Ho JC, Chau NQ, Tscheikuna J. Lung cancer staging now and in the future. *Respirology* 2015; 20: 526-34.
8. Goldstraw P, Kurzer M, Edwards D. Preoperative staging of lung cancer: accuracy of computed tomography versus mediastinoscopy. *Thorax* 1983; 38: 10-5.
9. Choi YR, An JY, Kim MK, Han HS, Lee KH, Kim SW, et al., The diagnostic efficacy and safety of endobronchial ultrasound-guided transbronchial needle aspiration as an initial diagnostic tool. *Korean J Intern Med* 2013; 28: 660-7.
10. Lemaire A, Nikolic I, Petersen T, Haney JC, Toloza EM, Harpole DH Jr, et al., Nine-year single center experience with cervical mediastinoscopy: complications and false negative rate. *Ann Thorac Surg* 2006; 82: 1185-90.