



THE AGA KHAN UNIVERSITY

eCommons@AKU

Department of Surgery

Department of Surgery

December 2016

Retrograde bullet migration from inferior vena cava into right common iliac vein following gunshot: a case report

Ibrahim Zahid

Dow University of Health Sciences

Hamza Abdur Rahim Khan

Aga Khan University

Omar Irfan

Aga Khan University

Benish Fatima,

Aga Khan University

Maha Tahir

Aga Khan University

See next page for additional authors

Follow this and additional works at: http://ecommons.aku.edu/pakistan_fhs_mc_surg_surg



Part of the [Cardiology Commons](#), and the [Surgery Commons](#)

Recommended Citation

Zahid, I., Khan, H., Irfan, O., Fatima, B., Tahir, M., Tariq, M., Khan, F. W., Fatimi, S. (2016). Retrograde bullet migration from inferior vena cava into right common iliac vein following gunshot: a case report. *JPMA: Journal of the Pakistan Medical Association*, 66(12), 1673-1675.

Available at: http://ecommons.aku.edu/pakistan_fhs_mc_surg_surg/526

Authors

Ibrahim Zahid; Hamza Abdur Rahim Khan; Omar Irfan; Benish Fatima,; Maha Tahir; Muhammad Tariq; Fazal Wahab Khan; and Saulat H. Fatimi

Retrograde bullet migration from inferior vena cava into right common iliac vein following gunshot: A case report

Ibrahim Zahid,¹ Hamza Abdur Rahim Khan,² Omar Irfan,³ Benish Fatima,⁴ Maha Tahir,⁵ Muhammad Tariq,⁶ Fazal Wahab Khan,⁷ Saulat Fatimi⁸

Abstract

Bullet embolization cases are rare and even rarer are its retrograde migration in the veins. We report the case of a 14 year old male with a gunshot wound to the left side of his chest. CT scan revealed bilateral haemothorax and foreign body in the right common iliac vein. The patient was immediately taken to the operating theatre and median sternotomy performed. Bullet entry tear was found in the inferior vena cava however, the bullet was found lodged in the right common iliac vein and slipped down against the flow of blood. The bullet was left in situ and after the necessary repair the chest was closed and the patient shifted to the CICU and discharged after 4 days in stable condition. Patient was followed after 1 week and reassured and advised for one year follow-up.

Keywords: Bullet injury, venous embolism, retrograde migration.

Introduction

A penetrating bullet generally follows a straight course. It can either exit the body or get stuck inside a tissue. Nonetheless, it can enter the vascular system, where it may wander around, resulting in bullet embolism into a vessel. Its occurrence rate is approximately 0.3% in penetrating trauma.¹ Venous bullet embolisms however, are incredibly rare.

Anterograde movement is a frequent finding however, this report is concerned about retrograde migration of a bullet from thorax to the abdomen into the right common iliac vein. A small projectile, caught in a large vein like the Inferior Vena Cava (IVC) might travel intra-luminally, until it is caught into the decreasing diameter of peripheral vasculature. Despite that, the findings have been gaining popularity however, no more than 200 cases of bullet

¹Dow University of Health Sciences, ^{2,3}Medical College, Aga Khan University, ⁴Medical College, Liaquat National Hospital, ⁵Medical College, Dow International, ⁶⁻⁸Department of Cardiothoracic Surgery, Aga Khan Hospital, Karachi, Pakistan.

Correspondence: Muhammad Tariq. Email: m.tariq@aku.edu

embolism have been reported globally.²

Through this report, we aim to help the reader to recognize the potential complications of bullet embolization and be aware of the diagnosis and approaches in such condition, particularly involving the right common iliac vein.

Case Report

A 14 years old male was referred to the hospital with a gunshot wound on the left side of his chest. He was reported to have been walking on his terrace when suddenly a stray bullet struck him. He was taken to a nearby trauma center where he underwent resuscitation, followed by the primary and secondary survey. The entry wound of the bullet was on the left chest at the mid axillary line in the 6th intercostal space without any exit wound. Left sided tube thoracotomy was done and the patient was managed conventionally and discharged home in stable condition without proper workup done.

Patient was presented to the ER with complains of dyspnoea, nausea, vomiting, dizziness and chest pain. His heart rate was 133/min, blood pressure was 80/50 mmHg, respiratory rate was 30/min and O₂ saturation was 99% (on face mask 4 liters) and a GCS of 15/15. Chest X-ray showed widening of the mediastinum and bilateral haemothorax while ultrasound Focused Assessment with

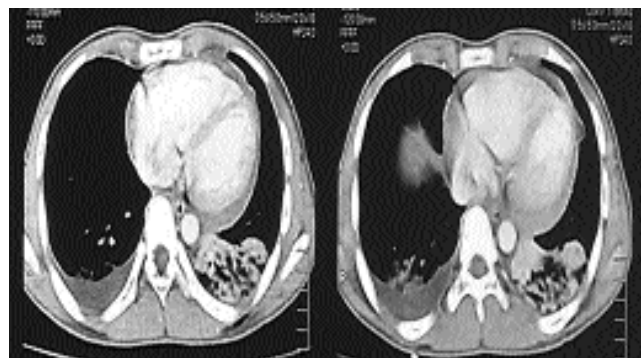


Figure-1: Bilateral haemothorax along with left lung contusion seen along with pericardial effusion.

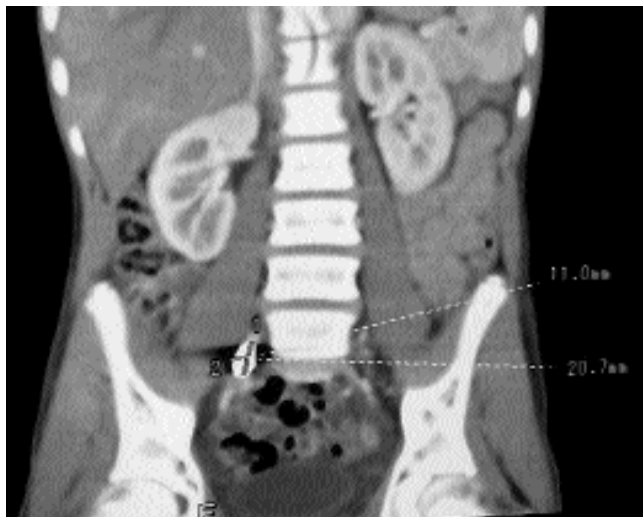

Figure-2: Bullet embolus seen lodged in the territory of the right common iliac vein in paravertebral region at L5-S1 level.

Sonography in Trauma (FAST) was negative.

CT scan of chest showed, pericardial effusion and bilateral haemothorax with left lung lower lobe contusion (Figure-1). A foreign body was seen in the territory of the right common iliac vein (Figure-2). Cardiothoracic surgeon was consulted. The patient was taken to the operating room on 31/3/2013, where a median sternotomy followed by pericardiectomy was done. Around 500cc of clotted blood was aspirated behind the IVC; however no active bleeding was found. Bullet track was retraced, which showed no obvious injury to the myocardium. The heart, diaphragm and great vessels were thoroughly inspected for possible injuries.

About 0.8cm bullet entry tear was found on the posterior surface of the inferior vena cava just above the diaphragm, without active bleeding. IVC tear was sewn with a pledgeted 4/0 prolene suture. It was ascertained again on CT scan that the bullet had migrated through the IVC into the right common iliac vein. The bullet was left in situ. After haemostasis, two 32F chest drains were placed in the mediastinum. Chest was closed and patient shifted to the CICU for critical monitoring. He was extubated 3 hours after the surgery. He remained vitally stable overnight. Next morning, he was shifted to step-down. Chest drains were removed on 2nd post-operative day and the patient was mobilized and sent for rehabilitation. He was started on Warfarin 2mg and Ascard 75mg once a day keeping in view the bullet in the right common iliac vein. He was discharged on 4th post-operative day and remained stable at home. The parents' consent was taken prior to surgery and the case to be

available for any future research study as part of our institutions routine protocol. At follow-up he was reassured for right common iliac vein injury and advised to continue his anti-coagulant therapy. He reported no symptoms at yearly follow-up.

Discussion

Gunshot wounds are a part of the exciting rushing scenario of the ER. The mortality rate of patients with penetrating wounds undergoing thoracotomy is very high 69.6%.³

Arterial bullet embolization can result from penetrating wounds originating from the left ventricle, pulmonary vein, thoracic aorta, abdominal aorta, and peripheral arteries that occur in most of the cases, while 20% of the cases involve venous embolization.⁴ The latter can be a result of the wounds from vena cava, right ventricle, neck veins and peripheral veins. About 80% of arterial bullet embolization cases were symptomatic due to ischaemia;⁴ while more than 70% of the cases presenting with venous bullet embolization are asymptomatic.⁶ Since it can have severe complications such as cardiac valvular destruction, endocarditis, sepsis, venous thrombosis, thrombophlebitis, dysrhythmia, and severe hypoxia, its extraction is preferable.⁷

Retrograde embolization occurs in 15% of the patients which is mainly due to the effect of gravity. Only 14 cases from the literature are associated with retrograde venous embolism, showing how rare of an incident it is.⁵ In this case, the path of retrograde migration of bullet started from the inferior vena cava down to the right common iliac vein and entered through the posterior wall of the IVC. The mediastinum was widened due to haemothorax, which was drained by chest tubes. When removing the emboli, risks of vascular perforation, embolization, ischaemia, and infection must be taken into account. Evidence of migration toward the heart, the development of endocarditis, septic pulmonary or cerebral emboli and lead poisoning and oedema indicate occlusion of a major vessel.⁸ The migration of the bullet embolus could result in a significant risk of morbidity such as venous thromboembolism, infection, aneurysm, perforation and fistula formation.

Bullet emboli treated surgically with open procedures have been associated with significant morbidity, especially when located in such difficult anatomic regions like iliac vessels. Fever, pericarditis, effusions, arrhythmia, thrombi, anxiety, objects >5 mm in diameter, or an irregular shape, are indications for the removal.¹ In such cases of surgical interference, preoperative and intra-operative localization of the bullet by fluoroscopy is

essential to recognize the precise location of bullet migration between preoperative imaging and the time of surgery.⁵ Endovascular approach on the other hand is comparatively easier, with lesser difficulty and minimized associated damage to surrounding structures but such repair is possible only if the equipment is available and the expertise is present-not accessible in our case.

Endovascular technique, along with the surgical procedures, is now used to treat more cases of venous bullet embolism. Overall complication rate in venous bullet emboli reported by Shannon et al. was 25%. Mandatory extraction of early detected (<6 weeks) venous bullet emboli was proposed by the author, however in asymptomatic patients with later discovery, selective observation is said to be sufficient.⁹ From 1987 to 2010, 45 cases of venous bullet embolism reported that 14 (31%) were managed successfully without extraction while intervention was used in 26 cases (58%).⁶ These authors were in favour of extraction of all intra-cardiac missiles. Nevertheless, leaving the bullet in a vessel has its cons and longterm complications. These include the risk of vascular perforation, ischaemia, cardiac valvular destruction, endocarditis, sepsis, venous thrombosis, thrombophlebitis, dysrhythmia, severe hypoxia, lead poisoning, impingement on local structures, infection, having psychological morbidity of leaving a foreign body inside and even transformation to a paradoxical emboli.¹ Interpreting the timing of discovery, presence of symptoms, and anatomical location of the embolus, a risk-benefit estimate can guide further management decisions. Conversely, it is still debatable whether or not a foreign body that embolizes in venous vessels should be removed. Apart from case management of the bullet injuries, ethical and professional aspects should be taken into considerations that are often disregarded in our health care delivery system. As we observed in this case, the patient was not evaluated and explored appropriately before discharge. This is either due to lack of standard protocols for integrated care and referral guidelines that need to be implemented with full force. This approach will enhance appropriate handover and improved care.

Conclusion

Through this report, we aimed to help the readers to choose selective approach to avoid serious complications of bullet embolization and whether to opt for its removal or staying in its present position considering the hazards of its attempted to removal, involving the right common iliac vein in particular.

Acknowledgment

We are grateful to Dr. Shiraz Hashmi, Instructor Research in the production of this manuscript.

Disclosure: None.

Conflict of Interest: None.

Funding Source: None.

References

- Schroeder ME, Pryor HI, Chun AK, Rahbar R, Arora S, Vaziri K. Retrograde migration and endovascular retrieval of a venous bullet embolus. *J Vasc Surg.* 2011; 53:1113-5.
- Duke E, Peterson AA, Eryl WK. Migrating bullet: A case of a bullet embolism to the pulmonary artery with secondary pulmonary infarction after gunshot wound to the left globe. *J Emerg Trauma Shock.* 2014; 7:38-40.
- Mandal A, Oparah S. Unusually low mortality of penetrating wounds of the chest. Twelve years' experience. *J Thorac Cardiovasc Surg.* 1989; 97:119-25.
- Michelassi F, Pietrabissa A, Ferrari M, Mosca F, Vargish T, Moosa HH. Bullet emboli to the systemic and venous circulation. *Surgery.* 1990;107:239-45.
- Bertoldo U, Enrichens F, Comba A, Ghiselli G, Vaccarisi S, Ferraris M. Retrograde venous bullet embolism: a rare occurrence-case report and literature review. *J Trauma.* 2004; 57:187-92.
- Miller KR, Bennis MV, Sciarretta JD, Harbrecht BG, Ross CB, Franklin GA, et al. The evolving management of venous bullet emboli: a case series and literature review. *Injury.* 2011; 42:441-6.
- Nolan T, Phan H, Hardy AH, Khanna P, Dong P. Bullet embolization: multidisciplinary approach by interventional radiology and surgery. *Semin Intervent Radiol.* 2012; 29:192-6.
- Greaves N. Case report Gunshot bullet embolus with pellet migration from the left brachiocephalic vein to the right ventricle: a case report. *Scand J Trauma Resusc Emerg Med.* 2010; 18:36.
- Shannon FL, McCroskey BL, Moore EE, Moore FA. Venous bullet embolism: rationale for mandatory extraction. *J Trauma.* 1987; 27:1118-22.