



THE AGA KHAN UNIVERSITY

eCommons@AKU

---

Department of Medicine

Department of Medicine

---

January 2011

# Undetected common variable immune deficiency in a young adult of Pakistani descent.

M Owais Khan  
*Dow Medical College*

Adil Iqba Memon  
*Dow University of Health Sciences*

Ali Bin Sarwar Zubairi  
*Aga Khan University, ali.zubairi@aku.edu*

Asifali Imam  
*Aga Khan University, asifali.imam@aku.edu*

Follow this and additional works at: [http://ecommons.aku.edu/pakistan\\_fhs\\_mc\\_med\\_med](http://ecommons.aku.edu/pakistan_fhs_mc_med_med)



Part of the [Pulmonology Commons](#)

---

## Recommended Citation

Khan, M. O., Memon, A. I., Zubairi, A., Imam, A. (2011). Undetected common variable immune deficiency in a young adult of Pakistani descent. *JAMC: Journal of Ayub Medical College, Abbottabad*, 23(1), 165-166.

Available at: [http://ecommons.aku.edu/pakistan\\_fhs\\_mc\\_med\\_med/302](http://ecommons.aku.edu/pakistan_fhs_mc_med_med/302)

**CASE REPORT**

**UNDETECTED COMMON VARIABLE IMMUNE DEFICIENCY IN A YOUNG ADULT OF PAKISTANI DESCENT**

**M Owais Khan, Adil Iqbal Memon, Ali Bin Sarwar Zubairi\*, Asif Ali Imam\***

Dow Medical College, Dow University of Health Sciences, \*Section of Pulmonary and Critical Care Medicine, Department of Medicine, Aga Khan University, Karachi, Pakistan

Common variable immune deficiency (CVID) is a syndrome which is due to deficiency of humoral immune response resulting in increased susceptibility to infections. We report a case of CVID in a 24-year-old male who presented with a history of recurrent pneumonias.

**INTRODUCTION**

CVID is a syndrome which is due to humoral immune deficiency which typically presents after 2 years of age. This results in increased susceptibility to infections. The majority is upper and lower respiratory infections caused by *Streptococcus pneumoniae*, *Hemophilus influenzae* and *Mycoplasma pneumoniae*.<sup>1</sup>

The true incidence and prevalence of CVID are difficult to ascertain, but the estimated incidence ranges between 1:50,000 and 1:75,000.<sup>1</sup> In most patients, infections are localized to the respiratory tract, presenting as recurrent bronchitis, sinusitis and pneumonia. Most incidences of pneumonia and meningitis occur before the diagnosis of CVID. Chronic and severe respiratory tract infections often results in serious sequelae like bronchiectasis, lung fibrosis and emphysema.<sup>2</sup>

We are reporting a case of a young Asian male with recurrent pneumonias who was diagnosed to have CVID in adulthood.

**CASE REPORT**

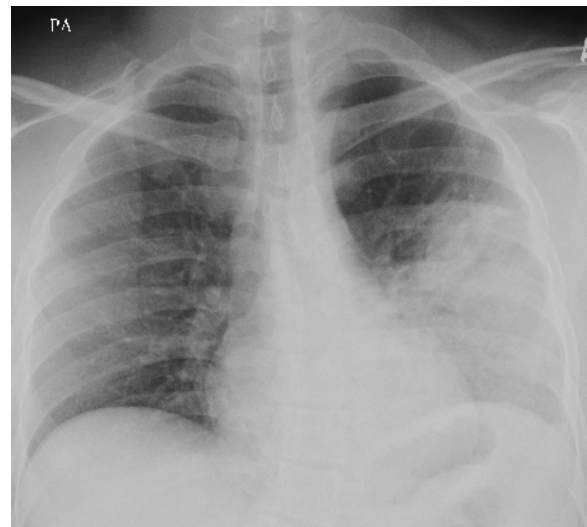
A 24-year-old Pakistani male residing in Dubai presented to the Emergency Department of Aga Khan University Hospital (AKUH, Karachi) with complaints of acute onset of fever, cough productive of mucoid sputum, nausea and vomiting for 3 days. He also complained of left-sided chest pain on changing postures. He had a history of recurrent infections with pneumonia since childhood. The last episode of Pneumococcal pneumonia occurred in 2007 requiring hospitalisation. He was a known case of Celiac disease since 10 years. He had no known allergies.

Physical examination revealed pulse 96 beats/min, blood pressure 106/54 mmHg, temperature 37 °C and respiratory rate 22 breaths/min. Cardiovascular examination revealed normal JVP, no visible pulsations over the precordium and normal heart sounds. On respiratory examination, he had dorsal scoliosis, increased vocal fremitus in left mid and lower zones, hyper resonance on left side, crackles and bronchial breath sounds in the left mid and lower zone. Rest of the systemic examination was unremarkable.

Laboratory data showed elevated WBC count of  $42.5 \times 10^9/L$  with neutrophilia of 92.9%. Blood cultures were negative and C-reactive protein (CRP) was 35.2 mg/L. Serum electrolytes, blood urea nitrogen, creatinine and liver function tests were within normal limits. Arterial blood gases revealed pH of 7.49,  $P_{CO_2}$  30 mmHg,  $P_{O_2}$  67.3 mmHg and  $O_2$  saturation of 94.5%. Chest X-Ray showed patchy alveolar infiltrates in left mid and lower lung zones (Figure-1). Serum immunoglobulin assay showed IgA <0.07g/L (Normal: 0.68–3.78 g/L), IgM 0.11 g/L (Normal: 0.68–2.63 g/L) and IgG 0.36 g/L (Normal: 6.94–16.18 g/L).

Follow-up visit after a week revealed a decrease of WBC count to  $9.0 \times 10^9/L$  with normal differential count and CRP decreased to 1.2 mg/L.

Our patient was treated with Levofloxacin and Amoxicillin-Clavulimic acid for 7 days. He was referred to Allergist-Immunologist who offered treatment with intravenous immunoglobulin (IVIG) which was refused. He was lost to follow-up therefore no further work-up for immunodeficiency like lymphocyte subset analysis, functional antibody responses to vaccination (Diphtheria, Tetanus, H. influenza etc.) and anti-blood group A and B titres could be done.



**Figure-1: Patchy alveolar infiltrates in left mid and lower lung zones**

## DISCUSSION

Common variable immunodeficiency (CVID) is characterized by hypo gamma globulinemia and varying degrees of defective T-cell and macrophage function. Impairment of the cellular immune system is often caused by a defect of T-helper cells that also lead to a polyclonal but non-specific B cell activation.<sup>3</sup> There is a bimodal age of onset which peaks between ages 1–5 and 18–25 years.<sup>4</sup>

Clinical symptoms include malabsorption, autoimmune-related symptoms like rheumatoid arthritis and systemic lupus erythematosus, blood cytopenias, hepatitis and non-caseating granulomas.<sup>5</sup> The risk for malignancy, particularly lymphomas is also increased.<sup>6</sup> They are also prone to chronic lung disease (bronchiectasis), liver disease (Hepatitis B and C) and conjunctivitis and otitis.<sup>7</sup> Several bone and joint abnormalities can occur in patients with CVID, with arthritis being the most common. Mono-arthritis or oligo-arthritis is the usual pattern, although poly-arthritis may occur, occasionally with nodules suggesting rheumatoid arthritis. Arthritis in patients with immune deficiencies is usually infectious in nature, the most common causative organism being *Mycoplasma*, followed by *Staphylococcus*, *Streptococcus*, and *Haemophilus*.<sup>8</sup> There is increased susceptibility to *Helicobacter pylori* who has gastritis. This may result from deficiency of humoral immunity, lack of B-cells and IgA plasma cells in the gastric mucosa.<sup>9</sup>

The diagnosis of CVID is made by decreased serum IgG, decreased serum concentrations of other immuno-globulins, especially IgA or IgM and decreased numbers of switched memory B-cells. Almost 20% of patients with CVID develop an autoimmune complication, most often haemolytic anaemia or immune thrombocytopenia. The pathogenesis of auto-reactivity is unknown in most CVID patients. There is decreased T-cell proliferation: decreased CD-4/CD-8 ratio, poor or absent response to immunisation (antibody titres) or characteristic clinical manifestations in absence of other detectable defects such as X-linked agammaglobulinemia.<sup>7</sup>

Patients who have received complete immunisations against polio, measles, diphtheria and tetanus will usually have very low or absent antibody levels to one or more of these vaccines.

Immunisation with other vaccines, such as the pneumococcal vaccine, is done to define the degree of immunodeficiency. In some instances, these tests help the physician decide if the patient will benefit from immunoglobulin replacement therapy.

The treatment includes immune globulin replacement therapy, purified immune globulin and antibiotics for infection control. The aim of the treatment is to keep the patient free of infections and to prevent the development of chronic lung disease. The outlook for patients with CVID depends on how much damage has occurred to their lungs or other organs before diagnosis and treatment with immunoglobulin replacement therapy and how successfully infections can be prevented in the future by using immunoglobulin and antibiotic therapy.

## CONCLUSION

This case highlights the importance of increasing awareness amongst primary care doctors for suspecting and confirming a diagnosis of CVID in young adult population. The diagnosis of CVID in most cases can be made with quantitative immunoglobulin levels. Milder and more complex forms of CVID may be more difficult to diagnose as it may require tests like specific antibody levels to bacterial antigens and IgG subclass levels to assess the functional aspect of the humoral immune system.

## REFERENCES

1. Bonilla FA, Bernstein IL, Khan DA, Ballas ZK, Chinen J, Frank MM, *et al.* Practice parameter for the diagnosis and management of primary immunodeficiency. *Ann Allergy Asthma Immunol* 2005;94(Suppl.-1):1-63.
2. Quinti I, Soresina A, Spadaro G, Martino S, Donnanno S, Agostini C, *et al.* Long-term follow-up and outcome of a large cohort of patients with common variable immunodeficiency. *J Clin Immunol* 2007;27:308-16.
3. Rosen FS, Cooper MD, Wedgewood RJ. The primary immunodeficiencies. *N Engl J Med* 1995;33:431-40.
4. Sneller MC. Common variable immunodeficiency. *Am J Med Sci* 2001;321(1): 42-8.
5. Sutor G, Fabel H. Sarcoidosis and Common Variable Immunodeficiency: A Case of a Malignant Course of Sarcoidosis in Conjunction with Severe Impairment of the Cellular and Humoral Immune System. *Respiration* 2000;67:204-8.
6. Piqueras B, Lavenu-Bombléd C, Galicier L, Bergeron-van der Cruyssen F, Mouthon L, Chevret S, *et al.* Common variable immunodeficiency patient classification based on impaired B cell memory differentiation correlates with clinical aspects. *J Clin Immunol*. 2003;23:385-400.
7. Quinti I, Pandolfi F, Paganelli R, Salman D EL, Giovannetti A, Rosso R, *et al.* HCV infection in patients with primary defects of immunoglobulin production. *Clin Exp Immunol* 1995;102:11-6.
8. Sordet C, Cantagrel A, Schaeffer T, Sibilia J. Bone and Joint Disease associated with primary immune deficiencies. *Joint Bone Spine* 2005;72:503-14.
9. Zullo A, Romiti A, Rinaldi V, Vecchione A, Tomao S, Aiuti F, *et al.* Gastric pathology in patients with common variable immunodeficiency. *Gut*. 1999;45:77-81.

### Address for Correspondence:

**Ali Bin Sarwar Zubairi**, Associate Professor, Department of Medicine, Aga Khan University, PO Box 3500, Stadium Road, Karachi 74800, Pakistan. **Cell:** +92-300-2339962  
**Email:** ali.zubairi@aku.edu