



THE AGA KHAN UNIVERSITY

eCommons@AKU

Department of Surgery

Department of Surgery

May 2001

# Treatment of tibial diaphyseal fractures with closed flexible intramedullary ender nails: 39 fractures followed for a period of two to seven years

Hussain R. Usman  
*Aga Khan University*

Muhammad A. Umer  
*Aga Khan University*

masood umer  
*Aga Khan University, masood.umer@aku.edu*

Follow this and additional works at: [http://ecommons.aku.edu/pakistan\\_fhs\\_mc\\_surg\\_surg](http://ecommons.aku.edu/pakistan_fhs_mc_surg_surg)

 Part of the [Orthopedics Commons](#)

## Recommended Citation

Usman, H., Umer, M. A., umer, m. (2001). Treatment of tibial diaphyseal fractures with closed flexible intramedullary ender nails: 39 fractures followed for a period of two to seven years. *JPMA: Journal of the Pakistan Medical Association*, 51(5), 190-193.

**Available at:** [http://ecommons.aku.edu/pakistan\\_fhs\\_mc\\_surg\\_surg/232](http://ecommons.aku.edu/pakistan_fhs_mc_surg_surg/232)

# Treatment of Tibial Diaphyseal Fractures with Closed Flexible Intramedullary Ender Nails: 39 Fractures Followed for a Period of Two to Seven Years

R. Hussain, M. Umer, M. Umar ( Orthopedic Division, Department of Surgery, The Aga Khan University, Karachi. )

## Abstract

**Objective:** To assess the efficacy of flexible intramedullary Ender nails for the treatment of tibial diaphyseal.

**Materials and Methods:** This is a retrospective review of patients treated with the Ender Nail for both open and closed tibial shaft fractures. Between January 1989 and December 1994, 43 fractures were treated with these nails. The configuration of each fracture was determined using the Orthopedic Trauma Association classification and the extent of soft tissue damage was assessed using the Gustilo and Anderson's classification. Four patients were excluded from the study due to inadequate follow-up. There were 27 closed and 12 open fractures.

**Results:** The average time to union in 34 out of 39 fractures was 17 weeks. Delayed union and malunion occurred in two patients each and superficial wound infection in 1 patient. Nonunion occurred in 5 fractures that were all located in the distal 1/3 of the tibial diaphysis. We attribute this high rate of non-union to a poor rotational control on the distal fragment by these nails.

**Conclusions:** The Ender nails provide effective fixation for the OTA stable class of tibial fractures, where they produce good axial and rotational stability by virtue of their three-point fixation. Rotational and angular stability should be improved by a supplementary cast immobilization for fractures with unstable configuration and those located in the distal third of the diaphysis (JPMA51:190;2001).

## Introduction

Non-operative treatment of tibial shaft fractures by closed reduction followed by application of cast has been the treatment of choice for low energy tibial shaft fractures<sup>1,2</sup>. However, treatment becomes more challenging when high-energy tibial fractures are to be treated. These fractures are usually displaced, comminuted, open and often associated with other injuries<sup>3</sup>. They are more unstable, slower to heal and more prone to infection, shortening and malunion. Depending upon the fracture configuration, associated soft tissue injury, availability and affordability of implants and imaging facilities, the options in operative treatment are fixation with plate and screws, closed intramedullary nailing and external fixation. As a method of fixation, the Ender nails provide the following features:<sup>1</sup>. The technique of insertion being closed, the fracture hematoma is preserved with very minimal risks of infection.<sup>2</sup> Insertion without intramedullary reaming does not disrupt endosteal blood supply to the diaphysis<sup>3-6</sup>. The flexible nails provide dynamic controlled motion, which stimulates periosteal callus formation<sup>4,7</sup>. Stacking of the canal provides axial stability and the three-point fixation produced by each nail affords rotational control<sup>5</sup>. The nails are load-sharing implants and allow early mobilization and weight bearing<sup>6</sup>. The implants are inexpensive, the instrumentation is simple and the inventory small. The technique is relatively easy once mastered and provides a consistent swift fixation. We now describe our experience with the use of the Ender nails in fractures of the tibial shaft.

## Materials and Methods

Between January 1990 and December 1994, 41 patients with 43 tibial shaft fractures were treated with the Ender's nails. Four patients with inadequate clinical and radiological follow-up were excluded from the study. This was not a consecutive series as some of the less severe injuries were treated with closed reduction and cast immobilization and some high energy unstable fractures were treated with locked intramedullary nails or with an external fixator.

Of the 37 patients, 32 were males and 5 females. Their ages ranged from 15 to 65 years, with a mean of 35 years. Two patients had a bilateral fracture. The most common site of fracture was the middle third of the tibia (n=21). Fourteen were located in the distal third and only four in the proximal third. Of the 39 fractures, 27 were closed and 12 were open. The open fractures were graded according to the classification of Gustilo and Anderson Ref. There were 7 type I, 4 type II and 1 type III open fractures. In addition the fracture configuration was assessed using the Orthopedic Trauma Association Ref (Figure 1).

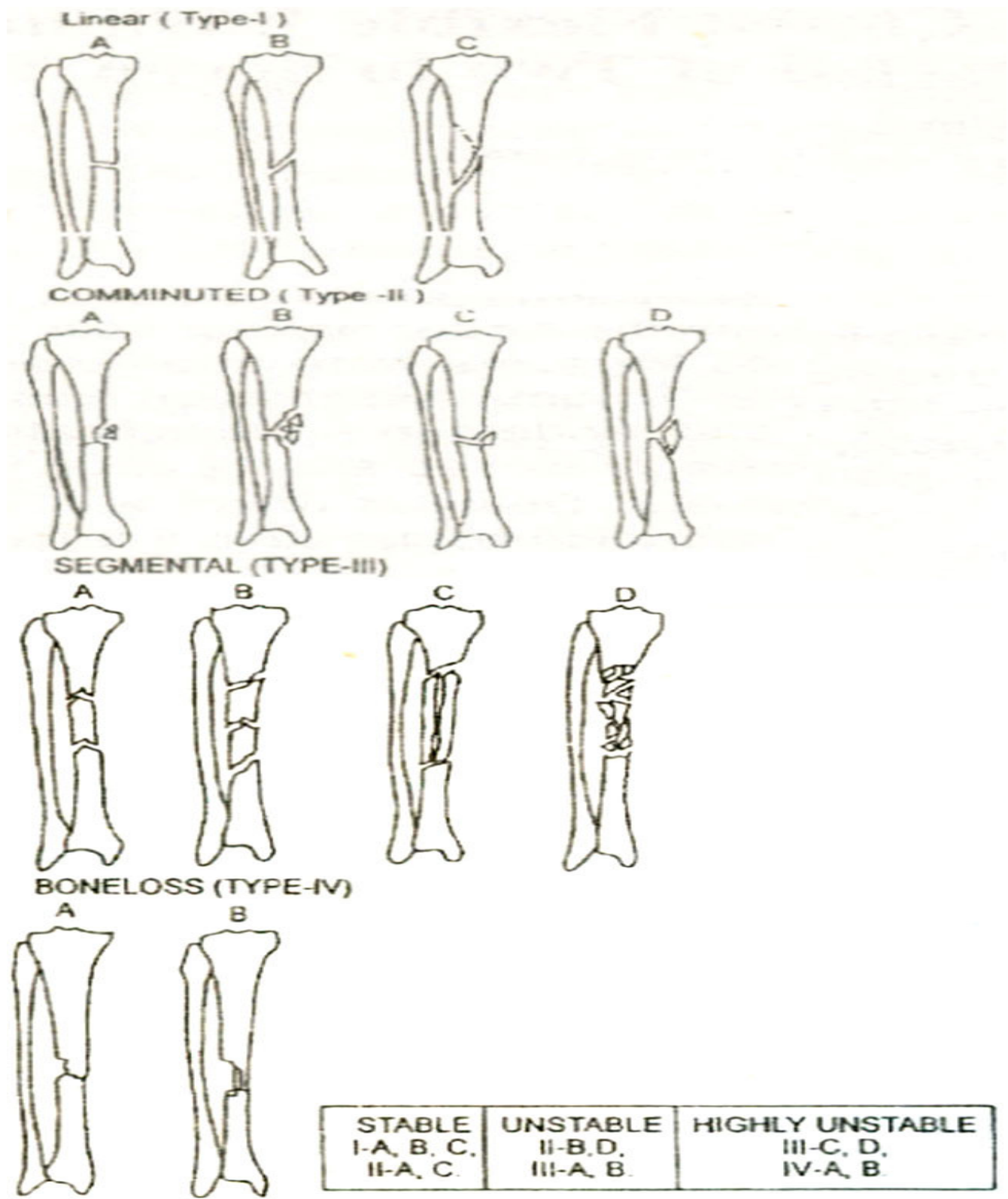


Figure 1. OTA Classification of long bone fractures.

Accordingly there were 29 stable and 10 unstable fractures. Of these 29 unstable fractures, there were 6 transverse, 17 oblique and 6 spiral fractures. The 10 unstable fractures had a wedge or a comminuted butterfly fragment which was less than 50% of the diameter of the bone. There were no highly unstable fractures in this series. In three patients the fibula was intact but the distal fragment was in an

unacceptable varus angulation which could not be reduced by closed manipulation. All patients were followed up until the endpoint of treatment i.e., union or need for a secondary procedure and spanned over a period of 2 to 7 years. Treatment for all open fractures was initiated as soon as the general condition of the patient permitted us to do so. This started with wound debridement, which involved exploration of the wound, excision of the devitalized tissue and removal of foreign material followed by irrigation with 5 to 10, liters of normal saline. Intravenous Cefazolin was started in the emergency room and continued postoperatively for 3 to 5 days. In most of the grade II and one grade III fractures, the wounds were left open at the initial debridement and the nailing was delayed for three to five days until the wound was clean both clinically and bacteriologically. Primary internal fixation was carried out in 7 out of the 12 open fractures.

Ender nailing was not used for diaphyseal fractures situated within 7.5 cm of the knee or ankle joints. Also excluded were segmental fractures and fractures with segmental comminution and segmental bone loss.

### **Operative Technique for Nail Insertion**

The patient is placed supine on the traction table. The size and the number of nails to be used are determined from preoperative radiographs. The canal size of the tibia is measured at its narrowest part. The size of the average adult medullary canal in the Pakistani population is about 7 to 9 mm which can easily accept two to three nails (medium and small diameter, 4.0 and 3.5 mm, respectively). The fracture is reduced using an image intensifier that is positioned between the legs to anteroposterior and lateral views of the bone. Five-cm long anteromedial and anterolateral oblique skin incisions are made over the flare of the proximal tibial metaphysis. Incisions are deepened to the bone and entry portals are created using a 4.5-mm drill bit in an oblique distal direction. The nails of measured size are introduced from the medial and lateral sides and advanced to the fracture site. One nail at a time is negotiated across the fracture site under image control. Traction is released and the leading ends are finally driven to their final position, which is within 1 to 2 cm of the tibial plafond. The fracture is finally examined under C-arm to ensure that the nails do not distract the fracture and that the eyelets are distal to the knee joint. The eyelets are now locked using the 3.5 mm cortical screws to prevent proximal nail migration. The subcutaneous tissue and skin are approximated and a light dressing is applied to the leg.

### **Post-Operative Management**

For all closed fractures, antibiotic prophylaxis was provided with intravenous Cefazolin, administered prior to induction of anaesthesia and continued for 24 hours postoperatively. Isometric quadriceps and range of motion exercises for the knee and ankle joint were instituted from the first post-operative day. On the second day, the dressing was changed and ambulation with weight bearing as tolerated resumed with crutches. Additional short leg cast immobilization was used in II patients with unstable and/or distal third fractures.

## **Results**

Thirty-four (87%) of the thirty-nine fractures healed within an average time of 17 weeks.

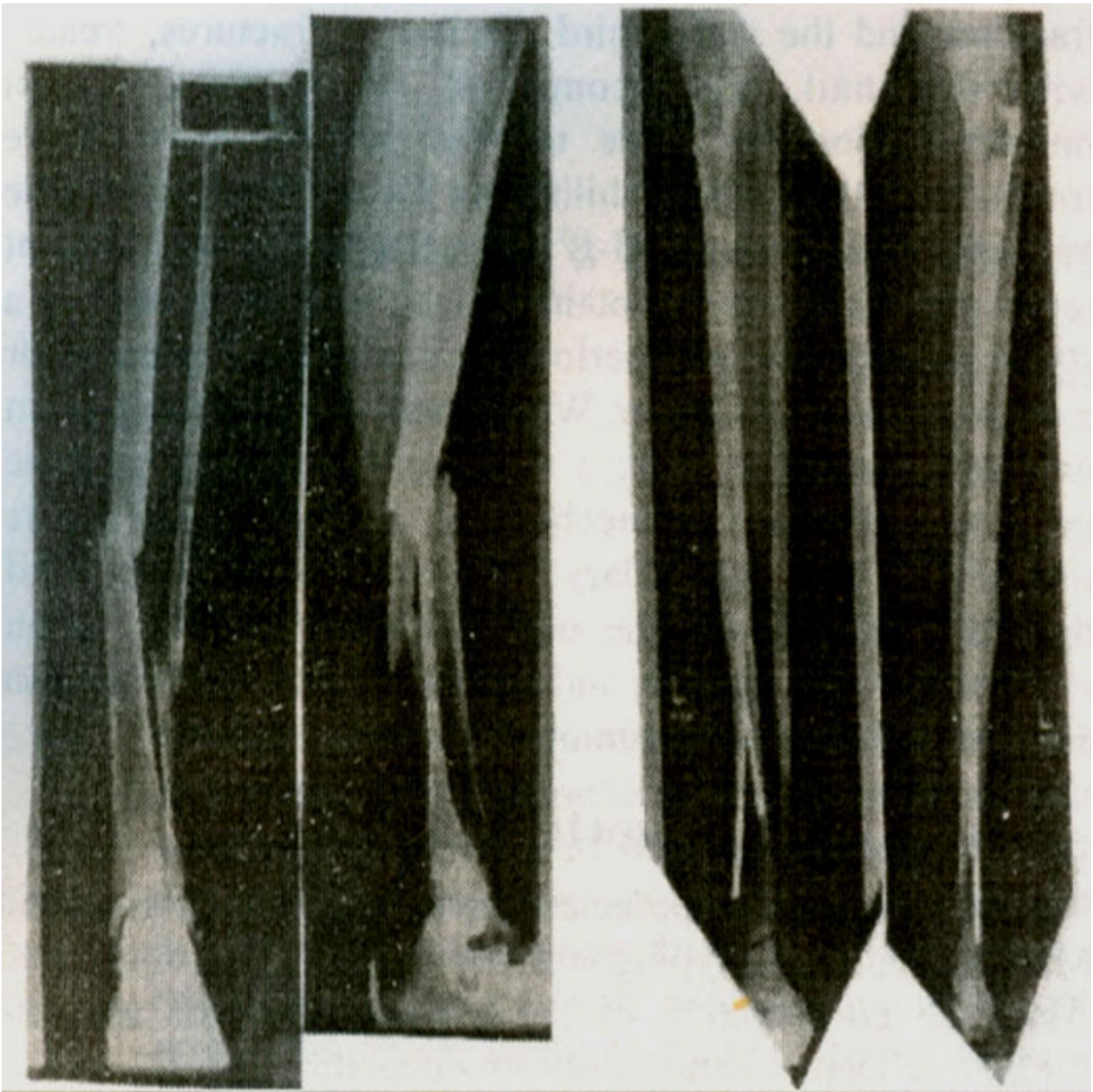


Figure 2A-D. Clinical radiograph (A) AP and (B) lateral, of a 25- year old man with a grade I, OTA 1A open tibial fracture. Ender nails were inserted. Approximately two years after the injury the fracture site is noted to have consolidated (C) and (D).

Figures 2A-D show an example of a fracture through the middle third of the tibia Two (5%) fractures were considered to have delayed union and healed at 20 and 24 weeks respectively. Another two (5%) fractures had malunion. One healed in a valgus of 10 degrees and the other in a varus of 6 degrees and neither required any intervention.

Five (13%) fractures did not heal in 9 months and we labeled them as non-unions.



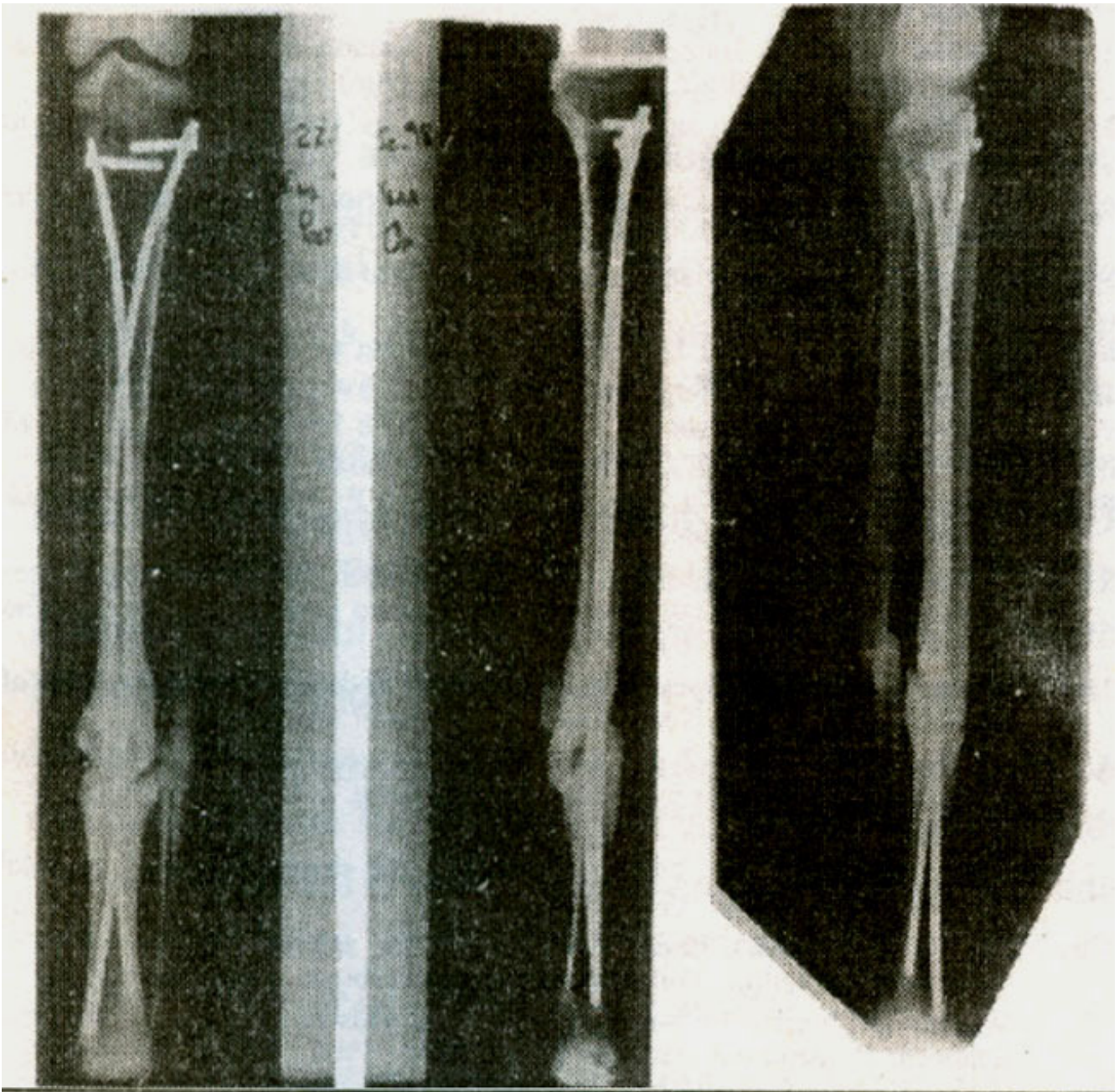


Figure 3A-C. Clinical radiographs (A) AP and (B) lateral views at 9 months after fixation of an unstable fracture at the junction of middle and distal third of tibia fixed with Ender nails. A hypertrophic non-union at the fracture site established which required exchange nailing with a reamed interlocking nail. Clinical radiograph (C) of another stable fracture, one year post-operatively, at the junction of the middle and distal third of tibia, which developed a hypertrophic non-union.

Figure 3A-B show the postoperative radiographs at 6 months of an unstable union at the junction of middle and distal third of the tibia, with a small bridging callus at the fracture. Radiographs at one-year post-operative showed a hypertrophic non-union.



---

Figure 4. Poor rotational control occurs when the location of the fracture coincides with intersection of the two nails, which provides an axis of rotation around the nails.

Figure 3-C shows another similar case.

Superficial wound infection occurred in one patient (2.5%). This patient with a grade I open fracture developed a staphylococcal stitch abscess which responded to removal of sutures and administration of oral cloxacillin for one week (Table 1).



## Table 1. Fracture configuration.

Type of Union	Stable (N=10)	Unstable (N=10)
Delayed Union	0	2
Malunion	0	2
Non-Union	4	1

No deep wound infection or osteomyelitis occurred in our series. There were no procedure-related complications like bending, breakage, or migration of the nails or penetration of the ankle or knee joints.

### Discussion

The time to union for both closed and open tibial fractures, as reported in the literature ranges from 15 to 22 weeks<sup>8-15</sup>. The average time to union of 17 weeks in our study corresponds to this period. Similarly the rate of matunion, delayed union and infection in this series is lower than other forms of tibial fractures<sup>16,20</sup>

The rate of non-union, however, was noted to be at the upper end of the spectrum as reported in the literature<sup>9,13,16,17,21</sup>. To seek an explanation we decided to analyze the problems with fracture union against three variables .viz.,1. The fracture conlfiguration;2. The fracture type i.e., closed v/s open and 3. The fracture site (Tables 2 and 3).

**Table 2. Open fracture grades.**

	Closed	G-I	G-II	G-III
Type of Union	(N=27)	(N=7)	(N=4)	(N=1)
Delayed Union	2	0	0	0
Malunion	2	0	0	0
Non-Union	4	0	1	0

**Table 3. Problems with Union vs Type of Fracture.**

	Closed	G-1	G-2	G-3
Type of Union	(N=27)	(N=7)	(N=4)	(N=1)
Delayed Union	2	0	0	0
Malunion	2	0	0	0
Non-Union	4	0	1	0

The first observation we made was that the 2 cases each of delayed union and mal-union occurred in closed fractures, which were unstable (<50% circumferential cortical contact).

The second observation, rather unexpected, was that in four out of five fractures, a hypertrophic non-union occurred in the stable configuration, all of which were closed, and being the so called low energy tibial fractures, at the junction between the middle and distal third of the bone. Based on the above evidence it was inferred that excessive motion due to poor rotational control at the fracture, predisposed to the hypertrophic non-union. This occurs when the location of the fracture coincides with the intersection of the two nails, which provides an axis of rotation for the fracture fragments (figure 4). One atrophic non-union occurred in an unstable and grade II open fracture located in the middle third of the diaphysis. All patients required a revision of fixation for the non-union.

The study confirms that Ender nails provide an effective method of treatment for most closed and open grade I and II fractures with stable configuration and the technique is relatively simple and the implants quite cheap. However, for the high risk tibial fractures i.e., unstable fractures and the distal third diaphyseal fractures, treated with this nail, we recommend, supplementary cast immobilization for

three to four weeks, to improve rotational and angular stability. As for the highly unstable and grade 111-A and III-B open fractures, the current recommendation is to obtain a clean wound as well as a stable fracture with an interlocking nail without reaming or a dynamic external fixator. When small diameter nails or an external fixator are used, a secondary procedure may be necessary due to biomechanical limitations of these implants. The secondary procedures include nail dynamisation, exchange nailing with reaming, open autogenous bone grafting and fibular osteotomy, alone or in combination to promote union.

## Acknowledgements

We sincerely appreciate the efforts of Mr. Sarwat and Mr. Hameed, in the typing and formatting of this document. Also, the co-operation of the Medical Records and the Radiology Departments is acknowledged.

## References

1. Johnson R J, Pope MH. Tibia) shaft fractures in skiing. Am. J. Sports Med., 1997;549-61.
2. Van Der Linden W, Sunzet H , Larsen K Fractures of the tibial shaft after skiing and other accidents. J Bone Joint Surg (Am), 1975;57A: 321-27.
3. Fraser R D. Hunter G A and Waddel J P.: Ipsilateral fractures of the femur and tibia. J. Bone Joint Surg (Br), 1978;60B: 510-515.
4. IAN Macnab and W.G De Hass: The role of periosteal blood supply in the healing of fractures of the tibia. Clin. Orthop., 1974;105:27-33.
5. Joseph T.: Blood supply and the rate of healing of tibial shaft fractures. Clin Orthop. 1974;105:11-26.
6. Rhinelander FW. Tibial blood supply in relation to fracture healing. Clin Orthop 1981;105:34-81.
7. Pankovich AM, Tarabishi F. Yelda S.: Flexible intramedullary nailing of tibial shaft fractures. Clin. Orthop., 1981; 160:185-95.
8. Bramowitz, Weizler M .J. Lew A S, Whitlaw G P.: Treatment of open tibial fractures with Ender Rods. Clin. Orthop.. 1993;293:246-55.
9. Holbroom JL, Swiontkowski M F and Saunders R. Treatment of open fractures of the tibial shaft. Ender nailing vs open external fixation. J. Bone Joint Surg (Am), 1989;71-A: 1231-1239.
10. Maver L, Werbie I, Schwab J et al The use of Ender nails in the fractures of the tibial shaft. J. Bone Joint Surg (Am), 1985;67:-A 446-48.
11. Merianos P, Caunbouris P and Symrins M. The treatment of 143 tibial shaft fractures by Ender nails and early weight bearing. J. Bone Joint Surg (Br).. 1985;67-13:576-77.
12. Sedin ED, Zetner DT. The Loites Nail in the closed treatment of tibial fractures. Clin. Orthop.. 1985;92:185-87.
13. Segal, Wiss DA.: Ender Nailing in the science and practice of intramedullary nailing. Philadelphia, Lea and Febiger. 1987, pp. 291-304.
14. Whitlaw GP, Wetzler NI. Nelson A, et al Ender rods vs external fixation in the treatment of open tibial fractures. Clin Orthop. 1990;253:258-59.
15. Wiss DA. Flexible medullary nailing of acute tibial shaft fractures. Clin Orthop., 1986;212:22-24.
16. Bach A W and Hansen ST Plate versus external fixation in severe open tibial fractures. A randomised trial. Clin Orthop., 1989;241:89-92.
17. Behrens F, Comfort T H, Searls K. et al Unilateral external fixation for severe open tibial fractures. Preliminary report of a prospective study. Clin Orthop., 1983;178:111-15.
18. Darder A, Gorner F. A Series of open tibial fractures treated conservatively. Injury, 1975;6:225-26.
19. Edwards C C, Simmons S C, Browner B D et al. Severe open tibial fractures: Results of treatment

of 202 injuries with external fixation. Clin Orthop., 1981;230:98-99.

20. Gustilo R B, Anderson J T. Prevention of infection in the treatment of one thousand and twenty-five open fractures of long bones. Retrospective and prospective analysis. J Bone Joint Surg (Am.), 1976;58-A:453-58.

21. Pfitzner RM, Tevnor JT, Nagano J et al. Critical analysis of results of treatment of 201 humeral shaft fractures. Clin. Orthop 1986;212:113-15.