



THE AGA KHAN UNIVERSITY

eCommons@AKU

---

Department of Surgery

Department of Surgery

---

November 2005

# Dural metastases presenting as an extradural hematoma: a rare presentation

Muhammad Shahzad Shamim

*Agha Khan University*, [shahzad.shamim@aku.edu](mailto:shahzad.shamim@aku.edu)

Muhammad Ehsan Bari

*Agha Khan University*, [ehsan.bari@aku.edu](mailto:ehsan.bari@aku.edu)

S. Ather Enam

*Agha Khan University*, [ather.enam@aku.edu](mailto:ather.enam@aku.edu)

Follow this and additional works at: [http://ecommons.aku.edu/pakistan\\_fhs\\_mc\\_surg\\_surg](http://ecommons.aku.edu/pakistan_fhs_mc_surg_surg)

 Part of the [Neurology Commons](#), and the [Surgery Commons](#)

---

## Recommended Citation

Shamim, M., Bari, M., Enam, S. (2005). Dural metastases presenting as an extradural hematoma: a rare presentation. *JPMA: Journal of The Pakistan Medical Association*, 55(11), 509-510.

**Available at:** [http://ecommons.aku.edu/pakistan\\_fhs\\_mc\\_surg\\_surg/191](http://ecommons.aku.edu/pakistan_fhs_mc_surg_surg/191)

## Case Report

### Dural metastases presenting as an extradural hematoma: a rare presentation

Muhammad Shahzad Shamim, Muhammad Ehsan Bari, Syed Ather Enam

Department of Neurosurgery, The Aga Khan University Hospital, Karachi.

#### Abstract

We report a case of an elderly man who presented with hemiparesis and plain CT scan findings highly suggestive of an extradural hematoma as the underlying cause. This patient was later found to have dural metastases secondary to bronchogenic carcinoma. Dural metastases are rare, usually presenting as dural mass, but may also present as chronic subdural or extradural hematoma on non contrast CT scan, leading to an erroneous diagnosis in the unsuspecting.

#### Introduction

Extradural hematomas usually occur secondary to trauma, and are more common in younger patients with only 10% seen in patients older than 50 years.<sup>1</sup> The classical CT scan finding is the double convex or lens shaped hematoma at the cerebral convexity, in the territory of middle meningeal artery, underlying a skull fracture although alternate diagnosis have been reported.<sup>2</sup> Brain metastases can occur in all cancers but are seen more commonly with breast and lung carcinomas. They are typically found in the cerebral hemispheres with a predilection for border zone regions of cerebral vascular supply and isolated dural metastases are rare. On CT scan, brain metastases most often appear as circumscribed parenchymal lesions of any density, showing heterogenous enhancement after contrast infusion. On extremely rare occasions, brain metastases, on plain CT scan, may appear almost identical to an extradural hematoma, and with a preceding history of head injury, may lead to a diagnostic dilemma for both the radiologist and the neurosurgeon.

#### Case report

Seventy years old man, chronic smoker, diabetic, hypertensive, presented to the Emergency Room (ER) with a history of fall in the toilet three weeks back and subsequent right sided hemiparesis. Patient had no history of loss of consciousness, vomiting, fits or headache although patient's son reported gradual alteration in conscious level after the fall. Past history revealed a curative upper lobectomy of the left lung two years ago with a histologically proven large cell bronchogenic carcinoma. On examination, he was drowsy but followed commands, had right sided motor weakness and brisk reflexes. Pupils were reactive bilaterally but dilated on left side.

Plain CT scan of brain showed a 10 x 3.4 cm iso-dense lesion over cerebral convexity of left parietal lobe, con-

sistent with extradural hematoma causing compression over ipsi-lateral ventricle and edema of underlying brain with mid-line shift towards right side. A hypo dense area was also visualized in left cerebellar hemisphere likely to be an old infarct. With a diagnosis of chronic extradural hematoma, a left mini craniotomy was carried out (Figure 1). Chest X Ray showed evidence of previous surgery (Figure 2).

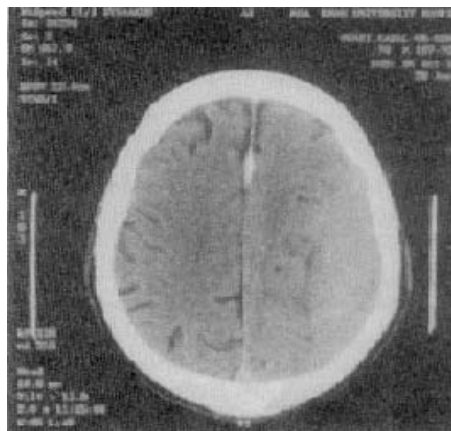


Figure 1. CT scan of patient showing the classical double convex appearance of an extradural hematoma.

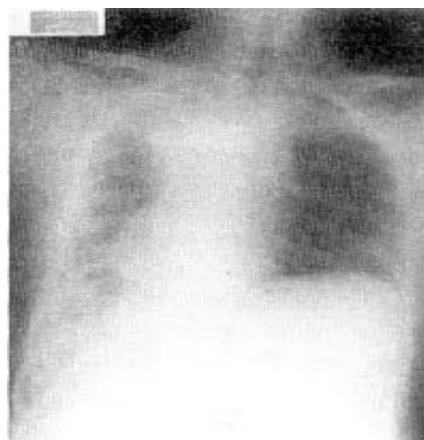


Figure 2. Chest X Ray following upper lobectomy of left lung. Liga clips also visible.

Intra-operatively, a large, firm to solid lesion involving both sides of the dura were found. It was adherent to the dura and was removed with difficulty. Histopathology revealed metastatic carcinoma compatible with known primary lung origin. Patient made an uneventful recovery with

improvement in both weakness and conscious level and an unremarkable one week follow up. Post operative CT scans revealed total excision of tumour and the patient was referred for radiotherapy.

## Discussion

Extradural hematoma occurs in 2% of all patients admitted for head injuries and results from tearing of dural or skull vessels caused by deformation or fracture of the skull.<sup>3</sup>

Lung cancer is the second most common cancer and the leading cause of cancer related deaths in both men and women in the United States and the risk of diagnosis and death in a lifetime in men is 7.9% and 5.8%, and in women is 7.5% and 4.9% respectively.<sup>4</sup> The majority of lung cancer patients are between 35 and 75 years old, with a peak incidence between the ages of 55 and 65. Large cell carcinoma is the least common of non small cell lung cancers (NSCLC), accounting for approximately 15% of all lung cancers. These are known to metastasize early and the more common sites for metastases are bone, liver, adrenals and brain.

Brain metastases are found at autopsy in 10% to 15% patients with cancer. These are of three basic types; a) metachronous: a lesion that appears at a different site months to years after the primary lesion is successfully controlled (7-14%), b) precocious: a metastatic lesion is the first sign of cancer with no detectable source (5-10%), and c) synchronous: metastasis and primary cancer present simultaneously (80-85%). Lung is the most frequent primary site for metastases to brain; varying from 28% to 59% in literature.<sup>5</sup> Approximately 80% of brain metastases are found in the cerebral hemispheres, 17% in the cerebellum and 3% in the brainstem although non random patterns have also been observed.<sup>6</sup> The pathophysiology of dural metastases is still a subject of debate and both venous and arterial dissemination have been implicated as possible mechanisms. On CT scan, brain metastases most often appear as circumscribed parenchymal lesions of any density, showing heterogenous enhancement after contrast infusion.

In our case, the history strongly suggested an intracranial injury secondary to trauma, more likely to be a slowly expanding subdural haematoma keeping in mind the patient's age and absence of skull fracture. When the plain CT scan was obtained and the classical radiographic find-

ings of extradural haematoma observed, a diagnosis of chronic extradural haematoma seemed straightforward and a contrast scan was not ordered, which may have led to the correct diagnosis. Furthermore, since a metastases rarely seen, the diagnosis of this lesion as a metastasis instead of extradural haematoma was not entertained. Interestingly, even the unlikely but correct diagnosis of dural metastases would still not have changed the management as patients who present with a solitary cerebral metastasis after resection of a primary NSCLC lesion and who have no evidence of extra-cranial tumor, have been shown to achieve prolonged disease-free survival with surgical excision of the brain metastasis and postoperative whole brain irradiation.<sup>7</sup> Dural metastases have also been reported to be confused with meningiomas on radiographic appearance and neoplastic lesions presenting as extradural haematoma have been reported in plasmacytomas and other tumours as well.<sup>8-11</sup> Thus with a knowledge of history of malignancy, these unusual presentations should be considered and even in the absence of a history of malignancy, one should keep in mind a precocious metastasis presenting as hematoma.

## References

1. Marshall L, Gautille T, Klauber MR. The outcome of severe closed head injury. *J Neurosurg* 1991;75:S28-S36.
2. Singleton SD, Koerner CE. Lenticular lesions: not always an epidural hematoma. *Pediatr Emerg Care* 2001;17:252-4.
3. Lindenberg R. Trauma of meninges and brain in Minckler J (eds). *Pathol Nerv Syst Vol. 2*. New York McGraw Hill. 1971;2:1705-65.
4. Ries LAG, Eisner MP, Kosary CL, Hankey BF, Miller BA, Clegg L, et al. SEER Cancer Statistics Review, 1973-1999, National Cancer Institute [http://seer.cancer.gov/csr/1973\\_1999/2002](http://seer.cancer.gov/csr/1973_1999/2002)
5. Chevalier TL, Smith FP, Caille P, Constans JP, Rouesse JG. Sites of primary malignancies in patients presenting with cerebral metastases. A review of 120 cases. *Cancer* 1985;56:880-2.
6. Tikhman AJ, Patchell RA. Brain metastasis. Morantz RA, Walsh JW, editors. *Brain tumors*. New York: Marcel Dekker, Inc 1995;553-6.
7. Patchell RA, Tibbs PA, Walsh JW, Dempsey RJ, Maruyama Y, Kryscio RJ, et al. A randomized trial of surgery in the treatment of single metastases to the brain. *New Eng Jour of Med* 1990;322:494-500.
8. Richello A, Sparano L, Del Basso De Caro ML, Russo G. Dural metastasis mimicking falx meningioma. Case report. *J-Neurosurg-Sci* 2003;47:167-71.
9. Tagle P, Villanueva P, Torrealba G, Huete I. Intracranial metastasis or meningioma? An uncommon clinical diagnostic dilemma. *Surg-Neurol* 2002;58:241-5.
10. Rutherford SA, Leach PA, Richardson PL. Solitary skull vault plasmacytoma masquerading as an extradural haematoma. *Acta Neurochir* 2004;146:863-4.
11. Rabin DN, Ramsey RG, Vedanthum KS, Foust RJ, Rabin M. Extradural lymphoma presenting as an acute surgical emergency. *Neurosurgery* 1987;20:788-90.