



THE AGA KHAN UNIVERSITY

eCommons@AKU

---

Department of Pathology and Laboratory Medicine

Medical College, Pakistan

---

October 2015

# Aleukemic myeloid sarcoma of the breast

Muhammad Shariq Shaikh

*Aga Khan University*, [muhammad.shariq@aku.edu](mailto:muhammad.shariq@aku.edu)

Naila Kayani

Follow this and additional works at: [http://ecommons.aku.edu/pakistan\\_fhs\\_mc\\_pathol\\_microbiol](http://ecommons.aku.edu/pakistan_fhs_mc_pathol_microbiol)

 Part of the [Pathology Commons](#)

---

## Recommended Citation

Shaikh, M. S., Kayani, N. (2015). Aleukemic myeloid sarcoma of the breast.

**Available at:** [http://ecommons.aku.edu/pakistan\\_fhs\\_mc\\_pathol\\_microbiol/463](http://ecommons.aku.edu/pakistan_fhs_mc_pathol_microbiol/463)

# Aleukemic Myeloid Sarcoma of the Breast

Muhammad Shariq Shaikh and Naila Kayani

## ABSTRACT

Myeloid sarcoma is a solid collection of leukemic blast cells outside bone marrow. It is seen infrequently in association with overt Acute Myeloid Leukemia (AML), however, it invariably transforms into this aggressive condition. A 28-year woman presented with a lump in left breast for last 2 years. Morphological and immunophenotypic results of breast mass were consistent with myeloid sarcoma. Bone marrow aspirate and biopsy were normal, however, patient died after one and a half years of diagnosis. Myeloid sarcoma at any extramedullary site heralds development of overt acute myeloid leukemia and should be appropriately managed at the time of diagnosis.

**Key Words:** Myeloid sarcoma. Breast. Acute myeloid leukemia. Extramedullary myeloid sarcoma.

## INTRODUCTION

Myeloid sarcoma also known as chloroma (due to greenish hue) or granulocytic sarcoma is a solid tumor composed of myeloblasts and is considered an extramedullary manifestation of Acute Myeloid Leukemia (AML).<sup>1</sup> Skin<sup>2</sup> and gums<sup>3</sup> are most frequently involved areas and clinical manifestations mainly depend upon the site of involvement.<sup>4,5</sup> The use of immunohistochemical stains<sup>6</sup> and flow cytometry is valuable in the accurate diagnosis of myeloid sarcoma. As it predicts a poor prognosis, with a poorer response to treatment and worse survival, treatment usually is similar to AML with consideration of local excision or radiation whenever indicated.

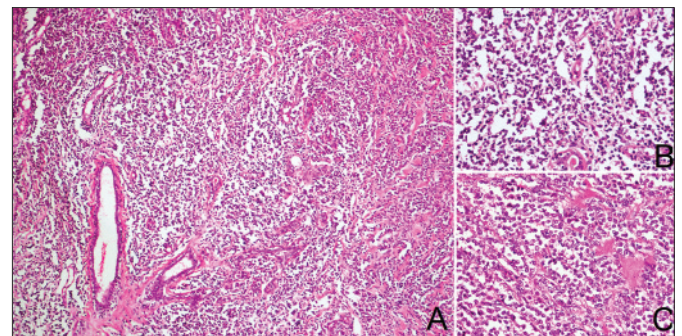
We report a case of young female who presented with lump in breast.

## CASE REPORT

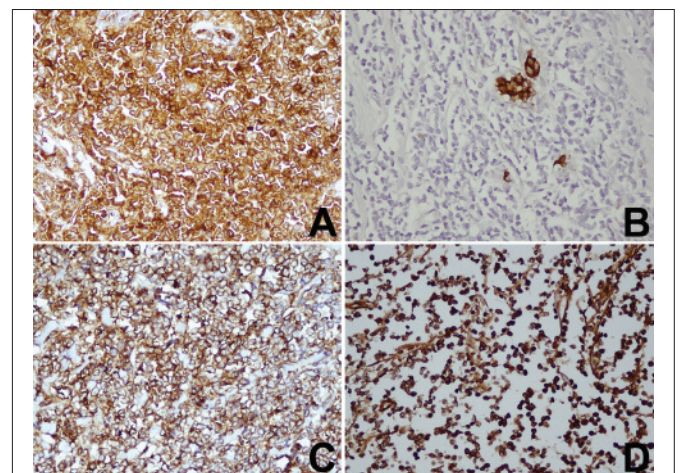
A 28-year old woman from Balochistan presented with history of lump in left breast which she discovered on self-examination. The lump was painless and static in size over the past 2 years. She had no history of shortness of breath, fever, bruising or bleeding from any site. Her personal history was unremarkable. General physical and systemic examinations did not reveal any abnormal findings. Examination of the lump revealed an approximately 7 x 6 cm, firm, non-tender fixed mass in upper-outer quadrant of the breast without associated lymphadenopathy. Ultrasound scan of the breast showed a hypoechoic area measuring approximately 6 cm in diameter. Based on atypical examination and

ultrasound findings, excisional biopsy of the breast lump was carried out.

Gross examination of the mass revealed nodular tissue piece measuring 6.5 x 5.5 x 4 cm. Cut section showed a grey-white lesion with areas of hemorrhage. Microscopic examination of the sections showed extensive infiltration of breast tissue by a neoplastic lesion comprising of sheets of intermediate sized cells exhibiting scant cytoplasm, round to oval nuclei with fine chromatin and inconspicuous nucleoli and mitotic figures (Figure 1 A,B



**Figure 1:** Haematoxylin and Eosin stained sections of breast tissue showing infiltration by myeloid sarcoma. (A) at 20x (B, C) at 40x.



**Figure 2:** Immunohistochemistry on breast tissue sections. (A) Leucocyte common antigen. (B) Cytokeratin. (C) CD34. (D) Myeloperoxidase.

Department of Pathology and Laboratory Medicine, The Aga Khan University Hospital, Karachi-74800.

Correspondence: Dr. Muhammad Shariq Shaikh, Bungalow A-1/D, (Ground Floor), Block E, Unit No. 6, Latifabad, Hyderabad.

E-mail: muhammad.shariq@aku.edu

Received: June 04, 2014; Accepted: June 19, 2015.

and C). As a part of initial immunohistochemical workup, leucocyte common antigen (Figure 2A) was positive whereas, cytokeratin AE1/AE3 (Figure 2B) was negative. Amongst second line immunohistochemical stains, tumor cells showed positivity for CD34 (Figure 2C), CD117, CD43 and MPO (Figure 2D). Mib-1 (Ki-67) was positive in approximately 30% of tumor cells. Other haematopoietic immunohistochemical stains including Pan B (CD20), Pan T (CD3) and terminal deoxynucleotidyl enzyme (TdT) were negative. Bone marrow aspirate and biopsy procedure was also performed as a part of workup. Peripheral blood counts including hemoglobin level (13.7 g/dl), leucocyte count ( $5.4 \times 10^9/L$ ) with differential count and platelet count ( $257 \times 10^9/L$ ) were within normal limits. Examination of peripheral blood film revealed no abnormal cells and bone marrow aspirate and biopsy showed trilineage hematopoiesis with less than 5% blast cells and normal cellularity for age.

Patient returned to her native area without further medical attention. Few months later, she developed fever, weakness, weight loss and bone pains. Patient's family did not seek specialized medical assistance and no further workup was carried out. However, she was managed conservatively in her native residential area including antipyretics, antibiotics, intravenous fluids and multiple blood transfusions. Almost after one and a half years of the diagnosis of myeloid sarcoma, she succumbed to her illness and died most likely secondary to overt acute myeloid leukemia.

### DISCUSSION

The report described a case of myeloid sarcoma involving the breast without any evidence of bone marrow involvement. The myeloid sarcoma is known as primary as in this case, if it occurs in the absence of acute or chronic myeloproliferative condition. Median time to development of acute leukemia is 7 months (range 1 - 25 months). However, maximum time period of > 12 years has also been reported in the literature.<sup>7</sup>

Involvement of breast by myeloid sarcoma is usually detected in cases without involvement of bone marrow at the time of diagnosis.<sup>8</sup> Whereas, concomitant involvement of other sites in addition to breast is usually found in cases of relapsed AML<sup>9</sup> or progression of chronic myeloproliferative neoplasms. This patient belonged to a remote area of the country and she visited the tertiary care center at the time of initial diagnosis only. Her family did not opt for specific treatment even when she became symptomatic. However, history of recurrent infections, weight loss, bone pains and multiple blood transfusions, ultimately leading to death is an indirect evidence of development of overt acute myeloid leukemia. Initiation of appropriate chemo-

therapeutic regimen at an earlier stage could have saved her life.

Involvement of breast by myeloid sarcoma is a rare entity and its detection becomes more challenging when there is no pre- or coexisting acute or chronic myeloproliferative neoplasm. Misdiagnosing myeloid sarcoma as carcinoma or malignant lymphoma is a common clinical practice error.<sup>10</sup> A high index of suspicion based on histological findings and a panel of immunohistochemical stains and/or flow cytometry is helpful in making the correct diagnosis. Prompt treatment including surgical resection and/or radiotherapy along with chemotherapy should be initiated at the time of diagnosis. In this regard, appropriate counselling of patients and their families about possible consequences of the diagnosis is of paramount importance.

### REFERENCES

1. Seifert RP, Bulkeley W 3rd, Zhang L, Menes M, Bui MM. A practical approach to diagnose soft tissue myeloid sarcoma preceding or coinciding with acute myeloid leukemia. *Ann Diagn Pathol* 2014; **18**:253-60.
2. Ishikawa M, Miyagishima T, Sawada K, Muranaka T, Umemura M, Kato R, *et al.* Case report; myeloid sarcoma with systemic lymphadenopathy, skin and gastrointestinal infiltration. *Nihon Naika Gakkai Zasshi* 2014; **103**:437-9.
3. Guastafierro S, Falcone U, Colella G. Gingival swelling and pleural effusion: non-leukemic myeloid sarcoma. *Eur J Haematol* 2013; **91**:94.
4. Kyaw TZ, Maniam JA, Bee PC, Chin EF, Nadarajan VS, Shanmugam H, *et al.* Myeloid sarcoma: an unusual presentation of acute promyelocytic leukemia causing spinal cord compression. *Turk J Hematol* 2012; **29**:278-82.
5. Messenger M, Amielh D, Chevallier C, Mariette C. Isolated granulocytic sarcoma of the pancreas: a tricky diagnostic for primary pancreatic extramedullary acute myeloid leukemia. *World J Surg Oncol* 2012; **10**:13.
6. Aggarwal E, Mulay K, Honavar SG. Orbital extra-medullary granulocytic sarcoma: clinicopathologic correlation with immunohistochemical features. *Surv Ophthalmol* 2014; **59**: 232-5.
7. Garcia MG, Deavers MT, Knoblock RJ, Chen W, Tsimberidou AM, Manning JT Jr, *et al.* Myeloid sarcoma involving the gynecologic tract: a report of 11 cases and review of the literature. *Am J Clin Pathol* 2006; **125**:783-90.
8. Delporte F, Voorhoopf LJ, Lodewyck T, De Paepe P. Primary granulocytic sarcoma of the breast: a case report and review of the literature. *Eur J Gynaecol Oncol* 2011; **32**:435-8.
9. Toumeh A, Phinney R, Kobalka P, Mohamed I. Bilateral myeloid sarcoma of the breast and cerebrospinal fluid as a relapse of acute myeloid leukemia after stem-cell transplantation: a case report. *J Clin Oncol* 2012; **30**:e199-201.
10. Klco JM, Welch JS, Nguyen TT, Hurley MY, Kreisel FH, Hassan A, *et al.* State of the art in myeloid sarcoma. *Int J Lab Hematol* 2011; **33**:555-65.

