



THE AGA KHAN UNIVERSITY

eCommons@AKU

Department of Surgery

Department of Surgery

December 2014

Our experience with van nes rotationplasty for locally advanced lower extremity tumours

Raza Askari
Aga Khan University

masood umer
Aga Khan University, masood.umer@aku.edu

Mohsin-e-Azam
Aga Khan University

Haroon Rashid
Aga Khan University, haroon.rashid@aku.edu

Follow this and additional works at: http://ecommons.aku.edu/pakistan_fhs_mc_surg_surg

 Part of the [Orthopedics Commons](#), and the [Surgery Commons](#)

Recommended Citation

Askari, R., umer, m., Mohsin-e-Azam, ., Rashid, H. (2014). Our experience with van nes rotationplasty for locally advanced lower extremity tumours. *JPMA : Journal of the Pakistan Medical Association*, 64(12), S-139-S-143.

Available at: http://ecommons.aku.edu/pakistan_fhs_mc_surg_surg/181

Our experience with Van Nes Rotationplasty for locally advanced lower extremity tumours

Raza Askari, Masood Umer, Mohsin-e-Azam, Haroon-ur-Rashid

Abstract

Objective: To present an early experience with the time-tested technique of Van Ness Rotationplasty to save distal limbs.

Methods: Van Nes Rotationplasty for locally advanced lower extremity tumours. A retrospective audit was conducted at Aga Khan University Hospital, Karachi, and comprised cases of bone and soft tissue sarcoma who underwent Van Ness Rotationplasty over seven years from January 2005 to December 2011. Demographic data, family history, past history, co-morbidities, date since diagnosis, duration of symptoms, type of tumour, metastasis, pre- and post-operative functional status, recurrence and survival were collected.

Results: Of the 351 cases of bone and soft tissue sarcoma, 9 (2.6%) underwent Van Ness Rotationplasty and were included in the study. The mean duration of symptoms was 7 ± 3 SD months (range: 8-41 months). All except 1 (11.1%) were osteogenic sarcomas. All except 1 (11.1%) involved distal femur. Overall, 7 (77.8%) had localised Enneking stage IIB disease. Two (22.2%) patients expired due to metastatic disease, but none had local recurrence. Complete excision of tumour was achieved in all (100%) patients. Longest follow-up was of 34 months while the shortest was of 6 months. No local recurrences were noted. Functional recovery was good. Two (22.2%) patients had simultaneous sciatic nerve repair as part of the primary procedure. Both of them had good motor function at the time of final follow-up. Mean Musculoskeletal Tumour Society score was 23.88 ± 2 SD.

Conclusions: Van Nes Rotationplasty was found to be a successful alternative to amputation in cases of locally advanced tumours of distal femur or proximal tibia.

Keywords: Amputation, Bone neoplasm, Van Nes Rotationplasty, Limb salvage. (JPMA 64: S-139 (Suppl. 2); 2014)

Introduction

Rotationplasty for functional replacement of knee joint by the rotated ankle joint was described in 1930 by Borggreve in a patient who had severe shortening of leg after tuberculosis of the knee.¹ Later, this technique was used to treat patients who had congenital deficiency of femur.²⁻⁷ The first rotationplasty after resection of osteosarcoma in the distal part of femur in a child was performed at the Orthopaedic University Clinic in Vienna in 1974.⁸

In patients who have had a primary osteogenic sarcoma, the improved rate of survival after the introduction of effective adjuvant chemotherapy has accentuated the need for optimum restoration of function. In the past, either disarticulation at the hip or proximal above-the-knee amputation was performed. Currently, rotationplasty is commonly used for limb salvage in patients who have a sarcoma of the lower extremity and as an alternative to above-the-knee amputation when resection of the tumour followed by endoprosthetic

reconstruction does not seem possible. En bloc resection of the tumour together with the intact knee joint allows oncologically safe margins to be achieved operatively even if the tumour has invaded the knee joint or the popliteal vessels.⁹ The procedure can be performed for malignant lesions in the proximal tibia or in distal femur.

In this procedure, segments of the femur or tibia, with adjacent soft tissue, are removed, and the neurovascular bundle is kept intact. The remaining distal part of the limb is rotated 180 degrees and is then attached to the femoral stump. For this operation to be done, the nerves must be intact and the principal vessels, if involved, must be able to be reconstructed with vascular grafts. Van Nes tibial rotationplasty allows wide excision of the tumour and continuation of longitudinal bone growth.

The Van Nes tibial rotationplasty has been used previously for reconstruction after excision of a tumour. Murray et al. measured the strength in the limb and the pattern of gait in two children who had had rotationplasty at the ages of six and seven years and concluded that the procedure was a worthwhile alternative to above-the-knee amputation. Knahr et al. evaluated the function of 12 patients who had had rotationplasty, most of whom could

.....
Aga Khan University Hospital, Karachi.

Correspondence: Raza Askari. Email: dr_razaaskari@hotmail.com

participate in sports. One of the major disadvantages of the procedure is the unusual appearance of the limb.

In the present study, we present our early clinical experience with the Van Nes rotationplasty procedure.

Patients and Methods

Van Nes Rotationplasty for locally advanced lower extremity tumours. A retrospective audit was conducted at Aga Khan University Hospital (AKUH), Karachi, and comprised cases of bone and soft tissue sarcoma that underwent Van Ness Rotationplasty over seven years from January 2005 to December 2011. Demographic data, family history, past history, comorbidities, date since diagnosis, duration of symptoms, type of tumour, metastasis, pre-op and post-op functional status, recurrence and survival were collected. The preoperative work-up included routine radiographs, bone and soft-tissue scintigraphy, magnetic resonance imaging (MRI) of the lesion and computed tomography (CT) scan of the chest.

The primary consideration in selection of the site of the femoral osteotomy was to allow for excision of at least 3cm of normal bone proximal to the most proximal extent of the tumour. Whenever possible, the secondary goal was that the level of the ankle (false knee) should be comparable with that of the normal knee at maturity. All patients received neo-adjuvant chemotherapy prior to surgery. All patients along with their relatives were counselled before the surgery regarding the various options available to them along with the advantages and disadvantages of each. All patients were shown photographs and functional videos of previous patients who had undergone the procedure. Rotationplasty surgery was performed only after the patients and their relatives were completely aware of the cosmetic consequences of the procedure and had given appropriate informed consent, including permission to use photographs for publication.

Intramedullary (IM) nail or 4.5mm Dynamic Compression Plate (DCP) was used in our cases to join femur with tibia depending upon skeletal maturity.

The operative technique was that of wide margin excision. The extent of bony resection was planned on MRI of the diseased region. The minimum margin of resection was 3cm from the maximum extent of the disease. The resection extent was planned so at skeletal maturity the heel of the rotated foot would come to the knee of the normal side. In a skeletally mature patient, this would be achieved at the time of surgery. In a skeletally immature patient, the operated limb would be kept longer. The skin

incision was rhomboid with the apex at the level of the proximal bone cut and the distal arms meeting at the level of distal cut. The two oblong arms of the skin incision met posteriorly both proximally and distally. The posterior cuts were then joined by a single vertical posterior incision.

First we identified the sciatic nerve and both its branches. Soft tissue was meticulously dissected out so that no spillage or breach of the tumour took place. If the vessel was not involved, it was also isolated and all surrounding tissue was dissected out and the bone was cut at the required level. Vascular reconstruction was done when required with synthetic grafts by the vascular surgeon. Femur was cut early as it allowed the distal portion to be rotated freely and give better and easy access to the dissection of vessels and nerves.

Once the resection was completed, hemostasis was achieved. The distal limb was then externally rotated and fixed to the femur with an IM nail or DCP. Cuts were made at right angles and excellent contact was made with the bone. The quadriceps muscles were sutured to the plantar flexors of the foot, and the hamstrings were sutured to the dorsiflexors. During closure, care was taken to adjust the excess girth of the thigh evenly around the leg to minimise wound-related complications.

Range-of-motion exercises to maximise dorsiflexion and plantar flexion of the ankle were started preoperatively and continued postoperatively. Ankle dorsiflexor and plantar flexor were strengthened.

Patients were kept in house for 5 to 6 days postoperatively. Drains were not used. On day 12 stitches were removed. When the wound got healed and bone ends were progressing well, the patients were fitted with external prosthesis and encouraged to walk usually at 6 weeks. The patients were followed up regularly in the outpatient department (OPD) for a period ranging from 6 months to 34 months (Figures 1-5).

Results

Of the 351 cases of bone and soft tissue sarcoma, 9(2.6%) underwent Van Ness Rotationplasty and were included in the study; 5(55.6%) females and 4(44.4%) males. Age ranged from 7 to 39 years with a mean of $15 \pm 2SD$ years. The mean duration of symptoms was 7 ± 3 SD months (range: 8-41 months). Eight (88.9%) were osteogenic sarcomas, and 1(11.1%) had squamous cell carcinoma of knee. Besides, 8(88.9%) involved distal femur. Overall, 7(77.8%) had localised Enneking stage IIB disease.

Two (22.2%) patients expired due to metastatic disease, but none had local recurrence. Complete excision of tumour was achieved in all (100%) patients. No local

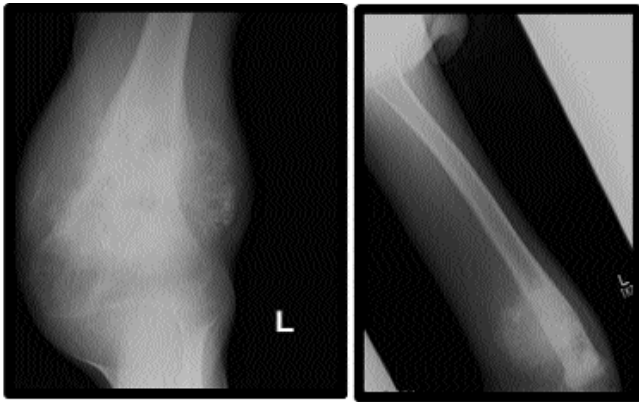

Figure-1: Pre-op X-rays of the patient showing lesion at distal femur.

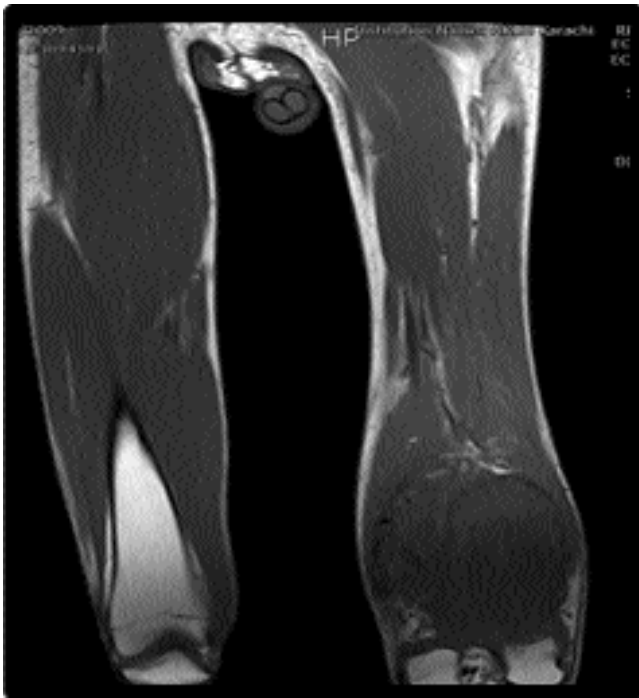


Figure-2: Pre-op magnetic resonance imaging (MRI) of the patient showing lesion at distal femur.

recurrences were noted and functional recovery was good. Two (22.2%) patients had simultaneous sciatic nerve repair as part of the primary procedure. Both of them had good motor function at the time of final follow-up. Only 1(11.1%) patient had attained full skeletal growth at the time of index surgery. All (100%) patients received neo-adjuvant chemotherapy. Mean Musculoskeletal Tumour Societyscore was $23.88 \pm 2SD$.

Two (22.2%) patients died of metastatic disease; 1(11.1%) about 12 months and 1(11.1%) about 18 months after the

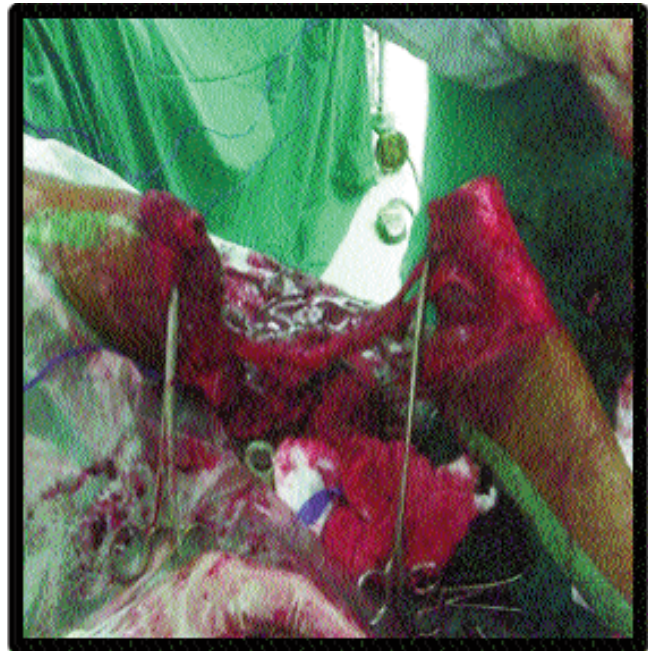

Figure-3: Intra-op picture of the patient after resection of the tumour.




Figure-4: Specimen X-rays of the resected tumour.

Table: Data on the patients who had rotationplasty.

Case	Gender, Age	Status at last follow-up
1	18 M	Died due to metastatic disease
2	39 M	Alive and well
3	7 F	Died due to metastatic disease
4	8 F	Alive and well
5	12 F	Alive and well
6	8 F	Alive and well
7	14 M	Alive and well
8	9 F	Alive and well
9	10 M	Alive and well

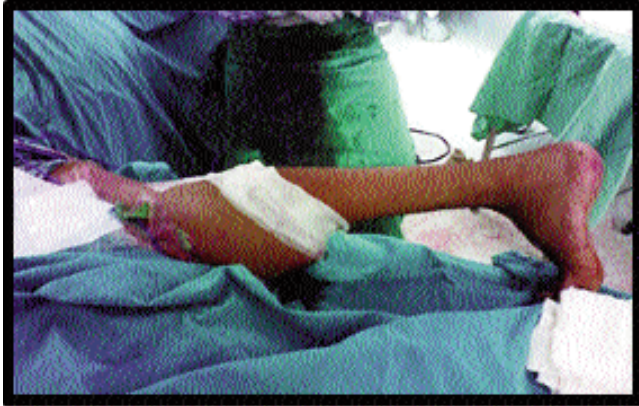


Figure-5: Post-op picture of the patient after surgery.

index surgery. None had local recurrence. One of the patients who expired had an MSTs score <20 while other had 21. The rest of the 7(77.8% patients walked by having a below-knee prosthesis and none had major complications or any delayed unions.

Discussion

Amputation, Van Nes Rotationplasty, endoprosthesis replacement and biological reconstruction are the operative choices for a skeletally immature patient with malignant sarcoma of the distal femur. The major advantages of rotationplasty are that the patient does not feel like an amputee because the foot is preserved, and the patient's function is comparable with that of a below-the-knee amputee. Furthermore, problems with the amputation stump, such as neuroma or phantom pain, which could jeopardise the use of a prosthesis, do not arise because weight is borne as it would be naturally, on the sole of the foot.¹⁰

The five-year disease-free survival rate after the Van Nes Rotationplasty in our patients was comparable with that for all patients who had osteogenic sarcoma of the distal end of the femur without metastases. An important feature of a successful procedure for ablation of a tumour is the absence of local recurrence. As noted, there were no recurrences in our series. The two patients who died had distant metastases.

Not all patients who have a tumour of the distal end of the femur are candidates for a limb-sparing procedure. In very young children, a substantial limb-length discrepancy may develop not only because one or both femoral physes are lost, but also because the unaffected limb grows faster than the affected limb. An expandable endoprosthesis, which can be lengthened at regular intervals to match the growth of the unaffected limb, may

be a solution, but the designs of expandable prostheses that are now commercially available are very costly and can be associated with mechanical failure.¹¹

The three main advantages of rotationplasty compared with above-the-knee amputation are that it provides a functioning joint at the level of the knee, the tissue of the foot tolerates the socket loads better than does a stump, and a smaller external prosthetic segment is needed. The two main advantages of rotationplasty compared with endoprosthesis replacement are that it allows continued growth of the modified segment of the limb and it is more durable. It is therefore important to know the functional outcomes associated with these operative alternatives. The relative energy cost for the patients who had a rotationplasty averaged 38 per cent of the maximum and for the above-the-knee amputees, it averaged 46 per cent. In general, an individual can sustain prolonged physical activity if the relative energy cost is less than 50 per cent of the maximum aerobic capacity.¹¹

Wilkins et al.¹² recommended amputation and rotationplasty should be preserved for patients who are not candidates for limb preservation or who are in an otherwise salvage situation. Functionally, however, rotationplasty is superior to an above-the-knee amputation¹³ and similar to megaprosthesis.¹⁴ Rotationplasty patients have good restoration of gait¹⁵ and have less pain and are able to participate in hobbies and sports more often than megaprosthesis patients.¹⁴

In a developing country like Pakistan, cost is the major decision-making factor in choosing the reconstructive option. Most of our patients had a poor socio-economic background. The procedure costs about Rs0.25 million, while a megaprosthesis costs about Rs1.5 million.

Though a Van Nes rotationplasty is cosmetically disfiguring, this is offset by good ambulatory function achieved provided its specific principles and indications are kept in mind (Annexure-1-2).¹⁶ Although it looks like an amputation, it is not perceived as one because the patient is weight-bearing on his sole. There is no phantom pain or neuroma. The patient retains active control of the knee unlike an above-the-knee amputee. It therefore functions like a below-the-knee amputation but with the advantage of weight-bearing on the normal sole.

None of our patients were identified to have any psychological problems. All our patients had detailed counselling sessions with their family members and were shown pictures and videos and, when possible, meetings were arranged with the patients and their family members who had undergone this operation. In normal attire of our

Annexure-1¹⁶: Specific principles for the Van Nes Rotationplasty procedure.

The foot and ankle MUST be disease-free
 The nerve supply to the foot and ankle MUST be preservable
 The vascular supply to the foot and ankle MUST be either preservable or restorable after resection of the diseased vessel segment
 Muscle power MUST be restorable in the ankle following surgery
 Large tissue segment resections are achievable

Annexure-2¹⁶: Indications for the Van Nes Rotationplasty procedure.

Lesions of the distal or proximal thirds of the femur and proximal tibia
 Expected remaining growth in contralateral leg >10cm in young children
 Extent of tumour size resection that may leave poor bone or soft tissue stock for reconstruction
 Distal vascular supply compromised secondary to tumour (reconstructable by segmental resection and anastomosis)
 Physical function and activity of major importance to child/adolescent and outweighs importance of cosmetic appearance
 Previous failed reconstructive attempts
 Late complications (leg length discrepancy/inadequate bone stock/failure of endoprosthesis)

country, lower limbs are fully covered and when prosthesis is applied it is fully disguised. Squatting is necessary in our lifestyle while eating, cooking, sitting or using toilets, and patients with rotationplasty were good at it.

Conclusion

All our patients who underwent rotationplasty had excellent function and were happy with the outcome and are now leading a near-normal life.

Acknowledgements

We are grateful to Dr Kashif Abbas, Dr Aurengzeb Qureshi and Dr Naveed Baloch for their assistance.

References

1. Kniegelenkersatz durch das in der Beinlängsachse um 180° gedrehte Fussgelenk. Arch. Orthop. Unfall-Chir. , 28: 175-178, 1930. (Not found)
2. CHAPCHAL G, VAN DE KERKHOVEW. Die Umdrehplastik des Sprunggelenkes bei der Behandlung des kongenitalen Femurdefektes. Archorthop Unfall-Chir 1941; 41: 109-15.
3. DEMELR, GOLD E. Erfolgreiche Anwendung der Umdrehplastik beim kongenitalen Femurdefekt mit Femurpseudarthrose. Wienerkin Wochenschr 1932; 45: 186.
4. KOSTUIKJP, GILLESPIE R, HALLJE, SHEILA H. Van Nes Rotational Osteotomy for Treatment of Proximal Femoral Focal Deficiency and Congenital Short Femur. J Bone Joint Surg 1975; 57-A: 1039-46.
5. KRISTEN H, KNAHRK, SALZER M. Die chirurgische Behandlung des kongenitalen Femurdefektes mittels Umdrehplastik. Zeitschr Orthop 1978; 116: 312-7.
6. KRITTER AE. Tibial Rotation-Plasty for Proximal Femoral Focal Deficiency. J Bone Joint Surg 1977; 59-A: 927-34.
7. VAN NES, C. P.: Rotation-Plasty for Congenital Defects of the Femur. Making Use of the Ankle of the Shortened Limb to Control the Knee Joint of a Prosthesis. J Bone Joint Surg. 1950; 32-B(1): 12-6.
8. RAINER K, MARTIN S. Rotation-Plasty for Childhood Osteosarcoma of the Distal Part of the Femur. J. Bone Joint Surg 1982; 64-A: 959-69.
9. SALZERM, KNAHRK. Resection of Malignant Bone Tumors. In: Grundmann E eds. Recent Results in Cancer Research. New York: Springer, 1976; pp 239-56.
10. Cammisa FP Jr, Glasser DB, Otis JC, Kroll MA, Lane JM, Healey JH. The Van Nestibial rotationplasty. A functionally viable reconstructive procedure in children who have a tumor of the distal end of the femur. J Bone Joint Surg 1990; 72-A: 1541-7.
11. Gottsauner-Wolf F, Kotz R, Knahr K, Kristen H, Ritschl P, Salzer M, et al. Rotationplasty for limb salvage in the treatment of malignant tumors at the knee. Am J Bone Joint Surg 1991; 73A: 1365-5.
12. Wilkins RM, Camozzi AB, Getilis SB. Reconstruction options for pediatric bone tumors about the knee. J Knee Surg. 2005; 18: 305-9.
13. Fuchs B, Kotajavari BR, Kaufman KR, Sim FH. Functional outcome of patients with rotationplasty about the knee. Clin Orthop Relat Res. 2003; (415): 52-8.
14. Hillmann A, Hoffmann C, Gosheger G, Karakau H, Winkelmann W. Malignant tumor of the distal part of the femur or the proximal part of the tibia : endoprosthesis replacement or rotationplasty: functional outcomes and quality of life measurements. J Bone Joint Surg Am 1999; 81 : 462 - 8.
15. Hillmann A, Rosenbaum D, Schroter J, Gosheger G, Hoffmann C, Winkelmann W. Electromyographic and gait analysis of 43 patients after rotationplasty. J Bone joint Surg Am 2000; 82: 187-96.
16. Bhamra JS, Abdul-Jabar HB, McKenna D, Ng Man Sun S, Gillott E, Pollock R. Van Nes rotationplasty as a treatment method for Ewing's sarcoma in a 14-month-old. Int J Surg Case Rep. 2013; 4: 893-7.