



THE AGA KHAN UNIVERSITY

eCommons@AKU

Department of Surgery

Department of Surgery

August 2012

Healing of cornea following an electric burn

Tanveer Anjum Chaudhry

Aga Khan University, tanveer.chaudhry@aku.edu

Farheen Shaikh

Aga Khan University, farheen.sheikh@aku.edu

Khabir Ahmad

Aga Khan University, khabir.ahmad@aku.edu

Follow this and additional works at: http://ecommons.aku.edu/pakistan_fhs_mc_surg_surg

 Part of the [Ophthalmology Commons](#), and the [Surgery Commons](#)

Recommended Citation

Chaudhry, T., Shaikh, F., Ahmad, K. (2012). Healing of cornea following an electric burn. *JCPSP: J Coll Physicians Surg Pak.*, 22(8), 533-535.

Available at: http://ecommons.aku.edu/pakistan_fhs_mc_surg_surg/178

See discussions, stats, and author profiles for this publication at: <https://www.researchgate.net/publication/230622425>

Healing of cornea following an electric burn

Article · August 2012

Source: PubMed

CITATIONS

0

READS

183

3 authors, including:



Tanveer Chaudhry

Aga Khan University, Pakistan

19 PUBLICATIONS 43 CITATIONS

SEE PROFILE



Khabir Ahmad

Aga Khan University, Pakistan

329 PUBLICATIONS 1,069 CITATIONS

SEE PROFILE

All content following this page was uploaded by [Khabir Ahmad](#) on 29 March 2014.

The user has requested enhancement of the downloaded file. All in-text references [underlined in blue](#) are added to the original document and are linked to publications on ResearchGate, letting you access and read them immediately.

Healing of Cornea Following an Electric Burn

Tanveer Anjum Chaudhry, Farheen Shaikh and Khabir Ahmad

ABSTRACT

Electrical injuries have become a significant health problem in developing countries because of increase in access to electricity in the last few decades and lack of adequate safety measures. Electrical injuries of eyes are relatively uncommon. A case report of a rapid and complete corneal healing accompanied by satisfactory visual recovery after an electric burn event in a 20-year-old male is reported. The patient had accidental exposure to high voltage live wire while he was repairing it, resulting in severe ocular and superficial body burn. He was not wearing any protective equipment at the time of injury. On examination, the best-corrected visual acuity was counting fingers in the left eye with severe corneal epithelial loss and diffuse corneal oedema. The patient was treated medically, with a rapid corneal healing and resolution of oedema over the next few days. Visual acuity in the worse eye (left) improved to 20/25 from counting fingers.

Key words: *Electric burn. Cornea. Healing. Ocular burn.*

INTRODUCTION

Electrical injuries have emerged as a significant health problem in developing countries because of increase in electrification of rural areas in the last few decades and lack of adequate safety measures.¹ Electrical eye or orbital injuries are not common events. However, they have a broad spectrum, ranging from minimal injury of the lid to complete retinal detachment and total blindness.²⁻⁶

Boozalis and colleagues reviewed 159 cases of electric burns to determine the ocular sequelae of such injuries.⁷ Only 5 (3.1%) of them had eye manifestation (number) including recurrent iritis, cataract, macular holes and central retinal artery occlusion.⁷ Of those who had electric-burn associated cataracts, 3 had anterior sub-capsular opacification while one had a dense white opacified lens. Ocular changes such as macular cysts, optic nerve damage and retinal changes⁸⁻¹⁰ have also been reported. Careful follow-up is recommended because many such cases develop delayed ocular changes.

A case report of an electric eye burn event in a 20-year-old male is reported below. Rapid and complete healing of the affected cornea was observed with satisfactory visual recovery because of timely presentation and management.

CASE REPORT

A 20-year-old male presented to the Emergency Department of the Aga Khan University Hospital,

Department of Surgery, Section of Ophthalmology, The Aga Khan University Hospital, Karachi.

Correspondence: *Dr. Tanveer Anjum Chaudhry, 134/11, P-Street, DHA, Phase VII, Karachi.*

E-mail: tanveer.chaudhry@aku.edu

Received November 10, 2011; accepted February 24, 2012.

Karachi, in mid-afternoon with a history of electric burn received at a local Jamat Khana (religious centre for the Ismaili community) an hour and a half before presentation. He was transported on a stretcher by his elder brother who confirmed history of electric shock induced by high voltage wire while repairing a cable fault unprotected. He did not have any previous significant medical or ocular history.

On presentation, the patient was conscious and well-oriented and vitally stable with a heart rate of 91 per minute and respiratory rate of 22 per minute. He was hydrated with normal saline and given a good pain control. Baseline investigations included electrocardiogram (ECG), complete blood count, serum electrolytes and random blood glucose. The patient had ocular complaints of intense burning and blurring of vision, predominantly on the left side. These were associated with watering and pain in both eyes. Systemic injuries included first degree superficial skin burns over the left half of the face, scalp and dorsum of the left hand.

An initial eye examination was carried out in the emergency department. He had a poor visual acuity of counting fingers in the left eye and a good visual acuity of 20/25 in his right eye. He had difficulty in opening his left eye due to burnt lashes matted together and charred skin in the peri-orbital region. Extra-ocular movements were normal and the pupils were regular and reacting to light. After gentle irrigation with normal saline, a thorough slit-lamp examination was performed. His left eye had a deeply-congested conjunctiva and a diffuse corneal epithelial burn with areas of epithelial loss. The right eye was less affected with marked conjunctival congestion and multiple corneal punctate epithelial staining. The anterior chamber was deep and the lens appeared clear in the right eye, while anterior chamber reaction in the left eye could not be assessed due to

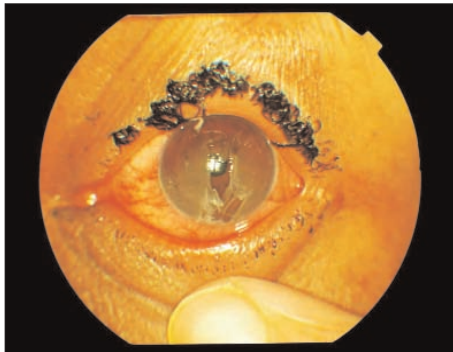


Figure 1: Corneal damage with charred and lost eyelashes in the left eye at presentation.

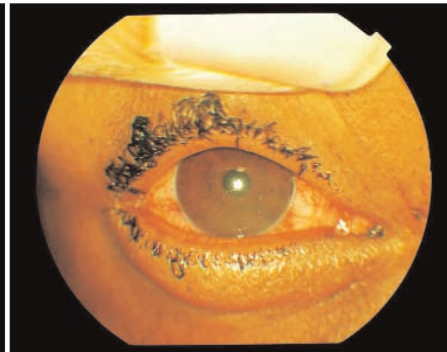


Figure 2: Corneal haze with charred and lost eyelashes in the right eye at presentation.

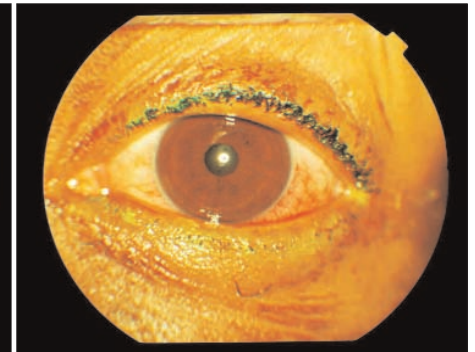


Figure 3: Completely healed left cornea following treatment.

marked corneal haze. Posterior segment examination was also not possible in this eye.

After anaesthetizing both eyes with lignocaine 0.5% eye drops, the superficial epithelial layer of patient's left eye was debrided using cotton wool buds. Topical antibiotic and dilating eye drops (1%) were instilled and the eye was padded for the next 48 hours. For the right eye, antibiotic 0.5% eye drops, mydriatic eye drops 1% and prednisolone 1% eye drops were prescribed. Plastic surgery and dermatology consults were generated who advised emollients and topical anti-bacterial skin cream. The patient was kept under observation for 24 hours and discharged in a stable condition on oral analgesics.

On the third day of injury, the left eye pad was removed and the patient was re-examined. There was a remarkable improvement in visual acuity from counting fingers at presentation to 20/25 in his severely affected left eye. Slit-lamp examination showed mild conjunctival congestion and a clear cornea with a small linear stain-positive epithelial defect in the lower half of cornea. Rest of the anterior segment examination was normal. By contrast, the right eye showed few superficial punctate erosions only. The intraocular pressure was normal. The posterior segment of both the eyes was assessed the same day and was found to be normal. The patient was advised to continue topical treatment for a week, which was gradually tapered off. Ten days after the injury, the patient had a good visual acuity of 20/20 in the right eye and 20/25 (best-corrected) in the left one. The cornea on both sides was found to be clear.

DISCUSSION

Electricity can be a serious health and environmental hazard, especially in developing countries where protective measures are almost non-existent.¹ These hazards include contact injuries, electric shocks, electrocutions, burns, fires, explosions and falls. We reported an electric eye injury involving a young adult who not only survived a high voltage trauma but also had a rapid and complete recovery from corneal burns. There are many factors that determine the severity of

the electric damage and its outcome. These include the type of current, the duration of exposure, the type of tissue surface contact, the extent of multisystem involvement, the duration between exposure and presentation and the extent of adherence to treatment. Electric eye injuries are uncommon events and this reported case had a rapid and complete healing of the cornea because of early referral, timely management and good treatment compliance.

There is a wide spectrum of ocular injuries associated with exposure to electricity.^{3,4,6} These include corneal burns, intraocular bleeding, thrombosis, cataract, glaucoma, retinal detachments. Severe lid burns from electrical exposure can also lead to various other complications such as loss of eye lashes and misdirected lashes (as was the case in our patient; Figure 1-3), and lid malpositioning. Thus ophthalmologists should not only focus on the presenting injuries, but also be aware of the long-term ocular complications.

It is important to note that electrical eye injuries are largely preventable by taking simple and time-tested protective measures such as the use of rubber insulating gloves and shoes, and industrial protective helmets. The victim was not a trained electrician with little knowledge of the potential electric hazards. He was working unprotected with no helmet, bare hands and feet. Targetted public awareness programmes can not only save many eyes from going blind but can also save many lives. This case report highlights the importance of seeking immediate medical attention, early intervention and targetted awareness programmes on electricity-related ocular and non-ocular hazards.

REFERENCES

1. Mashreky SR, Rahman A, Svanstrom L, Khan TF, Rahman F. Burn mortality in Bangladesh: findings of national health and injury survey. *Injury* 2011; **42**:507-10.
2. Luz DP, Millan LS, Alessi MS, Uguetto WF, Paggiaro A, Gomez DS, et al. Electrical burns: a retrospective analysis across a 5-year period. *Burns* 2009; **35**:1015-9.
3. Lakosha H, Tremblay F, De Becker I. High-voltage electrical trauma to the eye. *Can J Ophthalmol* 2009; **44**:605-6.

4. [Hashemi H, Jabbarvand M, Mohammadpour M. Bilateral electric cataracts: clinicopathologic report. *J Cataract Refract Surg* 2008; **34**: 1409-12.](#)
5. [Grewal DS, Jain R, Brar GS, Grewal SP. Unilateral electric cataract: Scheimpflug imaging and review of the literature. *J Cataract Refract Surg* 2007; **33**:1116-9.](#)
6. [Khan MR, El Faki H. Acute cataract and optic atrophy after high-voltage electrical injury. *Eur J Plast Surg* 2008; **31**:73-4.](#)
7. [Boozalis GT, Purdue GF, Hunt JL, McCulley JP. Ocular changes from electrical burn injuries. A literature review and report of cases. *J Burn Care Rehabil* 1991; **12**:458-62.](#)
8. [Sony P, Venkatesh P, Tewari HK, Garg SP. Bilateral macular cysts following electric burn. *Clin Experiment Ophthalmol* 2005; **33**: 78-80.](#)
9. [Bienfang DC, Zakov ZN, Albert DM. Severe electrical burn of the eye. *Albrecht Von Graefes Arch Klin Exp Ophthalmol* 1980; **214**:147-53.](#)
10. [Al Rabbiah SM, Archer DB, Millar R, Collins AD, Shepherd WF. Electrical injury of the eye. *Int Ophthalmol* 1987; **11**:31-40.](#)

.....☆.....