



THE AGA KHAN UNIVERSITY

eCommons@AKU

---

Department of Surgery

Department of Surgery

---

July 2013

# Abdominal tuberculosis with massive jejunal haemorrhage

Abdul Rehman Alvi

*Aga Khan University*, [rehman.alvi@aku.edu](mailto:rehman.alvi@aku.edu)

Tanveer UI Haq

*Aga Khan University*

Amyr Pardhan

*Aga Khan University*

Follow this and additional works at: [http://ecommons.aku.edu/pakistan\\_fhs\\_mc\\_surg\\_surg](http://ecommons.aku.edu/pakistan_fhs_mc_surg_surg)



Part of the [Radiology Commons](#), and the [Surgery Commons](#)

---

## Recommended Citation

Alvi, A., Haq, T., Pardhan, A. (2013). Abdominal tuberculosis with massive jejunal haemorrhage. *JCPSP: J Coll Physicians Surg Pak.*, 23(7), 509-511.

**Available at:** [http://ecommons.aku.edu/pakistan\\_fhs\\_mc\\_surg\\_surg/177](http://ecommons.aku.edu/pakistan_fhs_mc_surg_surg/177)

# Abdominal Tuberculosis with Massive Jejunal Haemorrhage

Abdul Rehman Alvi<sup>1</sup>, Tanveer Ul Haq<sup>2</sup> and Aryn Pardhan<sup>1</sup>

## ABSTRACT

Jejunum is a rare site of involvement in intestinal tuberculosis (TB) and massive lower gastrointestinal haemorrhage is an even rarer condition. The authors report a 15-year-old female student, who presented with fever, anaemia, hypoalbuminemia and developed massive lower gastrointestinal haemorrhage during hospital stay. The diagnosis of abdominal TB was established on tissue biopsy; tissue culture was positive for *Mycobacterium TB*. Optimal outcome was achieved with aggressive resuscitation, repeated mesenteric angio-embolization and anti-tuberculosis chemotherapy.

**Key Words:** Abdominal tuberculosis. Massive lower gastrointestinal haemorrhage. Intestinal tuberculosis.

## INTRODUCTION

Tuberculosis (TB) is a global communicable disease and majority of cases occur in overpopulated impoverished third world countries of South Asia, Sub-Saharan Africa and South America. In Pakistan, 1.5 million suffer from TB and more than 210000 new cases occur each year.<sup>1,2</sup> Over the last decade, 878 cases of abdominal TB has been reported in 15 retrospective reviews from Pakistan published in national periodicals. Most of the patients (60 – 70%) were young female and most of them (> 80%) were treated for an acute abdominal condition such as intestinal obstruction and perforation with reported mortality rate of 15 – 20%. There is no reported case of massive lower gastrointestinal bleeding from this part of the world. TB can involve any part of the gastrointestinal tract and accounts for 10 – 15% of all cases of extra pulmonary. In 75% of the case, it involves the ileocecal junction. Evidence of abdominal TB has been reported in 3.72% of 11,746 autopsies from India,<sup>3</sup> where 3 – 20% of small bowel obstruction and 5 – 9% of perforations are due to tuberculosis.

We report a unique presentation of abdominal tuberculosis with massive bleeding from jejunum and optimal result was achieved by repeated mesenteric angio-embolization.

## CASE REPORT

A 15-year-old female high school student was brought to the emergency room (ER) in August, 2009 with high-grade fever of 10 days duration, vomiting and generalized body swelling for past 3 days. She denied any gastrointestinal symptoms including anorexia,

diarrhea, abdominal pain, distention, malena and bleeding per rectum. She was in her usual state of health before these symptoms and was admitted to an orphanage boarding house 1 month back. She had been evaluated for chronic cough in March 2009, when her chest X-ray was reported normal and 3 samples of sputum were negative for AFB. Treatment with oral antibiotic relieved her cough. The family history was positive for pulmonary tuberculosis; her mother had received 6 months of anti-tuberculosis treatment in 2005, and her father had died of ischaemic heart disease.

On admission to the ER, the patient was looking extremely pale and dehydrated with periorbital and bilateral pedal oedema. She had a fever of 39°C, pulse rate of 120/minute, respiratory rate of 20/minute and her blood pressure was 100/70 mmHg. Her abdominal and other systemic examination was noted to be unremarkable. The laboratory data indicated anaemia, inflammatory status and malnutrition, with a white blood cell count of 13000/ $\mu$ l, haemoglobin of 5.6 g/dl and serum albumin of 1.2 g/dl. Her serum electrolytes, renal function, liver and coagulation profiles were within normal limits. The chest X-ray was reported normal with no evidence of chronic or acute infiltrations.

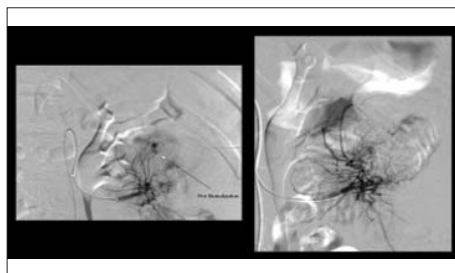
She received 3 units of pack cells in the ER, was started on broad-spectrum intravenous antibiotic therapy and admitted in medicine service for further evaluation. On the second hospital day, the patient developed 4 episodes of bleeding fresh blood per rectum and her haemoglobin dropped to 6.0 g/dl. She was transfused with packed cells and fresh frozen plasma. Nasogastric aspiration did not reveal any evidence of upper gastrointestinal haemorrhage. RBC tagged technetium scan (TC<sup>99m</sup>) was positive in the upper part of jejunum. Subsequent mesenteric angiography on the next day was negative because of arterial spasm and the catheter sheath was kept in place for 24 hours. She was shifted to the surgical service and mesenteric angiography was repeated (Figure 1) in the next 18 hours. Successful

Department of Surgery<sup>1</sup> / Radiology<sup>2</sup>, The Aga Khan University Hospital, Karachi.

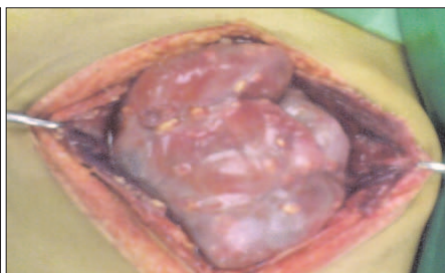
Correspondence: Dr. Abdul Rehman Alvi, Department of Surgery, The Aga Khan University Hospital, Stadium Road, P.O. Box 3500, Karachi-74800.

E-mail: rehman.alvi@aku.edu

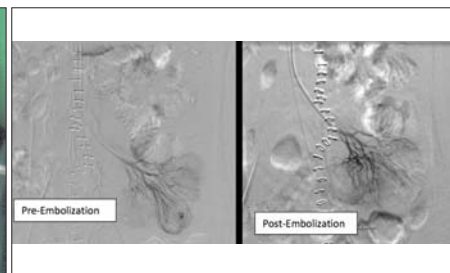
Received: November 11, 2009; Accepted: August 31, 2012.



**Figure 1:** Mesenteric angiography with pre- and post-intra-arterial micro-coil embolization of bleeding proximal jejunal artery.



**Figure 2:** Laparotomy finding; peritoneum is thick, inflamed, studded with yellowish white tubercles and dense adhesion of bowel loops.



**Figure 3:** Mesenteric angiography with pre- and post-intra-arterial micro-coil embolization of bleeding distal jejunal artery.

embolization of upper jejunal artery was achieved, and patient remained stable over the next 28 hours. On the 4<sup>th</sup> day of hospital admission, she developed massive lower gastrointestinal haemorrhage, with hypotension and her haemoglobin dropped to 4 g/dl. She was shifted to operation room after resuscitation at midnight. A mid line exploratory laparotomy revealed moderate ascites; the visceral and parietal peritoneum was inflamed riddled with yellowish white nodules and the bowel loops were densely adherent (Figure 2). Exploration and inspection of bowel for the site of bleeding was not feasible, because of dense adhesions. Multiple peritoneal and omental biopsies were taken and frozen section was reported to be benign with strong possibility of tuberculosis.

Patient was started on intravenous anti-tuberculous drugs (Isoniazid, Rifampicin, Ciprofloxacin and Streptomycin), enteral feeding and serial monitoring of haemoglobin. Again, she had massive lower gastrointestinal bleeding on 5<sup>th</sup> postoperative day, with hypotension and her haemoglobin again dropped to 4.0 g/dl. Patient underwent a third mesenteric angiography; this time bleeding point was found in lower part of jejunum (Figure 3) and successful remobilization was achieved. Patient was continued on anti-tubercle treatment and enteral feeding. She received 28 units of blood product during the course of hospital stay.

The final histopathology report showed chronic infection with caseation necrosis, suggestive of tuberculosis. The tissue culture was reported to be positive for *Mycobacterium TB*. Patient was discharged on the 15<sup>th</sup> day of hospital admission and was continued on four-drugs (Isoniazid, Rifampicin, Ethambutol and Pyrazinamide) orally. She was found to be recovering well in the third week of follow-up, with weight gain of two kilogram and repeat haemoglobin of 10.5 g/dl. Patient was advised to complete 12 months of anti-tubercle chemotherapy and continue follow-up in infectious disease clinic.

## DISCUSSION

Tuberculous enteritis accounts for a minority of massive gastrointestinal haemorrhage. Anand *et al.* reported 91 patients with massive lower gastrointestinal haemorrhage

over a period of 11 years. Ileocecal TB was found to be the second most cause of bleeding and the diagnosis was established on either colonoscopy or exploratory laparotomy with intra-operative endoscopy. No case of jejunal TB was reported in this series and no patient underwent mesenteric angiography and this could be due to lack of facility during the study period (1988 – 1999).<sup>4</sup> A review of the English literature lists 10 case reports of massive lower gastrointestinal haemorrhage because of tuberculosis.<sup>4-6</sup> Most of the reported case were due to ileocecal and colonic TB. One case of mesenteric pseudoaneurysm and abdominal TB managed successfully by transarterial micro-coil embolization.<sup>6</sup>

Abdominal tuberculosis can have varied presentation, frequently mimicking abdominal malignancy and other rare disease. Therefore, the clinician must think of TB with history of exposure and tissue diagnosis must be done to establish diagnosis or exclude this curable disease. Ulceration and erosions can occur in areas from stomach to rectum resulting in bleeding. The diagnosis can be established by endoscopic biopsy but getting tissue biopsy from jejunal lesions is a tedious job.<sup>8</sup> Wireless capsule endoscopy and multi-detector-row CT enterolysis are the two recently developed minimally invasive techniques that may provide a complete small bowel examination of both mucosa and mural pathology.<sup>9</sup> Laparoscopy has been advocated as the ideal method in achieving definite diagnosis in patients with suspected TB. The accuracy has been reported to be 85 – 90% and frozen section should be routinely done for adequacy of tissue biopsy.<sup>8,10</sup>

Mesenteric angiography is a commonly used diagnostic and therapeutic technique for gastrointestinal haemorrhage. Selective angiography requires a bleeding rate of 0.5 ml/min for diagnosis with the reported accuracy rate of 50 – 75%.<sup>9</sup> In this case report mesenteric angiography was negative at the 1<sup>st</sup> episode of bleeding and the subsequent 2<sup>nd</sup> and 3<sup>rd</sup> angiography were both diagnostic and therapeutic with intra-arterial micro-coil embolization.

To the authors' knowledge, this is the first report of massive jejunal haemorrhage in a patient with abdominal tuberculosis. The diagnosis was established

on histopathology and positive *Mycobacterium TB* on tissue culture. Patient required 28 units of blood product during hospital stay and developed massive bleeding on two occasions from different part of jejunum. Optimal outcome was achieved with repeated mesenteric intra-arterial micro-coil embolization, intravenous anti-tubercle chemotherapy and early enteral feeding.

### REFERENCES

1. Alvi AR, Hussain SF, Shah MA, Khalida M, Shamsudin M. Prevalence of pulmonary tuberculosis on the roof of the world. *Int J Tuberc Lung Dis* 1998; **2**:909-13.
2. Alvi AR, Masooma Z. A unique variant of intestinal tuberculosis. *J Coll Physicians Surg Pak* 2008; **18**:657-9.
3. Sharma MP, Bhatia V. Abdominal tuberculosis: review article. *Indian J Med Res* 2004; **120**:305-15.
4. Anand AC, Patnaik PK, Bhalla VP, Chaudhary R, Saha A, Rana VS.M. Massive lower intestinal bleeding: a decade of experience. *Trop Gastroenterol* 2001; **22**:131-4.
5. Eboda MA, Akande B. Massive lower gastrointestinal haemorrhage from abdominal tuberculosis. *Trop Geogr Med* 1991; **43**:307-9.
6. Corby R, Cranford C, Van Ha T, Yousefzadeh D. Mesenteric pseudoaneurysm in 12-year-old girl with abdominal tuberculosis with massive lower gastrointestinal bleeding. *Pediatric Radiol* 2006; **36**:456-9.
7. Johnston C, Tuie D, Usard RP, Ranold J, McEniff N, Ryan JM. Use of angiography to localize site in recurrent gastrointestinal bleeding. *Cardiovasc Intervent Radiol* 2007; **30**:1042-6.
8. Tan K, Chen K, Sim R. The spectrum of abdominal tuberculosis in a developed country: a single institution's experience over 7 years. *J Gastrointest Surg* 2009; **3**:142-7.
9. Filippone A, Cianci R, Milano A, Di Mizio SV, Storto ML. Obscure gastrointestinal bleeding and small bowel pathology: comparison between wireless capsule endoscopy and multi-detector row CT enteroclysis. *Abdominal Imaging* 2008; **33**:398-406.
10. Prasad K, Vayoth O, Dhar S, Surendar P, Ponnambathayil S. Laparoscopy in suspected abdominal tuberculosis is useful as an early diagnostic method. *ANZ J Surg* 2008; **78**:987-9.

