



THE AGA KHAN UNIVERSITY

eCommons@AKU

Section of Cardiothoracic Surgery

Department of Surgery

October 2016

Delayed presentation of forgotten thyroid goiter - 25 years after thyroidectomy

Fazal Wahab Khan
Aga Khan University

Ayesha Muhammad
Yale University, USA

Mohsin Abbas
Ziauddin University Hospital, Pakistan

Syed Usman Bin Mahmood
Aga Khan University

Benish Fatima
Liaquat National Hospital, Pakistan

See next page for additional authors

Follow this and additional works at: http://ecommons.aku.edu/pakistan_fhs_mc_surg_cardiothoracic

 Part of the [Cardiology Commons](#), and the [Surgery Commons](#)

Recommended Citation

Khan, F. W., Muhammad, A., Abbas, M., Mahmood, S., Fatima, B., Fatimi, S. (2016). Delayed presentation of forgotten thyroid goiter - 25 years after thyroidectomy. *JCPSP: Journal of the College of Physicians and Surgeons Pakistan*, 26(10), 858-860.
Available at: http://ecommons.aku.edu/pakistan_fhs_mc_surg_cardiothoracic/49

Authors

Fazal Wahab Khan, Ayesha Muhammad, Mohsin Abbas, Syed Usman Bin Mahmood, Benish Fatima, and Saulat H. Fatimi

Delayed Presentation of Forgotten Thyroid Goiter – 25 Years After Thyroidectomy

Fazal Wahab Khan¹, Ayesha Muhammad², Mohsin Abbas³, Syed Usman Bin Mahmood⁴, Benish Fatima⁵ and Saulat H. Fatimi¹

ABSTRACT

Forgotten goiter is a rare occurrence (2 - 16% of retrosternal thyroid cases) that depicts recurrence of retrosternal thyroid mass due to growth of remnant thyroid tissue overlooked during an initial thyroidectomy. The patient is a 59-year female who presented with dyspnea and stridor 25 years after total thyroidectomy. She was diagnosed as having a mediastinal mass on radiographic imaging. There were only localized pressure symptoms due to mass effect. The mass was excised employing an extra-cervical approach and using a partial sternotomy. The profuse extension of thyroid tissue, adherent to vital structures in the thorax and the extra-cervical thyroidectomy was a novel experience. The mass was completely excised and the patient's symptoms alleviated after the surgery. The patient recovered without any complications and there was no recurrence at 1 year of follow-up.

Key Words: Mediastinal mass. Thyroidectomy. Thoracic surgery.

INTRODUCTION

Forgotten thyroid is a rare phenomenon which presents in post-thyroidectomy patients. This finding constitutes approximately 9% of the patients with an isolated substernal (retrosternal) thyroid presentation. Various authors have different inclusion criteria for this condition, therefore, the prevalence of a retrosternal thyroid fluctuates from 2 - 30% in literature.¹ Embryologic thyroid gland appears as an epithelial proliferation in the floor of the pharynx and descends in front of the pharyngeal gut as a bilobed diverticulum; therefore, aberrant thyroid tissue is usually found in the midline along the path of descent. Sometimes, thyroid tissue migrating further down the trachea may give rise to retrosternal thyroid tissue. This retrosternal thyroid connects with the main thyroid gland via parenchymal or fibrous tissue through which thyroid arteries transverse to maintain blood supply. Recurrence of an isolated, retrosternal thyroid tissue mass years after a total thyroidectomy is mainly due to unsuccessful excision of the substernal (minor) thyroid tissue during primary surgery.

CASE REPORT

A 59-year female with no comorbidities presented to our clinic with dyspnea, mild stridor and dysphagia. She had a history of thyroidectomy for benign multinodular goiter 25 years ago. Two years prior to presentation, she started having shortness of breath, for which she was investigated and diagnosed with a mediastinal mass on chest radiograph. Subsequently, she underwent a CT scan with intravenous contrast which revealed a mediastinal mass involving the lower trachea (Figure 1). CT guided fine needle aspiration biopsy demonstrated benign thyroid cytology; therefore, excision of the mass through extra-cervical approach was planned.

Patient was anesthetized in the supine position. A partial median sternotomy was performed stretching from the suprasternal notch to the 2nd intercostal space just inferior to the angle of Louis, perpendicular to the sternum. A solid elongated mass could be felt after the sternotomy. The mass was in the vicinity of the innominate vein and the innominate artery inferiorly, lateral (left) to the trachea, anterior to the esophagus and passing superior to the thoracic inlet (on the left side). The thoracic inlet, being a confined space, had compressed the trachea causing it to shift towards the right side, leading to concomitant esophageal compression. The mass was mobilized circumferentially using blunt and sharp dissection, it was very vascular and the hemostasis was maintained by clipping off all the nearby vessels. The mass was then completely removed, preserving the vital structures nearby. Excised tissue was an elongated, well circumscribed mass measuring 11 cm in length and 4 cm in width, which was sent for histopathology and turned out to be well differentiated benign thyroid tissue.

The sternum was closed with steel wires and a redivac drain sized 16F was placed in the mediastinum. The

¹ Section of Cardiothoracic Surgery, The Aga Khan University Hospital, Karachi.

² Florez Lab, Massachusetts General Hospital, Yale University, USA.

³ Section of Cardiothoracic Surgery, Ziauddin University Hospital, Karachi.

⁴ Graduate, The Aga Khan University, Karachi.

⁵ Department of Biochemistry, Liaquat National Hospital, Karachi.

Correspondence: Dr. Fazal Wahab Khan, Chief Resident PGY-6, Section of Cardiothoracic Surgery, The Aga Khan University Hospital, Karachi.

E-mail: fazal.khan@aku.edu

Received: April 27, 2015; Accepted: March 04, 2016.

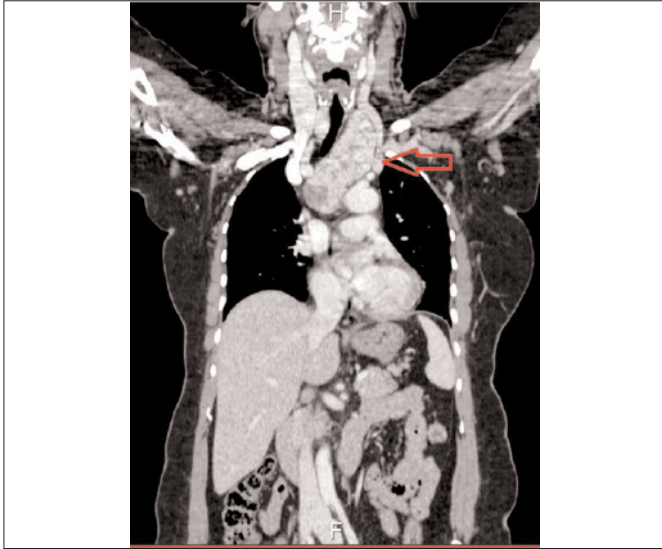


Figure 1: CT scan (chest) showing mediastinal mass and the deviation of trachea towards right side.

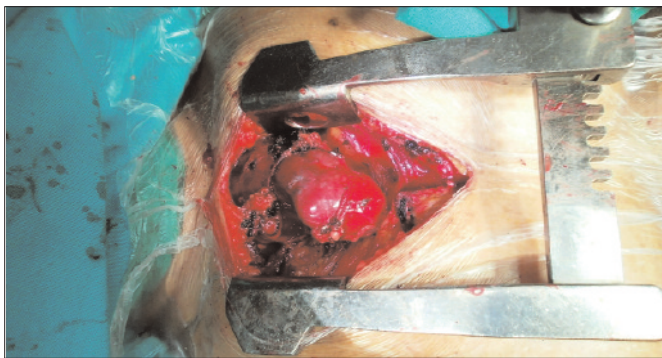

Figure 2: Intraoperative picture of the solid, elongated smooth surfaced mediastinal mass.

wound was closed in 2 layers. Patient was extubated within few hours of surgery and her postoperative recovery remained uneventful.

DISCUSSION

'Forgotten thyroid' refers literally to the presentation of a thyroid mass, which was overlooked during prior surgery to resect the thyroid.²⁻⁴ Usually, this type of thyroid goiter extends beyond its anatomical location, thereby making a complete resection difficult. Sometimes growth extends into the mediastinum, placing the thyroid tissue in close proximity of the great vessels and other vital organs.³ Usually, a cervical approach is adequate to resect these masses although an extra-cervical thyroidectomy (partial sternotomy or posterolateral thoracotomy) is indicated when there is a large retrosternal goiter, previous thyroidectomy, or high suspicion of malignancy. Trans-clavicular access can be used as an alternate route for excision of giant intra-thoracic goiter.²

Isolated retrosternal goiter can be a difficult diagnosis as only 20 - 40% patients are symptomatic. The same was experienced in this case as there were only pressure

symptoms present due to mass effect, but no other systemic effects.⁵ Sometimes, such masses might not be seen on chest radiographs³; however, chest CT scan nearly identifies all cases.⁶ MRI of the neck and mediastinum can further outline the involvement of the thoracic organs, thereby making the decision of surgical approach easier. Fine needle biopsy is usually not preferred in such cases due to the close proximity of nerves and vessels; however, due to the profuse growth, we had easy access to the tissue.

Standard of treatment for a 'forgotten thyroid goiter' is complete surgical excision.⁷ The route of exposure and excision is still controversial in surgical practice. There are several surgical techniques by which a cervical incision can be used to extract a substernal thyroid mass. These include using instrumental help, retraction using ties and excision.⁸⁻¹⁰ Extra cervical thyroidectomy is mostly done through a partial median sternotomy. The length of sternotomy is tailored according to the extent of growth caudally into the mediastinum.² Involvement of the trachea and vast local extension of the mass in this case justified the use of an extra-cervical approach (Figure 2). The extra-cervical approach helped us to visualize the superior mediastinum and ascertain that there were no other remnants of the gland present in the mediastinum.

Literature describes video-assisted thoracoscopy (VATS) being successfully used to perform extra-cervical thyroidectomy, although this may require some expertise.¹¹ This form of minimally invasive surgery can be the answer to future management of extensive 'forgotten thyroid goiters' inside the mediastinum, involving vital structures such as the respiratory tree.

In conclusion, it is imperative that patients who have undergone total thyroidectomy are followed with periodic imaging to rule out forgotten thyroid goiter (in cases which are suspected to be incomplete resections). If recurrence of a mass is seen on imaging, it should be carefully analyzed regarding its size and local involvement of other organs so that a timely decision regarding the approach of surgery can be made.

REFERENCES

1. Batori ME, Chatelou, Straniero A. Surgical treatment of retrosternal goiter. *Riv Eur Sci Med Farmacol* 2007; **11**:265.
2. Raffaelli M, De Crea C, Ronti S, Bellantone R, Lombardi CP. Substernal goiters: incidence, surgical approach, and complications in a tertiary care referral center. *Head Neck* 2011; **33**:1420-5.
3. Sahbaz A, Aksakal N, Ozcinar B. The forgotten goiter after total thyroidectomy. *Int J Surg Case Rep* 2013; **4**:269-71.
4. Calo PG, Tatti A, Medas F, Petruzzo P, Pisano G, Nicolosi A. Forgotten goiter. Our experience and a review of the literature. *Ann Ital Chir* 2012; **83**:487-90.
5. Newman E, Shaha AR. Substernal goiter. *J Surg Oncol Suppl* 1995; **60**:207-12.

6. Michel LA, Bradpiece HA. Surgical management of substernal goitre. *Br J Surg* 1988; **75**:565-9.
7. Erbil Y, Bozbora A, Barbaros U, Ozarmagan S, Azezli A, Molvalilar S. Surgical management of substernal goiters: clinical experience of 170 cases. *Surg Today* 2004; **34**: 732-6.
8. Pandya S, Sanders LE. Use of a Foley catheter in the removal of a substernal goiter. *Am J Surg* 1998; **175**:155-7.
9. Har-El G, Sundaram K. Powered instrumentation for transcervical removal of gigantic intrathoracic thyroid. *Head Neck* 2001; **23**:322-5.
10. Shemen L, Ko W. Current technique for resection of mediastinal goiter. *Ear Nose Throat J* 2006; **85**:609-11.
11. Gupta P, Lau KK, Rizvi I, Rathinam S, Waller DA. Video assisted thoracoscopic thyroidectomy for retrosternal goitre. *Ann R Coll Surg Engl* 2014; **96**:606-8.

