

**FHS PUBLIC ACCESS**

Author manuscript

Am J Med Genet A. Author manuscript; available in PMC 2016 November 28.

Published in final edited form as:

Am J Med Genet A. 2016 May ; 170A(5): 1288–1294. doi:10.1002/ajmg.a.37568.

Clinically Relevant Variants Identified in Thoracic Aortic Aneurysm Patients by Research Exome Sequencing

Jeffrey A. Schubert^{1,2}, Benjamin J. Landis², Amy R. Shikany³, Robert B. Hinton³, and Stephanie M. Ware^{1,2,*}¹Department of Molecular Genetics, Biochemistry and Microbiology, University of Cincinnati College of Medicine, Cincinnati, Ohio²Department of Pediatrics and Medical and Molecular Genetics, Indiana University School of Medicine, Indianapolis, Indiana³Division of Cardiology, Cincinnati Children's Hospital Medical Center, Cincinnati, Ohio

Abstract

Thoracic aortic aneurysm (TAA) is a genetically heterogeneous disease involving subclinical and progressive dilation of the thoracic aorta, which can lead to life-threatening complications such as dissection or rupture. Genetic testing is important for risk stratification and identification of at risk family members, and clinically available genetic testing panels have been expanding rapidly. However, when past testing results are normal, there is little evidence to guide decision-making about the indications and timing to pursue additional clinical genetic testing. Results from research based genetic testing can help inform this process. Here we present 10 TAA patients who have a family history of disease and who enrolled in research-based exome testing. Nine of these ten patients had previous clinical genetic testing that did not identify the cause of disease. We sought to determine the number of rare variants in 23 known TAA associated genes identified by research-based exome testing. In total, we found 10 rare variants in six patients. Likely pathogenic variants included a *TGFB2* variant in one patient and a *SMAD3* variant in another. These variants have been reported previously in individuals with similar phenotypes. Variants of uncertain significance of particular interest included novel variants in *MYLK* and *MFAP5*, which were identified in a third patient. In total, clinically reportable rare variants were found in 6/10 (60%) patients, with at least 2/10 (20%) patients having likely pathogenic variants identified. These data indicate that consideration of re-testing is important in TAA patients with previous negative or inconclusive results.

*Correspondence to: Stephanie M. Ware, M.D., Ph.D., Indiana University School of Medicine, 1044 West Walnut Street, Indianapolis, IN 46202. stware@iu.edu.

Jeffrey A. Schubert and Benjamin J. Landis contributed equally to this work.

Conflicts of interest: none.

SUPPORTING INFORMATION

Additional supporting information may be found in the online version of this article at the publisher's web-site.

Keywords

Marfan syndrome; Loeys-Dietz syndrome; next generation sequencing; clinical genetic testing; *TGFB2*; *SMAD3*; *MYLK*; *MFAP5*

INTRODUCTION

Thoracic aortic aneurysm (TAA) is an aortopathy in which dilation of the proximal aorta predisposes to life-threatening complications such as dissection yet is often asymptomatic until a patient suffers one of these acute events [Milewicz et al., 2008]. TAA can be classified broadly as syndromic or non-syndromic, the latter of which includes familial TAA (FTAA). Inherited connective tissue diseases such as Marfan syndrome (MFS), Loeys-Dietz syndrome (LDS), and vascular type Ehlers-Danlos syndrome (EDS) are strongly associated with highly penetrant TAA [Pomianowski and Elefteriades, 2013]. The genes associated with these syndromes include *FBN1* (MFS), *TGFBR1/2* (LDS), and *COL3A1* (EDS), and recent studies have implicated additional transforming-growth factor beta (TGF β) pathway genes such as *TGFB2* and *SMAD3* in disease pathogenesis [Van de Laar et al., 2011; Boileau et al., 2012]. Some genes are implicated in multiple disorders, for example, *TGFBR1/2* mutations are observed in both MFS and LDS [Gillis et al., 2013]. Approximately 20% of nonsyndromic TAA patients have FTAA [Albornoz et al., 2006; Jondeau and Boileau, 2014], which is associated with variants in a number of vascular smooth muscle genes including *ACTA2*, *MYLK*, and *MYH11*, but may also include genes associated with syndromic TAA such as *TGFBR1/2* [Renard et al., 2013a; Lerner-Ellis et al., 2014]. In spite of the considerable progress toward understanding the genetic basis of TAA, as much as 80% of disease etiologies remain unidentified [Jondeau and Boileau, 2012]. In addition to genetic heterogeneity, TAA is characterized by variable phenotypic features, both between unrelated individuals and within families, including age of onset, severity of dilation, and presence or absence of non-cardiovascular tissue involvement [Milewicz et al., 2014]. Many non-syndromic TAA cases may have subtle phenotypic features suggestive of connective tissue involvement [Landis et al., 2015]. Taken together, phenotypic heterogeneity and allelic overlap between syndromic and non-syndromic cases creates challenges with the approach to genetic testing. Because positive genetic testing for TAA has such important implications for disease management and screening of at risk family members, information to guide decisions about when to re-test as panels continue to expand is necessary.

Here we report a cohort of 10 patients with FTAA of unknown etiology, nine of whom had previous clinical genetic testing. We sought to determine how many patients with past clinical genetic testing for TAA would have rare variants in a more expanded list of known TAA genes using research-based exome sequencing. In total, variants that would be clinically reportable were identified in 6 of 10 patients, and two variants were considered likely pathogenic. Overall, our results demonstrate the importance of additional genetic testing for TAA and indicate that patients with previous negative or inconclusive results may benefit from re-testing using broader panels of TAA genes.

METHODS

Patients with TAA were prospectively enrolled through the Cardiovascular Genetics Clinic at Cincinnati Children's Hospital Medical Center (CCHMC). The local Institutional Review Board approved this study. TAA was diagnosed according to established guidelines [Hiratzka et al., 2010]. The 10 FTAA patients reported here all have a first-degree family member with TAA and were not known to have an established disease causing genotype. Previous clinical genetic testing had been performed in 9 of the 10 patients, including specific gene targeted tests or gene panels for MFS and related disorders or FTAA (Table I).

Using a standard extraction protocol, genomic DNA was isolated from whole blood samples provided by each subject. Genomic DNA (3 µg) was subsequently fragmented and enriched for the human exome, including coding regions and splice junctions, using the NimbleGen SeqCap EZ Human Exome v2.0 Library (2.1 million DNA probes). This capture targets approximately 30,000 coding genes (~300,000 exons), and contains probes that cover 44.1Mb in total. Post-enrichment, the exome libraries of each subject was sequenced with 100bp paired-end reads using the Illumina HiSeq 2500 machine in the CCHMC sequencing core. Sequenced reads were mapped to the reference genome GRCh37, and variants were called by the Biomedical Informatics Division at CCHMC.

Exome sequencing data was analyzed for the presence of rare variants (minor allele frequency <1% or not reported in Exome Aggregation Consortium [ExAC] database) in TAA associated genes [Exome Aggregation Consortium, 2015]. The following 23 genes were analyzed: *ACTA2*, *CBS*, *COL3A1*, *COL5A1*, *COL5A2*, *FBN1*, *FBLN4*, *FBN2*, *FLNA*, *MED12*, *MFAP5*, *MYH11*, *MYLK*, *NOTCH1*, *PRKG1*, *SKI*, *SLC2A10*, *SMAD3*, *SMAD4*, *TGFB2*, *TGFB3*, *TGFBR1*, and *TGFBR2*. Currently, each of these genes can be tested with clinically available TAA panels except *FBLN4* and *TGFB3*; these additional two genes were included for their known associations with TAA [Huchtagowder et al., 2006; Bertoli-Avella et al., 2015]. On average, the 10 patients reported here had 86% of the targeted exons in these 23 genes covered at a depth of at least 20×, with an average depth of 57×. The American College of Medical Genetics (ACMG) standards and guidelines for the interpretation of sequence variants were utilized to assess pathogenicity [Richards et al., 2015]. Bioinformatic programs (PROVEAN, SIFT, Polyphen-2, Condel, and SuSPect) were used to predict variant pathogenicity. We considered the bioinformatics results to support pathogenicity if a variant was assessed as damaging by at least three of five programs. Rare variants were queried in the Human Gene Mutation Database (HGMD) and ClinVar (<http://www.ncbi.nlm.nih.gov/clinvar/>). Variants designated as clinically reportable, defined as a variant considered to be pathogenic, likely pathogenic, or a variant of uncertain significance [VUS], were confirmed by Sanger sequencing.

CLINICAL REPORT AND RESULTS

Overall Genetic Findings

Among the 10 Caucasian patients, 10 rare variants were identified (Table I). Four patients did not have at least one rare variant within our list of TAA-associated genes. Three patients were found to have two or more rare variants in TAA-associated genes. Molecular

interpretation of the rare variants established that six patients had findings that would be reported on a clinical TAA panel (i.e., a variant considered to be pathogenic, likely pathogenic, or a VUS). Among these six patients, two had VUSs found on previous testing (Patients 1 and 5), three had previous negative testing (Patients 2, 7, and 10), and one patient had no previous genetic testing (Patient 3). None of these patients had family members with a history of positive genetic testing. Thus, the rate of discovering a clinically reportable variant with broad genetic testing in our small cohort of patients was 60% (6/10), including 20% (2/10) of patients who were found to have a likely pathogenic variant.

Phenotypic Findings

A summary of the phenotypes for the 10 patients can be found in Supplemental Table SI. The three patients with variants assessed as damaging by at least three of five bioinformatic programs are described in detail below.

Patient 1

Patient 1 is a 19-year-old male (Fig. 1A, proband III-3) with borderline TAA (aortic root 3.8 cm) and additional cardiovascular findings including arterial tortuosity, bilateral superior vena cava, and perimembranous ventricular septal defect. He has a number of signs associated with syndromic TAA including: scoliosis, chest asymmetry, joint hyperflexibility, downslanting palpebral fissures, retrognathia, malar hypoplasia, hyperextensible skin, and recurrent left inguinal hernia. Additionally, this patient has arthrogyrosis and camptodactyly. There is a positive family history of similar features; his father (Fig. 1A, II-6) exhibits TAA, secundum atrial septal defect, pes planus, pectus excavatum, and inguinal hernia, and is reported to be “double jointed.” Additionally, the proband’s older sister (Fig. 1A, III-2) has a history of atrial septal defect, malar hypoplasia, retrognathia, high and narrow palate, pectus excavatum, hyperflexibility, hip pain, pes planus, and enophthalmos, but no evidence of TAA. A second older sister (Fig. 1A, III-1) has had a normal echocardiogram but also reports hyperflexibility and joint pain.

Previous clinical sequencing of *FBN2* performed in this family identified a VUS (c.1040G>A; p.Arg347His; dbSNP rs112428886) that segregated in the proband, father and one sister (Fig. 1A, III-2). The proband’s father previously had negative sequencing of *TGFBR1* and *TGFBR2*, and his older sister (Fig. 1A, III-2) had previous negative *FBN1* sequencing. As expected, exome sequencing of the proband identified the known *FBN2* VUS but additionally revealed a *TGFB2* variant (c.979C>T; p.Arg327Trp). The *FBN2* VUS is not found in ClinVar or HGMD and is reported damaging by two bioinformatics prediction programs. The *TGFB2* variant, however, was predicted damaging by four of five programs, is found in HGMD, and has been reported in patients with TAA and features of connective tissue disease [Lindsay et al., 2012]. In addition, two other TAA patients in separate families have been reported with the same p.Arg327Trp variant, and another patient with TAA and Marfanoid features has been described with a different missense variant at this position (p.Arg327Gln) [Renard et al., 2013b]. This variant was confirmed with Sanger sequencing in the proband and his affected father (Fig. 1A, II-6), providing evidence of segregation with disease. Additionally, this variant was not found in the ExAC database.

Therefore, we conclude the p.Arg327Trp TGF β 2 is likely pathogenic in this family. DNA from additional informative family members was not available for sequencing.

Patient 2

Patient 2 is a 10-year-old male (Fig. 1B, proband III-4) with mild TAA (aortic root 3.1 cm, z-score+2.1), joint hyperflexibility (Beighton score of 6/9), hindfoot valgus, and a diagnosis of autism. The proband's father (Fig. 1B, II-2) also has mild TAA (aortic root 4.1 cm), a focal fusiform aneurysmal dilation of the celiac artery, and a reported history of hyperflexibility that has become less apparent with age (Beighton score 2/9). The proband's paternal grandfather (Fig. 1B, I-1) reportedly has an "enlarged aorta" (additional details unavailable), but no additional family members have known TAA. The proband's 8-year-old sister (Fig. 1B, III-6) has been diagnosed with hypermobile Ehlers–Danlos Syndrome, Chiari malformation (type 1), obstructive hydrocephalus, hypotonia, developmental delay, and dysmorphic features including a broad forehead with deep-set eyes. A 9-year-old sister (Fig. 1B, III-5) also has history of mild type 1 Chiari malformation and reported hyperflexibility (Beighton score 4/9). Neither of these sisters has TAA on last follow up echocardiogram.

Previous DNA sequencing of *TGFBR1*, *TGFBR2*, and *COL3A1*, and deletion/duplication testing for *FBNI*, *TGFBR1*, and *TGFBR2* were negative. Rare variants were found in three TAA genes via exome sequencing of the proband: *SKI*, *NOTCH1*, and *SMAD3* (Table I). Variants in *SKI* (c.1163C>T; p.Ala388Val) and *NOTCH1* (c.3767C>T; p.Pro1256Leu) had inconsistent results for pathogenicity prediction by bioinformatics programs. The *SKI* variant has been reported previously as a VUS in a study of cleft palate mutations [Vieira et al., 2005], and ClinVar reports the *NOTCH1* variant but without interpretation. Four of five bioinformatics programs utilized predicted the *SMAD3* variant (c.803G>A; p.Arg268His) to be damaging, and it is not found in ExAC. This p.Arg268His *SMAD3* variant has been cited in a meeting abstract that reported the variant in a 59-year-old woman with aneurysms and osteoarthritis, which are common phenotypic features of *SMAD3* mutations [Van de Laar et al., 2012]. We note that there is no known history of osteoarthritis in the proband or proband's family. Sanger sequencing confirmed the *SMAD3* variant in the proband. The same variant was also found in the affected father of the proband (Fig. 1B, II-2), suggesting this variant segregates with disease. Based on this evidence, we conclude the p.Arg268His *SMAD3* variant is likely pathogenic in this family. Lack of available DNA from additional informative family members prevented further confirmation of segregation.

Patient 3

Patient 3 is a 59-year-old male (Fig. 1C, proband II-1) with mild TAA restricted to the ascending aorta (diameter 4.0 cm). This patient presents subtle craniofacial features consistent with connective tissue disease, including downslanting palpebral fissures and myopia. Additionally, this patient has bicuspid aortic valve with partial fusion of the right and left coronary cusps and mild aortic insufficiency. The patient's brother (Fig. 1C, II-2) underwent surgical replacement of a unicuspid aortic valve, aortic root, ascending, and transverse aorta, as a result of severe dilation of the ascending aorta (diameter 5.8 cm). His

father also has mild dilation of the ascending aorta (Fig. 1C, I-1: dimension 4.3 cm). There is no known family history of dissection or sudden death.

Neither the proband nor the affected family members have had clinical genetic testing. Exome analysis of the proband revealed rare variants in *MFAP5* and *MYLK* (Table I). The *MYLK* variant (c.2693G>A; p.Arg898Gln) was predicted damaging by three of five programs. This variant has not been reported previously and is not present in ClinVar or HGMD, and has a reported MAF of 0.03% in ExAC. All five bioinformatics programs predicted the *MFAP5* variant (c.341G>A; p.Arg114Gln) to be damaging. Similarly, this variant has not been reported previously in ClinVar or HGMD and has a 0.02% MAF in ExAC. Further, no functional testing information is available. DNA was not available in any family members to confirm segregation. Both the *MYLK* and *MFAP5* variants were confirmed via Sanger sequencing.

DISCUSSION

TAA is most frequently an autosomal dominant condition. Therefore, a diagnosis of TAA in a family has significant implications for family members. Because of the age related onset of disease, decreased penetrance, and the importance of early diagnosis given the progressive and clinically silent nature of the disease, a molecular diagnosis can greatly aid risk stratification for at risk family members. However, the clinical yield of testing for non-syndromic TAA is such that a definitive molecular cause is not established in a majority of families. Because the clinical panels for TAA are changing rapidly as new causative genes are identified, decisions regarding re-testing are complex and family specific. As the genetic basis of FTAA is defined, the potential use of exome testing at the time of initial testing is beginning to be considered. The diagnostic yield of testing must be weighed against expense. In addition, the impact of a positive test result on management of at risk relatives is an important consideration with regard to cost. In the two families with likely disease causing variants, there are 15 at risk first degree relatives for whom positive genetic testing results would further inform management. There were no particular or shared phenotypic features identified in the individuals that had clinically reportable findings. However, it is interesting to note that the three families described in detail all had some phenotypic features of a connective tissue disorder.

Recently released ACMG guidelines have increased the stringency of variant interpretation. One outcome of this is an increase in the number of variants interpreted to be VUSs, but often variants can be stratified within this category. It is important for genetics care providers to interpret the molecular testing results in the context of the patient phenotype and family disease. Family based testing aids the interpretation of rare variants. In this study, two of our clinically actionable variants (in *TGFB2* and *SMAD3*) have previously been reported in individuals that share similar phenotypic features with the patients in our study and show segregation between affected parent child pairs, providing further evidence for the likely pathogenicity of these variants. As expected, testing additional genes results in a higher number of VUS findings, and 60% of the cohort tested was positive for a VUS. Although this indeterminate finding is the least desired outcome clinically, in the context of autosomal dominant disease with multiple affected family members, VUS findings can still

be quite important and may be able to be reinterpreted as either likely benign or likely disease causing in the near future. In this report, the new VUSs identified in Patient 3 were judged to be more significant than the newly identified VUSs in Patients 5, 7, and 10 based on bioinformatics prediction, information on the specific genes involved, and known disease mechanisms. The interpretation of the variants in *FBN2*, *NOTCH1*, *MYLK*, and *MFAP5* might be refined if additional testing revealed segregation with disease within this family or other families. The decision of whether to test family members for a VUS, once an avoided practice in clinical genetics, is now encountered on a daily basis, especially in cardiovascular genetics. This clinical decision is made based on level of suspicion related to variant specific findings, phenotyping, and availability of family members for assessment of segregation, among other factors.

This study was performed on a research basis, and it is important to note that there are differences between research-based exome and clinical exome testing with regard to stringency. For example, clinical exome would require Sanger based sequencing to complete any gaps identified in these genes by exome-based testing. Clinical targeted gene panels done for TAA would be expected to have much greater depth of coverage than the current study. Given that clinical testing would be expected to be more sensitive, the numbers reported here can be considered a minimum estimate of rare variants identified. It is also important to note that interpretation of variants can vary between research studies and between clinical testing laboratories. As clinical application of whole exome and genome sequencing increases, longitudinal evaluation in patients and families with TAA is important to aid variant interpretation. Based on our findings, we conclude that re-testing of TAA patients with an autosomal dominant family history of TAA is an important clinical consideration when previous genetic testing results have been negative or inconclusive. Larger studies to determine the overall prevalence of disease causing variants in newly described TAA genes will assist in decisions regarding timing of re-testing.

Supplementary Material

Refer to Web version on PubMed Central for supplementary material.

Acknowledgments

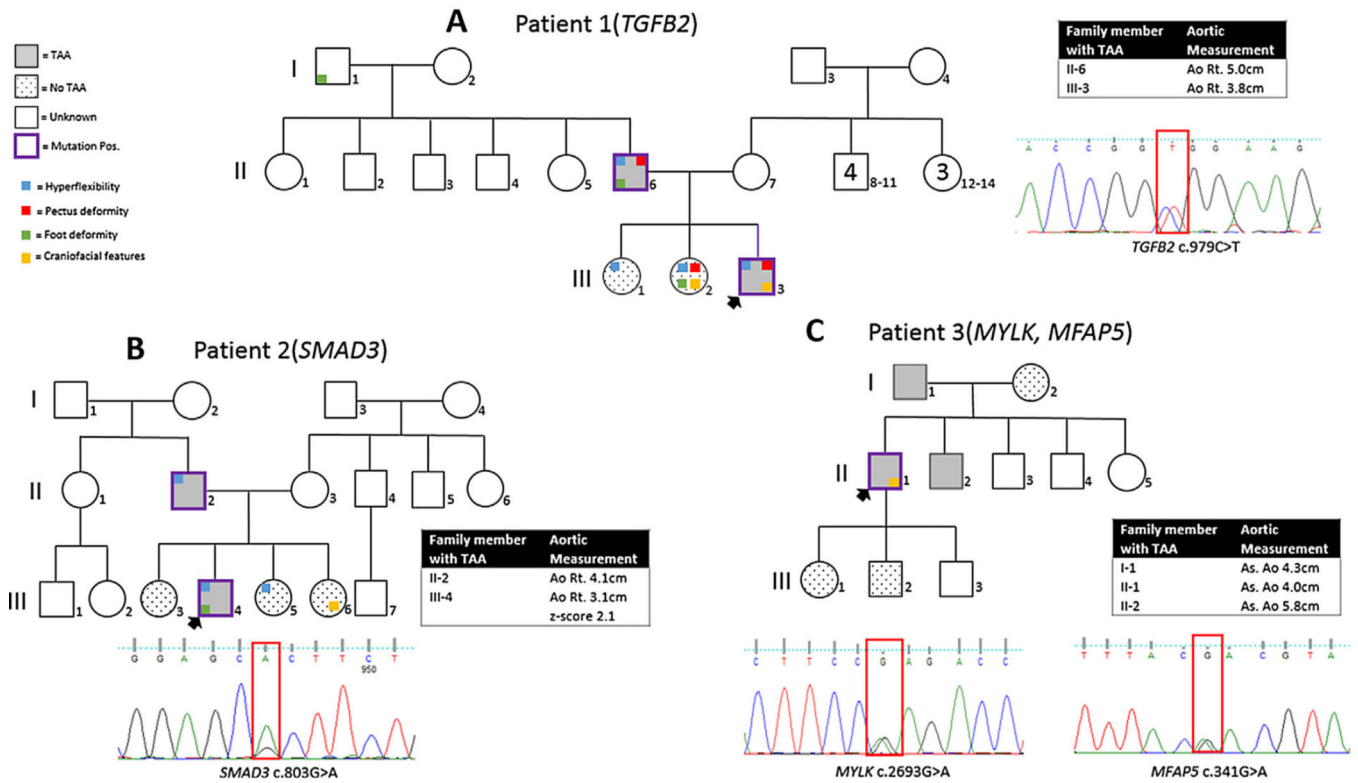
This study was supported by an American Heart Association Innovative Research Grant 14IRG18830027 (RBH) and a Burroughs Wellcome Fund Clinical Scientist Award in Translational Research #1008496 (SMW).

REFERENCES

- Albornoz G, Coady MA, Roberts M, Davies RR, Tranquilli M, Rizzo JA, Elefteriades JA. Familial thoracic aortic aneurysms and dissections—Incidence, modes of inheritance, and phenotypic patterns. *Ann Thorac Surg*. 2006; 82:1400–1405. [PubMed: 16996941]
- Bertoli-Avella AM, Gillis E, Morisaki H, Verhagen JMA, de Graaf BM, van de Beek G, Gallo E, Kruithof BPT, Venselaar H, Myers LA, Laga S, Doyle AJ, Oswald G, van Cappellen GWA, Yamanaka I, van der Helm RM, Beverloo B, de Klein A, Pardo L, Lammens M, Evers C, Devriendt K, Dumoulein M, Timmermans J, Bruggenwirth HT, Verheijen F, Rodrigus I, Baynam G, Kempers M, Saenen J, Van Craenenbroeck EM, Minatoya K, Matsukawa R, Tsukube T, Kubo N, Hofstra R, Goumans MJ, Bekkers JA, Roos-Hesselink JW, van de Laar IMBH, Dietz HC, Van Laer L,

- Morisaki T, Wessels MW, Loeys BL. Mutations in a TGF- β ligand, TGFB3, cause syndromic aortic aneurysms and dissections. *J Am Coll Cardiol*. 2015; 65:1324–1336. [PubMed: 25835445]
- Boileau C, Guo D-C, Hanna N, Regalado ES, Detaint D, Gong L, Varret M, Prakash SK, Li AH, d'Indy H, Braverman AC, Grandchamp B, Kwartler CS, Gouya L, Santos-Cortez RLP, Abifadel M, Leal SM, Muti C, Shendure J, Gross M-S, Rieder MJ, Vahanian A, Nickerson DA, Michel JB, Jondeau G, Milewicz DM. TGFB2 mutations cause familial thoracic aortic aneurysms and dissections associated with mild systemic features of Marfan syndrome. *Nat Genet*. 2012; 44:916–921. [PubMed: 22772371]
- Exome Aggregation Consortium. Analysis of protein-coding genetic variation in 60,706 humans 2015. <http://exac.broadinstitute.org/>.
- Gillis E, Van Laer L, Loeys BL. Genetics of thoracic aortic aneurysm: At the crossroad of transforming growth factor—Signaling and vascular smooth muscle cell contractility. *Circ Res*. 2013; 113:327–340. [PubMed: 23868829]
- Hiratzka LF, Bakris GL, Beckman JA, Bersin RM, Carr VF, Casey DE, Eagle KA, Hermann LK, Isselbacher EM, Kazerooni EA, Kouchoukos NT, Lytle BW, Milewicz DM, Reich DL, Sen S, Shinn JA, Svensson LG, Williams DM. 2010 ACCF/AHA/AATS/ACR/ASA/SCA/SCAI/SIR/STS/SVM guidelines for the diagnosis and management of patients with thoracic aortic disease. *Circulation*. 2010; 121:e266–e369. [PubMed: 20233780]
- Huchtagowder V, Sausgruber N, Kim KH, Angle B, Marmorstein LY, Urban Z. Fibulin-4: A novel gene for an autosomal recessive Cutis Laxa Syndrome. *Am J Hum Genet*. 2006; 78:1075–1080. [PubMed: 16685658]
- Jondeau G, Boileau C. Genetics of thoracic aortic aneurysms. *Curr Atheroscler Rep*. 2012; 14:219–226. [PubMed: 22415348]
- Jondeau G, Boileau C. Familial thoracic aortic aneurysms. *Curr Opin Cardiol*. 2014; 29:492–498. [PubMed: 25290696]
- Landis BJ, Ware SM, James J, Shikany AR, Martin LJ, Hinton RB. Clinical stratification of pediatric patients with idiopathic thoracic aortic aneurysm. *J Pediatr*. 2015; 167:131.e5–137.e5. [PubMed: 25812776]
- Lerner-Ellis JP, Aldubayan SH, Hernandez AL, Kelly MA, Stuenkel AJ, Walsh J, Joshi VA. The spectrum of FBN1, TGF β R1, TGF β R2 and ACTA2 variants in 594 individuals with suspected Marfan syndrome, Loeys–Dietz syndrome or thoracic aortic aneurysms and dissections (TAAD). *Mol Genet Metab*. 2014; 112:171–176. [PubMed: 24793577]
- Lindsay ME, Schepers D, Bolar NA, Doyle JJ, Gallo E, Fert-Bober J, Kempers MJE, Fishman EK, Chen Y, Myers L, Bjeda D, Oswald G, Elias AF, Levy HP, Anderlid B-M, Yang MH, Bongers EMHF, Timmermans J, Braverman AC, Canham N, Mortier GR, Brunner HG, Byers PH, Van Eyk J, Van Laer L, Dietz HC, Loeys BL. Loss-of-function mutations in TGFB2 cause a syndromic presentation of thoracic aortic aneurysm. *Nat Genet*. 2012; 44:922–927. [PubMed: 22772368]
- Milewicz DM, Guo D-C, Tran-Fadulu V, Lafont AL, Papke CL, Inamoto S, Kwartler CS, Pannu H. Genetic basis of thoracic aortic aneurysms and dissections: Focus on smooth muscle cell contractile dysfunction. *Annu Rev Genom Hum G*. 2008; 9:283–302.
- Milewicz DM, Regalado ES, Shendure J, Nickerson DA, Guo D. Successes and challenges of using whole exome sequencing to identify novel genes underlying an inherited predisposition for thoracic aortic aneurysms and acute aortic dissections. *Trends Cardiovas Med*. 2014; 24:53–60.
- Pomianowski P, Elefteriades JA. The genetics and genomics of thoracic aortic disease. *Ann Cardiothorac Surg*. 2013; 2:271–279. [PubMed: 23977594]
- Renard M, Callewaert B, Baetens M, Campens L, MacDermot K, Fryns J-P, Bonduelle M, Dietz HC, Gaspar IM, Cavaco D, Stattin E-L, Schrandner-Stumpel C, Coucke P, Loeys B, De Paepe A, De Backer J. Novel MYH11 and ACTA2 mutations reveal a role for enhanced TGF β signaling in FTAAD. *Int J Cardiol*. 2013a; 165:314–321. [PubMed: 21937134]
- Renard M, Callewaert B, Malfait F, Campens L, Sharif S, del Campo M, Valenzuela I, McWilliam C, Coucke P, De Paepe A, De Backer J. Thoracic aortic-aneurysm and dissection in association with significant mitral valve disease caused by mutations in TGFB2. *Int J Cardiol*. 2013b; 165:584–587. [PubMed: 23102774]

- Richards S, Aziz N, Bale S, Bick D, Das S, Gastier-Foster J, Grody WW, Hegde M, Lyon E, Spector E, Voelkerding K, Rehm HL. Standards and guidelines for the interpretation of sequence variants: A joint consensus recommendation of the American college of medical genetics and genomics and the association for molecular pathology. *Genet Med*. 2015; 17:405–424. [PubMed: 25741868]
- Van de Laar IMBH, Oldenburg RA, Pals G, Roos-Hesselink JW, de Graaf BM, Verhagen JMA, Hoedemaekers YM, Willemsen R, Severijnen L-A, Venselaar H, Vriend G, Pattynama PM, Collée M, Majoor-Krakauer D, Poldermans D, Frohn-Mulder IME, Micha D, Timmermans J, Hilhorst-Hofstee Y, Bierma-Zeinstra SM, Willems PJ, Kros JM, Oei EHG, Oostra BA, Wessels MW, Bertoli-Avella AM. Mutations in SMAD3 cause a syndromic form of aortic aneurysms and dissections with early-onset osteoarthritis. *Nat Genet*. 2011; 43:121–126. [PubMed: 21217753]
- Van de Laar IMBH, van der Linde D, Oei EHG, Bos PK, Bessems JH, Bierma-Zeinstra SM, van Meer BL, Pals G, Oldenburg RA, Bekkers JA, Moelker A, de Graaf BM, Matyas G, Frohn-Mulder IME, Timmermans J, Hilhorst-Hofstee Y, Cobben JM, Bruggenwirth HT, van Laer L, Loeyts B, De Backer J, Coucke PJ, Dietz HC, Willems PJ, Oostra BA, De Paepe A, Roos-Hesselink JW, Bertoli-Avella AM, Wessels MW. Phenotypic spectrum of the SMAD3-related aneurysms-osteoarthritis syndrome. *J Med Genet*. 2012; 49:47–57. [PubMed: 22167769]
- Vieira AR, Avila JR, Daack-Hirsch S, Dragan E, Féelix TM, Rahimov F, Harrington J, Schultz RR, Watanabe Y, Johnson M, Fang J, O'Brien SE, Orioli IM, Castilla EE, Fitzpatrick DR, Jiang R, Marazita ML, Murray JC. Medical sequencing of candidate genes for nonsyndromic cleft lip and palate. *PLoS Genet*. 2005; 1:e64. [PubMed: 16327884]

**FIG. 1.**

Pedigrees for three families in which a potentially clinically actionable variant was identified. Purple outlined boxes denote genotype positive family members for the clinically actionable variant identified in exome sequencing. Shaded boxes represent clinically diagnosed TAA, dotted boxes represent normal aorta dimensions by cardiac imaging and white boxes represent unknown TAA status (no available cardiac imaging). Aortic measurements are listed in boxes for family members with TAA or borderline TAA. Additional extra-thoracic features are represented by the presence of small, colored squares: hyperflexibility (blue), pectus deformity (red), foot deformity (green), and craniofacial features (yellow). Chromatograms show the variants of interest. (A) Pedigree for Patient 1 with identified variant in *TGFB2* (c.979C>T). (B) Pedigree for Patient 2 with identified variant in *SMAD3* (c.803G>A). (C) Pedigree for Patient 3 with identified variants in *MYLK* (c.2693G>A) and *MFAP5* (c.341G>A).

TABLE I
Rare Variants Identified in Ten FTAA Patients Via Research Based Exome Sequencing

Patient	Previous clinical genetic testing	TAA research exome gene finding	Rare coding variants	Minor allele frequency of non-finnish Europeans from ExAC (allele counts)	Amino acid changes	Bioinformatics predictions	Variant interpretation
1	<i>FBN1</i> ^a , <i>FBN2</i> <i>TGFBR1</i> ^a , <i>TGFBR2</i> ^a	1. <i>FBN2</i> ^b 2. <i>TGFBR2</i>	1. c.1040G>A 2. c.979C>T	1. 0.63% (423/66,706) 2. Not listed	1. p.Arg347His 2. p.Arg327Tyr	1. -/-/+/-/+/- 2. +/++/+/-	1. VUS 2. Likely pathogenic
2	<i>COL3A1</i> , <i>FBN1</i> , <i>TGFBR1</i> , <i>TGFBR2</i> , Del/dup: <i>FBN1</i> , <i>TGFBR1</i> , <i>TGFBR2</i>	1. <i>NOTCH1</i> 2. <i>SKI</i> 3. <i>SMAD3</i>	1. c.3767C>T 2. c.1163C>T 3. c.803G>A	1. 0.005% (3/57,602) 2. 0.61% (403/66,502) 3. Not listed	1. p.Pro1256Leu 2. p.Ala388Val 3. p.Arg268His	1. +/-/-/+ 2. -/-/+/- 3. +/++/+/-	1. VUS 2. Likely benign 3. Likely pathogenic
3	None	1. <i>MFAP5</i> 2. <i>MYLK</i>	1. c.341G>A 2. c.2693G>A	1. 0.02% (13/66,694) 2. 0.03% (24/66,690)	1. p.Arg114Gln 2. p.Arg898Gln	1. +/++/+/ 2. -/++/+/-	1. VUS 2. VUS
4	<i>ACTA2</i>	None	NA	NA	NA	NA	NA
5	<i>ACTA2</i> , <i>FBN1</i> , <i>MYH11</i> , <i>TGFBR1</i> , <i>TGFBR2</i>	<i>MYH11</i> ^b	c3848C>T	0.007% (5/66,608)	p.Ala1283Val	-/-/+/-	VUS
6	<i>ACTA2</i> , <i>FBN1</i> , <i>MYH11</i> , <i>TGFBR1</i> , <i>TGFBR2</i>	None	NA	NA	NA	NA	NA
7	<i>ACTA2</i> , <i>CBS</i> , <i>COL3A1</i> , <i>FBN1</i> , <i>FBN2</i> , <i>FLNA</i> , <i>MYH11</i> , <i>MYLK</i> , <i>SKI</i> , <i>SLC2A10</i> , <i>SMAD3</i> , <i>TGFBR2</i> , <i>TGFBR1</i> , <i>TGFBR2</i>	<i>COL5A1</i>	c.367C>G	0.03% (18/66,242)	p.Gln123Glu	-/-/+/-	VUS
8	<i>ACTA2</i> , <i>CBS</i> , <i>COL3A1</i> , <i>FBN1</i> , <i>FBN2</i> , <i>FLNA</i> , <i>MYH11</i> , <i>MYLK</i> , <i>SKI</i> , <i>SLC2A10</i> , <i>SMAD3</i> , <i>TGFBR2</i> , <i>TGFBR1</i> , <i>TGFBR2</i>	None	NA	NA	NA	NA	NA
9	<i>ACTA2</i> ^a , <i>FBN1</i> ^a , <i>MYH11</i> ^a , <i>TGFBR1</i> ^a , <i>TGFBR2</i> ^a Del/dup ^a : <i>FBN1</i> , <i>TGFBR1</i> , <i>TGFBR2</i>	None	NA	NA	NA	NA	NA
10	<i>FBN1</i> , <i>TGFBR1</i> , <i>TGFBR2</i> Del/dup: <i>FBN1</i> , <i>TGFBR1</i> , <i>TGFBR2</i>	<i>COL3A1</i>	c.3818A>G	0.02% (10/65,996)	p.Lys1273Arg	-/-/+/-	VUS

Bioinformatic predictions: PROVEAN/SIFT/Polyphen-2/Condel/SusPect.

^aGenes listed represent genetic testing done in a first degree relative of patient.

^bVariant reported on previous clinical testing, confirmed in research exome. Del/Dup, deletion/duplication testing.

Reference transcripts for each gene: *FBN2* (ENST00000508053), *TGFBR2* (ENST00000366929), *NOTCH1* (ENST00000277541), *SKI* (ENST00000378536), *SMAD3* (ENST00000327367), *MFAP5* (ENST00000359478), *MYLK* (ENST00000360304), *COL5A1* (ENST00000371817), *MYH11* (ENST00000396324), and *COL3A1* (ENST00000304636).