

## Reassessing the cardiac box: A comprehensive evaluation of the relationship between thoracic gunshot wounds and cardiac injury

|                                      |                                     |
|--------------------------------------|-------------------------------------|
| Rashi Jhunhunwala MA <sup>†</sup>    | rashi.jhunhunwala@emory.edu         |
| Michael J. Mina MD PhD <sup>†</sup>  | michael.j.mina@gmail.com            |
| Elizabeth I. Roger, MD <sup>†</sup>  | elizabeth.i.roger.mil@mail.mil      |
| Christopher J. Dente MD <sup>†</sup> | cdente@emory.edu                    |
| Michael Heninger, MD <sup>¥</sup>    | Michael.Heninger@fultoncountyga.gov |
| Jacquelyn S. Carr, MD <sup>†</sup>   | JaCarr@unch.unc.edu                 |
| Stacy D. Dougherty MD <sup>†</sup>   | sdougherty417@emory.edu             |
| Rondi B. Gelbard MD <sup>†</sup>     | rondi.beth.gelbard@emory.edu        |
| Jeffrey M. Nicholas MD,              | jmnicholas2525@att.net              |
| Amy D. Wyrzykowski MD,               | amy.wyrzykowski@me.com              |
| David V. Feliciano, MD <sup>*</sup>  | davfelic@iupui.edu                  |
| Bryan C. Morse MS, MD <sup>†</sup>   | bcmorse@emory.edu                   |

Departments of Surgery, <sup>†</sup>Emory University School of Medicine Department of Surgery, Grady Memorial Hospital, Atlanta, Georgia, <sup>¥</sup>Emory University School of Medicine Department of Pathology, <sup>\*</sup>Indiana University School of Medicine Department of Surgery, Indianapolis, Indiana

---

This is the author's manuscript of the article published in final edited form as:

Jhunhunwala, R., Mina, M. J., Roger, E. I., Dente, C. J., Heninger, M., Carr, J. S., ... & Feliciano, D. V. (2017). Reassessing the cardiac box: A comprehensive evaluation of the relationship between thoracic gunshot wounds and cardiac injury. *Journal of Trauma and Acute Care Surgery*. <http://dx.doi.org/10.1097/TA.0000000000001519>

**Short title: “Reassessing Cardiac Box”**

**Authors have no financial disclosures or conflicts of interest.**

Address correspondence to:

Bryan C. Morse MS MD

Assistant Professor of Surgery

Emory University Department of Surgery

Grady Memorial Hospital

69 Jesse Hill Jr. Drive SE

Glenn Memorial Building, Room 308

Atlanta, GA 30303

Phone: (404) 251-8745

Fax: (404) 523-3931

bcmorse@emory.edu

Oral Presentation at 75<sup>th</sup> Annual Meeting of the American Association for the Surgery of Trauma

September 14-17 2016, Waikoloa, Hawaii

## ABSTRACT

**Background:** High energy missiles can cause cardiac injury regardless of entrance site. This study assesses the adequacy of the anatomic borders of the current “cardiac box” to predict cardiac injury.

**Methods:** Retrospective autopsy review was performed to identify patients with penetrating torso gunshot wounds 2011-2013. Using a circumferential grid system around the thorax, logistic regression analysis was performed to detect differences in rates of cardiac injury from entrance/exit wounds in the “cardiac box” vs. the same for entrance/exit wounds outside the box. Analysis was repeated to identify regions to compare risk of cardiac injury between the current cardiac box and other regions of the thorax.

**Results:** Over the study period, 263 patients (89% male, mean age = 34 years, median injuries/person = 2) sustained 735 wounds [80% gunshot wounds (GSWs), and 239 patients with 620 GSWs were identified for study. Of these, 95 (34%) injured the heart. Of the 257 GSWs entering the cardiac box, 31% caused cardiac injury while 21% GSWs outside the cardiac box (n = 67) penetrated the heart, suggesting that the current “cardiac box” is a poor predictor of cardiac injury relative to the thoracic non-"cardiac box" regions [Relative Risk (RR) 0.96; p=0.82]. The regions from the anterior to posterior midline of the left thorax provided the highest positive predictive value (41%) with high sensitivity (90%) while minimizing false positives making this region the most statistically significant discriminator of cardiac injury (RR 2.9; p=0.01).

**Conclusion:** For GSWs, the current cardiac box is inadequate to discriminate whether a gunshot wound will cause a cardiac injury. As expected, entrance wounds nearest to the heart are the most likely to result in cardiac injury, but, from a clinical standpoint, it is best to think outside the “box” for GSWs to the thorax.

**Level of Evidence:** Therapeutic/Care Management, Level III

**Keywords:** cardiac box; penetrating cardiac injury; cardiac wounds; penetrating cardiac wounds; cardiac tamponade

## BACKGROUND

In recent publications, the authors have noted an increased rate of patients presenting to trauma centers with penetrating cardiac injuries (PCI) secondary to gunshot wounds.<sup>1-3</sup> Survival following PCI is highly time dependent and minimizing time from injury to operative repair is paramount. Therefore, a high index of suspicion for a PCI is critical for rapid transport to a trauma center by emergency medical technicians and early diagnosis by the trauma surgeon.<sup>1-15</sup>

Examination of the patient to identify thoracic entrance and exit wounds is a major criteria used to create this index of suspicion. In order to obtain a high suspicion for cardiac injury, examination assesses whether injury occurred within the canonical cardiac box (often referred to as “the box”), a region of the thorax where a penetrating entrance wound is considered high risk for cardiac injury. The “box” includes the area of the anterior chest bounded superiorly by the clavicles, laterally by the midclavicular lines, and inferiorly by a line drawn between the points where the midclavicular lines intersect the costal margins. Often, the box is extended to include posterior entrance wounds with a projection onto the posterior thorax as well. Although trauma clinicians are almost invariably trained to consider entrance wounds into the cardiac box to raise concern for PCI, studies examining this area as a predictor of cardiac injury are based primarily on small sample sizes involving mostly stab wounds.<sup>16-18</sup> Furthermore, Degiannis et al.<sup>19</sup> noted that injuries outside of the cardiac box were associated with higher mortality than those in the box, suggestive of a delayed diagnosis of PCI following low suspicion. This indicates that the canonical “box” may be inadequate to discriminate penetrating thoracic injuries likely to cause a cardiac injury versus those that do not.

With an increasing rate of gun violence, the authors have noted high numbers of cardiac injuries with thoracic entrance wounds from bullets located outside the cardiac box. The objective of this study is to assess the ability of the boundaries of the cardiac box to predict a penetrating cardiac wound. The hypothesis is that the cardiac box is a poor predictor of cardiac injuries from gunshot wounds to the chest.

## **METHODS**

A retrospective, population-based review of the Fulton County (Georgia) Medical Examiner's autopsy registry was performed to include all patients who sustained penetrating torso injuries from January, 2011, to December, 2013. All gunshot wounds with entrance and exit wounds and trajectory were documented. Autopsy records were supplemented with clinical data from the trauma registry for patients treated at Grady Memorial Hospital, a State of Georgia Level I trauma center in Atlanta for patients treated at our institution. This study was approved by the Emory University Institutional Review Board.

As described briefly above, the cardiac box is defined as the two-dimensional plane covering the anterior surface of the thorax from the level of the clavicle to the tip of the xiphoid (which roughly corresponds to a line drawn between the costal margins at the level where the midclavicular line intersects) and between the midclavicular lines (laterally). Based on observations by Evans et al.<sup>20</sup> that described a significant number of cardiac injuries were incurred from posterior thorax wounds, for the purposes of this study, we considered the anterior

boundaries of the cardiac box to project through to include the posterior thorax, as well. Autopsy reports for and photographs of these patients were reviewed to identify the location of all entry and exit wounds to the torso. These data were recorded on autopsy diagrams and the corresponding longitudinal and latitudinal markers of the wounds were transferred to a separate database. Anatomic landmarks used to create the circumferential grid system are described in Table I and shown in Figure 1. By this system, the reference or ‘gold standard’ cardiac box is bounded by horizontal regions (i.e. regions whose borders extend horizontally) C, D, and E and vertical regions 2, 3, 7, and 8. The following exclusion criteria were applied to injuries in this study: 1) in order to focus on gunshots to the chest, injuries outside of horizontal regions C, D, and E, ie above the clavicles and below the xyphoid, and 2) patients with incomplete data fields.

To assess the areas of the chest with the highest likelihood of cardiac injury from a gunshot wound, all possible combinations of vertical regions on the thoracic grid were assessed. Multiple statistical iterations were performed, and relative risk for these regions were compared to that of the current cardiac box as a “gold standard.”

### *Statistical Analysis*

Statistical analysis was performed within the R statistical environment (R Core Team, Vienna, Austria). Continuous data are presented as means ( $\pm$  standard deviation), and categorical data are presented as proportions. Skewed variables are reported as median with interquartile range. Comparisons of continuous data between two groups were performed using the Student’s

t-test and between greater than two groups using one-way analysis of variance (ANOVA). When a statistically significant difference ( $p < 0.05$ ) was detected in the ANOVA analysis, pairwise comparisons were performed using the method of Tukey. Overall differences in categorical (binomial) responses were assessed using  $\chi^2$  analysis. Where no direction was evident, a two-sided p-value was calculated to allow for detection in either direction. Relative risk and 95% confidence intervals were calculated. 95% confidence intervals that did not cross one were taken to be statistically significant at an alpha of 0.05.

## RESULTS

Over the three-year study period, 263 patients sustained 735 individual penetrating torso injuries. Of the 735 injuries, 620 (84%) were gunshot wounds (GSWs) which occurred in 239 individual patients (mean=2.6 GSWs/patient and median=2GSWs/patient). Of note, there were two patients with cardiac injuries that had entrance wounds outside latitudes of the box; one patient sustained a gunshot to the left buttocks, injuring the heart, that exited the chest and the other had a gunshot to the right neck that exited the left chest. Demographic information is summarized in Table II.

Summary of the study population is shown in Figure 1. Of the 384 penetrating injuries located within regions C, D, E (between clavicles and xiphoid), complete data were available for all but 19 (4.9%) injuries, and these were excluded



from analysis. After exclusion criteria were applied, a total of 320 GSWs were included in the study population to evaluate the likelihood of cardiac penetration based on region of entry or exit. Of the 257 GSWs that hit the standard cardiac box, 81 (31%) caused a cardiac injury, and, for the 67 wounds outside of the box, 14 (21%) injured the heart; this difference was not significant ( $p = 0.09$ ).

Figure 2 shows rates of cardiac injury by individual vertical regions for gunshots to regions C, D, and E. To determine which individual vertical regions were most likely to result in cardiac injury, odds ratios for a cardiac injury were calculated for a given GSW to each region independently (Table III). Region 3 sustained the highest number of penetrating entrance wounds ( $n = 72$ ) along with the highest number of cardiac injuries 27 (38%). Compared to other regions of the chest, this was associated with an RR = 1.26 ( $p = 0.20$ ) for a gunshot injury in this area causing a cardiac injury. Regions 5 and 7 also had high rates of cardiac injury [7/17 (41%) and 16/41 (39%), respectively] and a high likelihood of cardiac injury (RR = 1.33;  $p = 0.34$  and OR = 1.28;  $p = 0.24$ ; respectively). Region 10 (right lateral chest) also had a rate of cardiac injury greater than 30% despite the fact it is further from the heart.

Analysis was performed to compare the likelihood of a cardiac injury from a gunshot to the current cardiac box as well as other regions to assess the predictive value of the current “box” (Table IV). For the current “gold standard” cardiac box, the relative risk of a GSW in this area causing a cardiac injury is low and not

statistically significant (RR = 0.96; p=0.82), especially, when compared to other combinations of regions. (Table IV). GSWs to areas that included regions of the left chest (regions 3,4,5,6,7,8) had a statistically higher relative risk of causing cardiac injury compared to the current “cardiac box” (RR = 9.9, p =0.03).

## DISCUSSION

The primary goal of this study is to challenge the validity of the cardiac box. There exists significant ambiguity in the surgical literature regarding the relationship between penetrating thoracic wounds and cardiac injury. The majority of these studies are limited by small patient populations comprised primarily of stab wound victims and minimal statistical scrutiny. In his thesis, Nichol<sup>15</sup> summarized the multitude of terms relating injuries to the thoracic wall and cardiac injuries. Sauer and Murdock<sup>13</sup> recommended a “thoracotomy on suspicion” for penetrating injuries in the “danger zone” comprised of the area bounded laterally by the left mid-clavicular line and a line through the right medial 1/3 of the clavicle, superiorly by the sternal notch and inferiorly by the epigastrium. “Cardiac proximity” was defined as the presence of an entrance wound in an area with boundaries comprising the sternal notch superiorly, xiphisternum inferiorly, the left nipple line and the right parasternal line.<sup>21,22</sup> The cardiac “silhouette” or “box” is documented as a high-risk area for thoracic penetrating trauma, also. Wounds overlying the “cardiac silhouette” - defined as “the area encompassed by the nipple lines, manubrium and xiphoid” – have rates of cardiac injury from 60-84%.<sup>23-25</sup> Other terms have also been used including “juxta-cardiac” region–

bounded by the manubrium, the subcostal line and the left and right midclavicular lines, “precordium,” and “precordial zone” - the area between sternal notch and the xiphoid process and the nipples laterally.<sup>26</sup> Subsequent studies, however, demonstrated that stab wounds outside of the “precordial” region had a higher mortality (25%) compared to those in the precordium (4%).<sup>19</sup> Nicol et al.<sup>27</sup> refer to the cardiac zone for penetrating wounds as the area extending from the right anterior axillary line across to the back of the left chest to the vertebral line with the superior margin being the supraclavicular areas and the inferior margin being the costal margins, inclusive of the epigastrium. The results of this study demonstrate that the current cardiac box is inadequate to discriminate between gunshots that cause cardiac injury and those that do not. From bivariate logistic regression (Table III), certain regions, particularly those furthest from the heart, are included within the current definition of the cardiac box and have a low likelihood of causing a cardiac injury. Gunshots to regions 2 and 8 – areas of the right thorax and part of the current “box” – have rates of cardiac injury of 33% and 30%, respectively, but have a negative relative risk of a cardiac injury. Conversely, there are other regions not currently included in the cardiac box where, intuitively, a GSW has considerably higher risk of causing a cardiac injury as compared to other regions based on its proximity to the heart. Wounds in region 5, the left lateral thorax, have the second highest rate of cardiac injury overall and the second highest odds ratio of causing a cardiac injury, relative to all other regions, despite region 5 not being included within the current cardiac box. It is interesting to note, however, that the regions directly flanking region 5, i.e., regions 4 and 6, have reduced rates of cardiac injury and overall OR for injury as compared to the cardiac box, despite the fact these regions separate the cardiac box from region 5.

From Table IV, the current designation of the “gold standard” cardiac box may be inadequate to discriminate between penetrating injuries that do and do not cause a cardiac injury. The relative risk (RR = 0.96, p=0.82) of cardiac injury due to a penetrating GSW into the cardiac box versus the odds of cardiac injury due to a penetrating GSW in all regions of the thorax is low and does not meet statistical significance to discriminate between cardiac and non-cardiac injury. This suggests that the surgical dogma of the “box” being the highest risk for cardiac injury is likely invalid for gunshot wounds and warrants re-evaluation. As expected, regions overlying the left chest had the highest likelihood of injury. This is based on the high rate of cardiac injuries from GSWs to the left lateral chest (region 5) (Table IV). From a clinical standpoint, however, the fact that the iterations which include regions 8 (right posterior chest) and 10 (right lateral chest) are statistically superior to the current box indicates that gunshot wounds anywhere to the thorax should be considered as potentially injuring the heart.

In clinical practice, the term “cardiac box” is very misleading, based on poor data, and, in our experience, distracts clinicians from the real possibility that a GSW outside the “box” can cause an injury to the heart. To this end, the “cardiac box” is most likely irrelevant for GSWs. However, the principle of the “box” is taught ubiquitously across the United States and internationally to trainees in all aspects of medicine – from paramedics to trauma fellows - and is firmly ingrained in day-to-day communication as a method of anatomic triage at trauma centers with high volumes of penetrating trauma. So, while this may be a subtle point for trauma surgeons, this message needs to be communicated to the rest of the medical community. To the authors’ knowledge, this is the only large study that challenges the validity of the “cardiac box.”

The dogma of the cardiac box is largely based on small studies with primarily stab wounds. The underlying issue is that stab wounds are low kinetic energy and result from instruments with a fixed length. Thus, most stab wounds usually only result in a cardiac injury if the entrance is in very close proximity to the heart or there is a long weapon. Because these studies did include gunshots, the concept of the “box” was ultimately uniformly applied to all mechanisms. Injuries from high kinetic energy projectiles, however, can cause cardiac injury from entrance wounds to any area of the torso, especially the thorax. Therefore, the current boundaries of the “box” are clinically irrelevant for gunshot which is what this study demonstrates. At trauma centers with high volumes of gunshot victims and penetrating injuries, frequently, the surgeon is forced to triage multiple patients at once. In this setting, surgeons need to maintain a high index of suspicion for gunshot injuries outside the box, especially if the bullet wounds are in the left chest (Figure 2), even if the patients do not present with classic findings of cardiac tamponade or massive hemothorax, as the patient can still have a cardiac injury.

Several authors have published reports demonstrating that gunshot entrance wounds in remote locations have caused penetrating cardiac wounds.<sup>28-29</sup> Although this is a rare circumstance, as mentioned above, the authors have experience with treating these cardiac wounds, as well. Detection of these cardiac injuries with distant entrance wounds also requires a high index of suspicion and an early surgeon-performed ultrasound for rapid detection of a hemopericardium.<sup>30</sup>

There are several limitations to this study. First, this is a retrospective, autopsy-based study. While the authors cede that there are inherent limitations to this study, the primary

benefit is identification of all entrance and exit wounds and association with their internal injuries in order to determine the actual rate of injury to the heart from a given area of the chest. There is also the theoretical possibility that, as this is an autopsy study, there may be a difference in thoracic gunshot injury patterns in patients who survived cardiac injuries that may not be accounted for in this study. In the authors' experience with high volumes of penetrating cardiac injuries, these findings parallel clinical practice and experience.<sup>1,2</sup> .

## CONCLUSION

While any gunshot wound to the torso can potentially cause an injury, penetrating thoracic injuries are the most likely to result in an actual cardiac wound. The standard boundaries of the cardiac box are likely inadequate to discern between chest wounds causing cardiac injury compared to other regions of the chest. Conversely, as would be expected, gunshots to the left chest in close proximity to the heart are more likely to cause cardiac injury. . In summary, for gunshot wounds to the chest, the bottom line is to think outside the "box."

Author Contribution:

Literature search: BCM, MJM, RJ, EIR

Study design: BCM, MJM, RJ, CJD, EIR, DVF

Data collection: BCM, RJ, EIR, MH

Data analysis: BCM, MJM, CJD, MH, SDD, RJ, EIR

Data interpretation: BCM, MJM, JSC, CJD, JMN, ADW, JPS, GAV, SDD, DVF

Writing: BCM, MJM, RJ, CJD, DVF

Critical revision BCM, MJM, CJD, JMN, ADW, DVF

The authors would like to thank Elizabeth Roger, MD for her renderings of the body in this manuscript.

ACCEPTED

## REFERENCES

1. Mina MJ, Jhunhunwala R, Gelbard RB, Dougherty SD, Carr JS, Dente CJ, Nicholas JM, Wyrzykowski AD, Salomone JP, Vercruyssen GA, Feliciano DV, Morse BC. Factors affecting mortality after penetrating cardiac injuries: 10-year experience at urban level I trauma center. *Am J Surg*. 2016 Oct 15. Epub ahead of print .
2. Morse BC, Mina MJ, Carr JS, Jhunhunwala R, Dente CJ, Zink JU, Nicholas JM, Wyrzykowski AD, Salomone JP, Vercruyssen GA, Rozycki GS, Feliciano DV. Penetrating cardiac injuries: A 36-year perspective at an urban, level I trauma center. *J Trauma Acute Care Surg*. Oct;81(4):623-3.1
3. Jhunhunwala R, Dente CJ, Keeling WB, Prest PJ, Dougherty SD, Gelbard RB, Long WB, Nicholas JM, Morse BC. Injury to the conduction system: management of life-threatening arrhythmias after penetrating cardiac trauma. *Am J Surg*. 2016 Aug;212(2):352-3.
4. Gervin AS, Fischer RP: The importance of prompt transport in salvage of patients with penetrating heart wounds. *J Trauma*. 1982; 22: 443-448.
5. Moreno C, Moore EE, Majure JA, Hopeman AR. Pericardial tamponade: a critical determinant for survival following penetrating cardiac wounds. *J Trauma*. 1986;26: 821-825.



6. Mattox KL, Beall Jr. AC., Jordan Jr. GL, De Bakey ME: Cardiorrhaphy in the emergency center. *J ThoracCardiovasc Surg*. 1974; 68: 886-95.
7. Ivatury RR, Nallathambi MN, Roberge RJ, Rohman M, Stahl W.. Penetrating thoracic injuries: in-field stabilization vs. prompt transport. *J Trauma*. 1987; 27: 1066-73.
8. Thourani VH, Feliciano DV, Cooper WA, Brady KM, Adams AB, Rozycki GS, Symbas PN. Penetrating cardiac trauma at an urban trauma center: a 22-year perspective. *Am Surg*. 1999 Sep; 65: 811-6.
9. Ivatury RR, Rohman M, Steichen FM, Gunduz Y, Nallathambi M, Stahl WM. Penetrating cardiac injuries: Twenty-year experience. *Am Surg* 1987;53: 310-7.
10. Asensio JA, Murray J, Demetriades D, Berne J, Cornwell E, Velmahos G, Gomez H, Berne TV.. Penetrating cardiac injuries: A prospective study of variables predicting outcome. *J Am Coll Surg* 1998; 186:24-34.
11. Asensio JA, Berne JD, Demetriades D, Chan L, Murray J, Falabella A, Gomez H, Chahwan S, Velmahos G, Cornwell EE, et al. One hundred five penetrating cardiac injuries: A 2-year prospective evaluation. *J Trauma* 1998;44: 1073-82.
12. Demetriades D, van der Veen BW. Penetrating injuries of the heart: experience over two years in South Africa. *J Trauma* 1983;23:1034-41.

13. Ivatury RR, Shah PM, Ito K, Ramirez-Schon G, Suarez F, Rohman M. Emergency room thoracotomy for the resuscitation of patients with "fatal" penetrating injuries of the heart. *Ann ThoracSurg* 1981;32:377-85.
14. Rhee PM, Foy H, Kaufmann C, Areola C, Boyle E, Maier RV, Jurkovich G.. Penetrating cardiac injuries: a population-based study. *J Trauma*. 1998 ;45:366-70.
15. Nichol AJ.(2012). The current management of penetrating cardiac trauma (Doctoral dissertation). Retrieved from: [https://open.uct.ac.za/bitstream/item/11852/thesis\\_hsf\\_2012\\_nicol\\_a.pdf?sequence=1](https://open.uct.ac.za/bitstream/item/11852/thesis_hsf_2012_nicol_a.pdf?sequence=1),
16. Nagy KK, Lohmann C, Kim DO, Barrett J. Role of echocardiography in the diagnosis of occult penetrating cardiac injury. *J Trauma*. 1995 Jun;38(6):859-62.
17. Sauer PE, Murdock CE,Jr. Immediate surgery for cardiac and great vessel wounds. *Arch Surg* 1967 Jul;95(1):7-11.
18. Buckman RF,Jr, Badellino MM, Mauro LH, Asensio JA, Caputo C, Gass J, Grosh JD. Penetrating cardiac wounds: Prospective study of factors influencing initial resuscitation. *J Trauma* 1993 May;34(5):717-25; discussion 725-7.
19. Degiannis E, Loogna P, Doll D, Bonanno F, Bowley DM, Smith MD. Penetrating cardiac injuries: Recent experience in South Africa. *World J Surg* 2006 Jul;30(7):1258-64.

20. Evans J, Gray LA,Jr, Rayner A, Fulton RL. Principles for the management of penetrating cardiac wounds. *Ann Surg* 1979 Jun;189(6):777-84.
21. Grewal H, Ivatury RR, Divakar M, Simon RJ, Rohman M. Evaluation of subxiphoid pericardial window used in the detection of occult cardiac injury. *Injury* 1995 Jun;26(5):305-10.
22. Michelow BJ, Bremner CG. Penetrating cardiac injuries: Selective conservatism--favorable or foolish? *J Trauma* 1987 Apr;27(4):398-401.
23. Reece IJ, Davidson KG. Emergency surgery for stab wounds to the heart. *Ann R Coll Surg Engl* 1983 Sep;65(5):304-7.
24. von Oppell UO, Bautz P, De Groot M. Penetrating thoracic injuries: What we have learnt. *Thorac Cardiovasc Surg* 2000 Feb;48(1):55-61.
25. Meyer DM, Jessen ME, Grayburn PA. Use of echocardiography to detect occult cardiac injury after penetrating thoracic trauma: A prospective study. *J Trauma* 1995 Nov;39(5):902,7; discussion 907-9.
26. Jimenez E, Martin M, Krukenkamp I, Barrett J. Subxiphoid pericardiotomy versus echocardiography: A prospective evaluation of the diagnosis of occult penetrating cardiac injury. *Surgery* 1990 Oct;108(4):676,9; discussion 679-80.

27. Nicol AJ. Cardiac injuries. Oxford handbook of trauma. In: A. J. Nicol, E. Steyn, editors. 2nd edition ed. Cape Town, South Africa.: Oxford University Press; 2010.
28. Claassen CW, O'connor JV, Gens D, Sikorski R, Scalea TM. Penetrating cardiac injury: think outside the box. *J Trauma* 2010 Mar;68(3):E71-3.
29. Stranch EW, Zarzaur BL, Savage SA. Thinking outside the box: re-evaluating the approach to penetrating cardiac injuries. *Eur J Trauma Emerg Surg* 2016 May 18 [Epub ahead of print].
30. Rozycki GS, Feliciano DV, Ochsner MG, Knudson MM, Hoyt DB, Davis F, Hammerman D, Figueredo V, Harviel JD, Han DC, et al. The role of ultrasound in patients with possible penetrating cardiac wounds: A prospective multicenter study. *J Trauma* 1999 Apr;46(4):543-51; discussion 551-2.

## Figure Legends

Figure 1. Summary of study patients.

Figure 2. Rates of cardiac injury by vertical region between clavicles and xiphoid (regions C, D, and E).

ACCEPTED

**Figure 1**

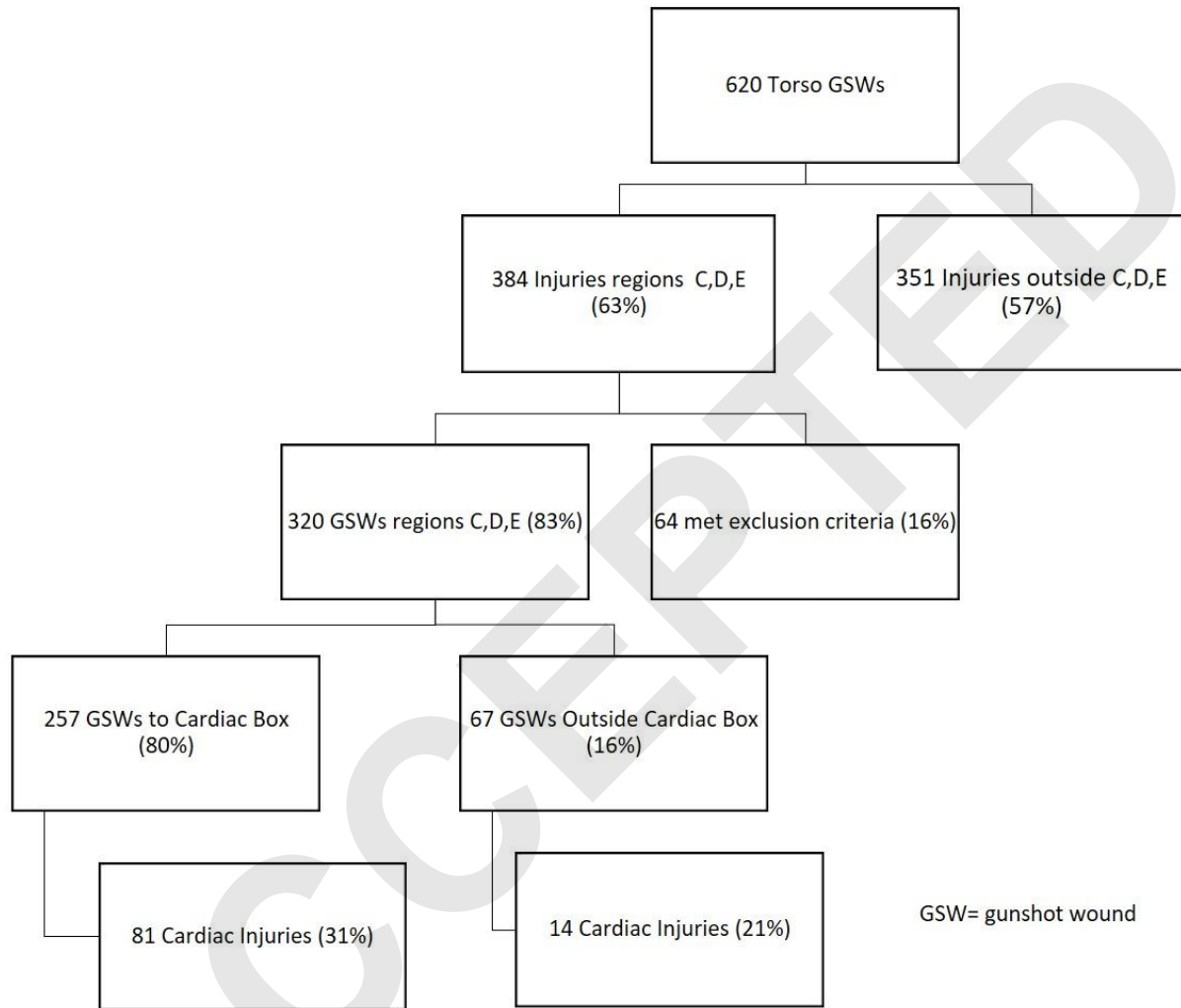


Figure 2

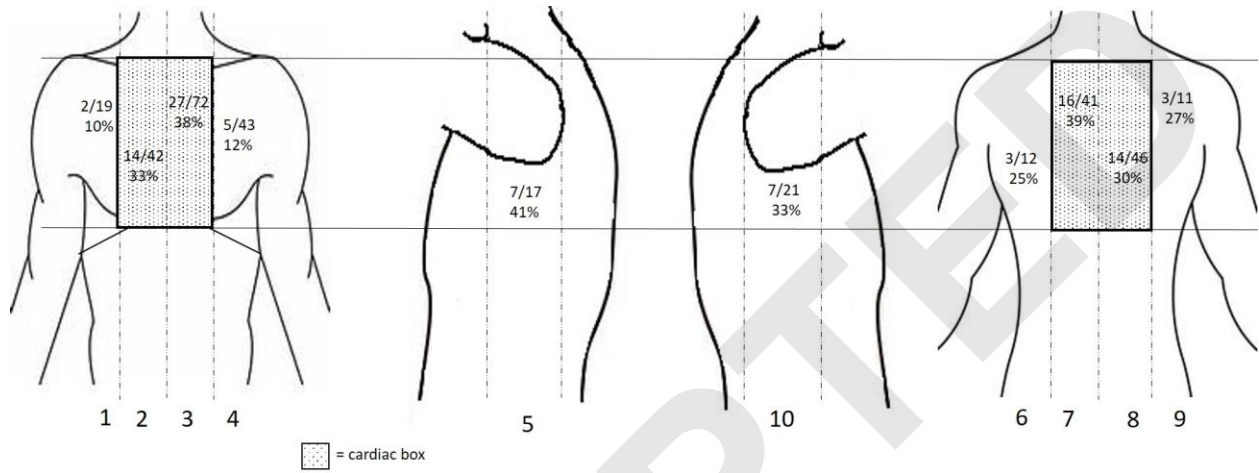


Table I. Anatomic landmarks used to create circumferential grid system for documenting ballistic injuries.

| <b>Vertical region</b>   | <b>From</b>                        | <b>To</b>                            |
|--------------------------|------------------------------------|--------------------------------------|
| <b>1</b>                 | Right anterior axillary line       | → Right anterior midclavicular line  |
| <b>2*</b>                | Right anterior midclavicular line  | → Anterior midline                   |
| <b>3*</b>                | Anterior midline                   | → Left anterior midclavicular line   |
| <b>4</b>                 | Left anterior midclavicular line   | → Left anterior axillary line        |
| <b>5</b>                 | Left anterior axillary line        | → Left posterior axillary line       |
| <b>6</b>                 | Left posterior axillary line       | → Left posterior midclavicular line  |
| <b>7*</b>                | Left posterior mid-clavicular line | → Posterior midline                  |
| <b>8*</b>                | Posterior midline                  | → Right posterior midclavicular line |
| <b>9</b>                 | Right posterior midclavicular line | → Right posterior axillary line      |
| <b>10</b>                | Right posterior axillary line      | → Right anterior axillary line       |
| <hr/>                    |                                    |                                      |
| <b>Horizontal region</b> |                                    |                                      |
| <b>A</b>                 | Top of head                        | → Mandible                           |
| <b>B</b>                 | Mandible                           | → Clavicle                           |
| <b>C*</b>                | Clavicle                           | → 3 <sup>rd</sup> rib                |
| <b>D*</b>                | 3 <sup>rd</sup> rib                | → Nipple line                        |



---

|           |                 |                   |
|-----------|-----------------|-------------------|
| <b>E*</b> | Nipple line     | → Xiphoid process |
| <b>F</b>  | Xiphoid process | → Umbilicus       |
| <b>G</b>  | Umbilicus       | → Groin           |
| <b>H</b>  | Groin           | → Knee            |
| <b>I</b>  | Knee            | → Foot            |
| <b>J</b>  | Shoulder        | → Elbow           |
| <b>K</b>  | Elbow           | → Hand            |

---

ACCEPTED

Table II. Summary of patient demographics.

|                           | n = 263         |
|---------------------------|-----------------|
| Male gender, n (%)        | 232 (87.2)      |
| Age (mean years $\pm$ SD) | 34.2 $\pm$ 15.2 |
| Gunshot victims, n (%)    | 239 (90.1)      |
| Total injuries            | 735             |
| Total GSWs, n (%)         | 620 (84.4)      |
| Dead at scene, n (%)      | 134 (50.4)      |
| Dead on arrival, n (%)    | 122 (46.0)      |
| Homicide, n (%)           | 243 (91.3)      |

SD = standard deviation

GSW = gunshot wound

Table III. Comparison of probability of thoracic GSW causing cardiac injury relative to all other regions.

| <b>Region</b> | <b>n</b> | <b>Cardiac Injury</b> | <b>RR</b> | <b>95% CI</b> | <b>p-value</b> |
|---------------|----------|-----------------------|-----------|---------------|----------------|
| 1             | 19       | 2 (10%)               | 0.32      | (0.09 - 1.20) | 0.09           |
| 2             | 42       | 14 (33%)              | 1.06      | (0.67 - 1.69) | 0.78           |
| 3             | 72       | 27 (38%)              | 1.26      | (0.84 - 1.79) | 0.20           |
| 4             | 43       | 5 (12%)               | 0.34      | (0.15 - 0.78) | 0.01           |
| 5             | 17       | 7 (41%)               | 1.33      | (0.74 - 2.41) | 0.34           |
| 6             | 12       | 3 (25%)               | 0.78      | (0.29 - 2.12) | 0.63           |
| 7             | 41       | 16 (39%)              | 1.28      | (0.84 - 1.96) | 0.24           |
| 8             | 46       | 18 (30%)              | 0.93      | (0.61 - 1.43) | 0.74           |
| 9             | 11       | 3 (27%)               | 0.86      | (0.32 - 2.29) | 0.77           |
| 10            | 21       | 7 (33%)               | 1.06      | (0.56 - 1.99) | 0.84           |

RR = relative risk

CI = confidence interval

Table IV. Comparison of likelihood of a cardiac injury from a gunshot wound to the current “gold standard” cardiac box versus other thoracic regions.

| <b>Region</b>          | <b>RR</b> | <b>95%<br/>CI</b> | <b><i>p</i>-value</b> | <b>Sens<br/>(%)</b> | <b>Spec<br/>(%)</b> | <b>PPV<br/>(%)</b> | <b>NPV<br/>(%)</b> |
|------------------------|-----------|-------------------|-----------------------|---------------------|---------------------|--------------------|--------------------|
| Cardiac Box<br>2,3,7,8 | 0.96      | (0.68 - 1.4)      | 0.82                  | 85                  | 16                  | 35                 | 68                 |
| 2,3,4,5,6,7            | 6.5       | (8.6 - 4.9)       | 0.02                  | 98                  | 12                  | 37                 | 91                 |
| 3,4,5,6,7,8            | 9.9       | (6.6 - 12.5)      | 0.03                  | 99                  | 9                   | 36                 | 94                 |
| 3,4,5,6,7,10           | 3.9       | (1.4-5.4)         | 0.001                 | 94                  | 22                  | 38                 | 87                 |
| 3,4,5,6,7              | 2.9       | (1.3 -4.7)        | 0.01                  | 90                  | 31                  | 41                 | 86                 |
| 3,4,5,7                | 3.5       | (1.5 - 5.5)       | 0.02                  | 86                  | 36                  | 41                 | 84                 |
| 2,3,5,6                | 3.1       | (2.5-3.7)         | 0.001                 | 88                  | 30                  | 40                 | 83                 |
| 2,3,5,7                | 2.9       | (1.9-3.9)         | 0.0001                | 88                  | 25                  | 38                 | 81                 |

RR = relative risk

CI = confidence interval

Sens = sensitivity

Spec = specificity

PPV = positive predictive value

NPV = negative predictive value