

# Multicenter, Prospective, Longitudinal Study of the Recurrence, Surgical Site Infection, and Quality of Life After Contaminated Ventral Hernia Repair Using Biosynthetic Absorbable Mesh

## The COBRA Study

Michael J. Rosen, MD,\* Joel J. Bauer, MD,† Marco Harmaty, MD,† Alfredo M. Carbonell, DO,‡ William S. Cobb, MD,‡ Brent Matthews, MD,§ Matthew I. Goldblatt, MD,¶ Don J. Selzer, MD, MS,|| Benjamin K. Poulouse, MD, MPH,\*\* Bibi M. E. Hansson, MD, PhD,†† Camiel Rosman, MD,†† James J. Chao, MD,‡‡ and Garth R. Jacobsen, MD§§

**Objective:** The aim of the study was to evaluate biosynthetic absorbable mesh in single-staged contaminated (Centers for Disease Control class II and III) ventral hernia (CVH) repair over 24 months.

**Background:** CVH has an increased risk of postoperative infection. CVH repair with synthetic or biologic meshes has reported chronic biomaterial infections and high hernia recurrence rates.

**Methods:** Patients with a contaminated or clean-contaminated operative field and a hernia defect at least 9 cm<sup>2</sup> had a biosynthetic mesh (open, sublay, retrorectus, or intraperitoneal) repair with fascial closure (n = 104). Endpoints included overall Kaplan-Meier estimates for hernia recurrence and postoperative wound infection rates at 24 months, and the EQ-5D and Short Form 12 Health Survey (SF-12). Analyses were conducted on the intent-to-treat population, and health outcome measures evaluated using paired *t* tests.

**Results:** Patients had a mean age of 58 years, body mass index of 28 kg/m<sup>2</sup>, 77% had contaminated wounds, and 84% completed 24-months follow-up. Concomitant procedures included fistula takedown (n = 24) or removal of infected previously placed mesh (n = 29). Hernia recurrence rate was 17% (n = 16). At the time of CVH repair, intraperitoneal placement of the biosynthetic mesh significantly increased the risk of recurrences ( $P \leq 0.04$ ). Surgical site infections (19/104) led to higher risk of recurrence ( $P < 0.01$ ). Mean 24-month EQ-5D (index and visual analogue) and SF-12 physical component and mental scores improved from baseline ( $P < 0.05$ ).

**Conclusions:** In this prospective longitudinal study, biosynthetic absorbable mesh showed efficacy in terms of long-term recurrence and quality of life for CVH repair patients and offers an alternative to biologic and permanent synthetic meshes in these complex situations.

**Keywords:** abdominal wall reconstruction, bioabsorbable mesh, complex ventral hernia repair, contaminated ventral hernia repair

(*Ann Surg* 2017;265:205–211)

Permanent synthetic meshes have been used in clean wounds with low infectious complications and excellent long-term results with low recurrence rates.<sup>1–3</sup> Synthetic meshes are nonabsorbable meshes made of polypropylene (PP), expanded polytetrafluoroethylene, polyester, lightweight PP, or a combination of these materials used to obtain a “tension-free” closure in ventral hernia repairs.<sup>4</sup> However, surgeons are reluctant to implant a permanent foreign material in a patient undergoing a contaminated ventral hernia repair because of the increased risk of postoperative infection, bowel adhesion, mesh extrusion, mesh erosion, fistula formation, seroma development, and pain.<sup>4–6</sup> The most appropriate mesh for hernia repair in clean-contaminated and contaminated wounds is not as clear. Current options have included staged repairs, primary fascial closure, or reinforcement with biologic mesh.<sup>7</sup> The proposed advantage of a biologic mesh is that the patient’s immune cells can infiltrate the material to defend against the bacterial load and eventually replace the biologic mesh with the host tissue.<sup>8</sup> However, the price of biologic grafts has caused an alarming increase in the cost of complex abdominal reconstructions. Additionally, long-term durability of biologic grafts used for complex abdominal wall reconstruction has been disappointing.<sup>7,9</sup>

Long-term absorbable synthetic materials, termed biosynthetic meshes, have recently been introduced as a potential alternative to biologic mesh for use during contaminated abdominal wall reconstructions. Because of their breakdown via hydrolysis, biosynthetic mesh may offer unique advantages when challenged with bacterial colonization during complex abdominal wall reconstruction.<sup>10</sup>

The GORE BIO-A Tissue Reinforcement is a biosynthetic mesh comprised of a bioabsorbable polyglycolide—trimethylene carbonate copolymer, which is gradually absorbed by the body. The open 3-dimensional (3D) matrix structure, with highly interconnected pores, facilitates tissue generation and healing. Degradation occurs via a combination of hydrolytic and enzymatic pathways. In vivo studies with this copolymer indicate that the bioabsorption process should be complete within 6 to 7 months.<sup>11</sup>

From the \*Department of General Surgery, Cleveland Clinic Foundation, Cleveland, OH; †Department of Surgery, Mount Sinai School of Medicine, New York, NY; ‡Division of Minimal Access and Bariatric Surgery, Greenville Health System, Greenville, SC; §Department of Surgery, Carolinas Medical Center, Charlotte, NC; ¶Department of Surgery, Medical College of Wisconsin, Milwaukee, WI; ||Department of Surgery, Indiana University School of Medicine, Indianapolis, IN; \*\*Division of General Surgery, Vanderbilt University Medical Center, Nashville, TN; ††Department of Surgery, Canisius-Wilhelmina Ziekenhuis, Nijmegen, The Netherlands; ‡‡Oasis MD Lifestyle Healthcare, San Diego, CA; and §§Department of Surgery, University California, San Diego School of Medicine, San Diego, CA.

Funding: The study was sponsored by W. L. Gore & Associates, Inc.

Disclosure: The authors report no conflicts of interest.

Supplemental digital content is available for this article. Direct URL citations appear in the printed text and are provided in the HTML and PDF versions of this article on the journal’s Web site ([www.annalsurgery.com](http://www.annalsurgery.com)).

This is an open-access article distributed under the terms of the Creative Commons Attribution-Non Commercial-No Derivatives License 4.0, where it is permissible to download and share the work provided it is properly cited. The work cannot be changed in any way or used commercially.

Reprints: Michael J. Rosen, Professor of Surgery, Lerner College of Medicine, Case Western Reserve, Cleveland Clinic Foundation, 9500 Euclid Avenue A10, Cleveland Ohio 44195. E-mail: [rosenm@ccf.org](mailto:rosenm@ccf.org).

Copyright © 2016 Wolters Kluwer Health, Inc. All rights reserved.

ISSN: 0003-4932/16/26501-0205

DOI: 10.1097/SLA.0000000000001601

The Complex Open Bioabsorbable Reconstruction of the Abdominal Wall (COBRA) study prospectively evaluated the use and performance of GORE BIO-A Tissue Reinforcement, a biosynthetic mesh, for reinforcement of the midline fascial closure in the single-staged repair of contaminated ventral hernias.

## METHODS

### Study Design

This prospective, multicenter, observational study conducted in 9 centers across the United States and the Netherlands, between February 2011 and December 2014, was approved by the Institutional Review Board of all sites. The study is registered on [www.clinicaltrials.gov](http://www.clinicaltrials.gov) # NCT01325792. Informed consent to participate in this study was provided by all patients enrolled. Adult patients with incisional hernias of at least 9 cm<sup>2</sup> by physical examination, undergoing a planned single-staged repair of a ventral/incisional hernia with an operation classified by Centers for Disease Control (CDC) wound criteria as a clean-contaminated or contaminated wound,<sup>12</sup> were eligible for study enrollment. Patients were enrolled if a single unit of biosynthetic mesh (GORE BIO-A Tissue Reinforcement; Flagstaff, Arizona) could adequately reinforce the midline fascial closure with at least 4 cm of lateral overlap.

Patients were excluded from the study if they had a clean (CDC class I) or dirty (CDC class IV) wound, had a laparoscopic repair, pre-existing systemic infection at the time of repair, cirrhosis, renal failure on dialysis, immunocompromised (chronic immunosuppression therapy [prednisone >10 mg/d], solid organ transplant patient, or actively on chemotherapy), diagnosed collagen formation disorder, and a body mass index (BMI) >40 kg/m<sup>2</sup>. Patients who required more than 1 mesh to be quilted together or could not achieve midline fascial closure without excessive tension or requiring planned, multistage repair were excluded.

### Surgical Technique

Surgical repair of the hernia required appropriate bioburden reduction technique with debridement of all nonviable tissue, removal of infected, nonincorporated prosthetic materials (both synthetic and biologic), and reconstruction of the gastrointestinal (GI) tract when appropriate. Defects were measured intraoperatively with a ruler and documented as maximal vertical (cm) and horizontal (cm) dimensions in accordance with the European Hernia Society guidelines.<sup>13</sup> As per study protocol, the biosynthetic mesh was placed as a sublay in either the intraperitoneal or retrorectus position, based on the discretion of the surgeon, to reinforce midline fascial closure. For both intraperitoneal and retrorectus placement, the interrupted, transfascial sutures were placed at least 4 cm from the medial edge of the rectus abdominis muscles bilaterally to secure the biosynthetic mesh so that it spanned the entire midline closure. With either placement, the primary fascia was re-approximated. Surgeons were permitted to perform myofascial releases as deemed necessary, based on the size of the defect, and the resultant tension on the fascial closure. For the purposes of analysis, a component separation was defined as those patients who had an incision in one of the lateral abdominal wall muscles (transversus abdominis or external oblique muscle). An anterior component separation was performed when external oblique muscles were released. A posterior component separation was defined as those patients undergoing incisions in both the posterior rectus sheath and the transversus abdominis muscle. If only the posterior rectus sheath was incised and the dissection was extended to the linea semilunaris and the posterior rectus sheaths were re-approximated to allow the mesh to be placed in retrorectus space as described by Stoppa,<sup>14</sup> it was not considered a

component separation. Anterior rectus sheath incisions that involved simply incising the anterior rectus sheath to provide fascial advancement (not a turnover procedure) were not recommended, but did not constitute a protocol deviation. The exact myofascial releases performed, the location of the mesh, number and placement of drains, and the duration of drains were recorded and managed at the discretion of the surgeon's standard management protocols. The biosynthetic meshes were secured in place with PDS (Ethicon, New Jersey) or MAXON (Covidien, CT) suture using interrupted transfascial sutures. Antibiotics were continued for the first 24 hours according to Surgical Care Improvement Project (SCIP) protocols. Recurrence and complication rates were evaluated by the treating surgeon at 30 days, 6, 12, and 24 months review.

### Endpoints

The primary endpoint was the rate of hernia recurrence, determined by physical examination, at 2 years. Hernia recurrences were recorded if there was a new hernia within 7 cm of the repair, and recurrences were categorized as midline, at the stoma site, or both.<sup>3</sup> Patients who had their intact midline repair violated during the 2-year follow-up period for reasons not related to the index hernia repair were excluded from the final recurrence analysis. For analysis purposes, if the prosthetic material came in contact with a stoma site in patients with a concomitant stoma with or without a parastomal hernia component, it was considered part of the primary repair. Recurrence was evaluated postoperatively at 30 days, 6, 12, and 24 months.

Secondary endpoints included incidence of wound events and quality-of-life assessments. Wound events were classified as surgical site infections based on CDC criteria into superficial, deep, or organ space.<sup>12</sup> Surgical site occurrences were reported based on the Ventral Hernia Working Group definitions.<sup>6,15</sup> Interventions for wound events were categorized as: antibiotics only, bedside wound interventions, percutaneous interventions, or surgical debridement. If surgical debridement was required, prosthetic management was defined as: no intervention, partial resection, or full removal of the biosynthetic mesh.

Quality of life and return of function were measured using the Short Form 12 Health Survey, version 2 (SF-12) and the EQ-5D at baseline, and postoperative day 30 and at 6, 12, and 24 months. The SF-12 measures generic health concepts across age, disease, and treatment groups.<sup>16</sup> The instrument measures health from the patients' point of view by scoring standardized response to standard questions. Eight concepts commonly represented in health surveys are assessed: physical functioning, role functioning physical, bodily pain, general health, vitality, social functioning, role functioning emotional, and mental health. The results of test items scored were normalized and expressed in terms of 2 meta-scores: the Physical Component Summary (PCS) and the Mental Component Summary (MCS). A higher SF-12 score indicates better physical functioning.

The EQ-5D Health Questionnaire—a standardized measure of health status and treatment—consists of 2 scores: the EQ-5D descriptive system and the EQ visual analog scale (EQ-VAS).<sup>17</sup> The EQ-5D descriptive system is comprised of 5 dimensions (mobility, self-care, usual activities, pain/discomfort, and anxiety-depression) and 3 levels (no problems, some problems, and extreme problems). Patients completed the questionnaire based on how good or bad their health was for that day of administration relative to their ventral hernia repair from which a single-digit score described the patients' health state. The EQ-VAS is patient-rated assessment of health on a vertical, visual analog scale on a spectrum of “best imaginable health state” and “worst imaginable health state,” and is quantified as a measure of health outcome as judged by the individual respondents.

## Follow-up

Patients were followed prospectively from the time of surgical repair of their hernia to study completion. All patients were included in long-term quality-of-life analysis regardless of the presence of recurrence, reoperation, or other events. Patient assessments were completed preoperatively (within 30 days of surgery), and postoperatively on day 30 ( $\pm 2$  weeks), and at 6 months, and 1 and 2 years ( $\pm 1$  month).

## Statistical Analysis

The power of the study was based on  $\alpha 0.05$ , an estimate of the 39% recurrence rate of patients with biosynthetic mesh, and an expected rate of 20% loss to follow-up, thus requiring a sample size of 100 patients. The calculation assumed a 50% recurrence rate for those patients undergoing component separation alone in complex ventral hernia repairs, which is in line with that reported in the literature.<sup>18</sup>

All analyses were conducted on the intent-to-treat (ITT) population. Overall recurrence and infection rates were estimated using Kaplan-Meier estimation and log-log 95% confidence intervals (CIs). Numerical variables were summarized using means, medians, standard deviations, quartiles, and 95% CI. Categorical variables were summarized using counts and percentages. Statistical differences for the SF-12 and EQ-5D over time were evaluated using paired *t* tests, using  $P < 0.05$  as the cut-off for statistical significance.

Post hoc evaluations of differences between subgroups were evaluated using Fisher exact tests (for 2 category variables), chi-square tests (for  $\geq 3$  category variables), *t* tests (for numerical variables predefined as normally distributed), Wilcoxon rank-sum tests (for numerical variables predefined as non-normally distributed), log-rank tests (for evaluating Kaplan-Meier estimates of events over time), and Wald tests with Efron ties (for evaluating Cox models of events over time). Statistical analysis was done using SAS Software (Cary, NC), version 9.2.

## RESULTS

A total of 104 patients had hernia repair with a single sheet of biosynthetic mesh, of which 87 (84%) completed the 24-month follow-up period (Supplemental Digital Content Fig. 1 <http://links.lww.com/SLA/A958>). Patient characteristics, comorbid conditions, and wound and hernia defect characteristics at the time of ventral hernia repair are presented in Table 1. Patients had a mean age of 58 years, the majority were women (60%), more than a third were obese (BMI  $> 30$  kg/m<sup>2</sup>) and had a prior wound infection, and 45% had recurrent incisional hernias present (Table 1). Of the surgical wound CDC classifications, 77% were contaminated and 23% were clean-contaminated. A stoma was present in 48% of patients and 21% had a concomitant parastomal hernia repair at the time of midline hernia repair. For the purposes of analysis, a parastomal hernia that the stoma was taken down and moved to another location was considered class III. If the stoma was left in situ and not moved, it was considered a class II. Other reasons for a contaminated wound included repair of a gastrointestinal (GI) fistula, or nonhealing abdominal wound. Concomitant procedures performed during abdominal wall reconstruction included GI reconstruction (bowel resection, enterocutaneous fistula repair, ostomy reversal, and ostomy creation), cholecystectomy, urinary and gynecologic resections, and removal of actively infected mesh. Of the 104 patients who underwent repair of a midline hernia, 22 patients required a concomitant repair of both a midline and parastomal hernia. The mean size and width of hernia defects was 137 cm<sup>2</sup> and 9 cm (Table 1).

Primary fascial closure with a single unit of biosynthetic mesh was achieved in all patients. A concomitant component separation

**TABLE 1.** Patient Demographics, Comorbid Conditions, and Wound and Hernia Defect Characteristics

	n = 104
Preoperative variables (mean)	
Age, y (range)	58 (27–91)
Sex (female), n (%)	62 (60)
Body mass index, kg/m <sup>2</sup> (range)	28 (17–40)
Recurrent hernia repaired, n (%)	47 (45)
Comorbid conditions, n (%)	
Previous abdominal wall infection	36 (35)
Obesity	35 (34)
Inflammatory bowel disease	27 (26)
Active smoking	20 (19)
Diabetes mellitus	19 (18)
Chronic obstructive pulmonary disease	11 (11)
Perioperative variables	
Contamination, n (%)	
Clean-contaminated wound (CDC class II)	24 (23)
Contaminated wound (CDC class III)	80 (77)
Reasons for contamination*, n (%)	
Presence of a stoma	50 (48)
Bowel resection	32 (31)
Infected mesh removal	29 (28)
Repair of gastrointestinal fistula	24 (23)
Nonhealing abdominal wound	24 (23)
Ostomy reversal	23 (22)
Parastomal hernia repair	22 (21)
Urologic and gynecologic procedure	8 (8)
Diverting ostomy procedure	7 (7)
Cholecystectomy	6 (6)
Hernia defect characteristics, mean (range)	
Defect size, cm <sup>2</sup>	137 (10–513)
Defect width, cm	9 (3–25)

\*Patients may have had more than one reason for contamination.  
CDC indicates Centers for Disease Control and Prevention.

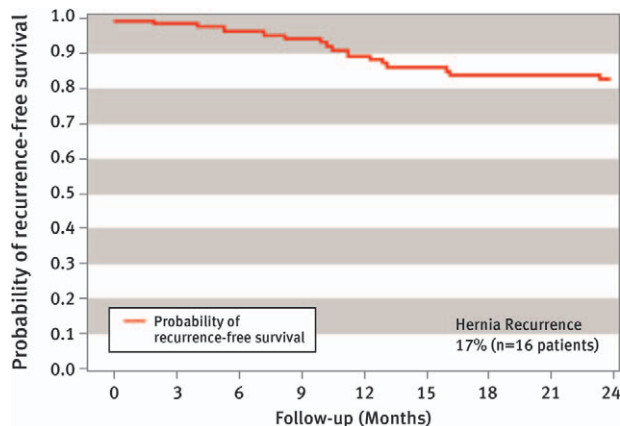
was performed in 68 patients, which included external oblique release (n = 21) and transversus abdominus release (n = 50) (Table 2). Thirty patients had a posterior rectus sheath incision alone with retromuscular mesh placement as described by Stoppa.<sup>14</sup> Three patients had an anterior rectus sheath incision.

The placement of the biosynthetic mesh was left to the discretion of the surgeon and a clear trend emerged for placement of the mesh in the retrorectus position. Only 10% of the biosynthetic meshes were placed in the intraperitoneal position. The mean operative time was 244 minutes and median length of hospital stay was 7 days. Extended hospitalization was required for 1 patient with acute respiratory distress syndrome requiring prolonged intubation. Drains placed in the retrorectus space in contact with the mesh were

**TABLE 2.** Operative Characteristics

Variables	Intent-to-treat Population (n = 104)
Mean operating time, min (range)	244 (60–505)
Component separation, n (%)	
Posterior component separation	50 (48)
Anterior component separation	21 (20)
Placement of biosynthetic mesh	
Retrorectus location, n (%)	94 (90)
Intraperitoneal location, n (%)	10 (10)
Median hospital stay, d (range)	7 (3–92)
Mean days to drain removal, d (range)	12 (2–33)





**FIGURE 1.** Kaplan-Meier estimate of freedom from postoperative hernia recurrence: all participants (n remaining at risk = 85 and 74 patients at 12 and 24 months, respectively).

removed an average of 12 days after surgery (Table 2). Five deaths occurred during the study, of which 4 succumbed to cancer (glioblastoma, GI stromal tumor, lung cancer, and metastatic cancer) and 1 had a history of cancer from an unknown site. Five patients had another operation during the study period in which their midline repair was disrupted for reasons of complications related to Crohn disease, removal of previously placed biologic and permanent synthetic mesh that had been left at index operation and was infected, anastomotic leak, and leaking ileostomy site.

**Hernia Recurrence**

The Kaplan-Meier analysis overall hernia recurrence rate in the ITT population (n = 104) was 17% (n = 16 patients) at the 24-month follow-up period (Fig. 1). The 16 recurrences included occurrence at the midline hernia (n = 13) and 3 parastomal sites (n = 3). When estimating only midline hernia recurrence, the Kaplan-Meier recurrence rate at 24 months was 14%. The recurrence rate was higher in patients with mesh placement in the intraperitoneal position (40%; 4/10) versus those with placement in the retrorectus position (13% [12/94]; P = 0.0451). Cox hazard ratio (HR) analysis for predictive baseline risk factors revealed increased risks for hernia recurrence for intraperitoneal mesh placement (HR = 3.41 [95% CI, 1.098–10.590]; P = 0.0339) compared with retrorectus placement. Time to hernia recurrence was shorter for patients with postoperative infection than those patients without (P = 0.0098) (Supplemental Digital Content Fig. 2 <http://links.lww.com/SLA/A958>) and with parastomal compared with midline hernia recurrences (P < 0.0001) (Supplemental Digital Content Fig. 3 <http://links.lww.com/SLA/A958>). Significant baseline risk factors for hernia recurrence are shown in Table 3.

**TABLE 4.** Postoperative Wound Events and Surgical Site Infections\*

Variables	n = 104
Wound events*, n (%)	33 (28)
Surgical site infection†	21 (18)
Seroma	6 (6)
Fistula	2 (2)
Bowel obstruction	2 (2)
Wound dehiscence	1 (1)
Hematoma	1 (1)
Postoperative infections†, n (%)	21 (18)
Superficial incisional infections	9 (9)
Deep incisional infections	10 (10)
Organ space infections	2 (2)

\*Patients may have had more than one wound event.  
 †Categorized by CDC criteria; 21 infections occurred in 19 patients.  
 CDC indicates Centers for Disease Control.

**Postoperative Wound Events**

A postoperative wound event developed in 29 patients. The 21 surgical site infection events that occurred in 19 patients were categorized by the CDC criteria (Table 4). In all cases, superficial surgical site infections (n = 9) resolved with oral or intravenous antibiotics. Deep surgical site infections (n = 10) required percutaneous drainage alone (n = 6), minor operative debridement (n = 3), and wide wound debridement with partial mesh excision (n = 1). Two organ space infections occurred in patients with a leak from a GI anastomosis in the early postoperative period and were unrelated to the biosynthetic mesh. No cases required complete explantation of the biosynthetic mesh. All wounds were completely healed at long-term follow-up. Other wound events included development of a postoperative seroma (n = 6), which resolved spontaneously (n = 3) or required percutaneous drainage and eventually resolved (n = 3). Two recurrent enterocutaneous fistulas developed in patients undergoing takedown of an enterocutaneous fistula and were felt to be unrelated to the biosynthetic mesh. Two postoperative bowel obstructions occurred in patients with mesh placed in the retrorectus position. One occurred during the primary hernia repair and resolved after re-exploration and revision of the anastomosis. The second occurred 212 days after hernia repair and was resolved with complete adhesiolysis of the GI tract.

Post hoc analysis for predictive baseline or operative risk factors for postoperative infections were significant (all P ≤ 0.05) for diabetes mellitus (HR = 2.969; 95% CI, 1.169–7.544), GI fistula takedown (HR = 4.486; 95% CI, 1.820–11.058), and mesh present from prior repair (HR = 2.666; 95% CI, 1.049–6.775). The only significant predictor of deep surgical site infection was the presence of a GI fistula (HR = 5.605 [95% CI, 1.581–19.874]; P = 0.0076) during ventral hernia repair.

**TABLE 3.** Recurrence and Risk Baseline Factors for Postoperative Hernia Recurrence

Variables	Intent-to-treat Population (n = 104)		P
	Patients With Hernia Recurrence (n = 16)	Patients Without Hernia Recurrence (n = 88)	
<b>Hernia Recurrence, n (%)</b>		<b>16 (15.4)</b>	
<b>Risk Baseline Factors</b>			
BMI (kg/m <sup>2</sup> ), mean (range)	30 (22–39)	27 (17–40)	0.046
Defect length (cm), mean (range)	11 (5–20)	15 (3–27)	0.044
Postoperative superficial incisional wound infection, n (%)	5 (31%)	4 (5%)	0.004

**TABLE 5.** Patient-reported Outcomes (Change in Scores From Baseline Over 24 Months)

Variable, Mean	Baseline	Mean Change			
		Month 1	Month 6	Month 12	Month 24
EQ-5D Index	0.73	-0.02	0.10*	0.10*	0.11*
EQ-5D VAS	63.9	-0.7	9.0*	8.4*	10.1*
SF-12 Physical	38.6	-3.9*	4.5*	6.2*	4.9*
SF-12 Mental	42.2	0.6	1.7	3.3*	3.7*

\* $P < 0.05$ .  
SF-12 indicates Short Form 12 Health Survey; VAS, visual analog scale.

### Patient-reported and Quality-of-life Outcomes

Patients reported overall sustained improvement in health over the 2-year follow-up period as measured by the EQ-5D Index, EQ VAS, and SF-12 scores (Table 5, Supplemental Table 1 <http://links.lww.com/SLA/A958>). The increase from baseline on the EQ-5D Index, EQ VAS, and the SF-12 Physical scores was significant ( $P < 0.05$ ) at 6 months postoperatively, and improvement was sustained at the 12 and 24-month ( $P < 0.05$ ) follow-up time points (Supplemental Digital Content Figs. 4, 5, and Fig 6 <http://links.lww.com/SLA/A958>). Patients without stomas versus with stomas at baseline or with an infected mesh removed versus not at the time of surgery reported significantly greater improvement on the SF-12 physical score ( $P < 0.05$ ). Stratification of the SF-12 physical score by hernia recurrence, or infections during study, did not reveal significant differences (Fig. 2). The increase from baseline for the SF-12 Mental score was significant at 12 and 24 months ( $P < 0.05$ ) (Supplemental Digital Content Fig. 7 <http://links.lww.com/SLA/A958>).

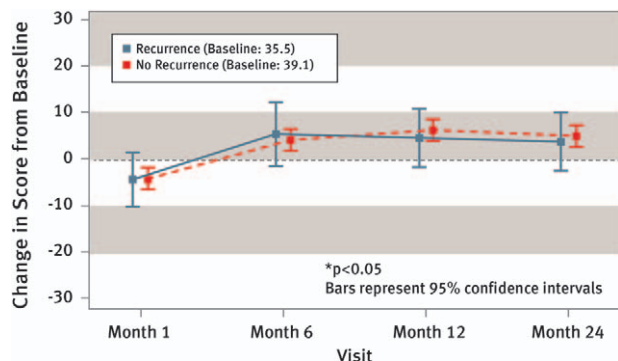
### DISCUSSION

This prospective COBRA study demonstrated that the biosynthetic mesh, GORE BIO-A Tissue Reinforcement, performed well in the reinforcement of the midline fascial closure in the single-staged repair of contaminated ventral hernias. Overall, hernia recurrence occurred in 16 patients with a Kaplan-Meier recurrence rate of 17% at 24 months.

Prospective, longitudinal, or randomized clinical studies evaluating outcomes for ventral hernia repair utilizing biologic mesh in

clean, clean-contaminated, contaminated, or infected wounds are deficient. In fact, the Repair of Infected and Contaminated Hernias (RICH) trial is the only long-term, multicentered, prospective trial to evaluate biologic mesh in CDC class II to IV wounds.<sup>9</sup> The RICH trial reported 66% surgical site occurrence and 28% hernia recurrence (ITT) after 2 years follow-up in patients who underwent ventral hernia repair with a noncross-linked porcine dermis. Hernia recurrence rate based on clinical assessment was 19% at 1 year and 28% at 2 years. The most provocative outcome was that operative technique had a significant influence on recurrence. Despite the use of myofascial release as described by Ramirez (anterior component separation release), facial closure was not completed in 19% of the repairs. The recurrence rate in “bridged” ventral hernia repairs was 45%. In addition, location of mesh placement seemed to influence recurrence rates in a similar fashion to the COBRA study, with a higher rate of recurrence when the biologic mesh was placed intraperitoneally as compared with a retrorectus position.<sup>19</sup> The primary endpoint in the COBRA study was ventral hernia recurrence. Based on Kaplan-Meier analysis, the overall hernia recurrence rate was 17% at 24 months—almost 11% less than in the RICH trial. Similar to the RICH trial, hernias repaired with intraperitoneal mesh placement in the COBRA study had a higher recurrence rate (3.41-fold increase). The overall reduction is likely due to technique as all patients in the COBRA study had primary fascial closure and 90% had retrorectus placement. In a nationwide prospective study of outcomes after elective incisional hernia repair, intraperitoneal placement of synthetic mesh had a cumulative reoperation rate for recurrence that was significantly greater than onlay or sublay (retrorectus) mesh placement.<sup>20</sup> Expertise is required to perform retrorectus or preperitoneal dissection and perforator sparing anterior component separation release or transversus abdominus/posterior component separation release. This may limit more universal application of advanced ventral hernia repair techniques that ultimately improve patient outcomes. Another randomized study using component separation technique to repair clean (CDC class I) or clean-contaminated (CDC class II) ventral hernias reported 53% of patients had development of a major wound complication postoperatively and hernia recurrence at 36 months.<sup>18</sup> A meta-analysis of the randomized study in addition to small retrospective studies with component separation used to repair large abdominal wall defects reported 24% morbidity rate and at 1 year and the hernia recurrence rate of 18%. Most of the repairs reported from these studies did not include use of a synthetic, biologic, or biosynthetic mesh.<sup>18,21</sup>

Achieving value, outcomes important to patients at a cost the healthcare market is willing to pay, has become an imperative in our unsustainable model of volume-based reimbursement for healthcare delivery. Biologic mesh has increased the cost of ventral hernia repair significantly. A recent study at the University of Kentucky reported that the median contribution margin for “complicated” open ventral hernia repairs (CPT codes 49560, 49561, 49565, and 49566) utilizing biologic mesh was -\$4560, and the median net financial loss was



**FIGURE 2.** Change in SF-12 physical score from baseline stratified by hernia recurrence during study ( $n = 10$  for patients with hernia recurrence evaluated at 12 and 24 months;  $n = 55$  and 49 for patients without hernia recurrence evaluated at 12 and 24 months, respectively). SF-12 indicates Short Form 12 Health Survey.

\$8370.<sup>22</sup> Recurrence rates have a tremendous financial impact on healthcare expenditures. It was estimated by Poulouse et al<sup>23</sup> that a 1% reduction in hernia recurrence would result in at least a US \$32 million yearly savings in procedural costs. These studies highlight the need for more cost-effective alternatives to biologic mesh for ventral hernia repair. Outcomes evaluating large-pore, reduced-weight synthetic mesh in clean-contaminated and contaminated ventral hernia repairs have been published. Carbonell et al<sup>24</sup> reported primary outcomes of surgical site infection, surgical site occurrence, need for mesh removal, and hernia recurrence in 100 patients with CDC class II to III wounds undergoing ventral hernia repair with retrorectus mesh placement. The overall incidence of surgical site occurrence was 31%, higher in the contaminated than in the clean-contaminated cases. The 30-day surgical site infection rate was 14%. Their recurrence rate was 7% (ITT) at mean follow-up of  $10.8 \pm 9.9$  months (range 1–63 mo). Mesh removal was required in 4 patients. The authors hypothesized that the overall cost for the 100 pieces of  $30 \times 30$  cm large-pore, reduced-weight synthetic mesh at 15 cents/cm<sup>2</sup> to repair the ventral hernias, was equivalent to the cost of one single piece of biologic mesh (\$10,000). Despite the significant potential for reduction in healthcare expenditures with the use of synthetic mesh in these patients, it is off-label to use synthetic mesh in clean-contaminated, contaminated, or infected wounds. As such, the surgical community is reluctant to do so until high-level clinical outcomes data are available. Furthermore, large-pore, reduced-weight mesh does have its limitations. Petro et al<sup>25</sup> described 7 patients with central mesh failure after ventral hernia repair with lightweight monofilament polyester mesh placed in the retrorectus position with complete posterior and anterior fascial coverage. In clean or CDC class I wounds, a prospective randomized trial demonstrated a trend ( $P = 0.052$ ) toward an increased recurrence rate for large-pore, lightweight mesh (17%) compared with “standard” mesh (7%) for retrorectus ventral hernia repairs.<sup>26</sup>

An alternative to biologic mesh for the repair of clean-contaminated and contaminated ventral hernia repairs is absorbable synthetic mesh. Constructive remodeling, a balance between scaffold degradation and collagen deposition with biomechanical integrity and resistance without evidence of biomaterial “footprint” long-term, is a potential benefit of absorbable materials, whether biologic or synthetic. Absorbable synthetic mesh has the prospective advantages of a reduced cost, minimal constraints in manufacturing alternative sizes (lengths, widths, and thicknesses), informed consent in certain religious or cultural groups, and ability to be iterative in generational improvements in mesh constructs based on outcome studies compared allogeneic or xenogeneic mesh. The absorption profile of the synthetic mesh, degradation versus time, may alter “constructive remodeling,” but comparative biomechanical data are not available.

In the past, surgical studies strictly assessed clinical outcomes without recognizing the impact of disease, convalescence from treatment, and resolution of symptoms have on patients. During the past decade, many have recognized this important aspect of surgical treatment necessitated recording and reporting. As a result, a greater focus has been made on assessing quality of life surrounding surgical procedures. Some groups have gathered significant data and have successfully generated quality-of-life assessment tools specific to a surgical procedure or a disease process. Although beneficial, these disease-specific instruments limit the ability to compare results from one event (eg, a hernia repair) to another, thereby impacting generalizability of the results.

This study utilized general quality-of-life assessment tool—the SF-12—and it introduced the EQ-5D and EQ-5D VAS in the hernia repair literature. Both instruments demonstrated sustained improvement in physical health, from the preoperative to 6-month

postoperative time points onto the 24-month time point. Not surprisingly, assessment of physical health at 1 month after surgery showed an initial drop as patients still contended with postoperative discomfort. However, the results seen in the SF-12 mental health domain suggested a more complex impact of hernia repair on these patients. For example, participants in the study group underwent both hernia repair and another procedure that included addressing an ongoing active infection or a procedure that frequently involved an intestinal procedure. One may hypothesize, these patients remained cautiously optimistic initially after surgery. However, they were reluctant to truly feel at ease well past the repair, having experienced problems after previous operations. Conditioning from previous bad experience, even if after only one such event, has permanently limited their ability to approach convalescence positively.

Considering this side effect of previous experience, one must recognize the limitations of outcomes research in patients with complex ventral hernia repair. The definition of a successful outcome is not clear. Whereas the surgeon often measures success by the absence of recurrence, patients often do not interpret their outcomes in a similar fashion. For example, a patient with a large recurrent defect, an enterocutaneous fistula, and an infected mesh with daily foul-smelling drainage likely, has a completely different outlook on their repair and the measure of success. For this patient, the resolution of the infection and reconstruction of the GI tract is the most important measure of success, and a small asymptomatic recurrence at 24 months is of little consequence.

This study is not without limitations. First, the selected study format of a longitudinal observation of a patient cohort potentially limits the ability to apply these results. Lack of a control group or any element of randomization does introduce an opportunity to suggest that alternative mesh options, including a biologic product, could provide a similar outcome. Second, the duration of follow-up of 24 months is a commonly selected time point, but it is well understood that the longer hernia repair patients are followed, the greater the rate of recurrence. However, the product used in this study undergoes hydrolysis, as it is replaced with vascularized soft tissue. This process is generally considered to have completed by 6 to 7 months. Therefore, the 24-month window seems to provide a more than adequate time period for recurrence to develop. Third, the diversity of hernia size may represent a challenge to draw conclusions. Inclusion criteria allowed hernias as small as 9 cm<sup>2</sup>. However, the mean defect size was 137 cm<sup>2</sup>, with a range from 10 to 513 cm<sup>2</sup>. So, the majority of hernias were well in excess of this minimum. Fourth, the clinical characteristics of patients varied within the study group, with several patients undergoing straightforward, clean-contaminated cases simultaneous to hernia repair, whereas others underwent contaminated cases that addressed infected mesh removal. Arguably, this could have also been approached with separated cohorts. Fifth, there are still inherent limitations of outcomes research (eg, quality-of-life indices) in patients with complex ventral hernia repair. The definition of a successful outcome is not as clear as would be desired. Sixth, physical examination, although an appropriate standard for assessment, is not as accurate as a computerized tomogram (CT). Routine postoperative CT examination of the abdominal wall would have been more accurate. However, this approach to hernia assessment has proven controversial as well. In some studies, the CT findings were not associated with sign or symptoms of a hernia. The clinical relevance of this scenario is not clear and in fact raises more questions than not. Therefore, relying on clinical evaluation with questioning and physical examination is more appropriate. Finally, the generalizability of any multicenter prospective trial or for that matter randomized controlled trial is always subject to real-time data and experience.

In conclusion, despite a longitudinal cohort format, the impact of this study should not be underestimated. This prospective study demonstrated that the biosynthetic mesh for reinforcement of the midline fascial closure in the single-staged repair of contaminated ventral hernias had low hernia recurrence and postoperative wound infection rates, particularly in light of a patient population with CDC class II and III wounds. The use of a biosynthetic alternative to biologic mesh provides a clear opportunity for reducing costs in caring for these complex patients.

### ACKNOWLEDGMENTS

The authors thank Millie S. Hollandbeck (Phoenix, AZ) for providing grammatical support during the writing of this manuscript.

### REFERENCES

- Cobb WS, Carbonell AM, Kalbaugh CL, et al. Infection risk of open placement of intraperitoneal composite mesh. *Am Surg*. 2009;75:762–767.
- Hawn MT, Snyder CW, Graham LA, et al. Long-term follow-up of technical outcomes for incisional hernia repair. *J Am Coll Surg*. 2010;210:648–655.
- Luijendijk RW, Hop WC, van den Tol MP, et al. A comparison of suture repair with mesh repair for incisional hernia. *N Eng J Med*. 2000;343:392–398.
- Park AE, Roth JS, Kavac SM. Abdominal wall hernia. *Curr Probl Surg*. 2006;43:326–375.
- Baillie DR, Stawicki SP, Eustance N, et al. Use of human and porcine dermal-derived bioprosthesis in complex abdominal wall reconstructions: a literature review and case report. *Ostomy Wound Manage*. 2007;53:30–37.
- Ventral Hernia Working Group, Breuing K, Butler CE, Ferzoco S, et al. Incisional ventral hernias: review of the literature and recommendations regarding the grading and technique of repair. *Surgery*. 2010;148:544–558.
- Rosen MJ, Krpata DM, Ermlich B, et al. A 5-year clinical experience with single-staged repairs of infected and contaminated abdominal wall defects utilizing biologic mesh. *Ann Surg*. 2013;257:991–996.
- Burns NK, Jaffari MV, Rios CN, et al. Non-cross-linked porcine acellular dermal matrices for abdominal wall reconstruction. *Plast Reconstr Surg*. 2010;125:167–176.
- Itani KM, Rosen M, Vargo D, et al., RICH Study Group. Prospective study of single-stage repair of contaminated hernias using a biologic porcine tissue matrix: the RICH Study. *Surgery*. 2012;152:498–505.
- Kim H, Bruen K, Vargo D. Acellular dermal matrix in the management of high-risk abdominal wall defects. *Am J Surg*. 2006;192:705–709.
- Katz AR, Mukherjee DP, Kaganov AL, et al. A new synthetic monofilament absorbable suture made from poly(trimethylene carbonate). *Surg Gynecol Obstet*. 1985;161:213–222.
- Mangram AJ, Horan TC, Pearson ML, et al. Guideline for prevention of surgical site infection, Hospital Infection Control Practices Advisory Committee. *Infect Control Hosp Epidemiol*. 1999;20:250–278.
- Muysoms FE, Miserez M, Berrevoet F, et al. Classification of primary and incisional abdominal wall hernias. *Hernia*. 2009;13:407–414.
- Stoppa RE. The treatment of complicated groin and incisional hernias. *World J Surg*. 1989;13:545–554.
- Kanters AE, Krpata DM, Blatnik JA, et al. Modified hernia grading scale to stratify surgical site occurrence after open ventral hernia repairs. *J Am Coll Surg*. 2012;215:787–793.
- Ware J Jr, Kosinski M, Keller SD. A 12-Item Short-Form Health Survey: construction of scales and preliminary tests of reliability and validity. *Med Care*. 1996;34:220–233.
- EuroQol Group. EuroQol: a new facility for the measurement of health-related quality of life. *Health Policy*. 1990;16:199–208.
- de Vries Reilingh TS, van Goor H, Charbon JA, et al. Repair of giant midline abdominal wall hernias: “components separation technique” versus prosthetic repair: interim analysis of a randomized controlled trial. *World J Surg*. 2007;31:756–763.
- Rosen MJ, Denoto G, Itani KM, et al. Evaluation of surgical outcomes of retrorectus versus intraperitoneal reinforcement with bio-prosthetic mesh in the repair of contaminated ventral hernias. *Hernia*. 2013;17:31–35.
- Helgstrand F, Rosenberg J, Kehlet H, et al. Nationwide prospective study of outcomes after elective incisional hernia repair. *J Am Coll Surg*. 2013;216:217–228.
- de Vries Reilingh TS, Bodegom ME, van Goor H, et al. Autologous tissue repair of large abdominal wall defects. *Br J Surg*. 2007;94:791–803.
- Reynolds D, Davenport DL, Korosec RL, et al. Financial implications of ventral hernia repair: a hospital cost analysis. *J Gastrointest Surg*. 2013;17:159–166.
- Poulose BK, Shelton J, Phillips S, et al. Epidemiology and cost of ventral hernia repair: making the case for hernia research. *Hernia*. 2012;16:179–183.
- Carbonell AM, Criss CN, Cobb WS, et al. Outcomes of synthetic mesh in contaminated ventral hernia repairs. *J Am Coll Surg*. 2013;217:991–998.
- Petro CC, Nahabet EH, Criss CN, et al. Central failures of lightweight monofilament polyester mesh causing hernia recurrence: a cautionary note. *Hernia*. 2015;19:155–159.
- Conze J, Kingsnorth AN, Flament JB, et al. Randomized clinical trial comparing lightweight composite mesh with polyester or polypropylene mesh for incisional hernia repair. *Br J Surg*. 2005;92:1488–1493.