

Hindawi Publishing Corporation
BioMed Research International
Volume 2014, Article ID 296498, 7 pages
<http://dx.doi.org/10.1155/2014/296498>



Clinical Study

Coating of Mesh Grafts for Prolapse and Urinary Incontinence Repair with Autologous Plasma: Exploration Stage of a Surgical Innovation

Dimitri Barski,¹ Holger Gerullis,^{1,2} Evangelos Georgas,¹ Andreas Bär,³ Bernhard Lammers,³ Albert Ramon,⁴ Dirk Ysebaert,⁵ Bernd Klosterhalfen,⁶ Mihaly Boros,⁷ and Thomas Otto^{1,2}

¹ Department of Urology, Lukas Hospital, 41464 Neuss, Germany

² German Centre for Assessment and Evaluation of Innovative Techniques in Medicine (DZITM), 41464 Neuss, Germany

³ Department of Surgery, Lukas Hospital, 41464 Neuss, Germany

⁴ ITERA (International Tissue Engineering Research Association), 2000 Antwerpen, Belgium

⁵ Department of Surgery, University of Antwerpen, 2000 Antwerpen, Belgium

⁶ German Centre for Implant-Pathology, 52351 Düren, Germany

⁷ Department of Experimental Surgery, University of Szeged, H-6720 Szeged, Hungary

Correspondence should be addressed to Dimitri Barski; dbarski@lukasneuss.de

Received 27 June 2014; Accepted 17 August 2014; Published 16 September 2014

Academic Editor: Uwe Klinge

Copyright © 2014 Dimitri Barski et al. This is an open access article distributed under the Creative Commons Attribution License, which permits unrestricted use, distribution, and reproduction in any medium, provided the original work is properly cited.

Purpose. Optimized biocompatibility is a major requirement for alloplastic materials currently applied for stress urinary incontinence (SUI) and pelvic organ prolapse (POP) repair. In the preliminary studies the mesh modification by coating with autologous plasma resulted in the increased adherence score *in vitro* and improved biocompatibility in an animal model. The first use of plasma coated meshes in human is presented. **Materials and Methods.** Between 04/2013 and 05/2014, 20 patients with the indication for SUI and POP repair were selected in a single institution. The applied meshes were modified by autologous plasma coating prior to implantation. A retrospective chart review for peri- and early postoperative complications was performed. Functional outcome and QoL were evaluated pre- and postoperatively. **Results.** The functional outcome and QoL improved significantly in all groups. Two reoperations (Grade IIIB) with the release of TVT-mesh in anesthesia due to the obstruction were needed. No other severe complications were registered. **Conclusion.** For the first time we applied a mesh modification in a human setting according to IDEAL criteria of surgical innovations. The procedure of mesh coating with autologous plasma is safe and a prospective randomized trial proving a positive effect of plasma coating on the biocompatibility and morbidity outcome with long-term registry is planned.

1. Introduction

Currently the approval of medical devices as surgical meshes is regulated by American Food and Drug Administration (FDA) and European guidelines according to risk classification. Clinical trials and postmarket followup were not required for the commercial approval. In a Public Health Notification (PHN), from 2008, the FDA reported more than 1000 unexpected and severe adverse events, associated with transvaginal placement of surgical mesh to treat POP and SUI. In

2011, a second FDA warning has been amended, proposing an upgrading in risk classifications for meshes, which would allow the request of premarket approval and postmarket surveillance studies [1].

Meshes or grafts potentially add to the complication profile the aspects of trauma of insertion, foreign body reaction to the implant in terms of inflammation, infection and/or rejection, and the stability of the prosthesis over time [2]. Polypropylene meshes (Type 1, Amid-classification) are usually used for vaginal repair of POP and SUI [3]. The rate of

TABLE 1: Material and biomechanic characteristics of selected meshes [7, 9, 10, 14, 28–31].

Mesh	Material	Biomechanic characteristics	Adhesion score (Melman)	Adhesion score after coating with plasma (Melman)
Seretim PA, Serag Wiessner	Monofilament polypropylene, polyglycol acid, and caprolacton	Partly absorbable (90–120 days) Pore size: 5800 μm (11 mm^2) Weight: 15 g/m^2 (after resorption) Thickness: 0.5 mm Tear resistance (F_{max}): 80 N	2.5	Pending
Vitamesh, ProxyBiomedical	Monofilament polypropylene	Nonabsorbable Weight: 35 g/m^2 Pore size: 2410 μm Thickness: 0.25 mm Tear resistance (F_{max}): 33.7 N	1.6	1.9
UltraPro, Ethicon	Monofilament polypropylene reinforced with poliglecaprone fibers (Monocryl)	Partly absorbable (90–120 days) Pore size: 3000–4000 μm Weight: 28 g/m^2 (after resorption) Thickness 0.5 mm Tear resistance (F_{max}): 69 N	1.4	1.6
TVT, Johnson and Johnson	Monofilament polypropylene	Nonabsorbable Pore size: <1000 μm Weight: 105–110 g/m^2 Thickness: 0.7 mm Tear resistance (F_{max}): about 10N	1	1.6

mesh-related complications after transvaginal mesh application for POP is about 15–25% and especially mesh erosion up to 10% for these indications [4, 5]. Most common complications after MUS (midurethral sling) are obstruction, *de novo* urge, chronic pain, dyspareunia, and mesh erosion [6]. The complications are attributed to a considerable extent to the wrong indication and faulty surgical techniques; material properties are the other reasons. The choice of the optimal mesh for a particular indication with the highest functionality (hold shape) as well as minimized side effects remains difficult. Mesh material (type of polymer, pore size, and material weight, etc.) and its biocompatibility were detected to be crucial parameters [7, 8]. A biocompatibility is described by the foreign body reaction (FBR) at the host-tissue/biomaterial interface. The dynamic of the FBR is given by the inflammatory host response depending on the biomaterial composition (Table 1) [7, 9, 10]. The current understanding about an optimized surgical mesh describes a material that permits the transmigration and localisation of beneficial host cells and if directly exposed to visceral organs, vessels, or nerves it strongly inhibits the adherence of the respective organs in order to avoid erosion, foreign body provoked pain, and so forth. Inert (Titan), (partly) absorbable, light-weight materials are currently under development. Sophisticated methods, like preoperative coating of meshes with a protective layer on the visceral side of the mesh, have been frequently investigated, mostly *in vivo* [11, 12]. They seem to present a potential approach to reduce foreign body reaction and improve biocompatibility and therefore have been introduced in mesh applying surgery.

In a considerably narrow time frame, reacting to the first and second FDA warnings, our international scientific collaboration group has recently developed and concluded

preliminary studies in order to investigate and improve biocompatibility of surgical meshes. Our entire innovative approach has been conducted following the five-step *IDEAL* model for surgical innovations (*Innovation, Development, Exploration, Assessment, and Long-term study*) with the aim of maintaining it comparable and reproducible at every single step of development [13]. A validated *in vitro* test system to compare biocompatibility features of different meshes has been developed (*Idea*, first stage) [9]. This test system was subsequently expanded, to show that mesh modification by autologous plasma coating results in higher biocompatibility and adherence score *in vitro* [9, 10]. The predictability of these approaches, biocompatibility evaluation, and improvement by plasma coating could then be validated and confirmed in a two-year large animal study (*Development*, second stage) [14]. In particular, an early inflammation reaction seems to be influenced by the coating procedure [15]. Herewith we present a consecutive study on the first clinical assessment of meshes modified by autologous plasma coating in human (*Exploration*, third stage).

2. Materials and Methods

Patients (age > 18 y) with surgical indication for SUI (Stamey grade \geq I) and POP (POP-Q Grades I–III and anterior and apical prolapse) repair with mesh were selected after the informed consent. In case of POP and SUI a concomitant *Burch* colposuspension was performed. All patients experienced an unsuccessful treatment with medicaments and physiotherapy prior to operation. The male patients presented a moderate SUI (grade I-II, 2–6 pads/day) after radical prostatectomy. Urodynamics and urethrocystoscopy were performed prior to the operation and a partial defect of the

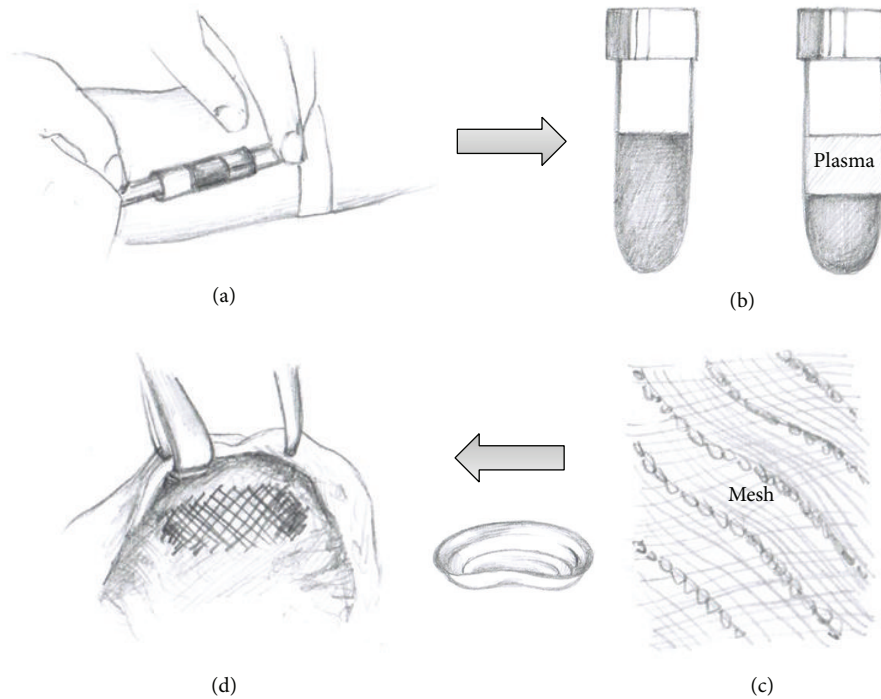


FIGURE 1: The technique of mesh coating with autologous plasma. (a) Vein puncture, 20–40 mL blood is obtained in EDTA-tube before anesthesia. (b) Centrifugation of blood sample in the operation room. (c) Plasma is abstracted and incubated with the mesh in a bowl. (d) The coated mesh is implanted. The rest of plasma is spilled over the implantation site.

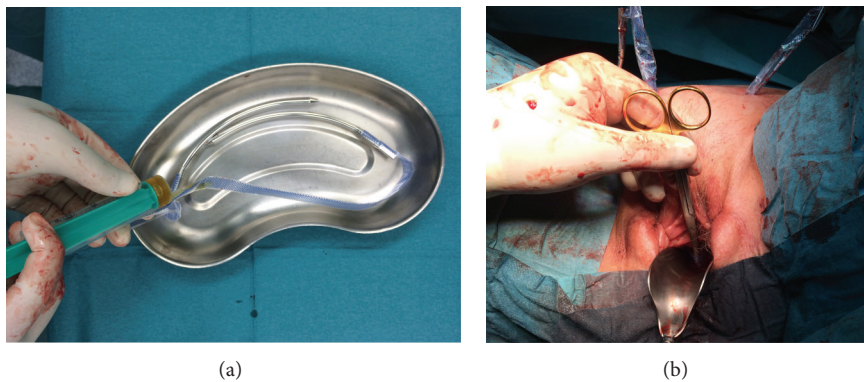


FIGURE 2: TVT-procedure. (a) Coating of TVT-mesh with autologous plasma. (b) Insertion of retropubic midurethral sling.

external sphincter was revealed. According to the *IDEAL* model a sophisticated, well-defined selection of patients was performed. The exclusion criteria were previous mesh implantation at the operation site, infection, chemo- or immunological therapy during the last three months, psychiatric illness or inability to answer the questionnaire, and pregnancy. Different mesh materials were used (TVT, Seratim, Ultrapro, and Vitamesh) (Table 1). 20–40 mL blood sample was obtained in the EDTA-tube (ethylenediaminetetraacetic acid) from the respective patient by vein puncture before the induction of anesthesia. The blood collection and centrifugation of blood sample (4000 rpm for 10 min) was performed in the operation room in order to prevent the contamination. The clear supernatant (plasma) after centrifugation of the

precipitation was removed with sterile syringe. Before the implantation the meshes were incubated for 30 min with 10–20 mL (depending on the size of the mesh) autologous plasma in a bowl (Figures 1 and 2). The surgical technique was not altered by the application of this technology (Figure 2). The patients were examined pre- and postoperatively and interviewed before the operation and on telephone 6–8 weeks after the operation. For high grade POP (grade \geq III) a peri-operative ureteral stenting for about two weeks was performed. Ultrasound controls for residual urine volume and hydronephrosis were done after catheter removal on the third postoperative day. In cases of obstruction due to MUS (midurethral sling) a prolonged catheterisation was needed. If the voiding dysfunction persisted (residual volume >

TABLE 2: Patient characteristics.

Procedure	TVT	TOT	Anterior vaginal mesh	Sacrocolpopexy
Number of patients (gender)	7 (female)	4 (male)	1 (female)	8 (female)
Age, mean (yr)	67 (57–85)	71 (70–72)	58	64 (45–75)
Operation time, mean (min)	36 (31–49)	46 (42–55)	51	57 (43–71)
Followup, median (mos)	3 (2–4)	4 (2–7)	3	3 (1–4)
Concomittant procedures	1 × SSF	No	1 × SSF	8 × Burch, 1 × Rectopexy

SSF: sacrospinous fixation.

TABLE 3: Peri- and early postoperative complications.

Procedure	TVT	TOT	Anterior vaginal mesh	Sacrocolpopexy	Total	IUGA/ICS-classification
Number of patients (gender)	7 (female)	4 (male)	1 (female)	8 (female)	20	
Complications, number (%)						
Clavien-Dindo Grade I						
Prolonged pain	0	1 (25%)	0	1 (12.5%)	2 (10%)	6Be/S4
Hematoma	1 (14%)	1 (25%)	0	0	2 (10%)	7A/S3/S4
Urge <i>de novo</i>	3 (43%)	0	0	0	3 (15%)	4B/site?
Obstruction (prolonged cath.)	1 (14%)	0	1 (100%)	0	2 (10%)	4B/site?
Grade II						
UTI	2 (28%)	0	0	2 (25%)	4 (25%)	4B/site?
Grade III						
Obstruction (reoperation)	2 (28%)	0	0	0	2 (10%)	4B/S1
Bladder/bowel injury	0	0	0	0	0	4A/S3, 5A/B/S5
Fistula	0	0	0	0	0	4/5B/S1 or S2
Mesh exposure	0	0	0	0	0	2B or 3B/S1 or S2
QoL improved	6 (86%)	2 (50%)	1 (100%)	7 (87.5%)	16 (80%)	

200 mL) an endoscopic evaluation with cystoscopic release of the sling was performed. The patient charts were searched for perioperative and early postoperative complications. The safety of our technology for the patient was validated by the Clavien-Dindo classification of surgical complications and ICS/IUGA classification [2, 16]. The quality of life (QoL) was assessed by P-QOL and ICIQ-SF 2004 questionnaires [17]. In cases of explantation the immunohistochemistry analyses of the mesh are planned [7, 14].

3. Legal Requirements

The application of autologous blood plasma coating was performed according to the German Pharmaceutical Law (AMG), the Medical Product Act (MPG) and the Transfusion Act. The permission for this new experimental method was provided by local government. According to the statement of the local government, the preparation of autologous blood plasma and the modification of the mesh by the coating procedure are subject to paragraph 13, 2 b, of the AMG and no permission according to paragraph 13, 1, of the AMG is necessary.

The patients were carefully educated on the experimental technique and possible complications. Because of the retrospective data evaluation no ethical approval was necessary.

4. Results

Between 04/2013 and 05/2014, 20 patients (16 females and 4 males) with the indication for SUI and POP repair with mesh graft were selected for surgery in a single institution. The patient characteristics are described in Table 2. The mean age was 67 years (45–85) and the mean followup was 3 months [1–7]. 11 patients were treated for SUI (grades II–III, Stamey score) and 9 patients were treated for POP (POP-Q grades I–III, anterior and apical prolapse). In 50% of patients concomitant operations (*Burch* colposuspension, sacrospinous fixation, and rectopexy) were performed. No intraoperative problems or complications (transfusion reaction, etc.) associated with mesh coating with autologous plasma were observed. Two reoperations (10%, Clavien-Dindo Grade IIIB) with the cystoscopic release of TVT-mesh in anesthesia due to the obstruction were needed. No other severe complications (mesh exposure, bladder or bowel injury, and fistula) were registered. Prolonged perineal parasthesia and hematoma were observed in 2 cases after TOT (50%) (Table 3). An 85-year female with extended usage of analgesics and antidepressant agents presented a prolonged voiding dysfunction after TVT. Prolonged catheterization and the cystoscopic release were not successful. A suprapubic tube was inserted, the antidepressants were reduced, and the medication with Ubretid was started. A 76-year female presented persisting SUI after the anterior POP repair (grade III)

with sacrocolpopexy and consecutive TVT (plasma-coated). The postoperative examination revealed a persisting Grade II-cystocele. A reoperation with colporrhaphy and plasma-coated vaginal mesh application is planned. Two of four male patients after TOT procedure complained about persisting SUI (>1 pad/day); in these cases an artificial urinary sphincter was planned. The functional outcome and QoL improved overall in all groups during the followup. No mesh resections or explantations were necessary up-to-date.

5. Discussion

The preliminary work on the principles of plasma coating were described in *in vitro* and animal studies previously [9, 10, 14, 15]. Our study illustrates the first clinical usage of the mesh modification by autologous plasma for POP and SUI repair. The observed early perioperative complications correspond to the data of current meta-analyses and studies [4, 5, 18]. Voiding dysfunction, UTI, recurrent SUI, and paraesthesia were described previously and are associated mostly with the surgical technique and not to the mesh modification. The procedure is safe and offers good functional results. The only Grade III (Clavien-Dindo) complication in the TVT-group was the obstruction with the need of reoperation. This complication is due to the operation technique and has no relation to the coating procedure. The technique of plasma coating is an easy-to-do and timely procedure. No additional complications or intraoperative problems due to this technique were observed. The complications were graduated according to Clavien-Dindo and ICS (International Continence Society)/IUGA (International Urogynecologic Association) classification. The ICS/IUGA classification is based on the information on the category, time, and location of complications. We had problems to make a precise classification for some complications due to inconsistent definitions (Table 3). Because of high complexity and low concordance in different trials ICS/IUGA-classification is currently rarely used [4, 19]. However, we consider the classification to be valuable for the report of long-term data in registries.

The current studies show the importance of acute inflammatory and immune responses for the integration of mesh into the surrounding tissue [9, 10, 15]. Foreign body reaction (FBR) often causes a fibrotic rebuilding of implants and the loss of functions (loss of flexibility, etc.). Furthermore, there is a risk of complications, like deformations (capsule fibrosis of breast implants), chronic pain, and dyspareunia, especially in a sensitive genital region. Seconds after the implantation, the biomaterials are covered by protein layer and 4–8 hours later the macrophages appear and in a few days a granuloma with fibrotic tissue appears [20]. Albumin, fibrinogen (Fg), and immune complexes, in particular IgG, can be found on many surfaces after implantation, such as polyethylene terephthalate (PET), expanded polytetrafluoroethylene (ePTFE), polydimethylsiloxane, polyurethane, and polyethylene polymers, which are all important materials in the manufacture of the implant [7]. Fibrin or fibrinogen modulation by the proteins in the inflammatory response after implantation of foreign materials in the body is particularly important. Studies show

that plasma-coated surfaces accumulate significantly less inflammatory cells compared to uncoated surfaces [21, 22]. The profound understanding of the FBR plays the crucial role for optimisation of biocompatibility of alloplastic materials in order to reduce the complications.

An ideal graft material is supposed to be chemically inert, nontoxic, nonallergic, noninflammatory, resistant to infection, noncarcinogenic, solid, sterilizable, convenient, and affordable [8]. New developments in material optimization are currently tested. There are only a few groups who have investigated polypropylene mesh modifications by surface coating with collagen, titanium, or absorbable polymers in animal and *in vitro* studies [11, 12, 23, 24]. While some of these studies found higher biocompatibility (e.g., light polypropylene mesh) compared to the standard polypropylene control group, others found very similar outcomes between the two groups. Some of these meshes have been now introduced into the market as they were thought to be associated with lower complications [25]. Our study group was the first one to analyse the mesh modification according to *IDEAL* criteria of surgical innovation [13]. On the basis of the results presented in this study we are currently initiating a prospective randomised clinical trial for the optimization of implants in mesh surgery. We will compare the group of native meshes versus coated meshes for postoperative complications and functional results. The last step of *IDEAL* model with long-term surveillance of mesh grafts was successfully introduced for hernia surgery by national and European registries [26, 27]. A consecutive urogynecological registry for implants is currently under construction (unpublished data).

It is crucial that randomised controlled clinical trials should be supported in the future, in particular with regard to fundraising or industrial sponsoring. Therefore research funders need to recognise the nature of surgical innovation to encourage high-quality research approaches.

In the study presented here we could first transfer the previous *in vitro* and animal model findings on optimisation of mesh properties in human. The results of this research and the developed evaluation approach for meshes could get more important in the future evaluating processes as the method can be performed independent from manufacturers concerns, in particular after market entry [14].

6. Conclusion

Coating of meshes with autologous plasma prior to implantation is a safe procedure with no increased perioperative complications. The modification is implemented according to *IDEAL* criteria of surgical innovations (*Exploration* stage). A randomized single-blinded clinical trial proving a positive effect of plasma coating on the biocompatibility of meshes and morbidity outcome is justified and is in the progress of preparation (*Assessment* stage). A long-term surveillance of new mesh materials will be performed in national and European urogynecological registries (unpublished data, EuraHS) (*Long-Term* stage). In reaction to FDA reports on mesh associated problems, our international collaboration group presents a unique implementation of all five steps of surgical innovations for mesh graft development in urogynecology.

Conflict of Interests

The authors declare that there is no conflict of interests regarding the publication of this paper.

Acknowledgments

Special thanks go to the patients and their families for the great support of our work. Extended collaboration group for investigation and development of surgical implants included Peter Ponsaerts, Laboratory of Experimental Hematology, University of Antwerp, Antwerp, Belgium; Jean-Pierre Timmermans, Laboratory of Cell Biology and Histology, University of Antwerp, Antwerp, Belgium; Rudolf Hohenfellner, Department of Urology, University of Mainz, Germany; Stefan C. Müller, Department of Urology, Bonn University, Bonn, Germany; Ferdinand Köckerling, Department of Surgery, Vivantes Hospital Spandau, Berlin, Germany; Uwe Klinge, Department of Surgery, University of Aachen, Germany; Werner Bader, Department of Gynecology, Hospital of Bielefeld, Germany; Christian Arndt, Christoph Eimer, Jens W. Bagner, Roman Karig, Annette Wiggen-Kremer, Department of Urology, Lukas Hospital Neuss, Germany; Stephan Otto, Department of Surgery, Clemens Hospital Münster, Germany; Mohamed Wishahi, Department of Urology, Theodor Bilharz Research Institute, Cairo, Egypt; Gerd Heusch, Institute for Pathophysiology, University of Essen, Germany; Nicholas Bohnert, Peter E. Goretzki, Department of Surgery, Lukas Hospital Neuss, Germany; Andreas Müllen, Boris Obolenski, FEG Textiltechnik mbH, Aachen; Eckhard Petri, Department of Gynecology, University of Greifswald, Germany; Christoph H. Gleiter, CenTrial GmbH, Tübingen, Germany; Wilma Hartung, TÜV (German Association for Technical Inspection) Rhineland, Cologne, Germany; Koudy Williams, Wake Forest Institute for Regenerative Medicine (WFIRM), Winston Salem, NC, USA; Alberto Garcia Gomez, UNESCO, Professor of Bioethics at the Pontifical University in Rome, Italy. The authors highly appreciate the support from ITERA (International Tissue Engineering Research Association) for outstanding support during the entire experiment.

References

- [1] "UPDATE on Serious Complications Associated with Transvaginal Placement of Surgical Mesh for Pelvic Organ Prolapse: FDA Safety Communication," <http://www.fda.gov/Medical-Devices/Safety/AlertsandNotices/ucm262435.htm>.
- [2] B. T. Haylen, R. M. Freeman, and S. E. Swift, "An International Urogynecological Association (IUGA)/International Continence Society (ICS) joint terminology and classification of the complications related directly to the insertion of prostheses (meshes, implants, tapes) and grafts in female pelvic floor surgery," *Neurourology and Urodynamics*, vol. 30, no. 1, pp. 2–12, 2011.
- [3] P. K. Amid and I. L. Lichtenstein, "Current situation of the Lichtenstein open tension-free hernioplasty," *Chirurg*, vol. 68, no. 10, pp. 959–964, 1997.
- [4] D. Barski, T. Otto, and H. Gerullis, "Systematic review and classification of complications after anterior, posterior, apical, and total vaginal mesh implantation for prolapse repair," *Surgical Technology International*, vol. 24, 2014.
- [5] C. Maher, B. Feiner, K. Baessler, and C. Schmid, "Surgical management of pelvic organ prolapse in women," *Cochrane Database of Systematic Reviews*, no. 4, Article ID CD004014, 2013.
- [6] K. Ashok and E. Petri, "Failures and complications in pelvic floor surgery," *World Journal of Urology*, vol. 30, no. 4, pp. 487–494, 2012.
- [7] U. Klinge and B. Klosterhalfen, "Modified classification of surgical meshes for hernia repair based on the analyses of 1,000 explanted meshes," *Hernia*, vol. 16, no. 3, pp. 251–258, 2012.
- [8] A. Gomelsky and R. R. Dmochowski, "Biocompatibility assessment of synthetic sling materials for female stress urinary incontinence," *Journal of Urology*, vol. 178, no. 4, pp. 1171–1181, 2007.
- [9] H. Gerullis, E. Georgas, C. Eimer et al., *Evaluation of Biocompatibility of Alloplastic Materials: Development of a Tissue Culture In Vitro Test System*, Surgical Technology International, 2011.
- [10] H. Gerullis, E. Georgas, C. Eimer et al., "Coating with autologous plasma improves biocompatibility of mesh grafts *in vitro*: development stage of a surgical innovation," *BioMed Research International*, vol. 2013, Article ID 536814, 6 pages, 2013.
- [11] K. Junge, R. Rosch, U. Klinge et al., "Titanium coating of a polypropylene mesh for hernia repair: effect on biocompatibility," *Hernia*, vol. 9, no. 2, pp. 115–119, 2005.
- [12] A. Lukaszewicz, J. Skopinska-Wisniewska, A. Marszalek, S. Molski, and T. Drewa, "Collagen/polypropylene composite mesh biocompatibility in abdominal wall reconstruction," *Plastic and Reconstructive Surgery*, vol. 131, no. 5, pp. 731e–740e, 2013.
- [13] P. McCulloch, "The IDEAL recommendations and urological innovation," *World Journal of Urology*, vol. 29, no. 3, pp. 331–336, 2011.
- [14] H. Gerullis, B. Klosterhalfen, M. Borós et al., "IDEAL in meshes for prolapse, urinary incontinence, and hernia repair," *Surgical Innovation*, vol. 20, no. 5, pp. 502–508, 2013.
- [15] H. Gerullis, E. Georgas, M. Borós et al., "Inflammatory reaction as determinant of foreign body reaction is an early and susceptible event after mesh implantation," *BioMed Research International*, vol. 2014, Article ID 510807, 6 pages, 2014.
- [16] P. A. Clavien, J. Barkun, M. L. de Oliveira et al., "The Clavien-Dindo classification of surgical complications: five-year experience," *Annals of Surgery*, vol. 250, no. 2, pp. 187–196, 2009.
- [17] F. Lenz, H. Stammer, K. Brocker, M. Rak, H. Scherg, and C. Sohn, "Validation of a German version of the P-QOL questionnaire," *International Urogynecology Journal and Pelvic Floor Dysfunction*, vol. 20, no. 6, pp. 641–649, 2009.
- [18] P. Rehder, F. Haab, J.-N. Cornu, C. Gozzi, and R. M. Bauer, "Treatment of postprostatectomy male urinary incontinence with the transobturator retroluminal repositioning sling suspension: 3-year follow-up," *European Urology*, vol. 62, no. 1, pp. 140–145, 2012.
- [19] E. Tunitzky, S. Abbott, and M. D. Barber, "Interrater reliability of the International Continence Society and International Urogynecological Association (ICS/IUGA) classification system for mesh-related complications," *The American Journal of Obstetrics and Gynecology*, vol. 206, no. 5, pp. 442.e1–442.e6, 2012.
- [20] D. T. Luttkhuizen, M. C. Harmsen, and M. J. A. van Luyn, "Cellular and molecular dynamics in the foreign body reaction," *Tissue Engineering*, vol. 12, no. 7, pp. 1955–1970, 2006.
- [21] L. Tang and J. W. Eaton, "Fibrin(ogen) mediates acute inflammatory responses to biomaterials," *Journal of Experimental Medicine*, vol. 178, no. 6, pp. 2147–2156, 1993.

- [22] J. Zdolsek, J. W. Eaton, and L. Tang, "Histamine release and fibrinogen adsorption mediate acute inflammatory responses to biomaterial implants in humans," *Journal of Translational Medicine*, vol. 5, article 31, 2007.
- [23] G. Böhm, Y. Ushakova, H. P. Alizai et al., "Biocompatibility of PLGA/sP(EO-stat-PO)-coated mesh surfaces under constant shearing stress," *European Surgical Research*, vol. 47, no. 3, pp. 118–129, 2011.
- [24] A. Mangera, A. J. Bullock, S. Roman, C. R. Chapple, and S. Macneil, "Comparison of candidate scaffolds for tissue engineering for stress urinary incontinence and pelvic organ prolapse repair," *BJU International*, vol. 112, no. 5, pp. 674–685, 2013.
- [25] R. D. Moore and J. C. Lukban, "Comparison of vaginal mesh extrusion rates between a lightweight type I polypropylene mesh versus heavier mesh in the treatment of pelvic organ prolapse," *International Urogynecology Journal*, vol. 23, no. 10, pp. 1379–1386, 2012.
- [26] B. Stechemesser, D. A. Jacob, C. Schug-Paß, and F. Köckerling, "Herniamed: an Internet-based registry for outcome research in hernia surgery," *Hernia*, vol. 16, no. 3, pp. 269–276, 2012.
- [27] F. Muysoms, G. Campanelli, G. G. Champault et al., "EuraHS: the Development of an international online platform for registration and outcome measurement of ventral abdominal wall Hernia repair," *Hernia*, vol. 16, no. 3, pp. 239–250, 2012.
- [28] B. Klosterhalfen, K. Junge, and U. Klinge, "The lightweight and large porous mesh concept for hernia repair," *Expert Review of Medical Devices*, vol. 2, no. 1, pp. 103–117, 2005.
- [29] A. Niesel, O. Gramalla, and A. Rohne, "A preliminary report on the use of a partially absorbable mesh in pelvic reconstructive surgery," *Pelviperrineology*, vol. 27, no. 1, pp. 22–25, 2008.
- [30] "Proxy Biomedical: Biomaterials Design & Development," <http://www.proxybiomedical.com/>.
- [31] "Ethicon," <http://www.ethicon.com>.



Hindawi
Submit your manuscripts at
<http://www.hindawi.com>

