



Prognostic Factors for Renal Cell Carcinoma Subtypes Diagnosed According to the 2016 WHO Renal Tumor Classification: a Study Involving 928 Patients

Levente Kuthi¹  · Alex Jenei¹ · Adrienn Hajdu¹ · István Németh² · Zoltán Varga³ · Zoltán Bajory⁴ · László Pajor⁴ · Béla Iványi¹

Received: 29 July 2016 / Accepted: 21 December 2016
© Arányi Lajos Foundation 2016

Abstract The morphotype and grade of renal cell carcinoma (RCC) in 928 nephrectomies were reclassified according to the 2016 WHO classification in order to analyze the distribution and outcomes of RCC subtypes in Hungary, to assess whether microscopic tumor necrosis is an independent prognostic factor in clear cell RCC, and to study whether a two-tiered grading (low/high) for clear cell and papillary RCC provides similar prognostic information to that of the four-tiered ISUP grading system. 83.4% of the cohort were clear cell, 6.9% papillary, 4.5% chromophobe, 2.3% unclassified, 1.1% Xp11 translocation, 1.1% clear cell papillary, 0.3% collecting duct and 0.1% mucinous tubular and spindle cell RCCs. RCC occurred in 16 patients with end-stage kidney disease and none of them displayed features of acquired cystic kidney disease-associated RCC. The 5-year survival rates were as follows: chromophobe 100%, clear cell papillary 100%, clear cell low-grade 96%, papillary type 1 92%, clear cell high-grade 63%, papillary type 2 65%, unclassified 46%, Xp11 translocation 20%, and collecting duct 0%. The 5-year survival rates in low-grade and high-grade papillary RCC were 95% and 59%, respectively. In clear cell RCC, only the grade, the stage and the positive surgical margin proved to be

independent prognostic factors statistically. Overall, papillary RCC occurred relatively infrequently; microscopic tumor necrosis in clear cell RCC did not predict the outcome independently of the tumor grading; and the assignment of clear cell and papillary RCCs into low-grade or high-grade tumors was in terms of survival no worse than the ISUP grading.

Keywords Renal cell carcinoma · ISUP grading · Microscopic tumor necrosis · Survival rates · Prognostic factors

Introduction

The diagnostic categories of the 2016 WHO Renal Tumor Classification was largely elaborated by the International Society of Urological Pathology (ISUP) consensus conference held in Vancouver, Canada in 2012 [1, 2]. The conference made recommendations on classification, prognostic factors, staging, and immunohistochemical and molecular evaluation of renal cell carcinoma (RCC) [2–4]. 5 new entities were recognized. A new grading system was formulated with the intention of replacing the Fuhrman's grading system, which has problems with the interpretation, validation and reproducibility [3, 5]. The incorporation of microscopic tumor necrosis in clear cell RCC as a grading parameter was also proposed, but it was agreed that further confirmatory studies were required [6].

In the present study, the distribution and outcomes of RCC morphotypes were analyzed in a set of Hungarian patients in accordance with the 2016 WHO Renal Tumor Classification in order to obtain reference data for the prevalence and cancer-specific survival (CSS) of the traditional and new entities in the south-eastern, non-industrialized region of Hungary, populated entirely by Caucasians. Since the prognostic

✉ Levente Kuthi
kuthi.levente@med.u-szeged.hu

¹ Department of Pathology, University of Szeged, Állomás Street 1, Szeged H-6725, Hungary
² Department of Dermatology and Allergology, University of Szeged, Korányi Alley 6, Szeged H-6720, Hungary
³ Department of Oncotherapy, University of Szeged, Korányi Alley 12, Szeged H-6720, Hungary
⁴ Department of Urology, University of Szeged, Kálvária Lane 57, Szeged H-6725, Hungary

significance of microscopic tumor necrosis in clear cell RCC has not yet been resolved, its presence relative to sarcomatoid/rhabdoid differentiation, tumor grade, TNM stage and surgical margin involvement was investigated using statistical methods in order to see whether it has an independent impact on CSS. Furthermore, the prognostic ability of a two-tiered grading system for clear cell RCC and papillary RCC was tested in order to conclude whether the simplification of the four-tiered ISUP grading system to a two-tiered grading system can be used in reporting RCCs.

Material and Methods

Review Process

Between 1st January 1990 and 31st December 2015, 843 radical and 85 partial nephrectomies for RCC were evaluated in our department. The pathology reports and the hematoxylin and eosin-stained slides were reviewed. Later the cases were regraded according to the recommendations of the consensus conference, and samples requiring immunostainings were selected [4].

Immunohistochemical Support for the Diagnosis

Carbonic anhydrase IX, cytokeratin 7 (CK7), alpha-methylacyl-CoA racemase, CD117, transcription factor E3 (TFE3), HMB-45 and *Ulex europaeus* agglutinin I immunostainings were applied in panels on tissue microarray slides of samples taken (2 cores/case) from 474 cases with overlapping lightmicroscopical features. The histomorphology and the typical immunoprofile of the tumor served to clarify the diagnosis [2, 4, 7–9]. If the lightmicroscopical appearance and the immunoprofile of the tumor did not allow the case to be assigned to the recognized categories, unclassified RCC was diagnosed.

Fluorescence in Situ Hybridization (FISH) Assays

The histological diagnosis of Xp11 translocation RCC was confirmed by *ZytoLight*® SPEC TFE3 Dual Color Break Apart Probe [4], considered positive if more than 10% of the tumor cells displayed a split signal. The diagnosis of clear cell papillary RCCs was supported by the lack of chromosome 3p loss (characteristic for clear cell RCCs), and the lack of trisomy of chromosomes 7 and 17 and Y chromosome loss (feature of papillary RCCs), looked for with appropriate probes (Cytocell Chromosome 7, 17 and Y Alpha Satellite Probes, *ZytoLight*® SPEC VHL/CEN3 Dual Color Probe) [10].

Pathological Features Evaluated

The ISUP nucleolar grade, the TNM stage amended according to the seventh edition, the surgical margin status, and features of nuclear pleiomorphism (i.e. sarcomatoid differentiation, rhabdoid change, and multinucleated giant tumor cells) were assessed [3, 11]. The highest grade occupying at least 1 high-power field determined the grade of the tumor. During the sampling of microscopic tumor necrosis in clear cell RCC, the extent of necrosis was not given a score.

Estimation of CSS

The duration of follow-up was calculated from the date of the surgical treatment to the date of death or the last follow-up. The CSS was analyzed only in patients with clinical M0 disease determined by imaging modalities at the time of the surgery. CSS was estimated by using the Kaplan-Meier method, and compared among groups via log rank tests. Deaths from causes other than RCC were censored. Univariate and multivariate Cox proportional hazard regression models served to estimate the degree of the association of the RCC histological subtype with the patient outcome, as shown by the HR and 95% CI. The statistical analyses were performed using the SPSS software package ($p > 0.05$).

Results

The clinicopathological features of the different subtypes are summarized in Table 1. The series comprised 28 extensively cystic carcinomas. 25 cases were reclassified as clear cell RCC, 2 as multilocular cystic clear cell renal cell neoplasm of low malignant potential, and 1 as clear cell papillary RCC. RCC occurred in 16 patients with end-stage kidney disease. The following morphotypes were encountered: clear cell on 11 occasions, papillary type 1 on 3 occasions and clear cell papillary on 2 occasions. Although the features of acquired cystic kidney disease (ACKD) were observed in 9 end-stage kidneys with RCC, the histological evaluation did not lead to the suspicion of ACKD-associated RCC in any of these cases. As for synchronous tumors, clear cell RCC and papillary RCC type 1 in the same kidney were recorded in 2 patients, and clear cell RCC and oncocytoma in 1 patient. Bilateral clear cell RCC occurred in 3 patients, one of whom had end-stage kidney disease.

Clear Cell RCC

Among the 253 (27%) high-grade carcinomas, the transition of low-grade tumor cells to high-grade tumor cells was commonly observed; and purely high-grade clear cell RCC was noted in 60 (7.7%) cases. 4 samples exhibited microscopic

Table 1 Clinicopathological features in different subtypes of renal cell carcinoma

	Clear cell	Papillary T1	Papillary T2	Chromophobe	Unclassified	Xp11 translocation	Clear cell papillary	Collecting duct	Mucinous tubular
Number of cases (%)	774 (83.4)	37 (3.9)	28 (3.0)	42 (4.5)	22 (2.3)	10 (1.1)	10 (1.1)	4 (0.4)	1 (0.1)
Age (years)	Median, range	61, 25–84	62, 12–79	58, 17–74	63, 30–77	55, 15–72	50, 32–78	62, 49–69	68
Male:female ratio	1.5:1	3.1:1	2.1:1	0.82:1	2.6:1	2.3:1	1.5:1	1:1	female
Right:left ratio	1.09:1	0.89:1	1:1	1.21:1	0.69:1	0.25:1	1:1	0.33:1	right
Size (mm)	Median, range	55, 10–220	43.5, 10–150	60, 9–170	50, 14–170	86.5, 34–173	90, 25–160	30, 10–65	92, 55–140
ISUP grade	G1	157	3	0	not graded	0	9	0	1
	G2	364	29	7	not graded	5	1	0	0
	G3	99	2	15	not graded	8	0	0	0
	G4	154	3	6	not graded	9	0	4	0
		221	11	21	3	19	0	3	0
Microscopic tumor necrosis		117	3	3	0	9	0	2	0
Rhabdoid and/or sarcomatoid		105	3	1	0	2	0	0	0
Giant tumor cells		37	1	2	0	2	0	2	0
Surgical margin positivity		215	16	7	13	2	9	0	1
Postoperative tumor stage	pT1a	147	7	3	9	3	1	0	0
	pT1b	49	5	4	6	1	0	0	0
	pT2a	18	3	1	8	1	0	0	0
	pT2b	297	6	10	6	13	0	2	0
	pT3a	16	0	0	0	2	0	0	0
	pT3b	9	0	0	0	0	0	0	0
	pT3c	23	0	3	0	3	0	2	0
	pT4	29	2	5	0	2	0	1	0
Lymph node involvement	N1	39	0	2	0	1	0	1	0
Distant metastases	M1	356	23	10	3	3	10	0	1
TNM stage groupings	I	63	7	5	2	1	0	0	0
	II	301	7	9	14	3	0	1	0
	III	54	0	4	0	2	0	3	0
	IV								

tumor necrosis in the grade 1 group, 28 in the grade 2 group, 65 in the grade 3 group, and 124 in the grade 4 group.

Papillary RCC

A combination of features of both histologic subtypes was present in 5 samples and these were assigned according to the predominant histological pattern. Type 1 carcinomas were essentially of low-grade; while type 2 carcinomas were mostly of high-grade

Chromophobe RCC

In 5 cases with predominantly eosinophilic cells, the possibility of oncocytoma was excluded by the diffuse membranous CD117 and diffuse cytoplasmic CK7 reactivity of the tumor cells, along with the positivity of the Hale colloidal iron staining.

Xp11 Translocation RCC

The labeling for TFE3 protein was diffuse in 8 samples, and focal in 2 samples. The FISH assay confirmed *TFE3* gene fusion in every case.

Clear Cell Papillary RCC

All of the tumors were in stage pT1. The FISH assay supported the histopathological diagnosis in each case.

Fig. 1 Cancer-specific survival rates of 763 non-metastatic patients with RCC based on histologic subtype. A 100% 5-year survival rate was observed for clear cell papillary RCC and chromophobe RCC. Clear cell RCCs had an 83.4%, papillary RCCs an 81%, unclassified RCCs a 46%, Xp11 translocation RCCs a 20%, and collecting duct RCCs a 0% 5-year survival rate

Collecting Duct RCC

All of the tumors were in an advanced stage, the main part of the tumor being centered in the medulla. The *Ulex europaeus* staining revealed diffuse positivity in 2 cases and focal positivity in 1 case.

Mucinous Tubular and Spindle RCC

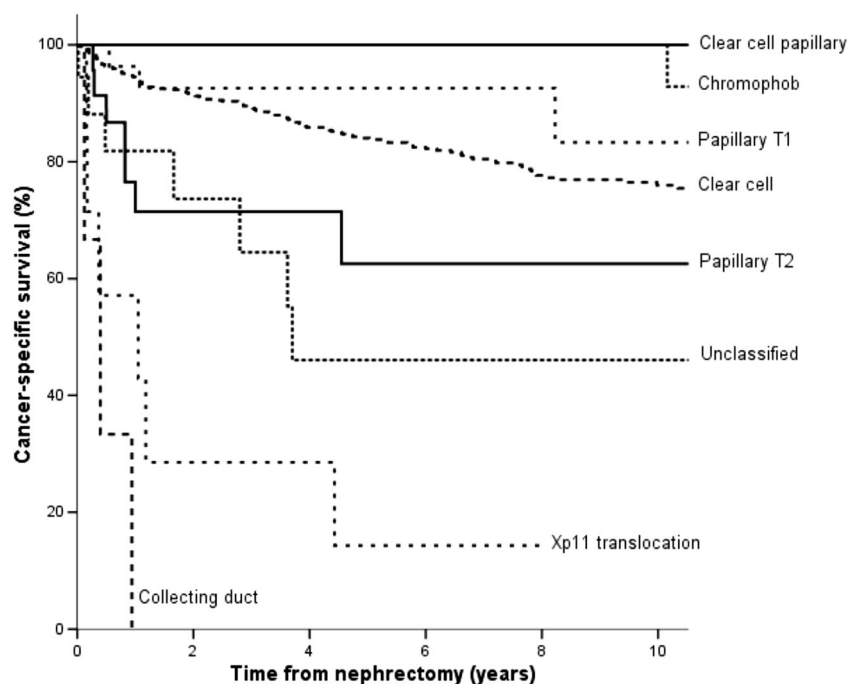
The patient did not have any evidence of disease recurrence or metastatic dissemination during the 15 month follow-up period.

Unclassified RCC

The majority of cases proved to be high-grade carcinomas.

Correlation between the Morphotype and CSS

Follow-up data sets were accessible for 804 patients (763 non-metastatic and 41 metastatic diseases at the time of surgery). 131 patients with clear cell RCC, 3 patients with type 1 papillary RCC, 7 patients with type 2 papillary RCC, 7 patients with unclassified RCC, 6 patients with Xp11 translocation RCC, and 3 patients with collecting duct RCC had died from an RCC-related cause. The median follow-up of these patients was 29 months (range 1–254 months), whereas the median follow-up for all survivors was 68 months (range 2–313 months). The CSS rates of histological types are shown in Fig. 1. The 5-year CSS was significantly different between patients with clear cell RCC and with chromophobe RCC ($p = 0.021$) or with unclassified RCC ($p < 0.001$) or with



Xp11 translocation RCC ($p < 0.001$), but not between patients with clear cell RCC and those with papillary RCC ($p = 0.39$). Although the statistical significance in survival rates could not be calculated between clear cell RCC and clear cell papillary RCC or collecting duct RCC because of the limited number of cases in the latter entities, the Kaplan Meyer curves leave no doubt that these entities represent a quite different outcome.

Among the 90 patients with non-metastatic clear cell RCC at the time of nephrectomy and who died from an RCC-related cause, 18 patients received tyrosine-kinase inhibitors. Although the average survival time was longer in the treated group (5.9 years vs 4.5 years), this did not affect CSS significantly ($p = 0.271$); hence, the treatment of metastatic disease did not conflict with what the survival data tell us in Fig. 1.

Grade and Microscopic Tumor Necrosis in Clear Cell RCC

CSS rates according to the four-tiered ISUP grade and the two-tiered grade assessment are shown in Fig. 2. A higher TNM stage predicted a significantly poorer prognosis (see Table 2). When CSS according to the presence or absence of microscopic tumor necrosis was analyzed, the necrotic tumors exhibited a significantly poorer outcome than the non-necrotic tumors ($p < 0.001$; not shown). When the presence or absence of tumor necrosis was tested in patients with low-grade tumors vs high-grade tumors (Fig. 3), necrosis was associated with a significantly poorer outcome only in high-grade tumors. In

univariate Cox proportional hazard analysis, the ISUP grade, TNM stage, tumor necrosis, giant tumor cells, rhabdoid/sarcomatoid morphology and positive surgical margins all proved to be negative predictors of CSS. In multivariate Cox proportional hazards analysis, however, only the ISUP grade, TNM stage and positive surgical margin turned out to be independent prognostic factors (Table 2).

Subtypes and Grade in Papillary RCC

The 5-year CSS rates in type 1 and type 2 subtypes are shown in Fig. 4. When the 5-year CSS was calculated according to the ISUP grade, 100% was observed for grade 1, 94% for grade 2, 74% for grade 3 and 33% for grade 4 samples, respectively. The 5-year survival rate was significantly better for patients with grade 2 tumors than for those with grade 3 tumors ($p = 0.011$). The sample size in grade 1 tumors did not allow a comparison of survival rates between those with grade 1 and grade 3 tumors. However, there was no significant difference in survival rates between cases with grade 1 vs grade 2 ($p = 0.696$), and grade 3 vs grade 4 ($p = 0.445$); and, therefore, samples with grades 1 and 2, and grades 3 and 4 were merged to low-grade and high-grade categories. The 5-year CSS rates according to the two-tiered grading system exhibited a significant difference; namely 95% for low-grade tumors and 59% for high-grade tumors (Fig. 4). In a Cox proportional hazard analysis, the ISUP grade and TNM stage, but not the

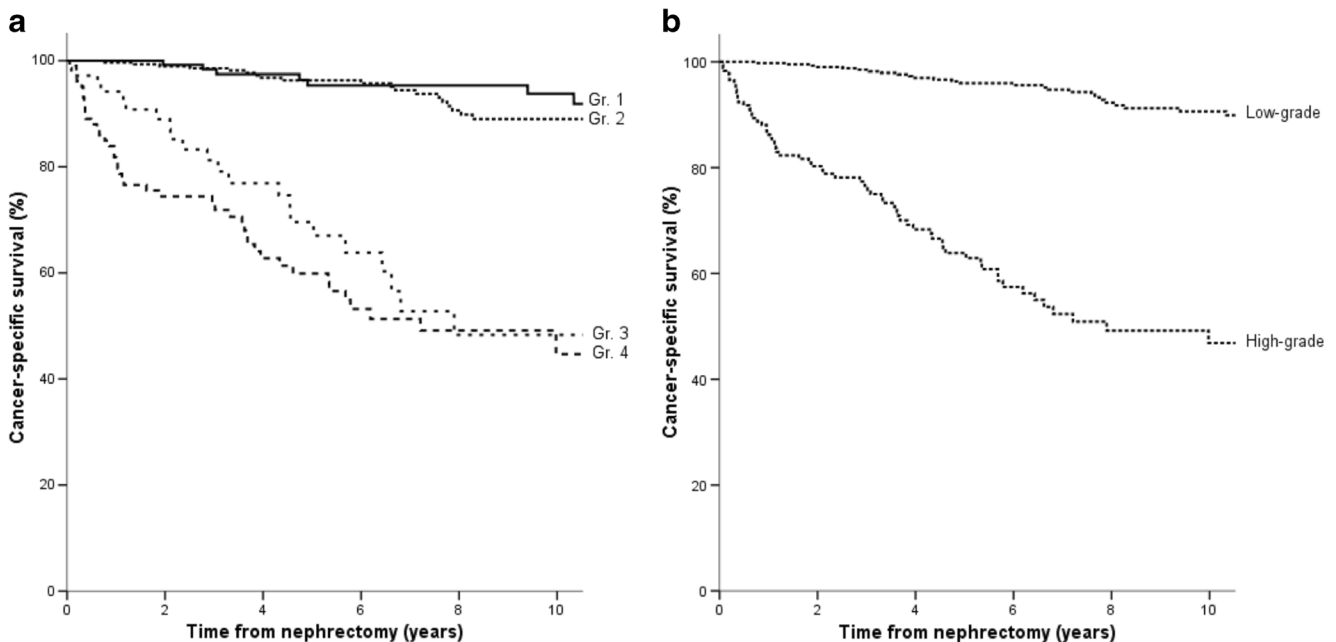


Fig. 2 Cancer-specific survival in clear cell RCC according to the ISUP grading system. **a** The Kaplan-Meier estimation did not reveal any difference in biological behavior between grade 1 vs grade 2 tumors ($p = 0.550$), and grade 3 vs 4 tumors ($p = 0.226$). Grade 1 or grade 2 tumors displayed a significantly better survival rate among patients than

grade 3 tumors ($p < 0.0001$). **b** When the grade 1 and 2 tumors were lumped together into low-grade carcinomas, and grade 3 and 4 tumors into high-grade carcinomas, the survival analysis revealed a significant difference between the low-grade and high-grade groups ($p < 0.0001$)

Table 2 Cox regression analysis for cancer-specific survival rates in non-metastatic clear cell RCC

Characteristic	Hazard ratio	CI 95%	<i>p</i> value
Univariate			
ISUP grade	7.50	5.01–11.21	<0.001
TNM stage	2.54	2.04–3.15	<0.001
Surgical margin status	2.95	1.57–5.53	<0.001
Microscopic tumor necrosis	6.74	4.53–10.07	<0.001
Rhabdoid/sarcomatoid change	5.14	3.39–7.78	<0.001
Giant tumor cells	3.93	2.51–6.15	<0.001
Multivariate			
ISUP grade	4.33	2.36–7.95	<0.001
TNM stage	1.86	1.49–2.33	<0.001
Surgical margin status	2.61	1.39–5.2	0.003
Microscopic tumor necrosis	1.69	0.93–3.05	0.081
Rhabdoid/sarcomatoid change	0.96	0.57–1.61	0.896
Giant tumor cells	0.67	0.4–1.13	0.139

morphotype, exerted a significant effect on the patient outcome (see Table 3).

Discussion

Distribution of RCC Morphotypes in Hungary

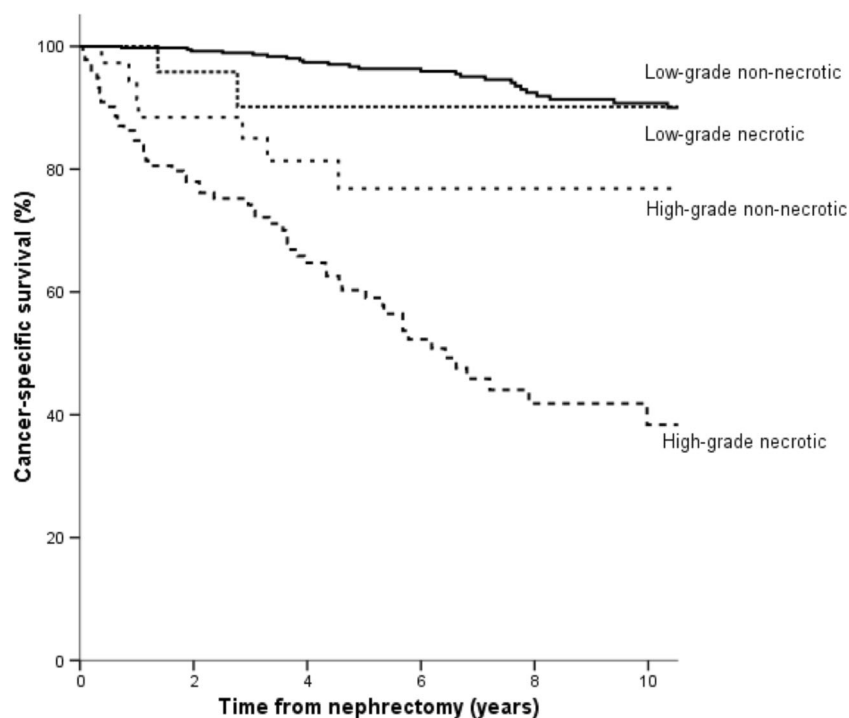
The incidence of RCC morphotypes is markedly influenced by geographic location and race [12, 13]. In our study, the

incidence of entities reflects the situation in white people from Central Eastern Europe, a fact which should be kept in mind when tumor prevalences from countries populated with different races are compared with those populated exclusively by Caucasians. Our study provided three new observations which complement or contradict the corresponding epidemiologic data of the 2016 WHO “blue book”.

First, our series was characterized by a relatively low incidence of papillary RCC (6.9%). A literature survey on the incidence of RCC in European countries reveals a uniform occurrence rate of approximately 80% for clear cell RCC and a geographical variation for the occurrence of papillary RCC. In the series of 2333 RCCs from Austria, 82.8% were clear cell, 10.9% papillary, 3% chromophobe, 0.3% collecting duct, and 3% unclassified [14]. In the study of 2197 small RCCs (≤ 4 cm) from Germany, the occurrence of clear cell, papillary, chromophobe and unclassified histology was 84.4%, 10.3%, 4.5% and 0.8%, respectively [15]. Also, a papillary RCC occurrence rate of 11% was observed in both Italy and Switzerland [16, 17]. In a recent publication from Denmark that focused on incidental renal neoplasms, 16% of the cases were diagnosed with papillary RCC [18]. The reason for the relative low prevalence of papillary RCC in the Carpathian Basin remains unclear at present.

Second, as regards the occurrence of the uncommon subtypes, clear cell papillary and Xp11 translocation RCC had a similar (1.1%) prevalence. Our observation disagrees with those obtained in a much smaller series from the USA, claiming that clear cell papillary RCC should be the fourth most common (4.1%) RCC morphotype [19]. Regrettably,

Fig. 3 Kaplan Meier estimates in clear cell RCC according to low-grade (ISUP grade 1 and 2) and high-grade (ISUP grade 3 and 4) assessment, and the presence or absence of microscopic tumor necrosis. The survival rates tended to be worse when tumor necrosis was present. However, the difference attained a level of significance only in the high-grade subtypes ($p = 0.02$)



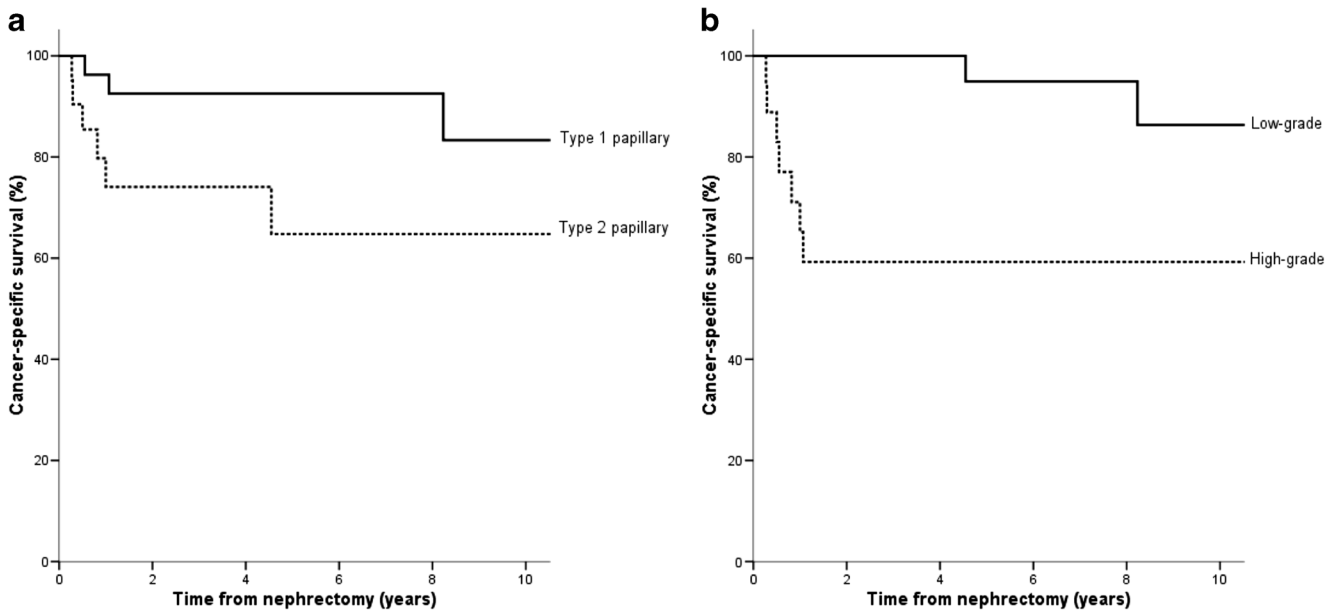


Fig. 4 Kaplan Meier estimates in papillary RCC. **a** The 5-year CSS rates in type 1 and type 2 subtypes were 92% and 65%, respectively ($p = 0.039$). **b** A significant difference was seen in survival rates

between the low-grade (ISUP grade 1 + grade 2) and the high-grade (ISUP grade 3 + grade 4) subtypes ($p < 0.001$)

that study did not investigate the race of their patients, and hence a possible racial difference in the occurrence rate of clear cell papillary RCC should not be concluded. Collecting duct RCC or mucinous tubular and spindle cell RCC are very rare subtypes worldwide, and accordingly, these were the rarest in the present series. Our series comprised 28 extensively cystic carcinomas, and the vast majority of cases turned out to be cystic clear cell RCC [10, 20]. Tubulocystic RCC did not occur in our cohort.

Table 3 Cox regression analysis for cancer-specific survival rates in non-metastatic papillary RCC

Characteristic	Hazard ratio	CI 95%	<i>p</i> value
Univariate			
ISUP grade	4.12	1.75–9.69	0.001
TNM stage	2.8	1.36–5.78	0.005
WHO type	3.64	0.9–14.7	0.039
Surgical margin status	2.97	0.36–24.1	0.30
Microscopic tumor necrosis	1.89	0.5–7.15	0.34
Rhabdoid/sarcomatoid change	3.18	0.63–16.1	0.16
Giant tumor cells	2.38	0.29–19.4	0.41
Multivariate			
ISUP grade	2.77	1.01–7.53	0.046
TNM stage	2.33	1.03–5.28	0.042
WHO type	3.15	0.55–17.85	0.19
Surgical margin status	2.54	0.02–247.3	0.68
Microscopic tumor necrosis	1.74	0.33–9.16	0.51
Rhabdoid/sarcomatoid change	5.11	0.25–102.3	0.28
Giant tumor cells	0.36	0.003–49.1	0.68

Third, a surprising finding was the lack of ACKD-associated RCC, which was said to be the most common RCC subtype in end-stage kidneys [21]. In our series, the most frequent subtype was clear cell RCC. In the evaluation of 43 RCCs in the native kidneys of patients who received kidney transplants in Budapest, Hungary, the predominant histological type was clear cell RCC [22]. In a multi-institutional study from Italy and Spain that analyzed the outcomes of RCC in patients with end-stage renal disease, clear cell RCC was similarly the most frequent subtype; and ACKD-associated RCC was not identified at all [23]. In a recent study of 181 patients with end-stage renal disease and RCC from South Korea, tumor histologic type was clear cell in 63%, papillary in 17%, chromophobe in 5%, clear cell papillary in 2.8% and ACKD-related in 6.1% of the cases [24]. Taken together, these findings do not support at all the statement that ACKD-associated RCC is the most common RCC subtype in end-stage renal disease [1, 23].

Prognostic Value of Histologic Subtypes of RCC

Previous large sample sized-studies focusing on the prognostic impact of clear cell, papillary and chromophobe RCCs provided contradictory results. In the study of Patard et al. [25] on 4063 RCC cases, the 5-year survival rates for localized clear cell, papillary, and chromophobe RCC were around 73.2% (in our cohort 83.4%), 79.4% (in our cohort 81%), and 87.9% (in our cohort 100%), respectively. However, when histologic subtypes, TNM stage, Furhman grade, and Eastern Cooperative Oncology Group performance status were subjected to a multivariate analysis, the histologic subtypes did

not prove to be an independent prognosticator. By contrast, in the study of Leibovich et al. on 3062 RCCs, clear cell RCC subtype remained a significant predictor of cancer specific death after adjustment for tumor size, stage and grade [26]. Capitanio et al. assessed the magnitude of the effect of histologic subtype on cancer-specific mortality in 11,618 nephrectomies because of RCC [27]. In a multivariate model predicting cancer-specific mortality, histologic subtype remained an independent predictor. In the study of 5339 Italian patients, the histologic subtype was shown to be a predictive variable for cancer-specific mortality in a multivariate analysis [16].

In the present study, the Kaplan Meier curves explored three, prognostically different groups.

The first group, associated with an excellent prognosis, was formed by chromophobe RCC and clear cell papillary RCC. Chromophobe RCC has been described as usually a low-grade neoplasm with little tendency to progress and metastasize; and the reported 5-year survival rates range from 78% to 100% [28, 29]. Predictors of progression include the microscopic tumor necrosis, sarcomatoid change and stage of the tumor [28, 30]. Although chromophobe RCCs should not be graded at the moment, all our cases lacked high-grade features, and only 3 out of 42 displayed microscopic tumor necrosis; and the majority of cases were limited to the kidney, features which help explain the observed excellent survival rate. Regarding clear cell papillary RCC, all our cases were kidney-limited and low-grade tumors, with no evidence of recurrence or metastatic disease in the follow-up period. Similar features have been reported with this subtype all over the world. Because of the excellent outcome data, this entity was recently suggested to be renamed as clear cell papillary neoplasm of low malignant potential [31].

The second prognostic group, displaying a fair outcome (5-year survival rate around 80%), comprised papillary RCC and clear cell RCC. In a recent study investigating correlations between tumor grade and histologic characteristics with clinical outcome in 154 cases of papillary RCC, the histologic subclassification was of relative prognostic significance [32]. Our findings turned out to be quite similar. Type 1 tumors exhibited a pretty good, 92% 5-year survival rate; morphologically these cancers were usually manifested with ISUP grade 1 or grade 2 atypia and were usually presented with kidney-limited disease. In contrast, in type 2 tumors the 5-year survival rate was just 65%; morphologically these cancers were predominantly present with ISUP grade 3 or grade 4 atypia and almost half of the tumor cases had grown outside the kidney at the time of the surgical removal. In Cox proportional hazard analysis, the ISUP grade and TNM stage, but not the morphotype, had an effect on the patient outcome. In an Austrian study on 88 type 1 and 89 type 2

papillary RCCs, the presence and extent (>20%) of histological tumor necrosis were demonstrated to be negative prognostic factors in type 1, but not in type 2 carcinoma [33, 34]. Since the sample size in our series was much smaller, we could not investigate microscopic tumor necrosis in isolation.

The third group, displaying a bad prognosis, was observed with cases of unclassified RCCs, Xp11 translocation RCCs and collecting duct RCCs. More than half of our cases with unclassified RCC exhibited rhabdoid or sarcomatoid change or giant tumor cells, and the majority spread beyond the kidney; these features are predictors of a dismal prognosis. Xp11 translocation RCC and collecting duct RCC have reportedly the worst prognosis, and the corresponding survival data in our series was in complete accordance with this finding.

Grade and Microscopic Tumor Necrosis as Prognostic Parameters in Clear Cell RCC

The survival analysis according to the ISUP grade provided two, statistically different subgroups, namely ISUP 1 plus 2 tumors, characterized by an excellent 5-year survival rate (96%), and ISUP 3 plus 4 tumors, characterized by a much worse survival rate (63%). Delahunt et al. recently regraded 3017 clear cell RCCs from the Mayo Clinic according to the ISUP grades [6]. The difference in the survival rate between the grade 1 and grade 2 groups did not attain a level of significance, and a similar situation was observed in our series. In contrast to our results, however, the survival rates of grade 3 vs grade 4 cancers were significantly different. The reason for the different survival rates in the Szeged and the Mayo series appears to be the difference in the rates of grades: 21.5% and 9% for grade 1, 48.5% and 42% for grade 2, 12.2% and 40% for grade 3, and 17.6% and 9% for grade 4, respectively. The differences in the cases of the grade 1 and grade 3 cancers are significant, with many more grade 1 tumors in Szeged, and many more grade 3 tumors in Rochester. In our cohort, there was no significant difference in the survival rates between cases with grade 1 vs grade 2, and grade 3 vs grade 4 atypia and, therefore, samples with grades 1 and 2, and grades 3 and 4 could be merged to low-grade and high-grade categories. This is an important finding.

Treating microscopic tumor necrosis as a prognostic parameter multivariate analyses yielded contradictory results [6, 35, 36]. In our study, the multivariate Cox model excluded microscopic tumor necrosis as an independent predictor of survival. Nevertheless, we do not rule out the possibility that a larger sample size might lead to a different result because when Delahunt et al. incorporated microscopic tumor necrosis into the ISUP grading system, a significant difference in survival between each of the grades for clear cell RCC was observed [6].

Morphotype and Grade as Prognostic Parameters in Papillary RCC

Papillary RCC is a heterogeneous disease with two histologic subtypes and variations in patient outcomes. Genetically, type 1 tumors are usually associated with alterations in the *MET* pathway, while type 2 tumors have at least three different pathways, among which *CDKN2A* loss or fumarate hydratase gene mutation are associated with a low survival rate [37]. Unfortunately, any correlation between the main driver genetic events and the grade of the tumor was not sought in that study.

In our series, type 1 tumors exhibited a pretty good, 92% 5-year survival rate. By contrast, the 5-year survival rate in type 2 tumors was only 65%. In a Cox proportional hazard analysis, however, the ISUP grade and TNM stage, but not the morphotype, had an effect on patient outcome. Similar results were obtained in a recent publication investigating correlations between tumor grade and histologic characteristics with clinical outcome in 154 cases of papillary RCC [33]. In the present study, no significant difference was found in survival rates between cases with grade 1 vs grade 2, and grade 3 vs grade 4 atypia, while the 5-year CSS rates outcome in terms of the to the two-tiered grading system revealed a significant difference between the low-grade (95%) and high-grade cases (59%).

Two-Tiered Grading for Clear Cell and Papillary RCCs

Since in clear cell RCC and papillary RCC there were no difference in survival in ISUP grade 1 and grade 2, and ISUP grade 3 and grade 4 tumors, we have decided to start reporting these subsets as either “low-grade” (ISUP 1 or 2) or “high-grade” (ISUP 3 or 4). We think that this simplification helps the urologists and oncologists to better understand the pathology report. Our findings are supported by a recent report published by urologists, who simplified the four-tiered Fuhrman grading system into a low-grade/high-grade scheme and the prognostic accuracy of the two schemes agreed perfectly in 2415 cases with clear cell RCC [38].

Morphological Prognosticators and Postoperative Management

The updated assessment of tumor grade, TNM stage, and histological subtype is mandatory since these variables can serve as selection criteria for clinical trials investigating perioperative management of localized kidney cancer [39]. In the ARISER study on organ confined clear cell RCC, for example, high-risk patients were defined on the basis of TNM stage and nuclear grade, and these patients received adjuvant girentuximab immunotherapy postoperatively, unfortunately without clinical benefit [40].

Summary and Conclusions

The distribution and prognostic features of RCC subtypes in 928 Hungarian Caucasian patients were analyzed after a revision of cases according to the 2016 WHO Renal Tumor Classification. A relatively low incidence of papillary RCC was observed. Also, Xp11 translocation RCC and clear cell papillary RCC exhibited incidences of 1.1% and 1.1%, respectively. ACKD-associated RCC did not occur in a cohort of 16 end-stage kidney disease with RCC. In clear cell RCC and papillary RCCs, low-grade (ISUP grade 1 plus 2) and high-grade groups (ISUP grade 3 and 4) were assigned, and these groups were associated with statistically different survival rates. Lastly, among the pathological prognostic factors in clear cell RCC, microscopic tumor necrosis did not prove to be an independent predictor of outcome.

Acknowledgment This study was supported by TÁMOP-4.2.2. A-11/1/KONV-2012-0. Earlier, some findings of the study were presented in a shortened form at the European Congress of Pathology, in Belgrade, Serbia, 2015

References

1. Moch H, Humphrey PA, Ulbright TM, Reuter VE (2016) WHO classification Tumours of the urinary system and male genital organs. International Agency for Research on Cancer, Lyon
2. Srigley JR, Delahunt B, Eble JN et al (2013) The International Society of Urological Pathology (ISUP) Vancouver classification of renal neoplasia. *Am J Surg Pathol* 37:1469–1489
3. Delahunt B, Cheville JC, Martignoni G et al (2013) The International Society of Urological Pathology (ISUP) grading system for renal cell carcinoma and other prognostic parameters. *Am J Surg Pathol* 37:1490–1504
4. Reuter VE, Argani P, Zhou M, Delahunt B, Members of the ISUP Immunohistochemistry in Diagnostic Urologic Pathology Group (2014) Best practices recommendations in the application of immunohistochemistry in the kidney tumors: report from the International Society of Urologic Pathology consensus conference. *Am J Surg Pathol* 38:e35–e49
5. Steffens S, Janssen M, Ross FC et al (2014) The Fuhrman grading system has no prognostic value in patients with nonsarcomatoid chromophobe renal cell carcinoma. *Hum Pathol* 45:2411–2416
6. Delahunt B, McKenney JK, Lohse CM, Leibovich BC, Thompson RH, Boorjian SA, Cheville JC (2013) A novel grading system for clear cell renal cell carcinoma incorporating tumor necrosis. *Am J Surg Pathol* 37:311–322
7. Tan PH, Cheng L, Rioux-Leclercq N et al (2013) Renal tumors: diagnostic and prognostic biomarkers. *Am J Surg Pathol* 37:1518–1531
8. Genega EM, Ghebremichael M, Najarian R et al (2010) Carbonic anhydrase IX expression in renal neoplasms: correlation with tumor type and grade. *Am J Clin Pathol* 134:873–879
9. Gupta R, Billis A, Shah RB et al (2012) Carcinoma of the collecting ducts of Bellini and renal medullary carcinoma: clinicopathologic analysis of 52 cases of rare aggressive subtypes of renal cell carcinoma with a focus on their interrelationship. *Am J Surg Pathol* 36:1265–1278

10. Williamson SR, Cheng L (2016) Clear cell renal cell tumors: not all that is “clear” is cancer. *Urol Oncol* 34:292.e17–292.e22
11. Sobin LH, Gospodarowicz MK, Wittekind C (2009) TNM classification of malignant tumors, 7th edn. Wiley-Blackwell, Oxford
12. Tarabeia J, Kaluski DN, Barchana M, Dichtiar R, Green MS (2010) Renal cell cancer in Israel: sex and ethnic differences in incidence and mortality, 1980–2004. *Cancer Epidemiol* 34:226–231
13. Lipworth L, Morgans AK, Edwards TL et al (2016) Renal cell cancer histologic subtype distribution differs by race and sex. *BJU Int* 117:260–265
14. Pichler M, Hutterer GC, Chromecki TF, Jesche J, Kappel-Kettner K, Pummer K, Zigeuner R (2012) Renal cell carcinoma stage migration in a single European Centre over 25 years: effects on 5- and 10-year metastasis-free survival. *Int Urol Nephrol* 44:997–1004
15. Steffens S, Junker K, Roos FC et al (2014) Small renal cell carcinomas—how dangerous are they really? Results of a large multicenter study. *Eur J Cancer* 50:739–745
16. Novara G, Ficarra V, Antonelli A et al (2010) Validation of the 2009 TNM version in a large multi-institutional cohort of patients treated for renal cell carcinoma: are further improvements needed? *Eur Urol* 58:588–595
17. Moch H, Gasser T, Amin MB, Torhorst J, Sauter G, Mihatsch MJ (2000) Prognostic utility of the recently recommended histologic classification and revised TNM staging system of renal cell carcinoma: a Swiss experience with 588 tumors. *Cancer* 89:604–614
18. Rabjerg M, Mikkelsen MN, Walter S, Marcussen N (2014) Incidental renal neoplasms: is there a need for routine screening? A Danish single-center epidemiological study. *APMIS* 122:708–714
19. Zhou H, Zheng S, Truong LD, Ro JY, Ayala AG, Shen SS (2014) Clear cell papillary renal cell carcinoma is the fourth most common histologic type of renal cell carcinoma in 290 consecutive nephrectomies for renal cell carcinoma. *Hum Pathol* 45:59–64
20. Dhakal HP, McKenney JK, Khor LY, Reynolds JP, Magi-Galluzzi C, Przybycin CG (2016) Renal neoplasms with overlapping features of clear cell renal cell carcinoma and clear cell papillary renal cell carcinoma: a clinicopathologic study of 37 cases from a single institution. *Am J Surg Pathol* 40:141–154
21. Tickoo SK, dePeralta-Venturina MN, Harik LR et al (2006) Spectrum of epithelial neoplasms in end-stage renal disease: an experience from 66 tumor-bearing kidneys with emphasis on histologic patterns distinct from those in sporadic adult renal neoplasia. *Am J Surg Pathol* 30:141–153
22. Végső G, Toronyi E, Hajdu M et al (2011) Renal cell carcinoma of the native kidney: a frequent tumor after kidney transplantation with favorable prognosis in case of early diagnosis. *Transplant Proc* 43:1261–1264
23. Breda A, Luccarelli G, Rodriguez-Faba O et al (2015) Clinical and pathological outcomes of renal cell carcinoma (RCC) in native kidneys of patients with end-stage renal disease: a long-term comparative retrospective study with RCC diagnosed in the general population. *World J Urol* 33:1–7
24. Song C, Hong SH, Chung JS, Byun SS, Kwak C, Jeong CW, Seo SI, Jeon HG, Seo IY (2016) Renal cell carcinoma in end-stage disease: multi-institutional comparative analysis of survival. *Int J Urol* 23:465–471
25. Patard JJ, Leray E, Rioux-Leclercq N, Cindolo L et al (2005) Prognostic value of histologic subtypes in renal cell carcinoma: a multicenter experience. *J Clin Oncol* 23:2763–2771
26. Leibovich BC, Lohse CM, Crispen PL, Boorjian SA, Thompson RH, Blute ML, Chevillie JC (2010) Histological subtype is an independent predictor of outcome for patients with renal cell carcinoma. *J Urol* 183:1309–1315
27. Capitanio U, Cloutier V, Zini L et al (2009) A critical assessment of the prognostic value of clear cell, papillary and chromophobe histological subtypes in renal cell carcinoma: a population-based study. *BJU Int* 103:1496–1500
28. Volpe A, Novara G, Antonelli A et al (2012) Chromophobe renal cell carcinoma (RCC): oncological outcomes and prognostic factors in a large multicentre series. *BJU Int* 110:76–83
29. Frees S, Kamal MM, Knoechlein L et al (2016) Differences in overall and cancer-specific survival of patients presenting with chromophobe versus clear cell renal cell carcinoma: a propensity score matched analysis. *Urology*. doi:10.1016/j.urology.2016.05.048
30. Amin MB, Paner GP, Alvarado-Cabrero I, Young AN, Stricker HJ, Lyles RH, Moch H (2008) Chromophobe renal cell carcinoma: histomorphologic characteristics and evaluation of conventional pathologic prognostic parameters in 145 cases. *Am J Surg Pathol* 32:1822–1834
31. Diolombi ML, Cheng L, Argani P, Epstein JI (2015) Do clear cell papillary renal cell carcinomas have malignant potential? *Am J Surg Pathol* 39:1621–1634
32. Cornejo KM, Dong F, Zhou AG et al (2015) Papillary renal cell carcinoma: correlation of tumor grade and histologic characteristics with clinical outcome. *Hum Pathol* 46:1411–1417
33. Warrick JI, Tsodikov A, Kunju LP et al (2012) Papillary renal cell carcinoma revisited: a comprehensive histomorphologic study with outcome correlations. *Hum Pathol* 45:1139–1146
34. Pichler M, Hutterer GC, Chromecki TF, Pummer K, Mannweiler S, Zigeuner R (2013) Presence and extent of histological tumour necrosis is an adverse prognostic factor in papillary type 1 but not in papillary type 2 renal cell carcinoma. *Histopathology* 62:219–228
35. Frank I, Blute ML, Chevillie JC, Lohse CM, Weaver AL, Zincke H (2002) An outcome prediction model for patients with clear cell renal cell carcinoma treated with radical nephrectomy based on tumor stage, size, grade and necrosis: the SSIGN score. *J Urol* 168:2395–2400
36. Lam JS, Shvarts O, Said JW et al (2005) Clinicopathologic and molecular correlations of necrosis in the primary tumor of patients with renal cell carcinoma. *Cancer* 103:2517–2525
37. The Cancer Genom Atlas Network (2016) Comprehensive molecular characterization of papillary renal-cell carcinoma. *N Engl J Med* 374:135–145
38. Becker A, Hickmann D, Hansen J et al (2016) Critical analysis of a simplified Fuhrman grading scheme for prediction of cancer specific mortality in patients with clear cell renal cell carcinoma—impact on prognosis. *Eur J Surg Oncol* 42:419–425
39. Pierorazio PM, Johnson MH, Patel HD et al (2016) Management of Renal Masses and Localized Renal Cancer: systematic review and meta-analysis. *J Urol*. doi:10.1016/j.juro.2016.04.081
40. Chamie K, Donin NM, Klöpfer P et al (2016) Adjuvant weekly girentuximab following nephrectomy for high-risk renal cell carcinoma: the ARISER randomized clinical trial. *JAMA Oncol*. doi:10.1001/jamaoncol.2016.4419