

The Laryngoscope
© 2016 The American Laryngological,
Rhinological and Otological Society, Inc.

Rotational Thyrotracheopexy After Cricoidectomy for Low-Grade Laryngeal Chondrosarcoma

László Rovó, MD, PhD; Ádám Bach, MD; Balázs Sztanó, MD, PhD; Vera Matievcics, MD;
Ilona Szegedi, MD; Paul F. Castellanos, MD, FCCP

Objectives: The complex laryngeal functions are fundamentally defined by the cricoid cartilage. Thus, lesions requiring subtotal or total resection of the cricoid cartilage commonly warrant total laryngectomy. However, from an oncological perspective, the resection of the cricoid cartilage would be an optimal solution in these cases. The poor functional results of the few reported cases of total and subtotal cricoideotomy with different reconstruction techniques confirm the need for new approaches to reconstruct the infrastructure of the larynx post cricoideotomy.

Study Design: Retrospective case series review.

Methods: Four consecutive patients with low-grade chondrosarcoma were treated by cricoideotomy with rotational thyrotracheopexy reconstruction to enable the functional creation of a complete cartilaginous ring that can substitute the functions of the cricoid cartilage. The glottic structures were stabilized with endoscopic arytenoid abduction lateropexy. Patients were evaluated with objective and subjective function tests.

Results: Tumor-free margins were proven; patients were successfully decannulated within 3 weeks. Voice outcomes were adequate for social conversation in all cases. Oral feeding was possible in three patients.

Conclusion: Total and subtotal cricoideotomy can be a surgical option to avoid total laryngectomy in cases of large chondrosarcomas destroying the cricoid cartilage. The thyrotracheopexy rotational advancement technique enables the effective reconstruction of the structural deficit of the resected cricoid cartilage in cases of total and subtotal cricoideotomy. An adequate airway for breathing, swallowing, and voice production can be reconstructed with good oncological control. In cases where the pharynx is not involved, good swallowing function can also be achieved.

Key Words: Airway reconstruction, chondrosarcoma, conservation resection, cricoid cartilage, cricoideotomy.

Level of Evidence: 4.

Laryngoscope, 00:000-000, 2016

INTRODUCTION

Chondrosarcoma of the larynx is an uncommon tumor, accounting for approximately 0.1% to 1% of all laryngeal neoplasms.¹ Its most frequent variants (95%–99% of cases) are of low- and intermediate-grade disease.^{2,3} Laryngeal chondrosarcomas manifest different pathological behaviors compared to other malignancies of the larynx, and thus the treatment of these tumors is different.^{4,5} Complete surgical excision with negative margins is the treatment of choice for oncological control.^{6,7} The balance between radical resection and the preservation of laryngeal function is crucial. In the case of cricoid chondrosarcoma, how well this can be achieved depends on how much and what part of the cricoid cartilage remains. It is the only complete ring in the cartilage

framework of the airway and is key to airway integrity. This makes preservation of function after cricoideotomy an obvious challenge.⁸ The difficulty in reconstruction after the loss of the cricoid often leads to total laryngectomy.^{9,10} To avoid this, many less radical procedures have been described. Nonetheless, due to the nature of these techniques, the chance of tumor recurrence increases.^{11,12} In the case of more radical techniques, like hemi-cricoidectomy and the few reported cases of subtotal and total cricoideotomy, prolonged stenting is unavoidable. If autografts such as with rib are used, the donor site complications are not rare. Stenosis is a common risk.^{13–15} The authors report a reconstruction technique useful after total and subtotal cricoideotomy for cases of large, low-grade chondrosarcomas of the cricoid cartilage. This technique provides an oncologically sound surgery using only local structures for reconstruction. Therefore, it efficiently leads to an adequate and stable airway with acceptable voice quality and swallowing function.

MATERIALS AND METHODS

Patients

In four consecutive patients, total cricoideotomy was performed in three patients (1, 2, and 4), and subtotal cricoideotomy was performed in one patient (3). All had low-grade chondrosarcoma of the cricoid cartilage. In all cases, magnetic resonance

From the Department of Otorhinolaryngology and Head-Neck Surgery (L.R., A.B., B.S., V.M.), the Department of Anesthesiology and Intensive Therapy (I.S.), Faculty of Medicine, University of Szeged, Hungary; and the Department of Otolaryngology-Head and Neck Surgery (P.F.C.), University of Alabama at Birmingham, Birmingham, Alabama, U.S.A.

Editor's Note: This Manuscript was accepted for publication May 16, 2016.

The authors have no funding, financial relationships, or conflicts of interest to disclose.

Send correspondence to Ádám Bach, Tisza Lajos krt. 111., 6725, Szeged, Hungary. E-mail: bach.adam@med.u-szeged.hu

DOI: 10.1002/lary.26142

TABLE I.
Patient Data and Type of the Surgery.

	Patient 1	Patient 2	Patient 3	Patient 4
Age (year)	59	35	30	64
Gender	Male	Male	Female	Male
Maximum diameter of the tumor (cm)	4.5	3.0	2.0	4.5
Extension of the tumor	Cricoid cartilage	Cricoid cartilage	Cricoid cartilage, 1st tracheal cartilage, lower quarter of the thyroid cartilage on the left side	Cricoid cartilage, retropharyngeal space, prevertebral fascia, oesophageal introitus
Mobility of the vocal cords	Bilaterally slightly impaired	Normal	Normal	Bilateral complete immobility
Previous surgery	-	-	-	Hemicricoidectomy, right-sided arytenoidectomy, partial resection of the right thyroid lamina
Cricoidectomy	Total	Total	Subtotal/right part of the cricoid lamina	Total

imaging or computed tomography (CT) imaging demonstrated a round cystic lesion of the posterior lamina of cricoid cartilage. The cortical layer of the cartilage was infiltrated by the tumor in case 1, 2, and 4. In the third case, the lesion infiltrated the first tracheal cartilage and the lower quarter of the thyroid cartilage on the ipsilateral (left) side. The maximum diameters of the tumors were 4.5, 3.0, 2.0, and 4.5 cm (cases 1, 2, 3, and 4), respectively. None of the patients had cervical or mediastinal adenopathy or findings of distant metastases. Patient data is reported in Table I.

The first three patients presented with progressive dysphonia and dyspnea that had started at least 4 months prior to their diagnosis. Vocal fold mobility was normal in the second and third cases. The first case had slightly impaired mobility.

The fourth patient was tracheostomy-dependent and was referred to the authors after tumor recurrence despite multiple laryngeal surgeries and external beam radiation therapy. Hemicricoidectomy, partial resection of the right thyroid lamina, and right-sided arytenoidectomy were previously performed. The tumor recurrence was spreading into the retropharyngeal space, infiltrating the surrounding soft tissues and extending to the prevertebral fascia. Preoperative endoscopy revealed complete immobility of both vocal folds.

Surgical Technique

All operations were performed under general anesthesia through a horizontal incision made at the level of the cricoid cartilage. The trachea was bluntly dissected from larynx to superior mediastinum, protecting the recurrent laryngeal nerves and great vessels. Isolating the tumor, the cricothyroid and cricotracheal ligaments and the inferior horns of the thyroid cartilage were transected (Figure 1.a). In the cases of total cricoidectomy (cases 1, 2, 4) the posterior and lateral cricoarytenoid muscles were sacrificed. The cricoid cartilage was dissected at the cricotracheal ligament and then completely removed together with its outer perichondrium (Figure 1.b). The pharyngeal constrictor muscle and the esophagus were carefully dissected from the cricoid and the rest of the tissue to be resected. Then a low, inferior tracheotomy was performed through a separate skin incision below the fifth tracheal cartilage. The orotracheal tube was replaced there (cases 1, 2, 3); in patient 4, it

was repositioned to this distal location from the existing tracheostomy.

Resection Variations in Specific Cases

In the first patient, the articular surface of the arytenoid cartilages had to be resected due to the massive extension of the lesion. In the third patient, the first two tracheal rings and the lower part of the thyroid cartilage were also resected below the ipsilateral vocal fold on the left side (Figure 2.a,b). In the fourth patient, a hemipharyngectomy, a partial resection of the esophageal introitus, and an expanded resection of the surrounding soft tissues were also performed.

Laryngotracheal Anastomosis

The distal trachea was mobilized until it could be easily pulled up to the level of the thyroid cartilage. The trachea was then rotated clockwise (looking at the trachea from above) by about 90 degrees for the anastomosis (Figure 1.c) simply because it is easier for a right-handed surgeon. In case 3, where the right side of the cricoid lamina with the right arytenoid remained after the resection, the tracheal trunk was rotated counter-clockwise to complete and support the resected part of the cricoid ring. The right posterolateral edge of the proximal tracheal cartilage was sutured to the left posterior part of the thyroid cartilage with absorbable suture (0-PDS, needle: 26 mm, 1/2 circle, round-bodied, Ethicon, Somerville, NJ) (Figure 1.d, 3.a). These massive holding threads fixed the laryngotracheal anastomosis during the healing period, and the robust needle was necessary for penetration through the rigid thyroid lamina. A second suture was placed on the opposite corner of the thyroid cartilage (the right posterior corner); thus, the trachea was fixed to the thyroid lamina on both sides rotated by approximately 90 degrees. This formed a complete ring, thereby replacing the structure of the missing cricoid cartilage.

In the next step, the arytenoid and interarytenoid mucosa were separately sutured (Vicryl 2.0, Ethicon) to the posteriorly rotated side (formerly the right side) of the trachea (Figure 3.b). Then a soft stent (silicon tube filled with gauze) was placed into the airway cavity within the reconstruction to promote better healing with less cicatricial scarring of the mucosa. This also

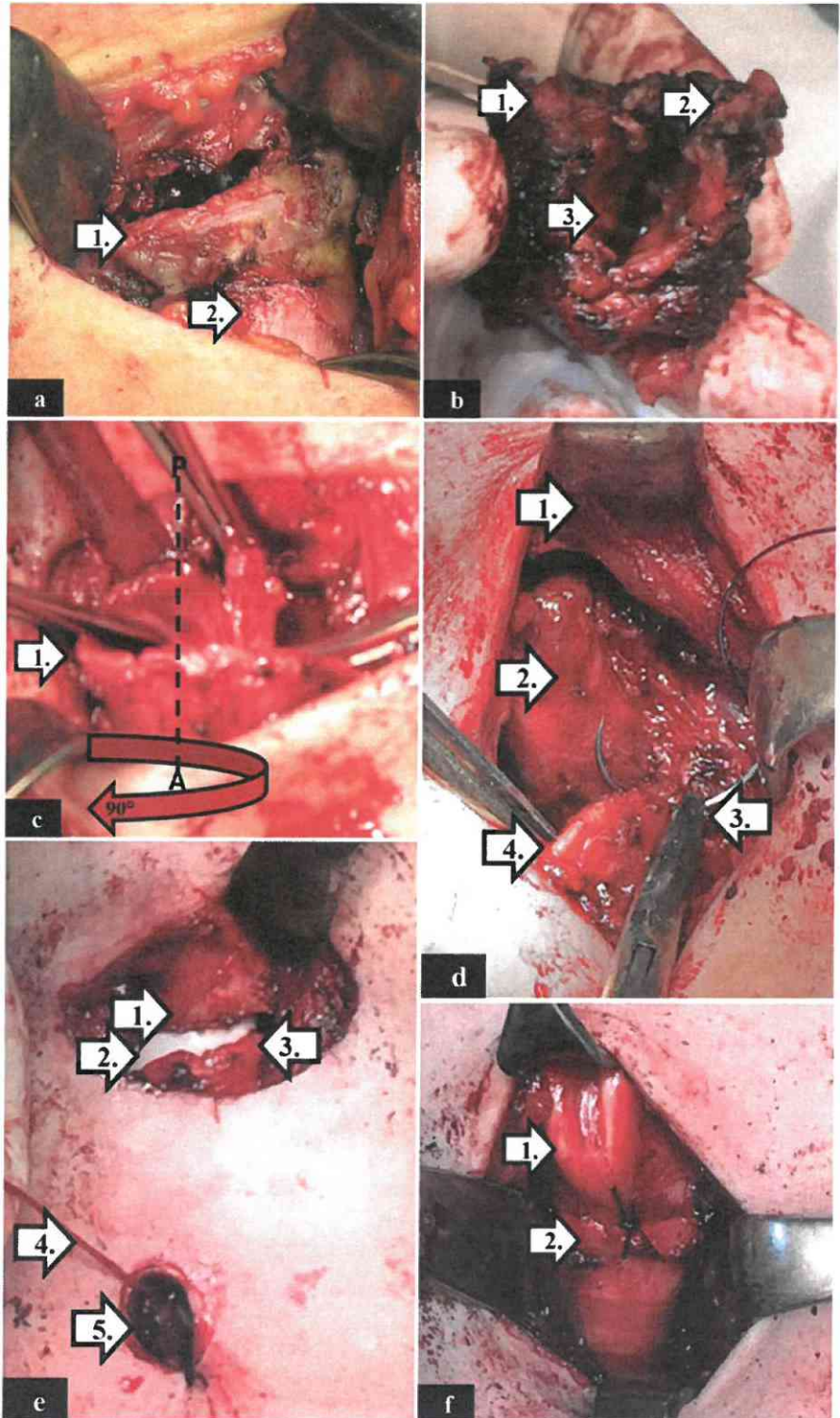


Fig. 1. (1.a) The explored cricoid cartilage (patient 2). The cricothyroid ligament is already transected. 1: the cricoid cartilage; 2: the first tracheal ring. (1.b) The completely removed cricoid cartilage (patient 2). 1,2: the articular surface of the cricoarytenoid joint; 3: the inner surface of the trachea is infiltrated by the tumor. (1.c) The rotated tracheal trunk (patient 2). 1: the trachea is rotated clockwise approximately by 90 degrees (the anteroposterior axis is marked by the dashed line). (1.d) The fixation of the rotated tracheal trunk (patient 2). 1: the thyroid cartilage is retracted; 2: the anterior wall of the esophagus; 3: the right part of the rotated trachea will be sutured to the left posterior part of the lower edge of the thyroid cartilage; 4: the posteriorly rotated midline of the trachea. (1.e) The soft stent in the reconstructed larynx (patient 2). 1: the inferior edge of the thyroid cartilage; 2: the soft stent; 3: the first rotated tracheal cartilage; 4: fixing thread of the soft stent; 5: inferior tracheostomy (the endotracheal tube is temporarily removed). (1.f) The reconstructed cartilage framework of the larynx (patient 2). 1: the remnant of the thyroid cartilage; 2: the rotated first tracheal cartilage.

served to stabilize the arytenoids in their abducted position (Figure 1.e, 2.b). The lower arch of the thyroid cartilage and the anterior (previously left) side of the trachea were sutured with four to five interrupted sutures. In summary, a modified thyrotracheopexy was performed in which the anterior wall of the

subglottic part of the larynx was reconstructed with the left side of the trachea, and the posterior wall was reconstructed with the right side. The new tracheostomy was intubated with a cuffed tracheal cannula at the end of the surgery. Parenteral ceftriaxone (Ceftriaxone Kabi; Frensenius Kabi Hungary,

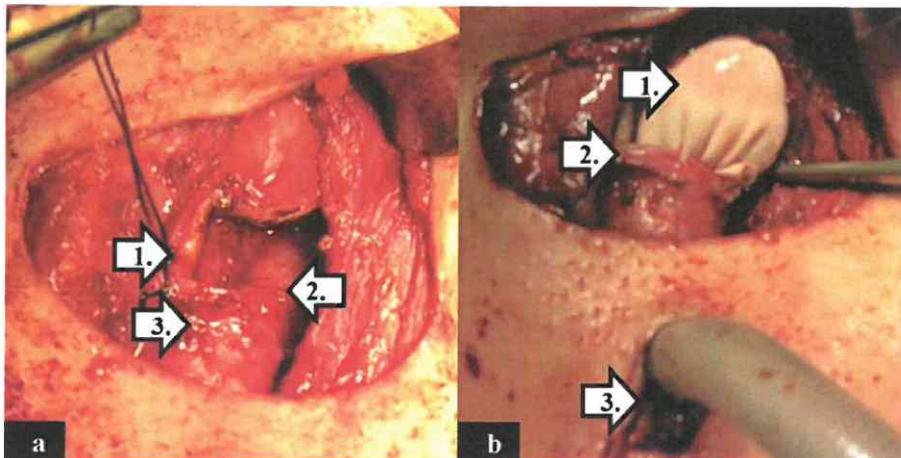


Fig. 2. Extension of the resection (patient 3). (2.a) 1: the left side of the thyroid cartilage is resected under the level of the vocal fold; 2: the left pyriform sinus; 3: the third rotated tracheal ring. (2.b) 1: soft stent; 2: the third rotated tracheal ring; 3: distal tracheostomy. [Color figure can be viewed in the online issue, which is available at www.laryngoscope.com.]

Hungary, Budapest) and metronidazole (Klion; Richter Gedeon, Hungary, Budapest) antibiotics were administered in all cases at least for 7 days.

This procedure ensured a sufficiently wide subglottic space. However, the glottic aperture was not intrinsically assured. In cases of total cricoidectomy, the lack of the muscles attached to the arytenoid cartilages caused the prolapse of the interarytenoid mucosa and the passive adduction of the vocal folds after removing the soft stent. Therefore, a second operation was performed involving a unilateral (case 4) or bilateral (cases 1, 2) arytenoid lateropexy with a special endolaryngeal thread guide instrument (ETGI; Mega Kft, Szeged, Hungary).^{16,17} In the same surgery (cases 2, 4), the edema of the supraglottic soft tissue and interarytenoid mucosa was reduced by Ultra Dream Pulse (UDP) CO₂ laser (DS-40U, Daeshin Enterprise, Seoul, Korea).

Functional Evaluation and Follow-up Care

The voice samples were recorded with a high sensitivity (40Hz–16kHz) condenser head microphone (Audio-Technica ATM75) at a sampling frequency of 96 kHz, 24 bit (Tascam US 122MkII external soundcard) and analyzed by Praat 5.3.2.9. software (www.praat.org). The following acoustic parameters were recorded in this study: mean fundamental frequency, jitter, shimmer, harmonics-to-noise ratio, and mean phonation time. Each patient was invited to fill out the Hungarian version of Voice Handicap Index (VHI) questionnaire.^{18,19} The functional outcomes of the surgery in terms of breathing, voice, swallowing, and overall satisfaction were evaluated by the Quality of Life (QOL) Questionnaire of the Lausanne team.²⁰ Paying special attention to the swallowing problems, the patients also completed the Swallowing Quality of Life questionnaire (SWAL-QOL) by McHorney.²¹ Spirometric measurements were performed by using a THOR Laboratories Kft., Székesfehérvár, Hungary. Peak inspiratory flow was registered in all cases.^{22,23} The status of the postoperative airway was investigated by high-resolution three-dimensional CT reconstruction. Follow-up evaluations included systematic endoscopic and radiological examinations (Figure 4.a,b and Figure 5).

RESULTS

No major perioperative or postoperative complications occurred. Tumor-free margins were proven by histology in all cases. The laryngeal soft stents (cases 2, 3,

4) were removed during direct laryngoscopy with general anesthesia on the ninth, sixth, and 12th postoperative day, respectively. Events of the early postoperative period are shown in Table II. Endoscopic arytenoid abduction lateropexy (EAAL) was performed in cases of total cricoidectomies (cases 1, 2, 4) on the 14th, 9th, and 12th postoperative day, respectively. The edema of the false vocal folds was also reduced by Ultra Dream Pulse (DS-40U, Daeshin Enterprise) CO₂ laser in the same session. Edema of the supraglottic region was also reduced by laser in the third patient on the 39th postoperative day. In the second case, reopening of the closed tracheostomy was necessary for 1 day due to safety reasons 7 weeks after the surgery. Speech ability was preserved in all cases. The acoustic parameters, VHI, and QOL scores for every subject are shown in Table III. Oral feeding was allowed for the first and third patient

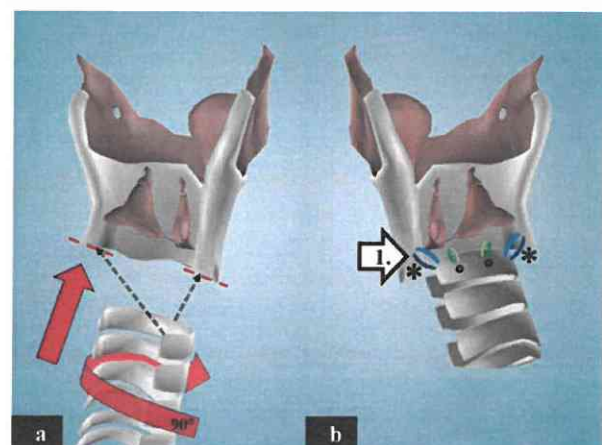
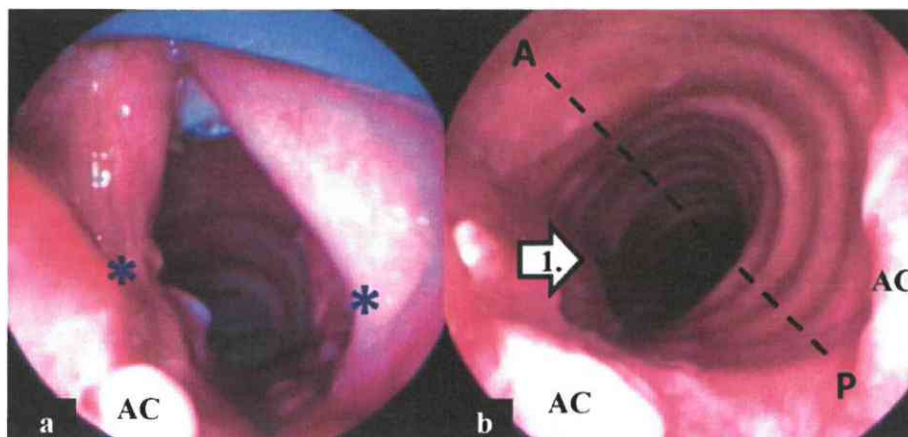


Fig. 3. Three-dimensional model of the reconstruction. (3.a) The tracheal cartilage is pulled up and is rotated clockwise approximately by 90 degrees. The inferior horns of the thyroid cartilage are resected. The dashed black lines indicate the fitting points of the reconstruction. (3.b) The posteriorly rotated right side of the trachea is sutured to the thyroid cartilage and to the arytenoid and interarytenoid mucosa. 1: the posterior suture line. [Color figure can be viewed in the online issue, which is available at www.laryngoscope.com.]

Fig. 4. Postoperative endoscopic view (patient 1). (4.a) A properly wide glottic gap was achieved by bilateral arytenoid lateralization. *Position of the sutures of the arytenoid lateralization; AC: arytenoid cartilage. (4.b) A wide subglottic space was formed by the reconstruction. 1: the membranous wall of the trachea; (the anteroposterior axis is marked by the dashed line); AC: arytenoid cartilage. [Color figure can be viewed in the online issue, which is available at www.laryngoscope.com.]



from the ninth postoperative day. Nasogastric feeding tube was used in the second patient for 20 days. The first three patients were able to tolerate a normal diet. The fourth patient, who had a partial pharyngectomy, was able to swallow saliva, but remained gastrostomy-dependent throughout the follow-up period (9 months). Functional results are reported in Table III. During the follow-up time (39, 18, 17, 9 months, respectively), the patients were free from local and distant recurrences.

DISCUSSION

Chondrosarcoma is the most common nonepithelial neoplasm in the laryngeal region. In 75% to 80% of the cases, the lesion arises from the cricoid cartilage, with a special predilection for the paramedian inner surface of the posterior plate.^{1,24} Their relatively low malignant potential allows the application of conservative surgical procedures. Options may vary from endoscopic resection and open-neck partial resection to total laryngectomy, depending on the localization, extension, and histological grade of the tumor.²⁵ If a complex surgery is not feasible, debulking through an anterior laryngofissure or endoscopic laser resection (generally by CO₂ laser) can be performed.¹¹ If the tumor involves less than half of the cricoid cartilage, conservative surgical treatment can be considered. Vertical hemircricoidectomy is a good surgical option with adequate oncologic and functional results as well.¹⁴ For the reconstruction of the airway after partial cricoidectomy, several autologous graft materials have been published. Thyroid cartilage, rib cartilage, rotated epiglottic cartilage, scapular tip, and a hyoidsternohyoid osteomuscular flap can be used to reestablish the posterior wall of the larynx.^{26,27} Delaere et al. published a case of a cricoid chondrosarcoma treated with a vertical hemircricoidectomy, followed by a complex two-step tracheal autotransplantation procedure.²⁸ However, the need for total cricoidectomy takes the problem of the airway reconstruction to a higher level. Total cricoidectomy was first described for the treatment of large chondrosarcomas by Leroux-Robert in 1956 and was recently cited by Nakano et al., Thomé et al., and de Vincentiis et al. in connection with a total

of six cases.^{10,29–31} The shortest stenting periods were 34, 90, and 56 days, respectively. Thomé et al. did not provide any functional results for their two cases. In the other two series (four patients), decannulation was possible in only one case.^{10,31}

Because the cricoid ring is the critical structure supporting normal laryngeal function, these outcomes are not surprising. In the opinion of the authors, poor functional results from the extended resection of the cricoid can be primarily traced back to two problems. First, the reconstruction of the subglottic airway is difficult with the existing (previously described) graft options.

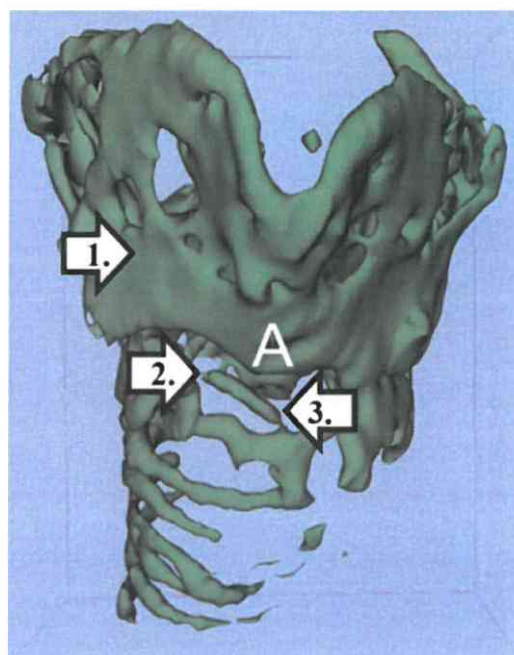


Fig. 5. Three-dimensional computed tomography reconstruction of the laryngeal framework (patient 2, 6th postoperative month). 1: the remnant of the thyroid cartilage; 2: the cricoid cartilage is resected; 3: the rotated tracheal rings (sagittal view). [Color figure can be viewed in the online issue, which is available at www.laryngoscope.com.]

TABLE II.
Postoperative Care After Total/Subtotal Cricoidectomy.

	Patient 1	Patient 2	Patient 3	Patient 4
Removing of the soft stent (postoperative day)	No stenting	9	6	12
Additional intervention (postoperative day)	Bilateral EAAL	Bilateral EAAL Edema reduction with UDP laser	Edema reduction with UDP laser	Unilateral EAAL Edema reduction with UDP laser
	14	9	39	12
Decannulation (postoperative day)	14	20	6	17
Oral feeding (postoperative day)	9	20	9	Gastrostomy-dependent

UDP = Ultra Dream Pulse (DS-40U, Daeshin Enterprise, Seoul, Korea); EAAL = endoscopic arytenoid abduction lateropexy.

Second, published methods do not address two issues of airway integrity: the unstable and often denervated arytenoid cartilages and the prolapse of the supraglottic soft tissues into the laryngeal cavity.

Based on this work, the subglottic support that is disrupted by the cricoidectomy can be reconstructed in a stable manner with the rotation of the autologous tracheal advancement flap. The remnant of the thyroid cartilage, together with the rotated trachea, provide a well-vascularized and mucosa-covered rigid ring. The segmental tracheoesophageal arteries must be transected on the anterior side (after rotation) down to the proximal three to four tracheal rings (where the maximal rotation happens) and maintained on the posterior side. Moreover, the transverse intercartilaginous arteries and the lateral longitudinal anastomoses remain intact and provide the basis for a quick, complication-free recovery.³² Postthyrotracheopexy, the arytenoid cartilages, and the surrounding soft tissues are sitting atop and supported by the rotated tracheal wall. This connection, however, does not prevent the passive adduction of the vocal folds because the cricoarytenoid joints are severed and the articular surface is resected on one or both sides. There are also no attachment points for three of the four muscles that act on the arytenoid bodies. The thyroarytenoid is the only

muscle that may still be functionally connected, and it only adducts the vocal fold. This can adversely affect the airway aperture. Endoscopic arytenoid abduction lateropexy can effectively address this problem because it has been already demonstrated in cases of bilateral vocal fold immobility.^{16,17,33} An adequately wide glottic gap can therefore be produced with this minimally invasive procedure after total cricoidectomy.

The laryngotracheal mucosa is difficult to anastomose due to the narrow surgical access. That is why the use of the soft stent is placed within the upper airway but only for a short postoperative interval. It also helps to keep the unstable arytenoids separated, obviating the need to use a Montgomery T-tube (e.g., The Montgomery Safe-T-Tube; Boston Medical Products, MA). The effectiveness of this approach is demonstrated by the results of the respiratory function tests. Some degree of dyspnea on exertion occurred in all patients. This was especially in the only female (case 3), whose laryngeal structures were significantly smaller and whose thyroid lamina had been resected. All the other patients were able to return to premorbid activities of daily living.

Swallowing and the prevention of the aspiration are also important issues. In those patients for whom the pharyngeal structures remained intact (cases 1, 2, 3),

TABLE III.
Functional Results.

	Patient 1	Patient 2	Patient 3	Patient 4	Physiological Values
Mean fundamental frequency (Hz)	98,46	134,9	150,1	86,65	Female: 155–334; male: 85–196
Mean phonation time(s)	4,12	2,39	3,55	2,91	10–20
Jitter (%)	7,45	9,36	9,65	8,05	< 1.04
Shimmer (%)	20,86	19,97	19,47	15,24	< 3.81
Harmonics-to-noise ratio (dB)	1,86	4,6	0,48	2,17	20 <
Voice Handicap Index	14	51	20	25	Min: 0; max: 120
Peak inspiratory flow L/min)	108	134,4	90	83,4	–
Quality of Life	9	14	10	12	Min: 6; max: 25
SWAL-QOL	212	167	200	Gastrostomy-dependent	Min: 44; max: 220
Follow-up (month)	38	17	16	8	

SWAL-QOL: Swallowing Quality of Life.

radiologically proven, safe swallowing could be achieved in a reasonable period of time. The results presented confirm that the mucosa of the arytenoid region can be preserved by these techniques. The protecting laryngeal reflex enables an adequate pharyngeal swallowing function despite the impairment of the glottic motions. Crumley observed this after partial medial arytenoidectomy as well.³⁴ For the patient who required a partial pharyngectomy (case 4), the widening of the esophageal introitus such as with a free graft or other flap technique might still be a possible option in the future to restore physiological deglutition.

A decline of voice quality was inevitable in these patients due to the resection of the arytenoid muscles (cases 1, 2, 4). Despite the whispering voice and the relatively low phonation time, a socially acceptable voice was maintained in all patients. While accounting for oncological concerns in radical surgery, it may still be possible to preserve the muscles attached to the arytenoids and the recurrent laryngeal nerve branches. This could lead to higher voice quality by the preserved motion of the vocal folds.

CONCLUSION

Total cricoideotomy is an excellent surgical option to obviate the need for total laryngectomy in cases of large chondrosarcomas destroying the cricoid cartilage. We present an easily performed reconstruction option using local tissues that are well-vascularized, readily available, and appropriately shaped. This facilitates the creation of an adequate airway in a single- or two-stage process, and enables voice preservation and the potential for safe swallowing. Moreover, this can be achieved in accordance with the concepts of oncologically sound surgery and only a temporary tracheostomy. This technique is described for low-grade chondrosarcoma but might be a reasonable option for other types of cricoid malignancy or even high-grade subglottic stenosis.

Acknowledgment

The authors wish to thank Dr. Kathleen I. Castellanos for reviewing the article. Her assistance is greatly appreciated.

BIBLIOGRAPHY

- Thompson LD, Gannon FH. Chondrosarcoma of the larynx: a clinicopathologic study of 111 cases with a review of the literature. *Am J Surg Pathol* 2002;26:836–851.
- Thompson LD. Chondrosarcoma of the larynx. *Ear Nose Throat J* 2004;83:609.
- Rinaldo A, Howard DJ, Ferlito A. Laryngeal chondrosarcoma: a 24-year experience at the Royal National Throat, Nose and Ear Hospital. *Acta Otolaryngol* 2000;120:680–688.
- Brandwein M, Moore S, Som P, Biller H. Laryngeal chondrosarcomas: a clinicopathologic study of 11 cases, including two "dedifferentiated" chondrosarcomas. *Laryngoscope* 1992;102:858–867.
- Garcia RE, Gannon FH, Thompson LD. Dedifferentiated chondrosarcomas of the larynx: a report of two cases and review of the literature. *Laryngoscope* 2002;112:1015–1018.
- Alexander S, Claus B, Katherine LL, Karl H, Ramin N. Chondrosarcoma of the larynx and review of the literature. *Anticancer Res* 2007;27:2925–2930.
- Gil Z, Fliss DM. Contemporary management of head and neck cancers. *Isr Med Assoc J* 2009;11:296–300.
- Jurg H, von Schulthess GK, Christoph Z. Diseases of the Brain, Head & Neck, Spine 2012–2015: Diagnostic Imaging and Interventional Techniques. Milano, Italy: Springer-Verlag Italia; 2012.
- Tiwari R, Mahieu H, Snow G. Long-term results of organ preservation in chondrosarcoma of the cricoid. *Eur Arch Otorhinolaryngol* 1999;256:271–276.
- Nakano Y, Asakura K, Himi T, Kataura A. Chondrosarcoma of larynx: a case successfully reconstructed after total cricoideotomy. *Auris Nasus Larynx* 1999;26:207–211.
- Inon B, Roy H, Raphael F, Jacob S. Chondrosarcoma of the Larynx. *Isr Med Assoc J* 2012;14:681–684.
- Cantrell RM, Reibel JF, Jahrsdoerfer RA, Johns ME. Conservative surgical treatment of chondrosarcoma of the larynx. *Ann Otol Rhinol Laryngol* 1980;89:567–571.
- Saleh HM, Guichard C, Russier M, Kemeny JL, Gilain L. Laryngeal chondrosarcoma: a report of five cases. *Eur Arch Otorhinolaryngol* 2002;259:211–216.
- Cohen JT, Postma GN, Gupta S, Koufman JA. Hemircicoideotomy as the primary diagnosis and treatment for cricoid chondrosarcomas. *Laryngoscope* 2003;113:1817–1819.
- Koltai PJ, Ellis B, Chan J, Calabro A. Anterior and posterior cartilage graft dimensions in successful laryngotracheal reconstruction. *Arch Otolaryngol Head Neck Surg* 2006;132:631–634.
- Rovo L, Madani S, Sztano B, et al. A new thread guide instrument for endoscopic arytenoid lateropexy. *Laryngoscope* 2010;120:2002–2007.
- Szakacs L, Sztano B, Matievics V, et al. A comparison between transoral glottis-widening techniques for bilateral vocal fold immobility. *Laryngoscope* 2015;125:2522–2529. doi: 10.1002/lary.25401.
- Jacobson BH, Johnson A, Grywalski C, et al. The voice handicap index (VHI): development and validation. *Am J Speech Lang Pathol* 1997;6:66–70.
- Smechak G, Szakacs L, Sztano B, Szamoskozi A, Rovo L. Is a deteriorated voice quality necessary after glottis enlarging procedures? 8th Congress of the European Laryngological Society, Vienna. *Eur Arch Otorhinolaryngol*; 2010.
- Jaquet Y, Lang F, Pilloud R, Savary M, Monnier P. Partial cricotracheal resection for pediatric subglottic stenosis: long-term outcome in 57 patients. *Thorac Cardiovasc Surg* 2005;130:726–732.
- McHorney CA, Rosenbek RJC, Chignell K, et al. The SWAL-QOL and SWAL-CARE outcomes tool for oropharyngeal dysphagia in adults: III. Documentation of reliability and validity. *Dysphagia* 2002;17:97–114.
- Cantarella G, Fasano V, Buechioni E, Domenichini E, Cesana BM. Spirometric and plethysmographic assessment of upper airway obstruction in laryngeal hemiplegia. *Ann Otol Rhinol Laryngol* 2003;112:1014–1020.
- Kashima HK. Documentation of upper airway obstruction in unilateral vocal cord paralysis: flow-volume loop studies in 43 subjects. *Laryngoscope* 1984;94:923–937.
- Piazza C, Del Bon F, Grazioli P, et al. Organ preservation surgery for low- and intermediate-grade laryngeal chondrosarcomas: analysis of 16 cases. *Laryngoscope* 2014;124:907–912.
- Policarpo M, Taranto F, Aina E, Aluffi PV, Pia F. Chondrosarcoma of the larynx: a case report. *Acta Otorhinolaryngol Ital* 2008;28:38–41.
- Hantzakos A, Evrard AS, Lawson G, Remacle M. Posthemircicoideotomy reconstruction with a composite hyoid-sternohyoid osteomuscular flap: the Rethi-Ward technique. *Eur Arch Otorhinolaryngol* 2007;264:1339–1342.
- Chanowski EJ, Haxer MJ, Chepeha DB. Microvascular cricoid cartilage reconstruction with the thoracodorsal artery scapular tip autogenous transplant. *Laryngoscope* 2012;122:282–285.
- Delaere PR, Vertriest R, Hermans R. Functional treatment of a large laryngeal chondrosarcoma by tracheal autotransplantation. *Ann Otol Rhinol Laryngol* 2003;112:678–682.
- Leroux-Robert J. 3 cases of chondromatous tumors in lamina of cricoid cartilage treated by total or partial sub-perichondrial cricoideotomy. *Ann Otolaryngol Chir Cervicofac* 1956;73:585–590.
- Thome R, Thome DC, de la Cortina RA. Long-term follow-up of cartilaginous tumors of the larynx. *Otolaryngol Head Neck Surg* 2001;124:634–640.
- de Vincentiis M, Greco A, Fusconi M, Pagliuca G, Martellucci S, Gallo A. Total cricoideotomy in the treatment of laryngeal chondrosarcomas. *Laryngoscope* 2011;121:2375–2380.
- Monnier P. Applied surgical anatomy of the larynx and trachea. In: Monnier P, ed. *Pediatric Airway Surgery; Management of Laryngotracheal Stenosis in Infants and Children*. Berlin, Heidelberg, Germany: Springer Verlag; 2011:7–29.
- Rovo L, Venczel K, Torkos A, Majoros V, Sztano B, Jori J. Endoscopic arytenoid lateropexy for isolated posterior glottic stenosis. *Laryngoscope* 2008;118:1550–1555.
- Crumley RL. Endoscopic laser medial arytenoidectomy for airway management in bilateral laryngeal paralysis. *Ann Otol Rhinol Laryngol* 1993;102:81–84.